



Sequelae of large-head metal-on-metal hip arthroplasties: current status and future prospects

Christiaan P. van Lingen¹

Luigi M. Zagra²

Harmen B. Ettema¹

Cees C. Verheyen¹

- Large-head metal-on-metal (MoM) bearings were re-popularised in the late 1990s with the introduction of modern hip resurfacing (HR), followed closely by large metal head total hip arthroplasty (THA). A worldwide increase in the use of MoM hip arthroplasty subsequently saw a sharp decline, due to serious complications.
- MoM was rapidly adopted in the early 2000s until medical device alerts were issued by government regulatory agencies and national and international organisations, leading to post-marketing surveillance and discontinuation of these implants.
- Guidelines for MoM hip implant follow-up differ considerably between regulatory authorities worldwide; this can in part be attributed to missing or conflicting evidence.
- The authors consider that the use of large-head MoM THA should be discontinued. MoM HR should be approached with caution and, when considered, should be used only in patients who meet all of the recommended selection criteria, which limits its indications considerably.
- The phased introduction of new prostheses should be mandatory in future. Close monitoring of outcomes and long-term follow-up is also necessary for the introduction of new prostheses.

Keywords: metal-on-metal; MoM; large-head; hip arthroplasty; complications

Cite this article: van Lingen CP, Zagra LM, Ettema HB, Verheyen CC. Sequelae of large-head metal-on-metal hip arthroplasties: current status and future prospects. *EFORT Open Rev* 2016;1:345-353. DOI: 10.1302/2058-5241.1.160014.

Introduction

Large-head metal-on-metal (MoM) bearings were re-popularised in the late 1990s with the introduction of

modern hip resurfacing (HR), followed shortly afterward by large metal head total hip arthroplasty (THA). The introduction of MoM articulations led to a worldwide increase in the use of MoM hip arthroplasty, which subsequently saw a sharp decline. MoM was rapidly adopted in the early 2000s until adverse reports in the literature led to medical device alerts which were issued by government regulatory agencies and national and international organisations, leading to post-marketing surveillance and the discontinuation of these implants.¹⁻³ It is estimated that more than one million large-head MoM hips have been implanted to date. MoM arthroplasties are among the least successful modern hip implants.⁴

As a result of safety concerns, several health authorities, scientific organisations and research groups have published recommendations for their use and follow-up. The British Hip Society advised that, as of 2011, large-stemmed MoM primary THA (excluding HR) should no longer be performed.⁵ In 2012 the Dutch Orthopaedic Association was the first nationwide society to suspend the use of all large-head (> 36 mm) MoM articulations; this advice has since been followed by several societies, including the European Federation of National Associations of Orthopaedics and Traumatology (EFORT).^{6,7} These concerns led the European Commission to ask for the opinion of the Scientific Committee on Emerging and Newly-Identified Health Risks (SCENIHR) regarding the safety of MoM implants.⁸

Guidelines for follow-up of these implants differ considerably between regulatory authorities worldwide, which can be attributed to missing or conflicting evidence.⁹

A number of studies have recently been published which may assist in defining the use of MoM bearings. Registry data reports a disappointing survival rate ranging between 56.7% and 88.9% at ten years, depending on implant design of large-diameter MoM THA.^{10,11} All available guidelines seem to agree that large-diameter MoM THA should not be used at present, and patients should remain under regular clinical surveillance.¹

A more fierce debate surrounds the use of MoM HR. Long-term results of modern MoM HR are more encouraging, with overall survival rates reported by the developers as well as independent surgeons ranging between 87.1% and 95.8% at 15 years.¹⁰ Registry data on survival



Fig. 1 Hip resurfacing: Birmingham hip resurfacing system (Smith & Nephew; Andover, Massachusetts).

of some types of MoM HR arthroplasties are sufficient, according to the guidelines of the National Institute for Health and Clinical Excellence.¹²

In this review we describe the outcomes and problems of MoM implant usage, and why these implants are now considered to be unacceptable.

Two different implants

There are two different types of large-head MoM hip prostheses: MoM HR and MoM THA (see Figs 1 and 2). Both types were designed with young and active patients in mind. Purported advantages over conventional polyethylene articulations were low wear rates, increased range of motion (with increasing head size), and improved stability and reduced dislocation rates,¹³ although these merits have been debated. An estimated 35% of all hip arthroplasties performed in the US between 2005 and 2006 involved large head MoM implants.¹⁴ In 2008, the UK National Joint Registry (NJR) recorded a peak in the use of MoM implants.¹⁵ The use of HR has been advocated ahead of THA due to several apparent advantages: preservation and conservation of bone stock on the femoral side (but not the acetabular side);¹⁶⁻²⁰ easier replication of biomechanics and limb length; and the absence of modular components with a taper.²¹ Both types have the advantage of reducing the risk of dislocation associated with the use of increasing head size when compared with conventional heads and a supposedly increased range of motion.⁴

Registry data suggest that MoM total hip arthroplasties fail at a higher rate than conventional THA using other bearing materials.²² Limitations in the interpretation of registry data are indication bias and the clustering of different MoM devices. Design differences are often ignored in registries and data regarding component positioning are typically unavailable.²¹ Table 1 lists survival percentages for the different hip arthroplasties as reported by the four largest implant registries.²³⁻²⁶



Fig. 2 Retrieval of total hip resurfacing, Bi-Metric TM stem with the M2a Magnum TM components (Biomet; Warsaw, Indiana).

Problems with MoM hip arthroplasty

Problems reported with MoM HR and large-head MoM THA initially concerned raised blood cobalt and chromium ions,²⁷ loosening of components,²⁸ soft-tissue reactions around the hip²⁹ and osteolysis.³⁰ Wear at the ball and socket interface as well as modularity at the head—neck junction and taper adaptors in MoM THA can be an important source of metal ions. Wear at the ball and socket is influenced by component positioning; in some studies, taper-head wear also seems to be influenced by wear at the ball—socket interface.²⁸

Some authors report excellent results with MoM HR devices. Well-designed components implanted within strict parameters, the knowledge of the surgeon and analysis of recently published research could contribute to an increasing understanding of the problems with large-head hip arthroplasties.²¹

Local tissue reactions

By generating metal debris, MoM hip arthroplasty can cause the formation of peri-articular masses referred to as pseudo-tumours. These are non-neoplastic and non-infective

Table 1. Ten-year survival rate (%) and number of THA osteoarthritis at risk from the annual reports of full ISAR members

	Total	Cemented		Uncemented		All hybrid		MoM THA		HRA		HRA BHR	
		All	< 55 yr M	All	< 55 yr M	All	< 55 yr M	All	< 55 yr M	All	< 55 yr M	All	< 55 yr M
Sweden 2012 ²³		98.0	–	98.8	–	96.6*	–	–	–	95.1	–	–	–
	123 012	91 055		16 241		14 916				800			
Australia 2014 ²⁴		94.0	91.5	94.6	94.4	95.2	93.2	82.6	81.5	90.0	89.3	93.0	92.8
	275 829	19 695	775	136 311	19 116	77 768	3927	3627	955	4747	2535	4161	2212
Denmark 2013 ²⁵		93.5	87.1*	93.7	92.6†	91.5	87.6†	89.0	–	–	–	94.0	–
	80 816	29 375	163	14 936	11 158	17 186	3079	4646				273	
NJR 2014 ²⁶		96.9*	93.2*	95.8*	94.8*	96.5*	95.0	80.1	75.5*	84.4	86.7*	90.6	–
	683 868	226 226	745	211 429	32 771	113 215	9731	30 175	5567	17 535	17 547	18 927	–
Total (%)		96.7	91.5	95.3	94.3	95.7	93.2	81.5	76.5	84.9	87.1	91.5	92.8
	1 163 525	366 351	1683	378 917	63045	223 085	16 737	38 448	6522	23 082	20 082	23 361	2212

*data acquired through calculation

†age <60

THA, total hip arthroplasty; ISAR, International Society of Arthroplasty Registers; NJR, National Joint Registry; MoM THA, metal-on-metal total hip arthroplasty; HRA, hip resurfacing arthroplasty; HRA BHR, hip resurfacing arthroplasty Birmingham Hip Resurfacing

Table 2. Incidence of pseudotumour and acute lymphocytic vasculitis associated lesion (ALVAL) reactions in metal-on-metal hip articulations*

Citation	Type of implant	Company	MoM type	Pseudotumour or ALVAL	%
Bosker 2012 ³⁶	M2A	Biomet	THA	42/108	38.8
Hasegawa 2014 ³⁷	Cormet	Corin	THA	24/108	22.2
Bayley 2015 ³⁸	M2A	Biomet	THA	38/191	19.8
Hasegawa 2014 ³⁷	Pinnacle	DePuy	THA	12/80	15.0
Korovessis 2006 ³⁹	Sikomet SM21	Plus Rotkreuz Orthopedics	THA	14/217	6.4
Zijlstra 2010 ⁴⁰	Stanmore MoM	Biomet	THA	1/42	2.3
Latteier 2011 ⁴¹	M2A	Biomet	THA	17/1212	1.4
Park 2005 ⁴²	S-rom	DePuy	THA	2/169	1.1
Saito 2010 ⁴³	Metasul	Zimmer	THA	0/90	0
Wagner 1996 ⁴⁴	Metasul	Zimmer	THA	0/70	0
Chang 2013 ⁴⁵	ASR	DePuy	HR	107/156	68.5
Bisschop 2013 ⁴⁶	BHR	Smith & Nephew	HR	40/143	27.9
Carrothers 2010 ⁴⁷	BHR	Smith & Nephew	HR	15/5000	0.3
Malviya 2009 ⁴⁸	BHR	Smith & Nephew	HR	1/670	0.1
Malviya 2011 ⁴⁹	BHR	Smith & Nephew	HR	0/50	0
Smolders 2011 ⁵⁰	Conserve plus	Wright Medical Technology	HR	0/43	0
Wagner 1996 ⁴⁴	Metasul	Zimmer	HR	0/35	0

*Reprinted from *J Arthroplasty*, Incidence of pseudotumour and acute lymphocytic vasculitis associated lesion (ALVAL) reactions in metal-on-metal hip articulations: a meta-analysis. Ding K, Stoner JA, Teague DC, Yousef KM.2013;28:1238-1245. With permission from Elsevier.

MoM, metal-on-metal; ALVAL, aseptic lymphocyte-dominated vasculitis-associated lesion; M2A, Magnum hip replacement; ASR, acetabular hip system; BHR, Birmingham hip resurfacing; THA, total hip arthroplasty; HR, hip resurfacing

lesions situated in various locations in the peri-prosthetic tissue.^{31,32} A pseudotumour is referred to more specifically as an adverse reaction to metal debris (ARMD), and more generally as an adverse local tissue reaction (ALTR). The term ‘aseptic lymphocytic vasculitis-associated lesion’ (ALVAL) is reserved for histological findings;³³ the term ‘metallosis’ should be avoided for these cases.

Pseudotumours can be solid, cystic lesions that have a direct communication with the joint.³¹ The described terminology can be confusing in the literature as there is inconsistency in its use. Imaging, operative and histopathological findings are used to describe the same phenomenon.³⁴ In most documented cases, metal wear particles have been found histologically.³⁵ The incidence of pseudotumours depends on the definition used and the type of pseudotumour, and their prevalence is estimated

to be from 3% to over 60% (Table 2) for both well- and poorly-functioning MoM hips.^{34,36-50} To date, it is not clear which implant type has the highest risk for development of a pseudotumour. Again, the large variety in data, pseudotumour definitions and diagnostic imaging techniques limit the successful evaluation of the information.

Metal ion levels

It is generally accepted that MoM HR and THA lead to increased whole blood levels of chromium (Cr) and cobalt (Co).⁵¹ Besides the local effect of metal debris, there are concerns about possible systemic toxic effects as impaired renal function, immune modulation, hypersensitivity, chromosomal damage, malignant cellular transformation, neuropathy, cardiomyopathy and thyroid

function disorders are reported.⁵²⁻⁵⁵ Causal associations between MoM bearings and potential risks have not yet been established, and neither have safe levels for metal ions.⁵⁶

Controversy remains regarding the need for metal ion analysis. There is in fact no international consensus as to whether chromium and/or cobalt should even be monitored.⁵⁷ Threshold ion levels for orthopaedic implants are provided by several authors, organisations and committees.⁵⁸ Median ion levels and acceptable ranges corresponding with well- or insufficiently-functioning MoM implants are reported.⁵⁹⁻⁶¹

Recent studies have tried to provide a more precise threshold level for cobalt in unilaterally-operated patients with additional information on sensitivity and specificity.^{60,62-67} End points differ considerably between these studies:⁶⁸ the specificity for predicting a poor clinical result is sometimes high while sensitivity is uniformly low. Metal ions only seem to adequately predict the presence of volumetric wear, and a metal ions trend may be more predictive of bearing malfunction than a single measurement.⁶⁹ Given these observations, institutional recommendations for a specific safe cut-off level or threshold for further investigation become questionable. Other studies also demonstrate that there is not enough evidence for precise threshold levels of metal ions as a trigger for intervention, or to predict adverse systemic effects for an individual patient.^{57,70,71}

In 2012 the UK Medicines and Healthcare Products Regulatory Agency (MHRA) adopted a 7 µg/L blood level for their medical advice alert. Above this level, additional investigations are recommended, including cross-sectional imaging.¹ In a January 2013 safety communication on MoM hip implants, the US Food and Drug Administration (FDA) did not define a threshold level as a trigger for revision or any other medical intervention. The American Academy of Orthopaedic Surgeons defines three groups in a stratification scheme. The cut-off points mentioned in this scheme are < 3 µg/L for the low-risk group metal ion level, 3-10 µg/L for the medium-risk group and > 10 µg/L for the high-risk group.

In their consensus statement on management of MoM bearings, EFORT, the European Hip Society (EHS), the Arbeitsgemeinschaft Endoprothetik (AE) and the Deutsche Arthroshilfe (DAH) use two cobalt levels; levels without clinical concern are < 2 µg/L and a threshold value for clinical concern, is within the range of 2 to 7 µg/L.^{5,6,8} The 2011 Dutch Orthopaedic Association (NOV) advice on MoM hip implants showed four cut-off points: normal at < 2 µg/L, slightly elevated at between 2 and 4 µg/L, elevated above 4 µg/L and extremely elevated at > 20 µg/L.⁷ The Agence Française de Sécurité Sanitaire des Produits de Santé does not use ion levels in its advice but emphasises clinical and radiological follow-up.⁷⁰

There is no obvious consensus in the current literature on threshold levels for metal ions or how to interpret them. In addition, there is not enough data available for bilateral MoM implants. Whether a threshold in the range of between 2 µg/L and 7 µg/L will be determined to differentiate between a well-functioning prosthesis and clinical concern remains to be determined. Moreover, it is unclear whether a maximal acceptable level can be determined above which revision surgery should be considered. There is still insufficient support for values such as the >20 µg/L level, as suggested by some authors.⁶⁷ Metal ion levels should be repeated and their development over time considered. Rather than being a single diagnostic tool, metal ions should be assessed in the entire context of the clinical and radiological findings. MoM HR and THA lead to increased whole blood levels of chromium and cobalt. An analysis of literature by Jantzen⁷² did not show a difference in ion concentrations between MoM HR or THA, but the study had major limitations, among them the inclusion of heterogeneous groups of patients and different measurement techniques for ion levels. We must also be aware that there is no precise knowledge on the longer-term effects on the human body of prolonged exposure to even mild elevation of blood metal ions.

Metal artefact reduction sequencing MRI, CT and ultrasound imaging

Imaging of MoM THA or HR is advised by all authorities, using several imaging modalities to screen and diagnose pseudotumours around a hip arthroplasty. Use of MRI with metal artefact reduction sequencing (MARS) or ultrasound is advocated. At present, MRI is widely used to assess adverse local tissue reactions (ALTR) owing to its advantages of superior imaging contrast for soft-tissue abnormalities and the ready availability of three-dimensional assessment of abnormal lesions.^{62,73,74} Computed tomography (CT) is also acceptable for the FDA and European agencies (Fig. 3). No consensus exists as to which modality is most effective.⁹ As different imaging modalities are under debate, a recent publication suggests that CT is not suitable for routine follow-up for MoM imaging.⁷³ Improved CT imaging techniques are however currently available.⁷⁴ In addition, screening for capsular reactions by means of CT is efficient and relatively quick. In general, availability of CT is higher than MR (especially MARS MRI), and costs are estimated to be between two and four times lower.⁷⁴ The additional advantage of CT is that implant positioning can be observed and it is much better in detecting osteolysis.⁷⁴ Ultrasound is an effective and attractive screening tool for identifying pseudotumours. It is observer-dependent, however, and only suitable for detecting soft-tissue abnormalities.^{9,75}

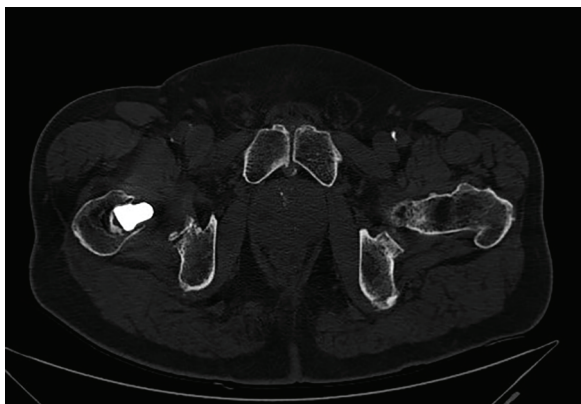


Fig. 3 CT scan of the axial section of an unilateral metal-on-metal total hip arthroplasty, showing a large pseudotumour anteromedial of the right hip.

Because of the high cost, required waiting and examination times and various contra-indications (e.g. for patients with pacemakers, ferromagnetic haemostatic clips or claustrophobia), MRI may not be the most suitable screening tool for ALTR in a large cohort of patients.⁷⁴ Ultrasound examination has advantages over other imaging modalities, including an absence of ionising radiation and metal artefacts, comparatively low cost and its availability for use at follow-up consultations.⁷⁵

New developments in imaging techniques such as MARS for MRI and CT such as the O-MAR automatic metal artefact reduction algorithm (Philips; Guildford, Surrey, UK) are available as screening tools for pseudotumours. These techniques are intended to reduce the size and intensity of artefacts such as orthopaedic implants. The Consensus Statement by EFORT and EHS^{57,58} states that ordinary MRI without use of the MARS technique is ineffective. Ultimately the choice should be made based on the availability of high-quality imaging, such as MARS MRI or O-MAR CT together with the availability of an experienced radiologist, the necessity to screen large cohorts of patients and the cost of different modalities, which can vary with different institutions.

Taper issues

Clinical failure of MoM THA may also be related to corrosion of the head–neck junction.⁷⁶ The exact mechanism remains unclear.⁷⁷⁻⁷⁹ Joint friction moments in mechanical loading cycles have been suggested to induce relative motion at the interface between modular components, facilitating fretting corrosion as well as removal of the protective oxide layer.^{77,79} This mechanism could explain the rising revision rates of modular MoM bearings with increasing bearing diameter,²⁶ mainly because the joint friction moment increases with bearing diameter and the

tolerance of the taper decreases with its diameter.⁸⁰ Small differences in taper angle between adaptor/head and stem tapers facilitate this due to design or manufacturing tolerances.⁷⁶ In the search for more stability, with increasing head size and reduced taper diameter, the tolerance of the head–neck junction seems to have failed. Further research is needed to determine the maximum head size to fit different taper diameter tolerances.

Revision

Revision of HR and MoM THA has become increasingly common. To date, few studies have reported on outcomes following revision of HR and MoM THA. There is no consensus on when to revise or how. High complication rates and poor functional outcome are frequently reported after revision of HR and THA.⁸¹⁻⁸⁸ In a systematic review, Matharu describes complication rates ranging between 4% and 68% and re-revision rates of between 3% and 38%.⁸⁶ Complication rates following ARMD revision appear higher than for other revision indications, and according to some authors, the extent of capsular resections makes this comparable to revision for infected arthroplasty.^{87,88}

Instability, infection and recurrence of the pseudotumour are the most frequently reported complications. Because of the high recurrence rates of pseudotumours post-revision, use of non-MoM bearings is recommended when revising these patients.^{82,83,87}

Current advice on large head MoM total hip arthroplasties

Follow-up strategy

At the moment there is no international consensus on follow-up for MoM HR or THA. Government regulatory agencies and national and international societies have issued advice for the follow-up of MoM hip arthroplasties. For example, Italian authorities adopted the advice of the EFORT-EHS European consensus statement and the SCENIHR document on the follow-up of patients.⁸⁹ Significant differences exist between protocols, which no longer reflect current evidence. Such differences include not stratifying patients according to implant type (THA or HR) or ARMD risk factors, using symptoms to decide on patient follow-up, and using suboptimal blood metal ion thresholds to identify poorly performing hips.^{1,2,6,7,8} Furthermore, variable information is provided by different authorities on the collection, processing and analysis of blood metal ion samples.^{1,2,6,7,8}

Patients with large-head MoM hip implants should be monitored according to a comprehensive screening protocol involving clinical results, metal ion levels and

radiological follow-up that includes cross-sectional imaging with metal artefact reduction or, alternately, ultrasound.

Follow-up frequency

More information has recently become available regarding the development and progression of ARMD.²⁶ Asymptomatic MoM-HR patients with normal blood metal ion levels (<2 µg/L) and normal ultrasound imaging are at very little risk of progression of ultrasound findings (2%), and at minimal risk of developing new pseudotumours (0%) within five years of initial assessment.⁹⁰ This sub-group does not require repeat follow-up within five years of initial assessment. Metal ion levels are insufficient as a single screening method for detecting failure of MoM implants; they are most useful as a measure of volumetric wear, and their development over time seems most useful in detecting possible failure of MoM implants.⁹⁰

Screening every five years can be considered for asymptomatic patients with a large-head MoM (T)HR *in situ* for at least ten years. An annual follow-up is generally indicated for symptomatic patients at present.

Conclusions

Discontinuation of use

The future role of MoM HR and THA is uncertain. Some authors report good long-term results for HR²¹ and emphasise the role of adequate surgical training, cup positioning and use of reliable HR implants. Unfortunately, bad publicity and the advice of several government regulatory agencies, national and international organisations on MoM hip implants as well as the burden of follow-up for these implants, will make most surgeons and patients reluctant to use them. Medico-legal issues may also play an important role in these decisions. Recently, Smith & Nephew withdrew the 46 diameter and smaller femoral heads from the market for the BHR system and issued new instructions for use that reflect new performance data.⁹¹

The use of large-head MoM THA should be discontinued. MoM HR should be approached with caution and, when considered, used only in patients who satisfy all of the recommended selection criteria, which limit its indications considerably. With alternatives at least equally successful using conventional THA available, even a limited indication for MoM HR is questionable.

Phased introduction of new prosthesis

In its new guidelines for hip prostheses, the Dutch Orthopaedic Association states that any new hip prosthesis under consideration for commercial usage in the Dutch market must pass a phased introduction that includes

mandatory radiostereometric (RSA) studies even before larger clinical trials can be initiated.⁹²⁻⁹⁴ Lessons from MoM HR and especially MoM THA are incorporated into these guidelines. This phased introduction of new implants or related developments has been proposed by several authors.⁹²⁻⁹⁵ The stepwise introduction described by Malchau⁹⁴ may be the most widely-known proposal. The phased introduction consists of these three steps: 1) pre-clinical tests, 2) large clinical trials (ideally multicentre and randomised), and 3) post-marked surveillance in national registries.

The phased introduction of new prostheses should be mandatory in the future. Close monitoring of outcomes and long-term follow-up is also necessary for the introduction of new prostheses.

Gold standard

Alternative arthroplasty options with extensive follow-up and excellent results are currently available. Frequently used bearing surfaces and proven head diameters (≤ 36 mm) with a satisfactory long-term follow-up are :

1. a ceramic head on a highly cross-linked polyethylene liner;
2. a metal head on a highly cross-linked polyethylene liner.

AUTHOR INFORMATION

¹Isala Clinics, Department of Orthopaedic Surgery and Traumatology, Zwolle, The Netherlands

²IRCCS Istituto Ortopedico Galeazzi, Milan, Italy

Correspondence should be sent to: Christiaan Peter van Lingen, Isala Clinics, Department of Orthopaedic Surgery and Traumatology, Zwolle, The Netherlands.

Email: cpvanlingen@hotmail.com

CONFLICT OF INTEREST

None declared.

FUNDING

No benefits in any form have been received or will be received from a commercial party related directly or indirectly to the subject of this article.

LICENCE

©2016 The author(s)

This article is distributed under the terms of the Creative Commons Attribution-NonCommercial 4.0 License (<http://www.creativecommons.org/licenses/by-nc/4.0/>) which permits non-commercial use, reproduction and distribution of the work without further permission provided the original work is attributed.

REFERENCES

1. **No authors listed.** Medicines and Healthcare products Regulatory Agency (MHRA). Medical device alert: all metal-on-metal (MoM) hip replacements. <https://www.gov.uk>

uk/drug-device-alerts/medical-device-alert-metal-on-metal-mom-hip-replacements-updated-advice-with-patient-follow-ups (date last accessed 2 September 2016).

2. No authors listed. U.S. Food and drug administration: Metal-on-metal hip implants. <http://www.fda.gov/MedicalDevices/ProductsandMedicalProcedures/ImplantsandProsthetics/MetalonMetalHipImplants/> (date last accessed 02 September 2016).

3. Verheyen CC, Verhaar JA. Failure rates of stemmed metal-on-metal hip replacements. *Lancet* 2012;380:105.

4. Haddad FS, Thakrar RR, Hart AJ, et al. Metal-on-metal bearings: the evidence so far. *J Bone Joint Surg [Br]* 2011;93-B:572-579.

5. Haddad FS, Konan S. Current controversies in hip surgery: a report on the proceedings of the London Hip Meeting 2011. *J Bone Joint Surg [Br]* 2012;94-B:297-301.

6. No authors listed. EFORT, European Commission issued final opinion on the safety of metal-on-metal (MoM) joint replacements with a particular focus on hip implants, <https://www.efort.eu/en/initiatives/metal-on-metal> (date last accessed 02 September 2016).

7. No authors listed. Dutch Orthopaedic Society, Advice on metal on metal THA <http://www.orthopeden.org/vereniging/nieuws/nieuws/uitwerking-nov-advies-metaal-op-metaal-articulere-implantaten-mom-3-juni-2012?objectSynopsis=clhw5DYtGNGBuxX9B83bdA#HNXkx41JB4ytzqWJhR6EUQ> (date last accessed 02 September 2016).

8. Scientific Committee. SCENIHR, The safety of metal-on-metal joint replacements with a particular focus on hip implants http://ec.europa.eu/health/scientific_committees/emerging/docs/scenihr_o_042.pdf; (date last accessed 02 September 2016).

9. Matharu GS, Mellon SJ, Murray DW, Pandit HG. Follow-up of metal-on-metal hip arthroplasty patients is currently not evidence based or cost effective. *J Arthroplasty* 2015;30:1317-1323.

10. Matharu GS, Pandit HG, Murray DW, Treacy RB. The future role of metal-on-metal hip resurfacing. *Int Orthop* 2015;39:2031-2036.

11. The NJR Editorial Board. National Joint Registry 10th annual report 2013. http://www.njrcentre.org.uk/njrcentre/Portals/o/Documents/England/Reports/10th_annual_report/NJR%2010th%20Annual%20Report%202013%20B.pdf (date last accessed 02 January 2016).

12. No authors listed. National Institute for Health and Care Excellence. Total hip replacement and resurfacing arthroplasty for end-stage arthritis of the hip. <https://www.nice.org.uk/guidance/ta304> (date last accessed 2 September 2016).

13. Girard J, Bocquet D, Autissier G, et al. Metal-on-metal hip arthroplasty in patients thirty years of age or younger. *J Bone Joint Surg [Am]* 2010;92-A:2419-2426.

14. Bozic KJ, Kurtz S, Lau E, et al. The epidemiology of bearing surface usage in total hip arthroplasty in the United States. *J Bone Joint Surg [Am]* 2009;91-A:1614-1620.

15. The NJR Editorial Board. National Joint Registry for England and Wales 9th Annual Report 2012. <http://www.njrcentre.org.uk/njrcentre/Reports,PublicationsandMinutes/Annualreports/Archivedannualreports/tabid/87/Default.aspx> (date last accessed 02 September 2016).

16. Kishida Y, Sugano N, Nishii T, et al. Preservation of the bone mineral density of the femur after surface replacement of the hip. *J Bone Joint Surg [Br]* 2004;86-B:185-189.

17. Smolders JM, Hol A, Rijnders T, van Susante JL. Changes in bone mineral density in the proximal femur after hip resurfacing and uncemented total hip replacement: A prospective randomised controlled study. *J Bone Joint Surg [Br]* 2010;92-B:1509-1514.

18. Tapaninen T, Kröger H, Jurvelin J, Venesmaa P. Femoral neck bone mineral density after resurfacing hip arthroplasty. *Scand J Surg* 2012;101:211-215.

19. Malviya A, Ng L, Hashmi M, Rawlings D, Holland JP. Patterns of changes in femoral bone mineral density up to five years after hip resurfacing. *J Arthroplasty* 2013;28:1025-1030

20. Marshall DA, Pykerman K, Werle J, et al. Hip resurfacing versus total hip arthroplasty: a systematic review comparing standardized outcomes. *Clin Orthop Relat Res* 2014;472:2217-2230.

21. Amstutz HC, Le Duff MJ. Hip resurfacing: history, current status, and future. *Hip Int* 2015;25:330-338.

22. Smith AJ, Dieppe P, Howard PW, Blom AW. National Joint Registry for England and Wales. Failure rates of metal-on-metal hip resurfacings: analysis of data from the National Joint Registry for England and Wales. *Lancet* 2012;380:1759-1766.

23. Garellick G, Rogmark C, Kärrholm J, Rolfson O. Swedish Hip Arthroplasty Register, Annual Report 2012 <http://www.shpr.se/en/Publications/DocumentsReports.aspx> (date last accessed 02 September 2016).

24. Graves S. Australian Orthopaedic Association, National Joint Replacement Registry, Annual Report 2014. <https://aoanjrr.sahmri.com/annual-reports-2014> (date last accessed 02 September 2016).

25. No authors listed. Danish Hip Arthroplasty Register, annual report 2013 http://www.dhr.dk/annual_report.htm (date last accessed 02 September 2016).

26. The NJR Editorial Board. National Joint Registry, 11th Annual Report 2014 <http://www.njrcentre.org.uk/njrcentre/Reports,PublicationsandMinutes/Annualreports/tabid/86/Default.aspx> (date last accessed 02 September 2016).

27. Hart AJ, Sabah S, Henckel J, et al. The painful metal-on-metal hip resurfacing. *J Bone Joint Surg [Br]* 2009;91-B:738-744.

28. Morlock MM, Bishop N, Zustin J, et al. Modes of implant failure after hip resurfacing: morphological and wear analysis of 267 retrieval specimens. *J Bone Joint Surg [Am]* 2008;90-A:89-95.

29. Pandit H, Glyn-Jones S, McLardy-Smith P, et al. Pseudotumours associated with metal-on-metal hip resurfacings. *J Bone Joint Surg [Br]* 2008;90-B:847-851.

30. Jacobs JJ, Hallab NJ. Loosening and osteolysis associated with metal-on-metal bearings: a local effect of metal hypersensitivity? *J Bone Joint Surg [Am]* 2006;88-A:1171-1172.

31. Sabah SA, Mitchell AW, Henckel J, et al. Magnetic resonance imaging findings in painful metal-on-metal hips: a prospective study. *J Arthroplasty* 2011;26:71-76

32. Boomsma MF, Edens MA, Van Lingen CP, et al. Development and first validation of a simplified CT-based classification system of soft tissue changes in large-head metal-on-metal total hip replacement: intra- and interrater reliability and association with revision rates in a uniform cohort of 664 arthroplasties. *Skeletal Radiol* 2015;44:1141-1149.

33. Langton DJ, Joyce TJ, Jameson SS, et al. Adverse reaction to metal debris following hip resurfacing: the influence of component type, orientation and volumetric wear. *J Bone Joint Surg [Br]* 2011;93-B:164-171.

34. Hothi HS, Berber R, Whittaker RK, et al. Detailed inspection of metal implants. *Hip Int* 2015;25:227-231.

35. Perino G, Ricciardi BF, Jerabek SA, et al. Implant based differences in adverse local tissue reaction in failed total hip arthroplasties: a morphological and immunohistochemical study. *BMC Clin Pathol* 2014;14:39.

36. Bosker BH, Ettema HB, Boomsma MF, et al. High incidence of pseudotumour formation after large-diameter metal-on-metal total hip replacement: a prospective cohort study. *J Bone Joint Surg [Br]* 2012;94-B:755-761.

- 37. Hasegawa M, Miyamoto N, Miyazaki S, Wakabayashi H, Sudo A.** Longitudinal magnetic resonance imaging of pseudotumors following metal-on-metal total hip arthroplasty. *J Arthroplasty* 2014;29:2236-2238.
- 38. Bayley N, Khan H, Grosso P, et al.** What are the predictors and prevalence of pseudotumor and elevated metal ions after large-diameter metal-on-metal THA? *Clin Orthop Relat Res* 2015;473:477-484.
- 39. Korovessis P, Petsinis G, Repanti M, Repantis T.** Metallosis after contemporary metal-on-metal THA: five to nine-year follow up. *J Bone Joint Surg [Am]* 2006;88-A:1183-1191.
- 40. Zijlstra WP, van Raay JJ, Bulstra SK, Deutman R.** No superiority of cemented metal-on-metal over metal-on-polyethylene THA in a randomized controlled trial at 10-year follow-up. *Orthopedics* 2010 (Epub ahead of print) PMID: 20349863.
- 41. Latteier MJ, Berend KR, Lombardi AV Jr, et al.** Gender is a significant factor for failure of metal-on-metal total hip arthroplasty. *J Arthroplasty* 2011;26:19-23.
- 42. Park YS, Moon YW, Lim SJ, et al.** Early osteolysis following second-generation metal-on-metal hip replacement. *J Bone Joint Surg [Am]* 2005;87-A:1515-1521.
- 43. Saito S, Ishii T, Mori S, Hosaka K, Ootaki M, Tokuhashi Y.** Long-term results of metal-on-metal total hip arthroplasty. *Orthopedics* 2010 (Epub ahead of print) PMID: 20704108.
- 44. Wagner M, Wagner H.** Preliminary results of uncemented metal on metal stemmed and resurfacing hip replacement arthroplasty. *Clin Orthop Relat Res* 1996;329:578-588.
- 45. Chang EY, McAnally JL, Van Horne JR, et al.** Relationship of plasma metal ions and clinical and imaging findings in patients with ASR XL metal-on-metal total hip replacements. *J Bone Joint Surg [Am]* 2013;95-A:2015-2020.
- 46. Bisschop R, Boomsma MF, Van Raay JJ, et al.** High prevalence of pseudotumors in patients with a Birmingham Hip Resurfacing prosthesis: a prospective cohort study of one hundred and twenty-nine patients. *J Bone Joint Surg [Am]* 2013;95-A:1554-1560.
- 47. Carrothers AD, Gilbert RE, Jaiswal A, Richardson JB.** Birmingham hip resurfacing: the prevalence of failure. *J Bone Joint Surg [Br]* 2010;92-B:1344-1350.
- 48. Malviya A, Holland JP.** Pseudotumours associated with metal-on-metal hip resurfacing: 10-year Newcastle experience. *Acta Orthop Belg* 2009;75:477-483.
- 49. Malviya A, Ramaskandhan JR, Bowman R, et al.** What advantage is there to be gained using large modular metal-on-metal bearings in routine primary hip replacement? A preliminary report of a prospective randomised controlled trial. *J Bone Joint Surg [Br]* 2011;93-B:1602-1609.
- 50. Bisseling P, Smolders JM, Hol A, van Susante JL.** Metal ion levels and functional results following resurfacing hip arthroplasty versus conventional small-diameter metal-on-metal total hip arthroplasty; a 3 to 5 year follow-up of a randomized controlled trial. *J Arthroplasty* 2015;30:61-67.
- 51. Lainiala OS, Moilanen TP, Hart AJ, et al.** Higher blood cobalt and chromium levels in patients with unilateral metal-on-metal total hip arthroplasties compared to hip resurfacings. *J Arthroplasty* 2016;31:1261-1266.
- 52. Merritt K, Brown SA.** Distribution of cobalt chromium wear and corrosion products and biologic reactions. *Clin Orthop Relat Res* 1996;329:5233-5243.
- 53. Hallab NJ, Mikecz K, Vermes C, Skipor A, Jacobs JJ.** Orthopaedic implant related metal toxicity in terms of human lymphocyte reactivity to metal-protein complexes produced from cobalt-base and titanium-base implant alloy degradation. *Mol Cell Biochem* 2001;222:127-136.
- 54. Mabileau G, Kwon YM, Pandit H, Murray DW, Sabokbar A.** Metal-on-metal hip resurfacing arthroplasty: a review of periprosthetic biological reactions. *Acta Orthop* 2008;79:734-747.
- 55. Tharani R, Dorey FJ, Schmalzried TP.** The risk of cancer following total hip or knee arthroplasty. *J Bone Joint Surg [Am]* 2001;83-A:774-780.
- 56. MacDonald SJ, Brodner W, Jacobs JJ.** A consensus paper on metal ions in metal-on-metal hip arthroplasties. *J Arthroplasty* 2004;19(suppl 3):12-16.
- 57. Hannemann F, Hartmann A, Schmitt J, et al.** European multidisciplinary consensus statement on the use and monitoring of metal-on-metal bearings for total hip replacement and hip resurfacing. *Orthop Traumatol Surg Res* 2013;99:263-271.
- 58. Günther KP, Schmitt J, Campbell P, et al.** Consensus statement "Current evidence on the management of metal-on-metal bearings" – April 16, 2012. *Hip Int* 2013;23:2-5.
- 59. Minoia C, Sabbioni E, Apostoli P, et al.** Trace element reference values in tissues from inhabitants of the European community. I. A study of 46 elements in urine, blood and serum of Italian subjects. *Sci Total Environ* 1990;95:89-105.
- 60. Van Der Straeten C, Grammatopoulos G, Gill HS, et al.** The 2012 Otto Aufranc Award: the interpretation of metal ion levels in unilateral and bilateral hip resurfacing. *Clin Orthop Relat Res* 2013;471:377-385.
- 61. Hart AJ, Sabah SA, Bandi AS, et al.** Sensitivity and specificity of blood cobalt and chromium metal ions for predicting failure of MoM hip replacement. *J Bone Joint Surg [Br]* 2011;93-B:1308-1313.
- 62. Kwon YM, Ostlere SJ, McLardy-Smith P, et al.** "Asymptomatic" pseudotumors after metal-on-metal hip resurfacing arthroplasty: prevalence and metal ion study. *J Arthroplasty* 2011;26:511-518.
- 63. Kwon YM, Thomas P, Sumner B, et al.** Lymphocyte proliferation responses in patients with pseudotumors following metal-on-metal hip resurfacing arthroplasty. *J Orthop Res* 2010;28:444-450.
- 64. Langton DJ, Jameson SS, Joyce TJ, et al.** Accelerating failure rate of the ASR total hip replacement. *J Bone Joint Surg [Br]* 2011;93-B:1011-1016.
- 65. Langton DJ, Jameson SS, Joyce TJ, et al.** Early failure of metal-on-metal bearings in hip resurfacing and large-diameter total hip replacement: A consequence of excess wear. *J Bone Joint Surg [Br]* 2010;92-B:38-46.
- 66. Skinner J, Kay P.** Commentary: metal on metal hips. *BMJ* 2011;342:d3009.
- 67. Sidaginamale RP, Joyce TJ, Lord JK, et al.** Blood metal ion testing is an effective screening tool to identify poorly performing metal-on-metal bearings surfaces. *Bone Joint Res* 2013;2:84-95.
- 68. van Lingen CP, Ettema HB, Verheyen CCPM.** Evaluation of different consensus statements on thresholds for metal ions in metal-on-metal total hip arthroplasties. In: Knahr K, ed. *Tribology in Total Hip and Knee Arthroplasty*. Heidelberg: Springer, 2014:163-169.
- 69. Macnair RD, Wynn-Jones H, Wilmhurst JA, Toms A, Cahir J.** Metal ion levels not sufficient as a screening measure for adverse reactions in metal-on-metal hip arthroplasties. *J Arthroplasty* 2013;28:78-83.
- 70. No authors listed.** Agence Française de Sécurité Sanitaire des Produits de Santé. Prothèses de hanche ASR du fabricant DePuy rappelées en juillet 2010. Recommandations de l'Afssaps. <http://ansm.sante.fr/content/download/39685/518877/version/3/file/pi-120229-protheses-DePuy.pdf> (date last accessed 02 September 2016).
- 71. No authors listed.** Health Products and Food Branch Inspectorate HC. Important safety information regarding metal-on-metal hip implant surgery. <http://healthycanadians.gc.ca/recall-alert-rappel-avis/hc-sc/2012/15835a-eng.php> (date last accessed 5 September 2016).

- 72. Jantzen C, Jørgensen HL, Duus BR, Sporning SL, Lauritzen JB.** Chromium and cobalt ion concentrations in blood and serum following various types of metal-on-metal hip arthroplasties: a literature overview. *Acta Orthop* 2013;84:229-236.
- 73. Robinson E, Henckel J, Sabah S, et al.** Cross-sectional imaging of metal-on-metal hip arthroplasties. Can we substitute MARS MRI with CT? *Acta Orthop* 2014;85:577-584.
- 74. Wellenberg RH, Ettema HB, Verheyen CC, Maas M, Boomsma MF.** Cross sectional imaging of metal-on-metal hip arthroplasties. *Acta Orthop* 2015;86:272-273.
- 75. Nishii T, Sakai T, Takao M, Yoshikawa H, Sugano N.** Is ultrasound screening reliable for adverse local tissue reaction after hip arthroplasty? *J Arthroplasty* 2014;29:2239-2244.
- 76. Witt F, Bosker BH, Bishop NE, et al.** The relation between titanium taper corrosion and cobalt-chromium bearing wear in large-head metal-on-metal total hip prostheses: a retrieval study. *J Bone Joint Surg [Am]* 2014;96-A:e157.
- 77. Vundelinckx BJ, Verhelst LA, De Schepper J.** Taper corrosion in modular hip prostheses: analysis of serum metal ions in 19 patients. *J Arthroplasty* 2013;28:1218-1223.
- 78. Matthies AK, Racasan R, Bills P, et al.** Material loss at the taper junction of retrieved large head metal-on-metal total hip replacements. *J Orthop Res* 2013;31:1677-1685.
- 79. Higgs GB, Hanzlik JA, MacDonald DW, et al; Implant Research Center Writing Committee.** Is increased modularity associated with increased fretting and corrosion damage in metal-on-metal total hip arthroplasty devices?: a retrieval study. *J Arthroplasty* 2013;28:2-6.
- 80. Bishop NE, Hothan A, Morlock MM.** High friction moments in large hard-on-hard hip replacement bearings in conditions of poor lubrication. *J Orthop Res* 2013;31:807-813.
- 81. de Steiger RN, Miller LN, Prosser GH, et al.** Poor outcome of revised resurfacing hip arthroplasty. *Acta Orthop* 2010;81:72-76.
- 82. De Smet KA, Van Der Straeten C, Van Orsouw M, et al.** Revisions of metal-on-metal hip resurfacing: lessons learned and improved outcome. *Orthop Clin North Am* 2011;42:259-269.
- 83. Liddle AD, Satchithananda K, Henckel J, et al.** Revision of metal-on-metal hip arthroplasty in a tertiary center: a prospective study of 39 hips with between 1 and 4 years of follow-up. *Acta Orthop* 2013;84:237-245.
- 84. Munro JT, Masri BA, Duncan CP, Garbuz DS.** High complication rate after revision of large-head metal-on-metal total hip arthroplasty. *Clin Orthop Relat Res* 2014;472:523-528.
- 85. Wyles CC, Van Demark RE III, Sierra RJ, Trousdale RT.** High rate of infection after aseptic revision of failed metal-on-metal total hip arthroplasty. *Clin Orthop Relat Res* 2014;472:509-516.
- 86. Matharu GS, Pynsent PB, Dunlop DJ.** Revision of metal-on-metal hip replacements and resurfacings for adverse reaction to metal debris: a systematic review of outcomes. *Hip Int* 2014;24:311-320.
- 87. Grammatopoulos G, Pandit H, Kwon YM, et al.** Hip resurfacings revised for inflammatory pseudotumour have a poor outcome. *J Bone Joint Surg [Br]* 2009;91-B:1019-1024.
- 88. van Lingen CP, Ettema HB, Bosker BH, Verheyen CC.** Revision of a single type of large metal head metal-on-metal hip prosthesis. *Hip Int* 2015;25:221-226.
- 89. No authors listed.** Scientific Committee on Emerging and Newly Identified Health Risks, 2013. Final opinion on the safety of metal-on-metal joint replacements with a particular focus on hip implants. http://ec.europa.eu/health/scientific_committees/emerging/docs/scenih_r_0_042.pdf (date last accessed 6 September 2016).
- 90. Low AK, Matharu GS, Ostlere SJ, Murray DW, Pandit HG.** How should we follow-up asymptomatic metal-on-metal hip resurfacing patients? A prospective longitudinal cohort study. *J Arthroplasty* 2016;31:146-151.
- 91. No authors listed.** Smith & Nephew. <http://www.smith-nephew.com/news-and-media/mediareleases/news/statement-regarding-bhr-system/> (date last accessed 5 September 2016).
- 92. Nelissen RG, Pijls BG, Kärrholm J, et al.** RSA and registries: the quest for phased introduction of new implants. *J Bone Joint Surg [Am]* 2011;93-A:62-65.
- 93. Poolman RW, Verhaar JA, Schreurs BW, et al.** Finding the right hip implant for patient and surgeon: the Dutch strategy—empowering patients. *Hip Int* 2015;25:131-137.
- 94. Huiskes R.** Failed innovation in total hip replacement. Diagnosis and proposals for a cure. *Acta Orthop Scand* 1993;64:699-716.
- 95. Malchau H.** *On the importance of stepwise introduction of new hip implant technology. Assessment of total hip replacement using clinical evaluation, radiostereometry, digitised radiography and a national hip registry.* Göteborg, Sweden: University of Göteborg, 1995. <https://gupea.ub.gu.se/handle/2077/12932?locale=en> (date last accessed 02 September 2016).