



Case report

Epithelial ingrowth through venting incision into laser-assisted in situ keratomileusis flap interface after descemet stripping automated endothelial keratoplasty

Lindsay Ciocco^a, Shahzeb Hassan^b, Fasika Woreta^a, Divya Srikumaran^{a,*}

^a Wilmer Eye Institute, Johns Hopkins University, Baltimore, MD, 21287, USA

^b Northwestern University Feinberg School of Medicine, Chicago, IL, 60611, USA

ARTICLE INFO

Keywords:

Epithelial ingrowth
Descemet stripping automated endothelial keratoplasty
Venting incisions

ABSTRACT

Purpose: To present a case of epithelial ingrowth into the laser-assisted in situ keratomileusis (LASIK) flap interface after a patient underwent descemet stripping automated endothelial keratoplasty (DSAEK) surgery with venting incisions.

Observations: We present a case of a 48-year-old man with previous history of LASIK that underwent DSAEK for pseudophakic bullous keratopathy after complicated cataract surgery requiring an intraocular lens (IOL) exchange. The patient developed epithelial ingrowth into the LASIK flap interface from one of the venting incisions. The epithelial ingrowth was observed as it was a small peripheral area that did not affect his visual acuity. **Conclusions and Importance:** Epithelial ingrowth is a well-described complication following LASIK but has rarely been described to occur after endothelial keratoplasty (EK). Even rarer, are reports of epithelial ingrowth after EK cases that have been found to result from venting incisions. To the authors' knowledge, this is the first case of the ingrowth into a LASIK flap interface occurring after EK through a venting incision. Although it may be an uncommon occurrence in which a patient with a history of LASIK requires EK, surgeons should take extra precautions to avoid this complication.

1. Introduction

Epithelial ingrowth occurs when epithelial cells invade other ocular tissues. Historically it was reported to occur retrocorneally into the anterior chamber after trauma or surgery.^{1,2} Currently, the term is most closely associated with epithelial invasion of a corneal lamellar interface such as in laser-assisted in situ keratomileusis (LASIK) or endothelial keratoplasty (EK).³ The term epithelial downgrowth more specifically refers to cases of epithelial invasion into other ocular tissues and can be used in these cases to help avoid confusion. After epithelial invasion, the cells may regress, remain stable, or progress and proliferate.^{4,5} A patient with this postoperative complication may be asymptomatic, requiring only observation, or in rare cases, might need surgical treatment to manage its sequelae.^{3,6} Complications resulting from epithelial ingrowth include growth of opacity into the visual axis, induction of irregular astigmatism, foreign body sensation and flap melt.^{3,7}

In LASIK, the ingrowth occurs when epithelial cells are introduced intraoperatively or invade postoperatively into the flap-stromal bed

interface.⁵ In contrast, epithelial ingrowth occurs post EK primarily at the donor graft-host interface and additionally can result in epithelial downgrowth retrocorneally.^{3,4} Venting incisions have been implicated in a few cases of epithelial invasion post EK and it has been demonstrated in vitro that corneal epithelial cells may migrate deeper into the cornea through such incisions.^{4,8,9}

We report a patient who developed epithelial ingrowth in the LASIK flap interface after having descemet stripping automated endothelial keratoplasty (DSAEK) surgery with venting incisions. Considering that both LASIK and EK have been independently associated with epithelial ingrowth, this case represents an interesting opportunity to examine the implications of this post-operative complication in a single case with history of both procedures.

2. Case report

A 48-year-old white male presented for consult of persistent corneal edema of the left eye after complicated surgery to repair a dislocated intraocular lens (IOL) implant. The patient had undergone pars plana

* Corresponding author. Wilmer Eye Institute, Odenton Medical Pavilion I, 1106 Annapolis Road, Suite 290, Odenton, MD, 21113, USA.

E-mail address: dsrikum1@jhmi.edu (D. Srikumaran).

<https://doi.org/10.1016/j.ajoc.2018.11.012>

Received 21 August 2018; Received in revised form 2 November 2018; Accepted 12 November 2018

Available online 14 November 2018

2451-9936/© 2018 The Authors. Published by Elsevier Inc. This is an open access article under the CC BY-NC-ND license (<http://creativecommons.org/licenses/by-nc-nd/4.0/>).

vitrectomy with scleral fixation of an Akreos AO lens (Bausch & Lomb). The patient's ocular history was also significant for LASIK and pseudophakia of both eyes. His systemic history was significant for anti-phospholipid antibody syndrome for which he was taking apixaban.

Visual acuity at presentation in that eye was 20/400 with no improvement through pinhole. Intraocular pressure was normal and equal to the other eye. Central corneal thickness was 686 compared to 527 in the other eye. The iris was noted to be incarcerated in the wound and with a large iridectomy and was poorly reactive. Posterior segment health was unremarkable for both eyes. The patient was offered DSAEK surgery instead of descemet's membrane endothelial keratoplasty (DMEK) surgery due to the abnormal anterior chamber anatomy and concern for opacification of the hydrophilic lens implant with injection of a long-acting gas.

The patient subsequently underwent DSAEK with pupilloplasty. An anterior chamber maintainer was used, and the graft was inserted using a pull through technique. The use of a large air bubble was not an option due to the large iris defects and lack of vitreous and capsule structures increasing the risk for posterior dislocation of the bubble. To promote graft adherence, the peripheral stromal bed of the host was roughened using a Terry scraper. In addition, three venting incisions were made to allow for drainage of interface fluid. The use of venting incisions was essential in this case since the abnormal anatomy prohibited the use of a large air bubble to aid in graft attachment and higher likelihood that the air bubble would go behind the iris and lens through the large iris defects. Post-surgical histopathological analysis confirmed pseudophakic bullous keratopathy as the etiology for the corneal edema.

Afterwards, the patient experienced a relatively uncomplicated recovery. Edema gradually resolved, and vision also improved. At the 6-month postoperative visit, a small area of epithelial ingrowth was noted for the first time near one of the venting incisions (Fig. 1). Due to the small size and peripheral location, the ingrowth is expected to remain

stable and not interfere with vision. At last visit, about 8 months postoperative, a manifest refraction obtained 20/20-2 best spectacle corrected visual acuity in that eye.

3. Discussion

Epithelial ingrowth into the cornea is characteristically apparent on slit lamp examination as a homogenous gray-white interface opacity, but may also be imaged by anterior segment optical coherence tomography (AS-OCT).^{4,10} A case series by Suh et al. utilized AS-OCT to evaluate epithelial ingrowth. These cases demonstrated hyperreflective and hyporeflexive areas in locations of epithelial ingrowth. These findings are apparent in our case. The AS-OCT obtained shows hyperreflectivity in the LASIK interface flap in this region with a darkened shadow below it (Fig. 2A and B).

Unlike other post-EK epithelial ingrowth cases, our patient experienced growth of the epithelial cells at the LASIK flap interface in contrast to the donor-host interface. In the overwhelming majority of cases, this finding is clinically insignificant.^{3,4,7} Despite being a well-known complication of LASIK (incidence up to 20%), the percent requiring surgical treatment is small after both primary treatment and enhancement (0.92% and 1.7% respectively).^{5,7} For mild ingrowth, simple observation is recommended. Surgical management of epithelial ingrowth in LASIK typically involves a flap lift, but additional interventions, such as suturing or fibrin glue, may be required, depending upon recurrence.¹¹

The overall occurrence with EK appears to be much less than in LASIK, with a recent case series by Dalal et al. identifying a total of 33 cases from both their clinics and in the literature including cases of epithelial downgrowth.⁴ Fortunately, the ingrowth observed in EK generally appears to occur at the donor-host interface and outside the visual axis, remaining static or even regressing over time.^{3,4} It appears that the majority of cases that require additional intervention post EK have epithelial downgrowth, involving ingrowth on the endothelium and into the anterior chamber.^{4,10} Downgrowth has the potential to cause more severe complications, such as corneal decompensation, iritis, glaucoma retinal detachment and phthisis bulbi.¹⁰

In general, three mechanisms have been identified as possible causes of ingrowth in EK including the introduction of loose epithelial cells intraoperatively through the wound site, migration of donor epithelial cells from eccentrically trephined grafts containing full-thickness cornea, and introduction of epithelial cells from full-thickness corneal incisions.³ Venting incisions appear to be the cause for the ingrowth in this reported case due to the proximity of the ingrowth to the location of one of the venting incisions.

It appears however that venting incisions are an uncommon cause of epithelial ingrowth. In the cases series by Dalal et al., only one patient out of eight documented to have venting incisions developed ingrowth attributable to an incision.⁴ A review of the literature identified one other similar case in which a 35-year old man developed epithelial ingrowth one month after Descemet stripping endothelial keratoplasty (DSEK) with stromal puncture.⁸ In both cases, cell growth did not progress and remained stable. Additionally, unlike our case, none of the cases appeared to have history of LASIK. Interestingly, we did find a case which occurred after phacoemulsification in which epithelial ingrowth into the LASIK flap interface seemed to have entered through a suture track.¹²

In the current state, our patient's epithelial ingrowth remains stable, similar to other post EK cases with ingrowth and not requiring intervention.¹⁰ As mentioned previously, two other post-EK cases were found to have venting incision associated epithelial ingrowth and both were able to be managed simply by observation.^{4,8} One of the cases first noted the ingrowth at the 1-month follow up and was closely monitored for 13 months after surgery with the ingrowth remaining stationary.⁸ In the other case, it is not mentioned when the epithelial ingrowth was first observed, but the patient was followed for two years and six

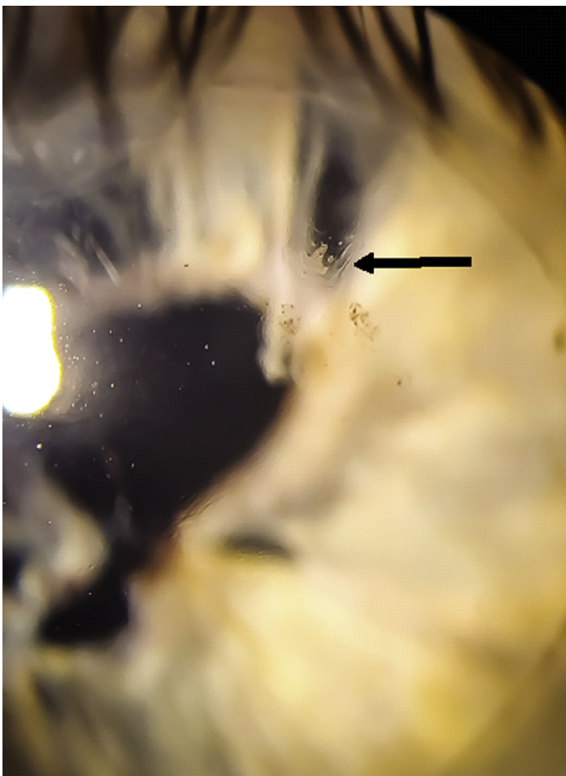


Fig. 1. Slit lamp photo 8 months post descemet stripping automated endothelial stripping automated keratoplasty (DSAEK) demonstrating area of epithelial ingrowth at arrow.

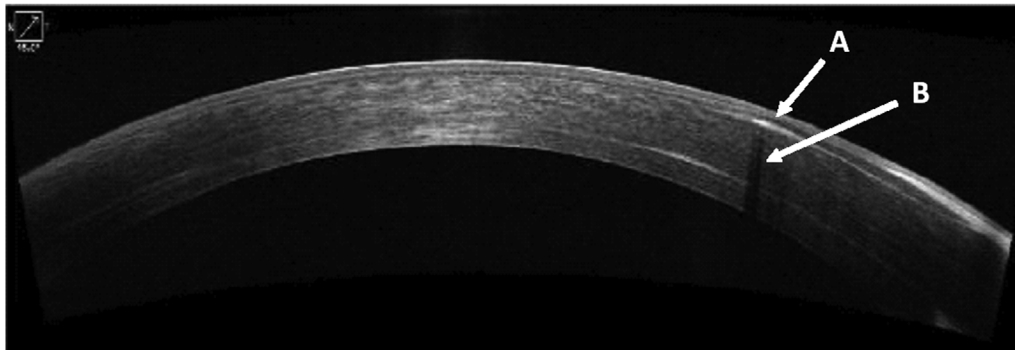


Fig. 2. Anterior segment optical coherence tomography (AS-OCT) image. A) Hyperreflectivity in area of epithelial ingrowth within flap interface. B) Underlying hyporeflective shadow.

months without complication.⁴

However, in some cases, such as endothelial graft failure, a repeat EK or penetrating keratoplasty may be required.^{13,14}

Prevention has been recommended as the best way to manage this complication.^{3–5} This includes utilizing careful surgical technique. Suggestions include debriding loose donor epithelium, removing epithelium around venting incisions and avoiding excessive intraocular manipulation.^{4,9} To avoid epithelial implantation during EK surgery, it is recommended to mark the edge of the stromal bed created by the microkeratome cut to facilitate centration of the tissue during trephination in order to avoid a full thickness edge for the DSAEK graft. This can be done by the surgeon at the time of surgery or by the eye bank during tissue preparation.⁴ Close observation is the most conservative approach and is likely the best option when in growth is limited to the interface and outside of visual axis as in the case we present.^{3,4} Another potential treatment for epithelial downgrowth includes the use of intracameral antimetabolites. 5-Fluorouracil has been reported as a successful treatment in a few cases post keratoplasty.^{15,16} YAG laser has also been reported as a potential treatment of epithelial ingrowth post LASIK, but involves the risk of flap breakthrough with additional ingrowth.^{17,18} Repeat EK or PKP may be necessary in severe cases such as those resulting in graft failure.

4. Conclusions

We present a unique case of venting incision associated epithelial ingrowth at the LASIK flap interface after undergoing DSAEK surgery. Though our patient has still experienced an excellent outcome, clinicians are advised to exercise added caution when performing DSAEK surgery on patients with prior history of LASIK especially if venting incisions are planned.^{3,4}

Patient consent

The patient consented to publication of the case in writing.

Funding

No funding or grant support.

Disclosures

The following authors have no financial disclosures: LC, SH, FW.

DS is a consultant for Alcon, but this is not relevant to this publication.

Authorship

All authors attest that they meet the current ICMJE criteria for

Authorship.

Acknowledgements

None.

References

- Friedman BB. 764 Notes, Cases, Instruments Treatment of Epithelial in- Growth Following Cata-ract Extraction. vol. 27. 1944; 1944[https://doi.org/10.1016/S0002-9394\(44\)91787-3](https://doi.org/10.1016/S0002-9394(44)91787-3).
- Stark WJ, Michels RG, Maumenee AE, Cupples H, Baltimore M. *Surgical Management of Epithelial Ingrowth*. 1978; 1978[https://doi.org/10.1016/S0002-9394\(14\)78104-8](https://doi.org/10.1016/S0002-9394(14)78104-8).
- Semeraro F, Di Salvatore A, Bova A, Forbice E. Etiopathogenesis and therapy of epithelial ingrowth after Descemet's stripping automated endothelial keratoplasty. *BioMed Res Int*. 2014;2014:906087. <https://doi.org/10.1155/2014/906087>.
- Dalal RR, Raber I, Dunn SP, et al. Epithelial ingrowth following endothelial keratoplasty. *Cornea*. 2016;35(4):465–470. <https://doi.org/10.1097/ICO.0000000000000775>.
- Ting DSJ, Srinivasan S, Danjou J-P. Epithelial ingrowth following laser in situ keratomileusis (LASIK): prevalence, risk factors, management and visual outcomes. *BMJ open Ophthalmol*. 2018;3(1):e000133<https://doi.org/10.1136/bmjophth-2017-000133>.
- Sutton G, Lawless M, Hodge C. Laser in situ keratomileusis in 2012: a review. *Clin Exp Optom*. 2014;97(1):18–29. <https://doi.org/10.1111/cxo.12075>.
- Wang MY, Maloney RK. Epithelial ingrowth after laser in situ keratomileusis. *Am J Ophthalmol*. 2000;129(6):746–751.
- Bansal R, Ramasubramanian A, Das P, Sukhija J, Jain AKK. Intracorneal epithelial ingrowth after descemet stripping endothelial keratoplasty and stromal puncture. *Cornea*. 2009;28(3):334–337. <https://doi.org/10.1097/ICO.0b013e3181907c00>.
- Steiner A, Flug A, Milman T, Udell IJ. Full-thickness corneal “vent incisions”: how deep does the epithelium penetrate? *Cornea*. 2011;30(7):804–806. <https://doi.org/10.1097/ICO.0b013e3181d527b1>.
- Suh LH, Shousha MA, Ventura RU, et al. Epithelial ingrowth after descemet stripping automated endothelial keratoplasty: description of cases and assessment with anterior segment optical coherence tomography. *Cornea*. 2011;30(5):528–534. <https://doi.org/10.1097/ICO.0b013e3181fb8149>.
- Rapuano CJ. Management of epithelial ingrowth after laser in situ keratomileusis on a tertiary care cornea service. *Cornea*. 2010;29(3):307–313. <https://doi.org/10.1097/ICO.0b013e3181b7f3c5>.
- Braunstein RE, Airiani S, Chang S. Epithelial ingrowth under a laser in situ keratomileusis flap after phacoemulsification. *J Cataract Refract Surg*. 2003. [https://doi.org/10.1016/S0886-3350\(03\)00335-3](https://doi.org/10.1016/S0886-3350(03)00335-3).
- Ghosh S, Bonshek R, Morgan SJ. Histologically proven epithelial ingrowth in failed Descemet stripping automated endothelial keratoplasty (DSAEK) managed by repeat DSAEK. *Clin Ophthalmol*. 2013;7:1035–1040. <https://doi.org/10.2147/OPHT.545016>.
- Saelens IEY, Bartels MC, Rij G Van, Dinjens WNM, Mooy CM. Introduction of epithelial cells in the flap-graft interface during descemet stripping automated endothelial keratoplasty. *Arch Ophthalmol*. 2009;127(7):936. <https://doi.org/10.1001/archophthol.2009.143>.
- Lai MM, Haller JA. Resolution of epithelial ingrowth in a patient treated with 5-fluorouracil. *Am J Ophthalmol*. 2002. [https://doi.org/10.1016/S0002-9394\(01\)01419-2](https://doi.org/10.1016/S0002-9394(01)01419-2).
- Wong RK, Greene DP, Shield DR, Eberhart CG, Huang JJ, Shayegani A. 5-Fluorouracil for epithelial downgrowth after Descemet stripping automated endothelial keratoplasty. *Cornea*. 2013. <https://doi.org/10.1097/ICO.0b013e3182a9fc85>.
- Ayala MJ, Alió JL, Mulet ME, De La Hoz F. Treatment of laser in situ keratomileusis interface epithelial ingrowth with Neodymium:Yttrium-Aluminum-Garnet laser. *Am J Ophthalmol*. 2008. <https://doi.org/10.1016/j.ajo.2007.11.022>.
- Lapid-Gortzak R, Hughes JM, Nieuwendaal CP, Mourits MP, van der Meulen IJE. LASIK flap breakthrough in Nd:YAG laser treatment of epithelial ingrowth. *J Refract Surg*. 2015. <https://doi.org/10.3928/1081597X-20150424-03>.