

# Non-small cell lung cancer harboring *EGFR* G724S mutation and exon 19 deletion responded to afatinib monotherapy after multiple lines of target therapies

Francesco Cortiula<sup>a</sup>, Giacomo Pelizzari<sup>a</sup>, Carla Corvaja<sup>b</sup>,  
Giovanna De Maglio<sup>c</sup> and Gianpiero Fasola<sup>a</sup>

**Epidermal growth factor receptor (EGFR) G724S mutation represents a resistance mechanism to first- and third-generation EGFR tyrosine kinase inhibitors. Limited data are available regarding the efficacy of afatinib in patients with non-small cell lung cancer (NSCLC) harboring G724S mutation, particularly after osimertinib. A patient diagnosed with advanced EGFR-mutated (exon 19 deletion) NSCLC after several lines of treatment – gefitinib, osimertinib, heat shock protein inhibitors and chemotherapy-developed EGFR G724S mutation retaining the exon 19 deletion. She was then treated successfully with afatinib leading to a progression free survival of 9 months (and counting). This is the first report of the emergence of G724S mutation, together with ex19del, after three subsequent lines of therapy following progressive disease to Osimertinib, and**

**we report for the first time the activity of afatinib against EGFR exon 18 G724S mutation in this setting. *Anti-Cancer Drugs* 33: 960–962 Copyright © 2022 The Author(s). Published by Wolters Kluwer Health, Inc.**

*Anti-Cancer Drugs* 2022, 33:960–962

**Keywords:** afatinib, EGFR G724S, target therapy

<sup>a</sup>Department of Medical Oncology, University Hospital of Udine, Azienda Sanitaria Universitaria Friuli Centrale (ASUFC), <sup>b</sup>Department of Medicine, University of Udine and <sup>c</sup>Department of Pathology, University Hospital of Udine, Azienda Sanitaria Universitaria Friuli Centrale (ASU FC), Udine, Italy

Correspondence to Francesco Cortiula, MD, Department of Medical Oncology, University Hospital of Udine, Azienda Sanitaria Universitaria Friuli Centrale (ASUFC), 33100 Udine, Italy  
Tel: +0039 0432552754; e-mail: francesco.cortiula@asufc.sanita.fvg.it

Received 5 June 2022 Revised form accepted 5 June 2022

## Introduction

We report the case of a patient diagnosed with advanced epidermal growth factor receptor (*EGFR*)-mutated (exon 19 deletion) non-small cell lung cancer (NSCLC) who, after several lines of treatment developed *EGFR* G724S mutation, was treated successfully with afatinib.

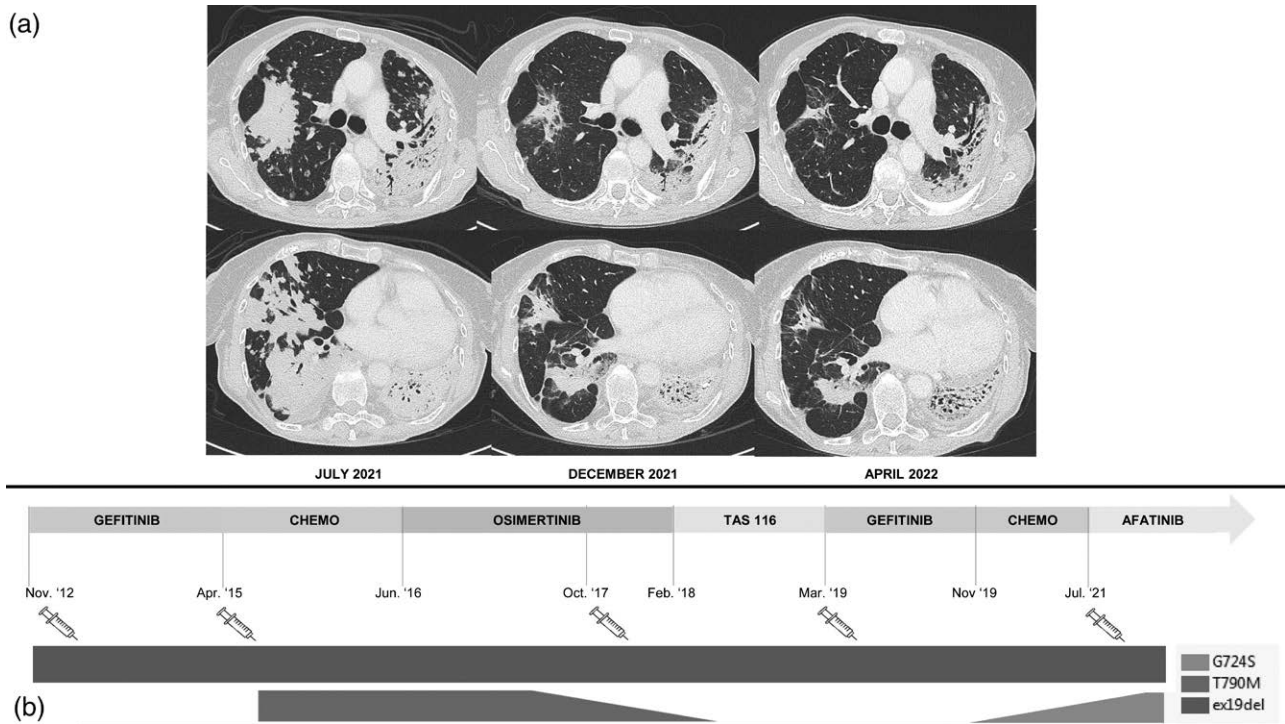
## Case presentation

In November 2012, a 55-year-old never-smoker Caucasian female was diagnosed with stage IV papillary adenocarcinoma – multiple bilateral lung nodules and mediastinal lymph nodes. The patient was staged with total body PET and brain computed tomography (CT) scan. She presented in good clinical conditions, and Eastern Cooperative Oncology Group performance status (PS) is 0. She referred neither any clinically significant symptoms nor relevant comorbidities. Activating *EGFR* exon 19 deletion (ex19del) E746\_S752>V was identified by PCR on tissue biopsy. Thus, in December 2012, the patient was started on first-generation tyrosine kinase inhibitor gefitinib 250 mg daily. In April 2015, the CT scan showed new bilateral lung nodules. A second tissue biopsy and PCR were performed showing both ex19del and *EGFR* exon 20 T790M mutation. The patient was then treated with four

cycles of carboplatin (area under the plasma concentration-time curve 5 mg/ml per min, intravenously, on day 1 every 3 weeks) and pemetrexed (500 mg/m<sup>2</sup> intravenously on day 1 every 3 weeks). Then the patient was followed up until June 2016 when she developed new lung nodules. At that time, she was referred to our Institution, and she was started on osimertinib 80 mg daily, within the open-label, single-arm, real-world treatment study ASTRIS [1]. The best response to osimertinib was partial response (PR) according to RECIST criteria v1.1 [2]. In October 2017, she developed progressive disease (PD) with new lung nodules. The tissue biopsy performed at that time showed no T790M and confirmed the presence of the baseline ex19del. Papillary adenocarcinoma histology was also confirmed. Osimertinib was continued beyond progression until February 2018 when the CT scan revealed a further PD, and the patient was treated within a clinical trial (NCT02965885) with TAS-116. TAS-116 is an orally available selective inhibitor of Heat Shock Protein 90 (HSP90). HSPs mediate key signaling pathways for tumor survival, and *EGFR* levels have been shown to decline upon treatment with HSP90 inhibitors [3]. The disease was controlled until March 2019 when it progressed with new lung nodules. Next-generation sequencing (NGS) through the oncomine focus assay (ThermoFisher Scientific, Waltham, Massachusetts) on tissue biopsy was performed: baseline ex19del was still present, whereas no other molecular alterations were found. The patient was still PS 0 and her only complaint was dyspnea after strenuous exercise.

This is an open-access article distributed under the terms of the Creative Commons Attribution-Non Commercial-No Derivatives License 4.0 (CCBY-NC-ND), where it is permissible to download and share the work provided it is properly cited. The work cannot be changed in any way or used commercially without permission from the journal.

Fig. 1



Disease response to afatinib treatment (a) and sequence of treatment received in relation to the emergence of resistance mechanisms (b).

She was subsequently treated with gefitinib 250 mg daily (from March 2019 to November 2019, the best response was PD for pleural effusion) and single-agent gemcitabine (from December 2019 to July 2020). Gemcitabine was suspended with stable disease, due to suboptimal tolerance, and the patient was followed up with CT scans every 3 months. In June 2021, the restaging CT scan showed an increase in the lung nodules. NGS (Oncomine Focus Assay - ThermoFisher Scientific) on tissue biopsy highlighted the ex19del and the emergence of the *EGFR* exon 18 G724S mutation; neither T790M nor other mutations were found. The case was discussed at the local molecular tumor board, and treatment with afatinib was started in August 2021, in light of the preclinical evidence of sensitivity to afatinib retained by NSCLC harboring exon 18 G724S mutation<sup>4</sup>. The first restaging CT scan showed that PR and treatment with afatinib are still ongoing. The last CT scan, performed in April 2022, confirmed PR leading to a progression free survival (PFS) of 9 months (and counting). The patient is in good clinical condition, PS is 0 and her current survival, calculated from metastatic cancer diagnosis, is 9.5 years (Fig.1).

## Discussion

In-vitro and in-vivo experiments showed how G724S promotes a conformational change in the *EGFR* glycine-rich loop inducing resistance, in the context of ex19del, by reducing the binding affinity of osimertinib [4]. The

emergence of *EGFR* exon 18 G724S mutation as a resistance mechanism to osimertinib in patients with NSCLC, and the activity of afatinib in this setting, have already been reported [5,6]. However, to the best of our knowledge, this is the first report of the emergence of G724S mutation, together with ex19del, after three subsequent lines of therapy following PD to Osimertinib. More importantly, we reported for the first time the activity of afatinib against *EGFR* exon 18 G724S mutation in a later line of treatment. The occurrence of G724S mutation in NSCLC with baseline E746\_S752>V ex19del is consistent with what has been observed in previous studies [5]. The patient responded extraordinarily well to anticancer treatments, as shown by the PFS achieved with first-line gefitinib and with chemotherapy both in second and fifth lines [7]. Nonetheless, the disease control achieved with target treatments was in line with the literature and the best response to gefitinib rechallenge was PD [8,9]. This validates the remarkable disease control provided by afatinib, being mechanistically explained by the presence of ex19de/G724S comutation. Our findings are particularly relevant in light of the increasing number of patients receiving osimertinib in first line and the consequent need to tackle resistance mechanisms in subsequent lines of treatment. Real-world experiences are of great value for gathering evidence about the best treatment choice in specific and rare molecular population – such patients with NSCLC harboring the *EGFR* ex19del/G724S comutation

- since developing a specific clinical trial would not be feasible. Furthermore, our case highlights the value of genotyping oncogene-addicted NSCLC, even in later lines of treatment, in order to deliver the next best treatment. At the same time, it shows how chemotherapy might play a key role in prolonging survival, working as a bridge between target therapies.

## Conclusion

We confirmed the efficacy of afatinib monotherapy in patients with NSCLC harboring *EGFR* ex19del/G724S comutation, gathering evidence for afatinib as the best treatment choice in this very specific patient population.

## Acknowledgements

### Conflicts of interest

There are no conflicts of interest.

## References

- 1 Marinis F, Wu YL, de Castro G Jr, Chang GC, Chen YM, Cho BC, *et al.* ASTRIS: a global real-world study of osimertinib in >3000 patients with EGFR T790M positive non-small-cell lung cancer. *Future Oncol* 2019; **15**:3003–3014.
- 2 Eisenhauer EA, Therasse P, Bogaerts J, Schwartz LH, Sargent D, Ford R, *et al.* New response evaluation criteria in solid tumours: revised RECIST guideline (version 1.1). *Eur J Cancer* 2009; **45**:228–247.
- 3 Neckers L, Workman P. Hsp90 molecular chaperone inhibitors: are we there yet? *Clin Cancer Res* 2012; **18**:64–76.
- 4 Fassunke J, Müller F, Keul M, Michels S, Dammert MA, Schmitt A, *et al.* Overcoming EGFRG724S-mediated osimertinib resistance through unique binding characteristics of second-generation EGFR inhibitors. *Nat Commun* 2018; **9**:4655.
- 5 Wei Y, Jiang B, Liu S, Zhang Z, Fang W, Yang Y, *et al.* Afatinib as a potential therapeutic option for patients with NSCLC with EGFR G724S. *JTO Clin Res Rep* 2021; **2**:100193.
- 6 Minari R, Leonetti A, Gnetti L, Zielli T, Ventura L, Bottarelli L, *et al.* Afatinib therapy in case of EGFR G724S emergence as resistance mechanism to osimertinib. *Anticancer Drugs* 2021; **32**:758–762.
- 7 Soria JC, Ohe Y, Vansteenkiste J, Reungwetwattana T, Chewaskulyong B, Lee KH, *et al.*; FLAURA Investigators. Osimertinib in untreated EGFR-mutated advanced non-small-cell lung cancer. *N Engl J Med* 2018; **378**:113–125.
- 8 Shimomura A, Yamamoto N, Kondo S, Fujiwara Y, Suzuki S, Yanagitani N, *et al.* First-in-human phase I study of an Oral HSP90 Inhibitor, TAS-116, in patients with advanced solid tumors. *Mol Cancer Ther* 2019; **18**:531–540.
- 9 Mok TS, Wu Y-L, Ahn M-J, Garassino MC, Kim HR, Ramalingam SS, *et al.*; AURA3 Investigators. Osimertinib or platinum-pemetrexed in EGFR T790M-positive lung cancer. *N Engl J Med* 2017; **376**:629–640.