

Case Report

Laparoscopic pelvic organ prolapse repair by mesh interposition following radical cystectomy

Hirokazu Abe,¹  Bo Fan,¹ Tingwen Huang,¹ Hiroka Komori,¹ Atsuhiko Ochi,¹ Koichiro Suzuki,¹ Yasuhide Kitagawa² and Naoki Shiga¹

¹Department of Urology, Kameda Medical Center, Kamogawa, and ²Department of Urology, Komatsu Municipal Hospital, Komatsu, Japan

Abbreviations & Acronyms

BMI = body mass index
IC = ileal conduit
LSSC = laparoscopic sacrospinous colpopexy
MIBC = muscle-invasive bladder cancer
POP = pelvic organ prolapse
POP-Q = POP quantification
RC = radical cystectomy

Correspondence: Hirokazu Abe M.D., Ph.D., Department of Urology, Kameda Medical Center, 929 Higashicho, Kamogawa, Chiba 296-8602, Japan. Email: abe.hirokazu@kameda.jp

This is an open access article under the terms of the Creative Commons Attribution-NonCommercial License, which permits use, distribution and reproduction in any medium, provided the original work is properly cited and is not used for commercial purposes.

Received 14 November 2018; accepted 11 February 2019. Online publication 20 March 2019

Introduction: The present study aims to introduce laparoscopic treatment by the interposition of polypropylene mesh for a pelvic organ prolapse in females following radical cystectomy for treating muscle-invasive bladder carcinoma.

Case presentation: The patients included two women aged 77 and 79 years with symptomatic enterocele following radical cystectomy and ileal conduit urinary diversion. We performed laparoscopic sacrospinous colpopexy using polypropylene and polypropylene/ePTFE composite meshes.

Conclusion: No recurrent prolapse occurred during 26 and 14 months of follow-up after the operation. No severe perioperative complications were noted. This is a first report on cases of laparoscopic sacrospinous colpopexy for post-cystectomy pelvic organ prolapse. Our procedure could be safely performed in two patients with post-cystectomy pelvic organ prolapse.

Key words: enterocele, laparoscopic sacrospinous colpopexy, mesh interposition, pelvic organ prolapse, radical cystectomy.

Keynote message

Laparoscopic treatment by the interposition of polypropylene mesh for a POP in two females following RC was performed. No recurrent prolapse occurred during 26 and 14 months of follow-up after the operation, and no severe perioperative complications were noted. LSSC is thought to be safely performed in the patients with post-cystectomy POP.

Case presentation

We present two cases of women with POP following RC for treating MIBC. Both patients were removed bladder with urethra, anterior vaginal wall, bilateral ovary, and uterine by a traditional manner of cystectomy. For both patients, POP treatment involved a polypropylene mesh and a polypropylene/ePTFE composite mesh, and both patients exhibited good clinical courses.

Case 1

A 79-year-old woman who had previously undergone RC and IC urinary diversion for MIBC (pT3cN0M0) at the age of 78 presented with a stage IV enterocele (POP-Q) and superficial vaginal ulceration. Her BMI was 18. LSSC was performed according to the following protocol:

The patient was placed in the 15° Trendelenburg position under general anesthesia. The Trendelenburg position maintains the intestinal loops outside the pelvic cavity. We used four trocars on the umbilical top, halfway between the umbilicus and the pubic symphysis, the left ileac fossa, and the right ileac fossa. The first step of the operation involved the dissection of the intestinal and colonic adhesions in the pelvic floor. The vaginal apex was especially strongly adhered to the colon in the pelvic floor and was safely dissected. The rectovaginal space was dissected to an anorectal angle in the middle and until the levator ani muscle

(puborectalis muscle) fascia on each lateral side was reached. In this case, the left ureter was on the promontrium of the sacrum, and we performed LSSC, not laparoscopic sacrocolpopexy.

Two self-cut sheets of polypropylene mesh (Gynemesh™; Gynecare, Ethicon Inc., Somerville, NJ, USA) were fixed from the tip end of each dissected postvesical and rectovaginal space to the sacrospinous ligament (Fig. 1). Polypropylene/ePTFE composite mesh (Composix™; Bard Inc., Murray Hill, NJ, USA), which has reasonable characteristics for promoting tissue growth and minimizing the risk of bowel adhesion, was used to cover the polypropylene mesh interposing on the pelvic floor (Fig. 2). This reconstructive structure did not interfere with IC in the pelvis (Fig. 3). The total operation time was 120 min, and blood loss was approximately 25 mL.

On Day 7 after the operation, the patient was discharged from our hospital. A small mesh erosion occurred 3 months after the operation. The eroded part of the mesh was cut during an outpatient clinic visit, and local estrogen therapy was administered. POP symptoms, a pelvic pain, and constipation did not occur during 18 months of follow-up.

Case 2

A 77-year-old woman who had previously undergone RC and IC for MIBC (pT3cN0M0) at the age of 76 presented with POP-Q stage IV enterocele and superficial vaginal ulceration. Her BMI was 27. LSSC was performed, as previously described. Total operation time was 153 min, and blood loss was 10 mL.

On Day 5 after the operation, the patient was discharged from our hospital. She experienced no post-surgical complications. POP symptoms, a pelvic pain, and constipation were absent up to 4 months after the operation.

Discussion

RC has been a standard surgical approach for treating MIBC. In female patients, RC sometimes requires the removal of not only the bladder but also the uterus, ovaries, and a segment of the anterior vaginal wall. This surgical procedure may weaken pelvic floor muscle structures, and the small intestine or large bowels may herniate through the anterior or posterior vaginal wall forming an enterocele. Theoretically, POP occurs more commonly in female patients following RC; however,

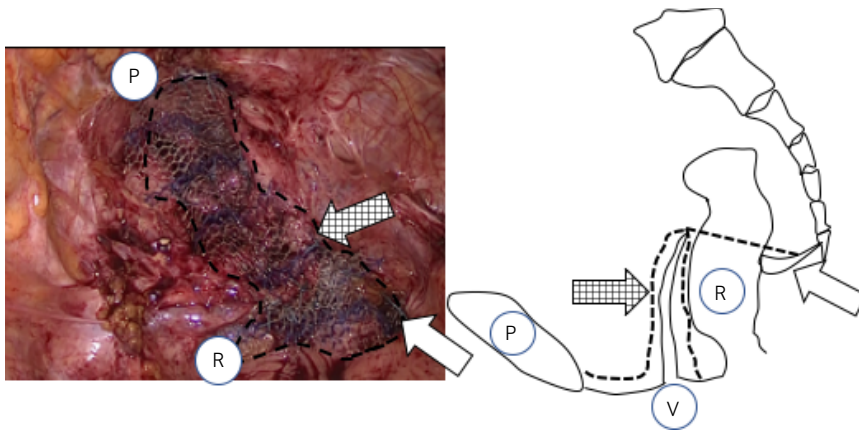


Fig. 1 Two self-cut sheets of polypropylene mesh (Gynemesh™) were interposed on the anterior and posterior vagina, and solidly attached to the sacrospinous ligament. The right side of the sacrospinous ligament is indicated by the white arrow. The check arrow indicates two self-cut sheets of polypropylene mesh. P; pubic bone, V; vagina, R; rectum.

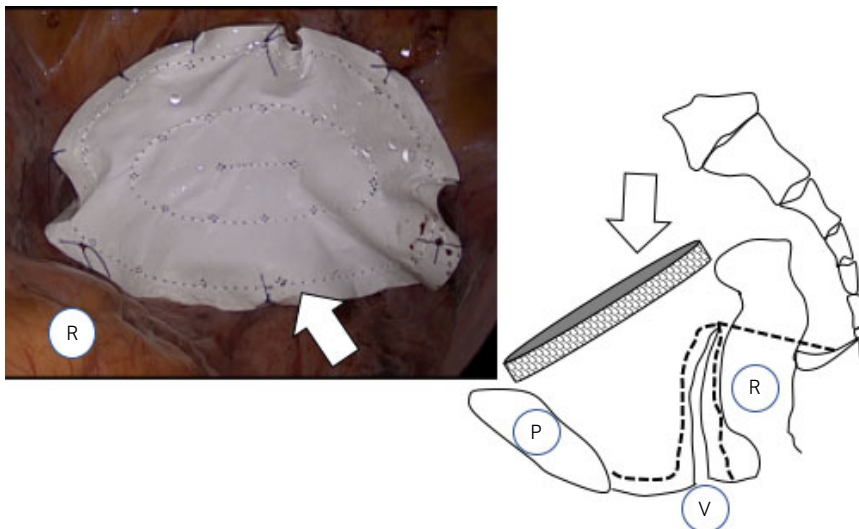


Fig. 2 Polypropylene/ePTFE composite mesh (Composix™) covered the polypropylene mesh interposing on the pelvic floor (white arrow). P; pubic bone, V; vagina, R; rectum.

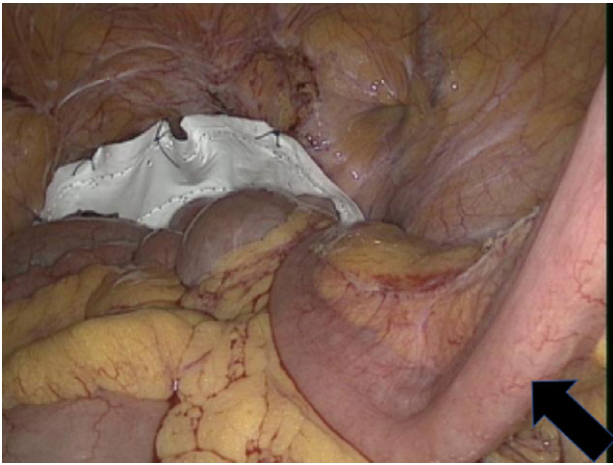


Fig. 3 Overview of the post-surgical pelvis. IC is indicated by the black arrow.

there are few reports regarding post-cystectomy POP.^{1–3} In patients who undergo RC for MIBC, oncologic clinical outcomes are generally focused upon post-operatively, and the quality of life affected by surgical complications, including POP, may escape attention.⁴ In this manuscript, we reported two successful cases of LSSC in patients with post-cystectomy POP.

Transvaginal repair using native tissue in cases of anterior enterocele, although not attempted by us, would be technically difficult for several reasons. First, some anatomic mechanisms predispose post-cystectomy women to POP. Specifically, the endopelvic fascia overlying the pelvic floor is usually partially excised during RC. Second, a uterosacral ligamentous injury may result in inadequate native tissue repair. In previous reports in which different cases of patients with POP following RC and IC were presented, one woman received fascial repair without mesh reinforcement, the other patients received transvaginal repair using biological meshes and colpoceleisis.^{4,5} There has been no consensus regarding surgical procedures for post-cystectomy POP, and the usage of biological mesh for pelvic repair is controversial.⁶ Generally, abdominal approach to the sacrum may be more reasonable than transvaginal approaches. In the previous prospective randomized study, subjective and objective success rates were higher (although the difference did not rise to the level of statistical significance) in the group of patients with abdominal sacral colpopexy compared to a group of patients with vaginal sacrospinous colpopexy for vaginal vault prolapse.⁷ To our knowledge, there is no report of

LSSC performed in patients with post-cystectomy POP. We presented two cases of LSSC in patients with POP following RC and IC.

Mesh erosion is a late complication of abdominal sacral colpopexy with a reported incidence of 3–7.6%.^{7–10} Lower rates of erosion have been identified with monofilament polypropylene mesh.¹¹ Polypropylene/ePTFE composite mesh may be useful for treating peritoneal defects of the pelvic floor. The composite mesh merges ease of use with excellent tissue integration and minimization of visceral attachment risk.

Conclusions

Surgical repair of POP in women who have undergone RC and IC may be difficult and challenging. The present cases demonstrated the usefulness of a laparoscopic approach with fundamental advantages.

Conflict of interest

The authors declare no conflict of interest.

References

- 1 Stenzl A, Colleselli K, Bartsch G. Update of urethra sparing approaches in cystectomy in women. *World J. Urol.* 1997; **15**: 134–8.
- 2 Anderson J, Carrion R, Ordorica R *et al.* Anterior enterocele following cystectomy for intractable interstitial cystitis. *J. Urol.* 1998; **159**: 1868–70.
- 3 Lee U, Raz S. Emerging concepts for pelvic organ prolapse surgery: what is cure? *Curr. Urol. Rep.* 2011; **12**: 62–7.
- 4 Stav K, Dwyer PL, Rosamilia A, Lim YN, Alcalay M. Transvaginal pelvic organ prolapse repair of anterior enterocele following cystectomy in females. *Int. Urogynecol. J.* 2009; **20**: 411–5.
- 5 Graefe F, Beilleche K, Tunn R. Vaginal vault prolapse following cystectomy: transvaginal reconstruction by mesh interposition. *Int. Urogynecol. J.* 2013; **24**: 1407–9.
- 6 Puppo P, Introini C, Calvi P *et al.* Pelvic floor reconstruction before orthotopic bladder replacement after radical cystectomy for bladder cancer. *Urology* 2005; **65**: 174.
- 7 Maher CF, Qatawneh AM, Dwyer PL *et al.* Abdominal sacral colpopexy or vaginal sacrospinous colpopexy for vaginal vault prolapse: a prospective randomized study. *Am. J. Obstet. Gynecol.* 2004; **190**: 20–6.
- 8 Begley JS, Kupferman SP, Kuznetsov DD *et al.* Incidence and management of abdominal sacrocolpopexy mesh erosions. *Am. J. Obstet. Gynecol.* 2005; **192**: 1956–62.
- 9 Nygaard IE, McCreery R, Brubaker L *et al.* Abdominal sacrocolpopexy: a comprehensive review. *Obstet. Gynecol.* 2004; **104**: 805–23.
- 10 Ferry P, Sedille L, Roncheau V. Rectal mesh exposure after laparoscopic sacrocolpopexy. *J. Minim. Invasive Gynecol.* 2014; **21**: 311–3.
- 11 Dwyer PL, O'Reilly BA. Transvaginal repair of anterior and posterior compartment prolapse with Atrium polypropylene mesh. *BJOG* 2004; **111**: 831–6.