

# Stress Fracture of Proximal Femur after Hip Resurfacing Treated with Cannulated Screw

Daniele Fabbri<sup>1</sup> Riccardo Orsini<sup>1</sup> Antonio Moroni<sup>2</sup>

<sup>1</sup>Hip Resurfacing Service, IRCCS Galeazzi Orthopaedic Institute, San Siro Clinical Institute, Milan, Italy

<sup>2</sup>Hip Resurfacing Department, San Raffaele Hospital, Vita e Salute University, Milan, Italy

Address for correspondence Daniele Fabbri, MD, Hip Resurfacing Service, IRCCS Galeazzi Orthopaedic Institute, San Siro Clinical Institute, Via Monreale 48, 20148 Milan, Italy (e-mail: dott.danielefabbri@gmail.com).

Joints 2018;6:128–130.

## Abstract

Stress fractures of the proximal femur are described in athletes and military personnel. In most cases, they are not treated surgically, except when they are at the top of the femoral neck and with cortical involvement. The return to sports is not recommended in patients with hip replacement, especially for the high rate of revision of implants in the younger patients. One of the major complications of hip resurfacing (HR) is the medial fracture of the femoral neck, which usually occurs within 9 weeks after surgery. The causes have to be attributed to a malposition of the femoral component or to an insufficient bone density. The case reported herein is unique because it describes a stress fracture on patient operated with HR, treated with screw fixation. Two years after surgery, the patient returned to his normal life, practicing sports, without progression of varus angulation of the stem.

## Keywords

- ▶ hip
- ▶ resurfacing
- ▶ stress fracture
- ▶ sports
- ▶ fixation

## Introduction

Femoral neck stress fracture has a high potential for complications and early recognition is important. It is reported by literature an increased risk of stress fracture of the femoral neck in athletes who perform intense physical activity (e.g., long runner) and soldiers.<sup>1</sup>

These fractures can be tension type in the upper part and compression type in the lower part. Fractures in tension should be treated surgically to avoid the risk of progression in a displaced fracture or osteonecrosis of the femoral head.<sup>1</sup>

We describe a case illustrating a femoral neck stress fracture in a patient operated with hip resurfacing (HR), surgically treated with osteosynthesis.

## Case Presentation

A 45-year-old male athlete who had been suffering from right hip osteoarthritis underwent hip replacement with a resurfacing implant (Birmingham Hip Resurfacing [BHR]; Smith & Nephew, Memphis, Tennessee, United States) through a posterior–lateral approach in 2014. At the

time of surgery, body mass index (BMI) was 23.7 and T-score at dual energy X-ray absorptiometry was 0.5. The postoperative X-ray showed a well-positioned implant (▶ Fig. 1).

The postoperative course was regular with a full recovery of weight-bearing after 30 days; at 3 months, he was back to play the sports. The patient reported to be a downhill runner and had covered an average of 3,000 km in the last year, mostly on asphalt.

In March 2016, he came at our clinic with right hip pain, without referring trauma. The patient told us that he began to feel a “little pain” in the groin ~2 weeks before, during a workout session. Pain increased with time, but he could walk without crutches.

On physical examination, the pain appeared to be located in inguinal region. Passive range of motion of the hip was painful. The patient had a FABER and FADIR positive test; also, the hop test was positive for the painful hip.

The anteroposterior X-ray showed a stress fracture of the femoral neck with a slight variation (4 degrees) of the prosthetic component compared with the postoperative X-rays (▶ Fig. 2). No magnetic resonance imaging was required

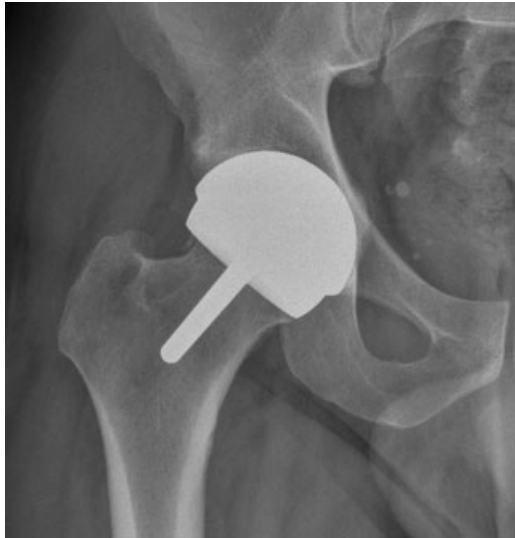received  
February 18, 2018  
accepted  
May 12, 2018  
published online  
June 22, 2018

DOI <https://doi.org/10.1055/s-0038-1660815>.  
ISSN 2282-4324.

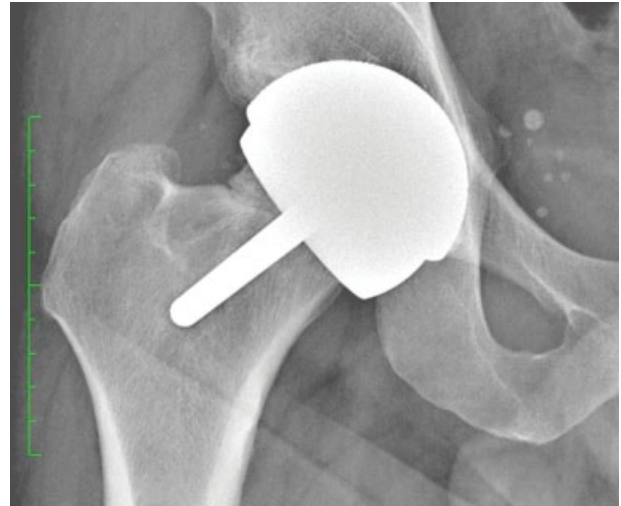
Copyright © 2018 Georg Thieme Verlag  
KG Stuttgart · New York

License terms





**Fig. 1** Postoperative anteroposterior X-ray after hip resurfacing.



**Fig. 2** Anteroposterior X-ray at 2-year follow-up after hip resurfacing showing a stress fracture of the femoral neck.

to better assess diagnosis. The blood serum level of Cr was 1.82  $\mu\text{g/L}$  and Co was 1.38  $\mu\text{g/L}$ .

The day after, the patient underwent surgery under spinal anesthesia in the supine position. As the fracture was incomplete, it was treated like undisplaced femoral neck fracture, with reduction maneuver. A lateral incision was made and under observation from the image intensifier a guidewire was passed superior to the stem of the femoral component of the BHR. One 6.5 mm cannulated screw 75-mm long was placed into the superior neck. The image intensifier was used to confirm that the threads were beyond the fracture line and that the fracture was compressed (**Fig. 3**).

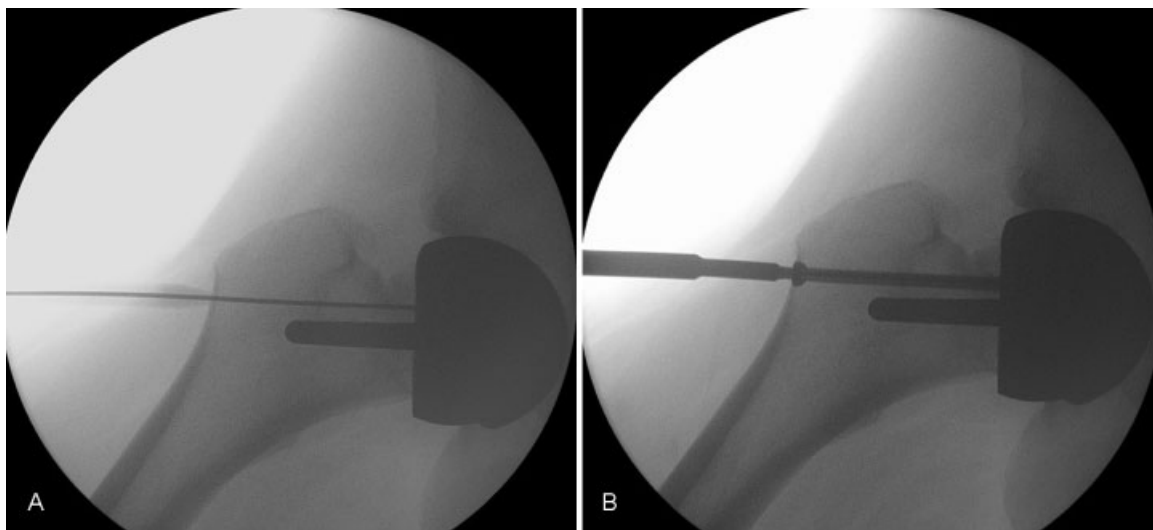
The patient was discharged after 2 days, with two crutches and partial weight-bearing for the next 6 weeks (to prevent a secondary increase of varus angulation), then he gradually returned to his full activity. At 6 months, he began running without limitation. All radiographic controls

at last follow-up showed a good consolidation of the fracture (**Fig. 4**). No differences were found compared with the exams prior to fracture. At the last follow-up, the patient was asymptomatic.

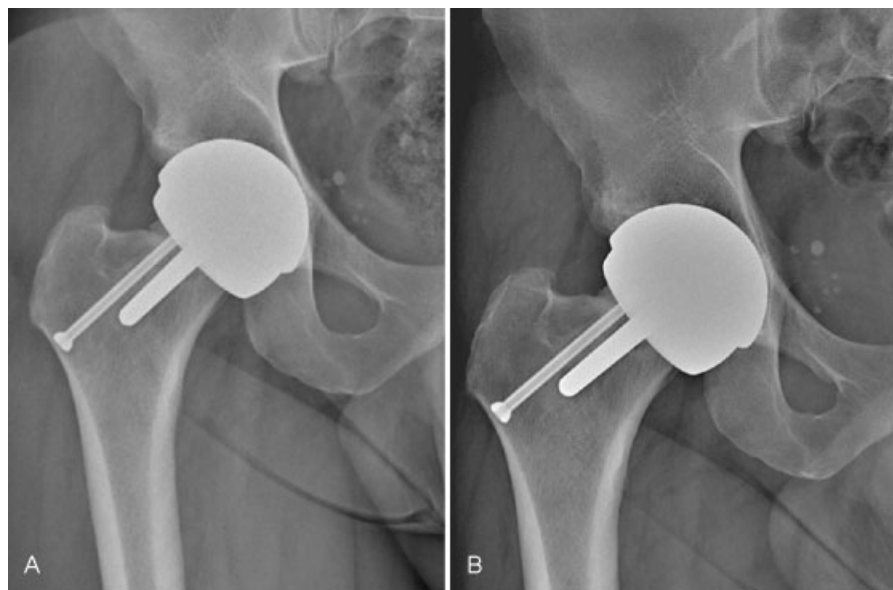
## Discussion

Femoral neck fractures are a well-documented complication of HR and occur within the 9th week after surgery.<sup>2</sup> To prevent this event, it is recommended a careful patient selection and careful surgical technique. In our case, fracture occurred many years after surgery, despite correct implantation of the femoral component and normal BMI of the patient. This scenario and patient history led us to diagnose a stress fracture.

Stress fractures are generated by repetitive mechanical stresses combined with an imbalance of osteoblastic activity



**Fig. 3** Image intensifier during surgery: K-wire is used to check the correct position after (A) reduction maneuver. (B) Screw introduction.



**Fig. 4** Anteroposterior radiograph at (A) 6 months and (B) 18 months after fracture fixation.

in favor of osteoclasts. The result is the appearance of microfractures which, in some cases, may lead to complete fractures.<sup>1,3</sup> For this reason, we chose not to weaken the lower part of the femoral neck and tried to stabilize the fracture. In our opinion, factors associated with the occurrence of the fracture were prolonged downhill running and the hard training on a hard-on-hard prostheses.

The choice of using a single screw was made for several reasons: limited surgical access that does not compromise the blood supply; preserving the bone stock of the femoral neck; avoiding the risk a screw-implant contact resulting in metallosis; and the good quality of bone of the metaphyseal femur.<sup>4</sup>

Although the current consensus in the scientific community is to limit the return to sports, more and more articles are documenting the results of hip prosthesis in athletes.<sup>5</sup> Poor long-term results were reported with total hip replacement (THR) in young patients (under 50 years), revision rate at 20 years being close to 50%. This is probably due to high functional demand of this population. HR is probably the better choice for young patients involved in sports activities. The advantages of this kind of implant are related to preservation of the femoral bone stock, mechanoreceptors of the femoral neck, femoral offset, and femoral lever arm that allow a better perception and reconstruction of the hip anatomy compared with THR.

In conclusion, in selected cases, femoral neck fracture fixation can be attempted in patients with HR. However, it is important to carry out serious checks to avoid a progression of varus angulation of the stem, which could result in a secondary fracture.

#### Conflict of Interest

None.

#### References

- 1 McCormick F, Nwachukwu BU, Provencher MT. Stress fractures in runners. *Clin Sports Med* 2012;31(02):291–306
- 2 Carrothers AD, Gilbert RE, Jaiswal A, Richardson JB. Birmingham hip resurfacing: the prevalence of failure. *J Bone Joint Surg Br* 2010;92(10):1344–1350
- 3 Cadossi M, Moroni A, Romagnoli M, Chiarello E, Faldini C, Giannini S. Bone mineral density of the proximal femur recovers after metal-on-metal hip resurfacing. *Clin Cases Miner Bone Metab* 2010;7(02):135–139
- 4 Kutty S, Pettit P, Powell JN. Intracapsular fracture of the proximal femur fracture after hip resurfacing treated by cannulated screws. *J Bone Joint Surg Br* 2009;91(08):1100–1102
- 5 Banerjee M, Bouillon B, Banerjee C, et al. Sports activity after total hip resurfacing. *Am J Sports Med* 2010;38(06):1229–1236