

Detection of upper extremity deep vein thrombosis by magnetic resonance non-contrast thrombus imaging

Lisette F. van Dam¹ | Charlotte E. A. Dronkers^{1,2} | Gargi Gautam³ | Åsa Eckerbom³ |
Waleed Ghanima^{4,5} | Jostein Gleditsch⁶ | Guido R. van Haren⁷ | Anders von Heijne³ |
Menno V. Huisman¹ | J. Lauran Stöger⁷ | Eli Westerlund³ | Lucia J. M. Kroft⁷ |
Frederikus A. Klok¹

¹Department of Thrombosis and Hemostasis, Leiden University Medical Center, Leiden, The Netherlands

²Department of Internal Medicine, Haaglanden Medical Center, The Hague, The Netherlands

³Department of Clinical Sciences, Karolinska Institute, Danderyd Hospital, Stockholm, Sweden

⁴Internal Medicine Clinic, Østfold Hospital Trust, Østfold, Norway

⁵Department of Haematology, Oslo University Hospital and Institute of Clinical Medicine, University of Oslo, Oslo, Norway

⁶Department of Radiology, Østfold Hospital Trust, Østfold, Norway

⁷Department of Radiology, Leiden University Medical Center, Leiden, The Netherlands

Correspondence

Frederikus A. Klok, Department of Thrombosis and Hemostasis, Leiden University Medical Center, Albinusdreef 2, 2300RC, Leiden, The Netherlands.
Email: f.a.klok@LUMC.nl

Funding information

Dutch Thrombosis Association, Grant/Award Number: 2013-01; Bristol-Myers Squibb/Pfizer, Grant/Award Number: CV185-390

Abstract

Background: Compression ultrasonography (CUS) is the first-line imaging test for diagnosing upper extremity deep vein thrombosis (UEDVT), but often yields inconclusive test results. Contrast venography is still considered the diagnostic standard but is an invasive technique.

Objectives: We aimed to determine the diagnostic accuracy of magnetic resonance noncontrast thrombus imaging (MR-NCTI) for the diagnosis of UEDVT.

Methods: In this international multicenter diagnostic study, we prospectively included patients with clinically suspected UEDVT who were managed according to a diagnostic algorithm that included a clinical decision rule (CDR), D-dimer test, and diagnostic imaging. UEDVT was confirmed by CUS or (computed tomography [CT]) venography. UEDVT was excluded by (1) an unlikely CDR and normal D-dimer, (2) a normal serial CUS or (3) a normal (CT) venography. Within 48 h after the final diagnosis was established, patients underwent MR-NCTI. MR-NCTI images were assessed post hoc by two independent radiologists unaware of the presence or absence of UEDVT. The sensitivity, specificity, and interobserver agreement of MR-NCTI for UEDVT were determined.

Results: Magnetic resonance noncontrast thrombus imaging demonstrated UEDVT in 28 of 30 patients with UEDVT and was normal in all 30 patients where UEDVT was ruled out, yielding a sensitivity of 93% (95% CI 78–99) and specificity of 100% (95% CI 88–100). The interobserver agreement of MR-NCTI had a kappa value of 0.83 (95% CI 0.69–0.97).

Conclusions: Magnetic resonance noncontrast thrombus imaging is an accurate and reproducible method for diagnosing UEDVT. Clinical outcome studies should

determine whether MR-NCTI can replace venography as the second-line imaging test in case of inconclusive CUS.

KEYWORDS

anticoagulation, deep vein thrombosis, diagnosis, diagnostic imaging, magnetic resonance imaging

1 | INTRODUCTION

Upper extremity deep vein thrombosis (UEDVT) is an uncommon presentation of venous thromboembolism (VTE), accounting for approximately 5% to 10% of all thromboses in the deep veins.^{1,2} As in lower extremity deep vein thrombosis (DVT), the first-line imaging test is compression ultrasonography (CUS).³ Diagnosing UEDVT with ultrasonography is more complex than in the lower extremities because of the local anatomy, especially in the axillary and clavicular areas where veins may be difficult to visualize and compress. Therefore, CUS is commonly used in combination with Doppler ultrasonography to diagnose or exclude UEDVT. Contrast venography is the diagnostic standard for UEDVT, but it is an invasive imaging test where patients are exposed to intravenous contrast and radiation. Furthermore, because venography is not routinely performed anymore, radiologists have limited experience evaluating UEDVT by this method.^{4,5} Computed tomography (CT) venography is often used as an alternative, although studies regarding its diagnostic accuracy in UEDVT are scarce.⁶ Moreover, CT venography may be less applicable in patients with severe chronic kidney disease (e.g., stage 4) given the need for intravenous contrast dye. The validation of an alternative, noninvasive imaging technique would therefore satisfy an unmet clinical need.

Magnetic resonance noncontrast thrombus imaging (MR-NCTI) is an imaging technique that may have the potential to replace venography as second-line diagnostic test in case of inconclusive CUS. MR-NCTI is a noncontrast-enhanced MR technique used to directly visualize acute thrombi using the formation of methemoglobin in a fresh thrombus, which appears as a high signal intensity (Appendix S1).^{7,8} MR direct thrombus imaging (MRDTI) is a T1-weighted MR-NCTI sequence that previously has been shown to be an accurate and reproducible diagnostic test in patients with suspected first and recurrent ipsilateral DVT.^{9–11} Moreover, MR-NCTI has shown to be useful in other locations where the diagnosis of thrombosis can be difficult, including isolated pelvic vein thrombosis in pregnant patients and portal vein thrombosis.^{12,13} Three-dimensional turbo spin-echo spectral attenuated inversion recovery (3D TSE-SPAIR) is another T1-weighted MR-NCTI sequence that could be useful in the diagnostic management of UEDVT. Both MRDTI and 3D TSE-SPAIR were found feasible for the diagnosis of UEDVT in a recent small pilot study.¹⁴ We aimed to more accurately determine the diagnostic accuracy of MR-NCTI, combining MRDTI and 3D TSE-SPAIR for the diagnosis of UEDVT.

Essentials

- Diagnosing 'upper extremity deep vein thrombosis (UEDVT)' with 'compression ultrasonography (CUS)' may be challenging.
- We studied the diagnostic accuracy of 'magnetic resonance non-contrast thrombus imaging (MR-NCTI)' for the diagnosis of UEDVT.
- Magnetic resonance non-contrast thrombus imaging is an accurate and reproducible diagnostic test for diagnosing UEDVT.
- Clinical outcome studies should determine whether MR-NCTI can replace venography as the second-line imaging test.

2 | METHODS

2.1 | Study design and patients

The Selene study was a prospective, international, multicenter diagnostic study conducted at three hospitals across three countries from December 2016 to December 2020 (NTR5738). Patients aged 18 years or older with clinically suspected UEDVT, in whom UEDVT was confirmed or excluded by a diagnostic algorithm, were included in the study. Exclusion criteria were suspected recurrent ipsilateral UEDVT, onset of symptoms of more than 10 days before presentation, medical or psychological condition not permitting completion of the study or signing informed consent, and general contraindications for MRI, including but not limited to a cardiac pacemaker or subcutaneous defibrillator. The study protocol was approved by the institutional review board of the Leiden University Medical Center (Leiden, the Netherlands), Danderyd Hospital (Stockholm, Sweden), and Østfold Hospital (Østfold, Norway). All patients provided written informed consent.

2.2 | Procedures

Patients were managed by a predefined diagnostic algorithm, consisting of a clinical decision rule (CDR) for UEDVT by Constans et al,¹⁵ a D-dimer test and imaging including (repeat) CUS and/

or (CT) venography (Figure 1).¹⁶ D-dimer levels were measured with an automated, well-validated, high-sensitivity, quantitative D-dimer assay in accordance with local guidelines (STA-Lia test or Siemens dependent on study site). UEDVT was excluded by either an unlikely clinical probability according the Constans rule in combination with a normal D-dimer test, a normal serial CUS or a normal (CT) venography. UEDVT was confirmed by a positive CUS or (CT) venography. Anticoagulant treatment was started when UEDVT was confirmed according to local protocols.

In all patients with confirmed (group 1) or excluded UEDVT (group 2) MR-NCTI, including both MRDTI and 3D-TSE SPAIR sequences, was performed within 48 h of the initial diagnosis. MRI scans were performed with a 1.5 or 3.0 Tesla unit using an integrated 16-channel posterior coil and a 16-channel anterior body coil for signal reception.^{9,10,17} The complete MRDTI and 3D-TSE SPAIR sequence parameters are provided in Table 1. All MR-NCTI scans were evaluated by a radiologist (L.K.) for assessment of image quality. Patients with MR images with insufficient image quality were excluded from further analysis. We continued the recruitment of patients in groups 1 and 2 until inclusion of 30 patients in each group with MR images of sufficient image quality was achieved.

Patients in whom UEDVT was ruled out were followed for the occurrence of symptomatic VTE over a period of 3 months after inclusion.

2.3 | Image assessment and interpretation

Magnetic resonance non-contrast thrombus imaging scans were evaluated post hoc by two radiologists (L.K. and L.S.) with more than 20 years and 3 years of experience with vascular MRI, respectively, who independently reviewed the images unaware of clinical and radiological (ultrasound and venography) information. In case of any dispute, consensus reading between the two radiologists was performed. They noted the presence or absence of UEDVT for each patient based on all available MR images.

2.4 | Outcomes

The primary outcome was the sensitivity and specificity of MR-NCTI for the diagnosis of UEDVT. The secondary outcome was the inter-observer agreement of MR-NCTI reading for suspected UEDVT.

2.5 | Definitions

An unlikely clinical probability according the Constans rule was defined as a score of <2 points (Table 2).¹⁵ A normal D-dimer test was defined as normal according to the assay-dependent threshold, which differed between the different assays used in the study. A positive CUS for UEDVT was defined as the presence of venous segment area of the upper extremity including subclavian, axillary, brachial, or brachiocephalic vein with >4 mm of noncompressibility.³ A positive (CT) venography for UEDVT was defined as presence of a constant intraluminal filling defect in the deep veins of the arms (subclavian, axillary, brachial, or brachiocephalic vein), as shown on at least two projections. A positive MR-NCTI scan for UEDVT was defined as an increased or aberrant signal intensity in the location of the subclavian, axillary, brachial, or brachiocephalic vein against the suppressed background.¹⁴ Pulmonary embolism (PE) during follow-up was diagnosed with CT pulmonary angiography if there was an intraluminal defect in a segmental or greater pulmonary artery.^{3,18} For ventilation-perfusion scanning, PE was defined as a perfusion defect, segmental or more proximal on lung perfusion scan, and in the presence of a mismatch with the concomitant ventilation scan. PE found at autopsy was also considered diagnostic of VTE. Death related to PE was defined according the following criteria: (1) Certain: hypotension, hypoxia, cardiac arrest with no other explanation other than PE with autopsy or radiographic confirmation; (2) Highly probable: criterion for certain fulfilled but another plausible factor/disease as cause of death also present; (3) Probable: other cause suspected based on clinical evidence but 100% certainty not available; and (4) Unlikely: all other cases.¹⁹

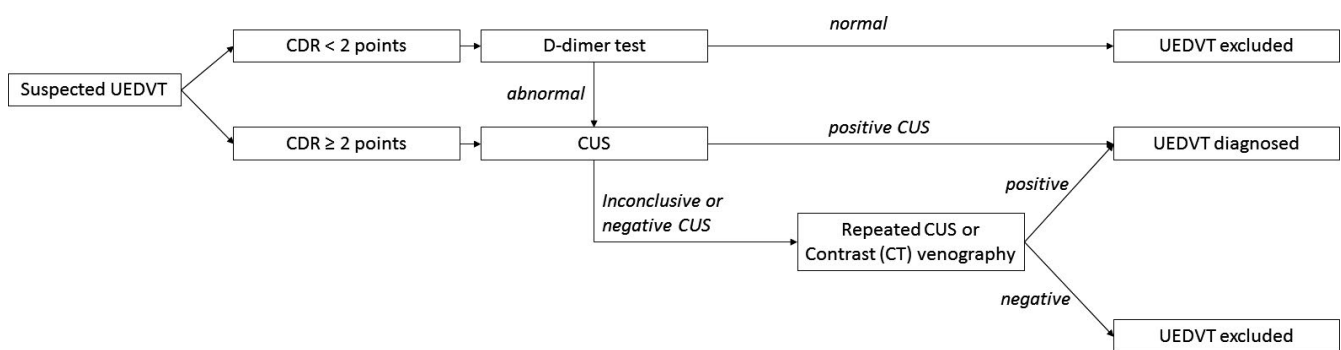


FIGURE 1 Diagnostic algorithm in suspected upper extremity deep vein thrombosis (UEDVT). Note: CDR, clinical decision rule; CT, computed tomography; CUS, compression ultrasonography

	MRDTI	3D TSE-SPAIR
Technique	T1TFE	TSE
Orientation	Coronal	Coronal
FOV	400 × 405	350 × 400
Slices	60	180
Slice thickness (mm)	4.0	1.1
Reconstructed slice thickness (mm)	2.0	-
Voxel size (mm)	1.6 × 2.24 acq. 1.6 × 1.6 recon	1.09 × 1.1 acq. 0.5 × 0.5 recon
Scan time (min)	5:53	5:33
Echo time (ms)	5.4	23
Repetition time (ms)	11	400
Flip angle	15	90
TFE prepulse inversion time (ms)	1200	-
SPAIR inversion delay (ms)	-	110

TABLE 1 Details of MRDTI and 3D TSE-SPAIR scan parameters applied in the study

Note: This table was originally published in *Thrombosis Research*. Dronkers CEA, Klok FA, van Haren GR, Gleditsch J, Westerlund E, Huisman MV, et al. Diagnosing upper extremity deep vein thrombosis with non-contrast-enhanced Magnetic Resonance Direct Thrombus Imaging: A pilot study. *Thrombosis research*. 2018;163:47-50.¹⁴

Abbreviations: 3D TSE-SPAIR, three-dimensional turbo spin-echo spectral attenuated inversion recovery; acq, acquired; FOV, field of view; MRDTI, magnetic resonance direct thrombus imaging; recon, reconstructed; TFE, turbo field-echo; TSE, turbo spin-echo.

TABLE 2 Clinical decision rule for upper extremity deep vein thrombosis by Constans et al

Item	Value
Venous material ^a	1 point
Localized pain along deep veins of the upper arm	1 point
Unilateral pitting edema of the upper arm	1 point
Other diagnosis at least as plausible	-1 point
	Cutoff points
Unlikely clinical probability	<2
Likely clinical probability	≥2

^aVenous material including catheter or access device in a subclavian or jugular vein or pacemaker.

2.6 | Statistical analysis

Baseline characteristics are described as mean with standard deviation (SD) or median with interquartile range (IQR).

For the primary outcome, we estimated the sensitivity of MR-NCTI for the diagnosis of UEDVT which was determined by calculating the proportion of MR scans that were read as “positive for UEDVT” in patients with CUS or (CT) venography proven UEDVT. Specificity was determined by calculating the proportion of MR scans that were read as “negative for UEDVT” in patients where UEDVT was ruled out by either an unlikely CDR and normal D-dimer test or a normal serial CUS or normal (CT) venography both followed by a 3-month follow-up without VTE. The corresponding 95% confidence interval (95% CI) of both the sensitivity and specificity were

calculated. A point estimate of the sensitivity of >90% was defined as acceptable for initiating a future management study. We estimated that a sample size of 30 patients in each group (positive and negative UEDVT diagnosis) was needed to reach the sensitivity of greater than 90% with a corresponding 95% CI of ±15%. Therefore, we aimed to include 60 patients in total.

For the secondary outcome, in which we assessed interobserver agreement of MR-NCTI reading, the κ -statistic was calculated. The kappa value for agreement was interpreted as follows: poor (<0.20), fair (0.21-0.40), moderate (0.41-0.60), good (0.61-0.80), or excellent (0.81-1.00).²⁰ Analyses were performed in SPSS version 25 (IBM, Armonk, NY, USA).

3 | RESULTS

3.1 | Patients

A total of 218 consecutive patients with clinically suspected UEDVT were screened, of whom 148 patients (68%) were excluded for various reasons as per predefined exclusion criteria (Figure 2). Among the 148 patients excluded, 22 (15%) could not be included because of the presence of an implantable device not compatible with MRI (e.g., pacemaker). A total of 70 patients provided written informed consent. MR-NCTI images were adequate for interpretation in 89% of the cases: eight patients were excluded from the main analysis because of MR imaging artefact issues rendering image quality insufficient for final diagnosis. In one patient, MRI could not be performed because of claustrophobia,

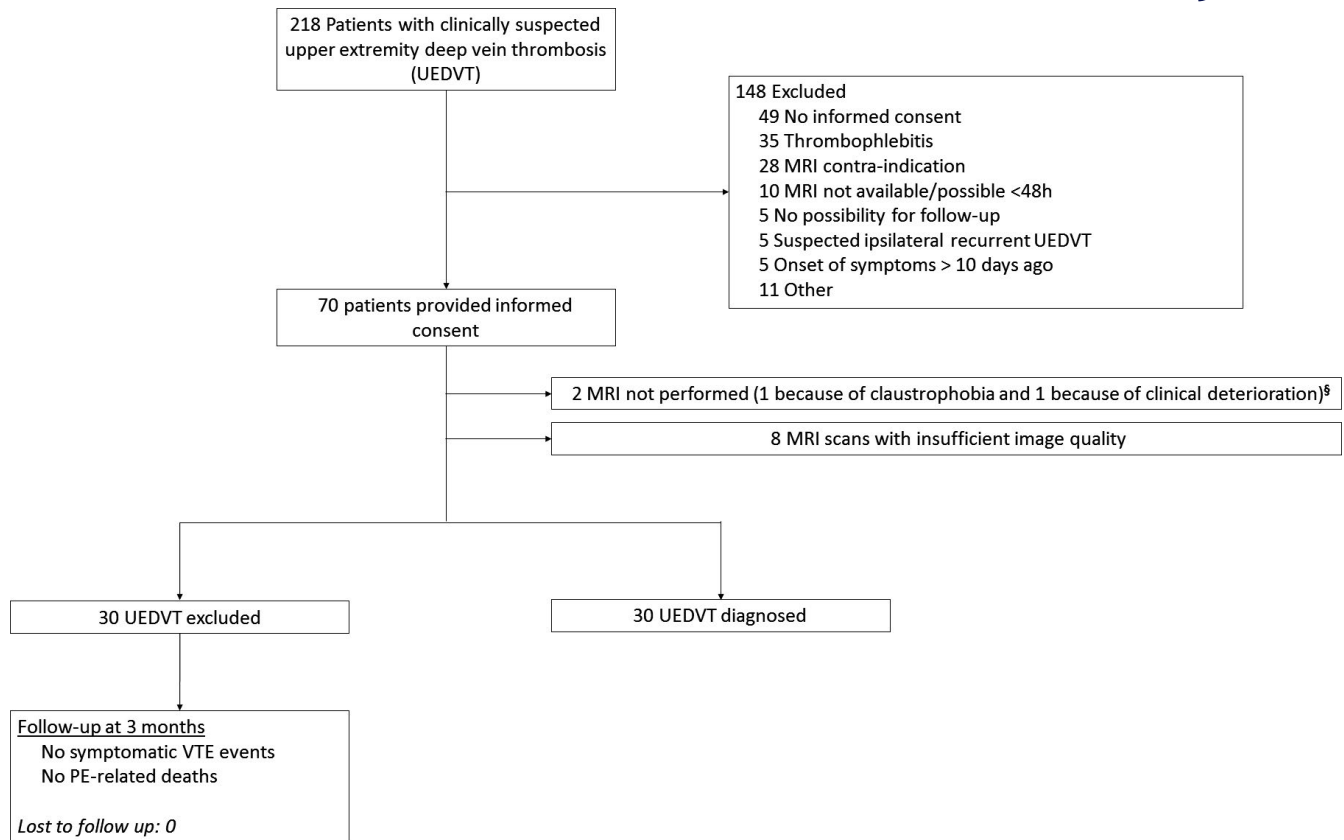


FIGURE 2 Flowchart of study patients. Note: MRI, magnetic resonance imaging; PE, pulmonary embolism; UEDVT, upper extremity deep vein thrombosis; VTE, venous thromboembolism

whereas another patient experienced acute clinical deterioration during scanning. Hence, 60 patients could be included, of whom 30 patients had a confirmed UEDVT and 30 patients had UEDVT ruled out. All patients were subjected to MRDTI, but because of logistical reasons, 3D TSE-SPAIR sequence could not be performed in 8 (13%). The baseline characteristics of the 60 study patients are shown in Table 3. In two patients (3.3%), UEDVT was excluded based on an unlikely clinical probability according the Constans rule in combination with a normal D-dimer result and these patients had no VTE at follow-up. UEDVT was ruled out based on diagnostic imaging in 28 patients and none of these patients were diagnosed with VTE during follow-up (Figure 2). The diagnosis was based on (repeat) ultrasonography in 43 patients (72%) and (CT) venography in 15 patients (25%). In 12 patients (20%), (CT) venography was performed because of an inconclusive CUS or negative CUS but high clinical suspicion. Of these 12 patients, three patients had a negative (repeat) CUS for UEDVT of whom two patients were diagnosed with UEDVT based on (CT) venography and in one patient UEDVT was also excluded based on (CT) venography. In nine patients, (repeat) CUS was positive for UEDVT, but the diagnosis was uncertain and were thus referred for (CT) venography. UEDVT was excluded based on (CT) venography in one patient and also positive for UEDVT in eight patients.

3.2 | Primary outcome

Magnetic resonance noncontrast thrombus imaging was positive in 28 of 30 patients with UEDVT and normal in two patients (Tables 4 and 5). Of these two, the first patient was a 66-year-old female patient with known leiomyosarcoma. She presented with a 6-day episode of pain and swelling of the left upper and lower arm in which a central venous catheter was in situ. At presentation, the patient had a likely clinical probability according the Constans rule (3 points) and D-dimer level of 1975 ng/ml. CT venography was performed because of an inconclusive CUS examination. CT showed a hypoplastic left internal jugular vein with an intraluminal hypodensity, compatible with thrombosis, at the confluence and in the proximal hypoplastic left internal jugular vein. MR-NCTI was performed at 48 h after the diagnosis. MRDTI and 3D TSE-SPAIR sequences were considered diagnostic for DVT in the left jugular vein according one reviewer and negative for DVT according to the second reviewer. Consensus reading resulted in a negative DVT diagnosis. The second case with UEDVT and a normal MR-NCTI involved a 52-year-old male patient presenting with pain and pitting edema of the right arm for 3 days. At presentation, the patient had a likely clinical probability according the Constans rule (2 points) and a D-dimer result of 1600 ng/ml. CT venography showed thrombosis in the right subclavian vein. MR-NCTI scan was performed at 2 h after the diagnosis.

Both MRDTI and 3D TSE SPAIR sequences were negative for DVT according to both reviewers. In both patients, therapeutic anticoagulant treatment was started based on the results of CT venography.

Magnetic resonance noncontrast thrombus imaging was normal in all 30 patients in whom UEDVT was ruled out (Table 4). Hence,

TABLE 3 Baseline characteristics of 60 patients with suspected upper extremity deep vein thrombosis (UEDVT)

	Patients With Confirmed UEDVT	Patients With UEDVT Excluded
Mean age (\pm SD) – years	50 (16)	58 (17)
Male – no. (%)	16 (53)	18 (60)
Median duration of complaints (IQR) – days	4.0 (2.0–8.0)	2.5 (2.0–6.3)
Malignancy – no. (%)	7 (23)	10 (33)
Trauma/surgery during the past 4 weeks – no. (%)	5 (17)	4 (13)
Hormone (replacement) therapy – no. (%)	5 (17)	2 (6.7)
Paralysis, paresis, or plaster immobilization – no. (%)	0 (0)	1 (3.3)
Intravenous material in subclavian or jugular vein (catheter or access device)	7 (23)	5 (17)

Abbreviations: IQR, interquartile range; SD, standard deviation.

TABLE 4 Comparison of MR-NCTI results in patients with UEDVT and without UEDVT

		UEDVT	No UEDVT
MR-NCTI	Abnormal	28	0
	Normal	2	30

Abbreviations: CDR, clinical decision rule; MR-NCTI, magnetic resonance noncontrast thrombus imaging; UEDVT, upper extremity deep vein thrombosis; US, ultrasonography.

TABLE 5 Characteristics of the two patients with false-negative MR-NCTI result

	Sex	Age (years)	Symptom Duration (days)	Constans' Score (points)	D-dimer (ng/ml)	MR-NCTI	Contrast Venography
Patient 1	Female	66	6	3	1975	Negative for UEDVT	Hypoplastic left internal jugular vein and intraluminal hypodensity at the confluence of the left subclavian and internal jugular vein and in the proximal hypoplastic jugular vein
Patient 2	Male	52	3	2	1600	Negative for UEDVT	Thrombus in right subclavian vein

Abbreviations: MR-NCTI, magnetic resonance non-contrast thrombus imaging; UEDVT, upper extremity deep vein thrombosis.

the sensitivity of MR-NCTI for the diagnosis of UEDVT was 93% (95% CI 78–99) and the specificity was 100% (95% CI 88–100). Figure 3 shows MR images diagnostic for UEDVT.

3.3 | Secondary outcome

The two independent reviewers disagreed on five of the 60 MR-NCTI readings. Hence, the interobserver agreement between two independent readers had a kappa value of 0.83 (95% CI 0.69–0.97). Consensus reading of the MR-NCTI scans with discrepancy between the two readers resulted in a correct positive diagnosis in four patients and a falsely negative UEDVT diagnosis in one patient.

4 | DISCUSSION

In this study, we showed that MR-NCTI is accurate for the diagnosis of UEDVT, with a sensitivity of 93% (95% CI 78–99%) and specificity of 100% (95% CI 88–100%). Moreover, the interobserver agreement was excellent with a kappa value of 0.83 (95% CI 0.69–0.97).

Current guidelines recommend CUS combined with Doppler ultrasonography as the first-line imaging test in patients with suspected UEDVT, because of its availability, relatively low cost and noninvasive nature.³ Because the diagnosis of UEDVT can be difficult as deep axillary and retro-clavicular areas cannot be well visualized nor compressed due to overlying (bone) structures, both CUS and Doppler ultrasonography can be used to confirm UEDVT in the presence of noncompressibility of a venous segment and/or in the absence of a color or Doppler signal within the lumen of the vein or to exclude UEDVT in the absence of these findings. Moreover, follow-up imaging including repeat CUS combined with Doppler, contrast-venography or CT venography is recommended in patients with high clinical suspicion but negative ultrasound.³

Previously, MR venography (time-of-flight and contrast-enhanced) has been evaluated as alternative in the diagnostic management of UEDVT, but was not safe to exclude UEDVT (sensitivity of 71% [95% CI 29–96] and 50% [95% CI 12–88] and specificity of 89% [95% CI 52–100] and 80% [95% CI 44–97], respectively).²¹ MR-NCTI has the advantage of direct thrombus visualization without the use of a contrast agent as the technique is based on the intrinsic

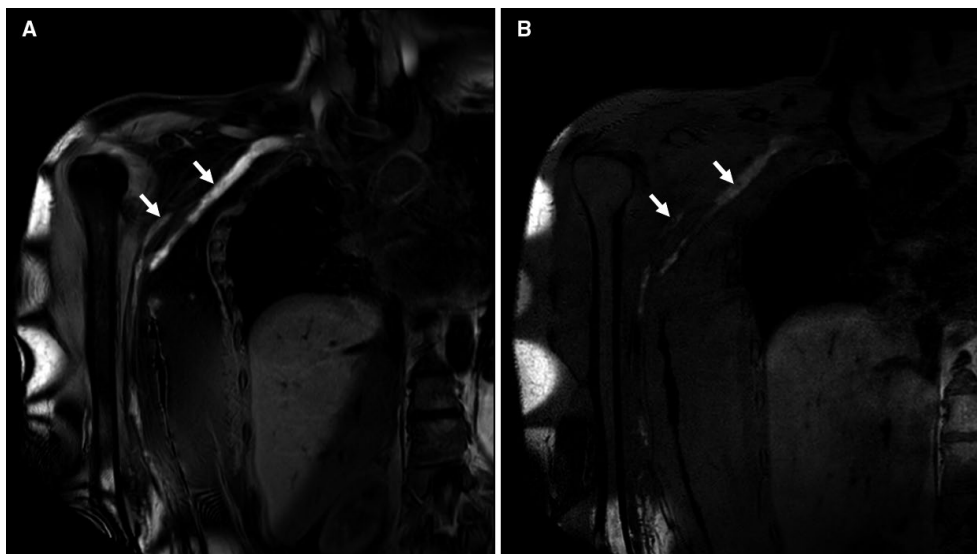


FIGURE 3 Magnetic resonance imaging of the right upper extremity in coronal view of a patient diagnosed with acute deep vein thrombosis in right brachial and axillar vein. (A) Magnetic resonance direct thrombus imaging (MRDTI) and (B) three-dimensional turbo spin-echo spectral attenuated inversion recovery (3D TSE-SPAIR) showing high signal intensity in brachial and axillar vein (arrows) compatible with an acute thrombus

contrast of fresh thrombus itself.^{7,11-14,22-26} 3D TSE-SPAIR has some advantages over MRDTI sequences, including a higher spatial resolution of the vessel wall and less inflow artefacts in the arteries.¹⁴ The two techniques were found to be potentially feasible for the diagnosis of UEDVT, which was confirmed in this study.¹⁴ We found a sensitivity and specificity of MR-NCTI that are comparable to that of MRDTI in the diagnosis of recurrent ipsilateral DVT of the leg, and for which the safety to exclude recurrent ipsilateral DVT of the leg was confirmed in an outcome study.^{9,11} Notably, MR-NCTI missed the diagnosis of UEDVT in two patients in our study. In one patient, the MR-NCTI was performed after 48 h of anticoagulant therapy and the anatomy was particular complex with a hypoplastic jugular vein, which may have contributed to a false-negative reading by the experts. In the other case, no straightforward explanation was identified.

A limitation of the study is that 3D TSE-SPAIR sequence was not performed in all patients. Also, MR image quality of eight patients was deemed insufficient to provide a definite diagnosis. Direct thrombus imaging seems more challenging in the upper arms and clavicular areas than in the lower extremities, because of the vascular orientation and image artefacts due to respiratory motion and cardiac and vascular pulsation, limiting the image and contrast quality of the MRDTI scan. Therefore, we recommend using the combination of MRDTI and 3D TSE-SPAIR sequences in all patients when applied in the diagnostic management of suspected UEDVT. A drawback of such practice is the longer image acquisition time (30 min) compared with that of performing only one of the sequences (MRDTI) in the lower extremities (10 min). Moreover, it is important that experience in performing and image reading of these techniques is gained before it can be used for the diagnosis of UEDVT.

Strengths of this study include its prospective design. The MR-NCTI scans were performed in different centers across different countries and using MR scanners of different manufactures. This, together with the excellent interobserver agreement, supports the wide applicability of this technique. We were able to prove its accuracy for the diagnosis of UEDVT in an adequate patient sample and also included the subgroup of patients with inconclusive ultrasound, for which the use of MR-NCTI may be particularly relevant. Because MRI is associated with higher costs compared with ultrasonography, it should not be used as first-line imaging test. Instead, we suggest that MR-NCTI could potentially serve as a second-line imaging test in patients with high clinical suspicion for UEDVT but inconclusive ultrasound. Because it was not the aim of the current study to assess the accuracy of MR-NCTI in this particular setting, future studies to the safety of this technique to exclude UEDVT in case of an inconclusive ultrasound are needed.

In conclusion, MR-NCTI was accurate for the diagnosis of UEDVT, and had an excellent interobserver agreement. Future studies should determine whether this technique can replace venography as the second-line imaging test in patients with an inconclusive CUS.

ACKNOWLEDGMENTS

This study was supported by an unrestricted grant from BMS/Pfizer (CV185-390). F. A. K. and C. E. A. D. are supported by the Dutch Thrombosis Association (2013-01). INVENT (International Network of Venous Thromboembolism Clinical Research Networks) endorsed and supported this study.

CONFLICT OF INTEREST

We declare no competing interests.

AUTHOR CONTRIBUTION

Charlotte E. A. Dronkers, Menno V. Huisman, Lucia J. M. Kroft, and Frederikus A. Klok designed the study. Lisette F. van Dam, Charlotte E. A. Dronkers, Lucia J. M. Kroft, Gargi Gautam, Eli Westerlund, and Frederikus A. Klok managed the study with support and input from all other authors. Lisette F. van Dam, Charlotte E. A. Dronkers, Gargi Gautam, Eli Westerlund, and Frederikus A. Klok analyzed the data, which were interpreted by all other authors. Lisette F. van Dam and Frederikus A. Klok wrote the first draft of the manuscript, which was reviewed, modified and approved by all other authors.

REFERENCES

- Spencer FA, Emery C, Lessard D, Goldberg RJ. Upper extremity deep vein thrombosis: a community-based perspective. *Am J Med.* 2007;120(8):678-684.
- Muñoz FJ, Mismetti P, Poggio R, et al. Clinical outcome of patients with upper-extremity deep vein thrombosis: results from the RIETE registry. *Chest.* 2008;133(1):143-148.
- Lim W, Le Gal G, Bates SM, et al. American Society of Hematology 2018 guidelines for management of venous thromboembolism: diagnosis of venous thromboembolism. *Blood Adv.* 2018;2(22):3226-3256.
- Baarslag HJ, van Beek EJ, Koopman MM, Reekers JA. Prospective study of color duplex ultrasonography compared with contrast venography in patients suspected of having deep venous thrombosis of the upper extremities. *Ann Intern Med.* 2002;136(12):865-872.
- Dronkers CE, Klok FA, Huisman MV. Current and future perspectives in imaging of venous thromboembolism. *J Thromb Haemost.* 2016;14(9):1696-1710.
- Bosch FTM, Nisio MD, Büller HR, van Es N. Diagnostic and therapeutic management of upper extremity deep vein thrombosis. *J Clin Med.* 2020;9(7):2069.
- Moody AR. Magnetic resonance direct thrombus imaging. *J Thromb Haemost.* 2003;1(7):1403-1409.
- Saha P, Andia ME, Modarai B, et al. Magnetic resonance T1 relaxation time of venous thrombus is determined by iron processing and predicts susceptibility to lysis. *Circulation.* 2013;128(7):729-736.
- Tan M, Mol GC, van Rooden CJ, et al. Ability of magnetic resonance direct thrombus imaging (MRDTI) to differentiate acute recurrent ipsilateral deep vein thrombosis from residual thrombosis. *Blood.* 2014;124:623-627.
- Westerbeek RE, Van Rooden CJ, Tan M, et al. Magnetic resonance direct thrombus imaging of the evolution of acute deep vein thrombosis of the leg. *J Thromb Haemost.* 2008;6(7):1087-1092.
- van Dam LF, Dronkers CEA, Gautam G, et al. Magnetic resonance imaging for diagnosis of recurrent ipsilateral deep vein thrombosis. *Blood.* 2020;135(16):1377-1385.
- Dronkers CE, Sramek A, Huisman MV, Klok FA. Accurate diagnosis of iliac vein thrombosis in pregnancy with magnetic resonance direct thrombus imaging (MRDTI). *BMJ Case Rep.* 2016;2016:bcr2016218091.
- van Dam LF, Klok FA, Tushuizen ME, et al. Magnetic resonance thrombus imaging to differentiate acute from chronic portal vein thrombosis. *TH Open.* 2020;4(3):e224-e230.
- Dronkers CEA, Klok FA, van Haren GR, et al. Diagnosing upper extremity deep vein thrombosis with non-contrast-enhanced magnetic resonance direct thrombus imaging: a pilot study. *Thromb Res.* 2018;163:47-50.
- Constans J, Salmi LR, Sevestre-Pietri MA, et al. A clinical prediction score for upper extremity deep venous thrombosis. *Thromb Haemost.* 2008;99(1):202-207.
- Huisman MV, Klok FA. Diagnostic management of acute deep vein thrombosis and pulmonary embolism. *J Thromb Haemost.* 2013;11(3):412-422.
- Dronkers CEA, Klok FA, van Langevelde K, et al. Diagnosing recurrent DVT of the leg by two different non-contrast-enhanced magnetic resonance direct thrombus imaging techniques: a pilot study. *TH Open.* 2019;3(1):e37-e44.
- Huisman MV, Barco S, Cannegieter SC, et al. Pulmonary embolism. *Nat Rev Dis Primers.* 2018;4:18028.
- Scarvelis D, Anderson J, Davis L, et al. Hospital mortality due to pulmonary embolism and an evaluation of the usefulness of preventative interventions. *Thromb Res.* 2010;125(2):166-170.
- Cohen J. Weighted kappa: nominal scale agreement with provision for scaled disagreement or partial credit. *Psychol Bull.* 1968;70(4):213-220.
- Baarslag HJ, Van Beek EJ, Reekers JA. Magnetic resonance venography in consecutive patients with suspected deep vein thrombosis of the upper extremity: initial experience. *Acta Radiol.* 2004;45(1):38-43.
- Klok FA, Pruefer D, Rolf A, Konstantinides SV. Magnetic resonance direct thrombus imaging for pre-operative assessment of acute thrombosis in chronic thromboembolic pulmonary hypertension. *Eur Heart J.* 2019;40(11):944.
- Kelly J, Hunt BJ, Moody A. Magnetic resonance direct thrombus imaging: a novel technique for imaging venous thromboemboli. *Thromb Haemost.* 2003;89(5):773-782.
- Tan M, Mol GC, van Rooden CJ, et al. Magnetic resonance direct thrombus imaging differentiates acute recurrent ipsilateral deep vein thrombosis from residual thrombosis. *Blood.* 2014;124(4):623-627.
- Barco S, Konstantinides S, Huisman MV, Klok FA. Diagnosis of recurrent venous thromboembolism. *Thromb Res.* 2018;163:229-235.
- van Dam LF, Kroft LJ, Dronkers CE, et al. Magnetic resonance direct thrombus imaging (MRDTI) can distinguish between old and new thrombosis in the abdominal aorta: a case report. *Eur J Case Rep Intern Med.* 2020;7(1):1351.

SUPPORTING INFORMATION

Additional supporting information may be found online in the Supporting Information section.

How to cite this article: van Dam LF, Dronkers CEA, Gautam G, et al. Detection of upper extremity deep vein thrombosis by magnetic resonance non-contrast thrombus imaging. *J Thromb Haemost.* 2021;19:1973-1980. <https://doi.org/10.1111/jth.15394>