

## Accumulation of Eosinophils in the Infundibulum of the Bovine Oviduct Just after Ovulation

Rasoul KOWSAR<sup>1)\*\*</sup>, Sineenard JIEMTAWEEBOON<sup>1)</sup>, Koumei SHIRASUNA<sup>1)</sup>, Takashi SHIMIZU<sup>1)</sup>, Motoki SASAKI<sup>2)</sup>, Nobuo KITAMURA<sup>2)</sup> and Akio MIYAMOTO<sup>1)\*</sup>

<sup>1)</sup>Graduate School of Animal and Food Hygiene, Obihiro University of Agriculture and Veterinary Medicine, Obihiro, Hokkaido 080-8555, Japan

<sup>2)</sup>Department of Basic Veterinary Medicine, Obihiro University of Agriculture and Veterinary Medicine, Obihiro, Hokkaido 080-8555, Japan

(Received 11 March 2013/Accepted 14 May 2014/Published online in J-STAGE 30 May 2014)

**ABSTRACT.** This study was to investigate the localization and distribution of eosinophils (EOS) in the bovine oviduct throughout the estrous cycle. Histological studies revealed more abundant EOS in the infundibula of the oviducts ipsilateral to the preovulatory dominant follicle and the ovulated ovary. The number of EOS was higher in the infundibula of the oviducts ipsilateral to the ovulated ovary than those of the oviducts contralateral to the ovulated ovary. The infundibula of the oviducts ipsilateral to the preovulatory dominant follicle had higher number of EOS than those of the oviducts ipsilateral to the mid-cycle corpus luteum. The number of EOS in the isthmus, but not in the ampulla, was higher in the outer layers (*tunica muscularis* and *tunica serosa*) than in the inner layers (*tunica mucosa* and *tunica submucosa*) during the estrous cycle. Thus, the EOS number varied with the region of the bovine oviduct, with greater number in the infundibula of the oviduct ipsilateral to the ovulated ovary, suggesting the impact of ovulation.

**KEY WORDS:** bovine, eosinophil, oviduct, ovulation

doi: 10.1292/jvms.13-0130; *J. Vet. Med. Sci.* 76(9): 1231–1234, 2014

The mammalian oviduct provides an optimal environment for sperm capacitation, fertilization and transport of gametes and the new embryo. Sperm and the embryo, which are allogenic and semi-allogenic agents, respectively, directly contact with oviduct epithelial cells, that could induce the immune responses in female [13, 15].

During the estrous cycle in the cow, the oviduct is exposed to different concentrations of the sex hormones, estradiol (E<sub>2</sub>, during the preovulatory phase) and progesterone (P<sub>4</sub>, during the luteal phase). Moreover, the oviduct ipsilateral to the dominant follicle or corpus luteum (CL) is exposed to much higher levels of E<sub>2</sub> and P<sub>4</sub>, respectively [19]. Importantly, the oviduct ipsilateral to the functional ovary is the site of sperm capacitation and the development of the new embryo. Therefore, immunological discrimination between the ipsilateral and contralateral oviducts could help to explain local reproductive immunity, at least in part.

Eosinophils (EOS) are involved in both innate and acquired immunity [14], and they are able to regulate local immunity through their secretion of cytokines and enzymes

[7, 12]. The EOS also produces cysteinyl leukotrienes (cysLTs), which increases vascular permeability, mucus secretion and smooth muscle constriction [3]. Since these local phenomena are known to be the feature of the bovine oviduct around the time of ovulation [18], EOS may play a role in the oviduct physiology around this period.

So far, no information is available on the distribution of EOS in the different layers and regions of the oviduct in relation to the functional ovary throughout the estrous cycle. It is hypothesized that the number of EOS in the oviduct changes 1) according to the position of the oviduct relative to the functional ovary bearing the preovulatory dominant follicle, ovulated site or CL (i.e., ipsilateral vs. contralateral), 2) in response to fluctuations in the levels of sex steroid hormones during the estrous cycle and 3) also regarding the different layers of the oviduct, the outer layers (*tunica muscularis* and *tunica serosa*) than the inner layers (epithelial layer, *tunica mucosa* and *tunica submucosa*). Thus, we aimed to investigate in detail the regional distribution of EOS in the bovine oviduct during the estrous cycle.

### MATERIALS AND METHODS

*Collection and classification of oviducts:* In the local slaughterhouse, the female reproductive tracts were opened and macroscopically examined to be healthy (free of inflammation, pus and abnormal color). Forty-two oviducts from 21 Holstein cows were transported from the slaughterhouse to the laboratory immersed in 0.9% saline solution in an ice box. In the laboratory, the ovaries were also examined to be free of any cystic follicle and inflammation. Moreover, the oviducts were checked to be without inflammation, swelling,

\*CORRESPONDENCE TO: MIYAMOTO, A., Graduate School of Animal and Food Hygiene, Obihiro University of Agriculture and Veterinary Medicine, Obihiro, Hokkaido 080-8555, Japan.  
e-mail: akiomiya@obihiro.ac.jp

\*\*CURRENT ADDRESS: KOWSAR, R., Department of Animal Science, College of Agriculture, Isfahan University of Technology, Isfahan 84156-83111, Iran.

©2014 The Japanese Society of Veterinary Science

This is an open-access article distributed under the terms of the Creative Commons Attribution Non-Commercial No Derivatives (by-nc-nd) License <<http://creativecommons.org/licenses/by-nc-nd/3.0/>>.

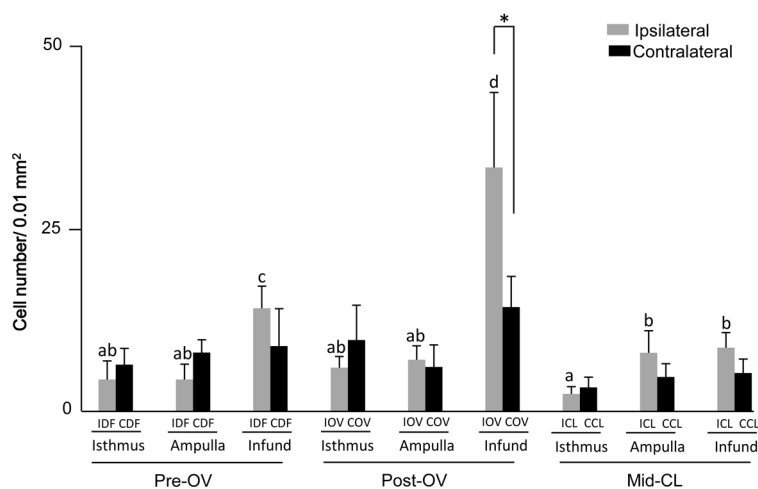


Fig. 1. Number of eosinophils in the different regions of the bovine oviduct during the estrous cycle. Pre-OV: preovulatory phase; Post-OV: postovulatory phase; Mid-CL: mid-cycle corpus luteum; IDF: oviducts ipsilateral to the preovulatory dominant follicle; CDF: oviducts contralateral to the preovulatory dominant follicle; IOV: oviducts ipsilateral to the ovulated ovary; COV: oviducts contralateral to the ovulated ovary; ICL: oviducts ipsilateral to the corpus luteum; CCL: oviducts contralateral to the corpus luteum; Infund: Infundibulum. Data are presented as the mean  $\pm$  SEM. a-d Different letters for black bars indicate significant differences ( $P<0.05$ ) among the oviduct ipsilateral to dominant follicle, ovulated ovary and the corpus luteum. \* Indicates significant differences ( $P<0.05$ ) between ipsilateral and contralateral infundibula to the ovulated ovary at postovulatory phase.

abscesses and pus. Then, the oviducts were classified based on the stage of the estrous cycle as preovulatory, postovulatory and mid-luteal. The stage of the estrous cycle was identified by macroscopic observation, based on the size, color, consistency and connective tissue of the ovaries (CL and follicles) as previously described [6, 10]. Briefly, the preovulatory phase was estimated as the ovary contained at least one large follicle  $>10$  mm in diameter and a regressed corpus luteum ( $<10$  mm in diameter, firm in consistency) with no vasculature visible on its surface. The external appearance of CL was light yellow to white in color. The postovulatory phase was estimated as the CL recently ovulated with point of rupture that was not covered over by epithelium. The CL (5 to 15 mm in diameter) was red in color in both the surface and the vertical section, and cells were loosely organized. There was not any follicle  $>8$  mm in diameter on the ovary. The mid-luteal phase was estimated with mature CL (15 to 25 mm in diameter) in a tan or orange color in the external and internal parts.

Oviducts were also classified as ipsilateral to the preovulatory dominant follicle (IDF,  $n=7$ ), contralateral to the dominant follicle (CDF,  $n=7$ ), ipsilateral to the ovulated ovary (IOV,  $n=7$ ), contralateral to the ovulated ovary (COV,  $n=7$ ), ipsilateral to the CL (ICL,  $n=7$ ) and contralateral to the CL (CCL,  $n=7$ ) depending on the side and the stage of the estrous cycle. The connective tissues were removed, and the oviducts divided into the isthmus, ampulla and infundibulum; the ambiguous area between the isthmus and ampulla was discarded.

**Examination of EOS number:** Three paraffin-embedded tissue sections (5- $\mu$ m thick) of the samples were serially mounted on gelatin-coated slides. The EOS were stained across 3 serial slides using the Luna protocol [8], and positive-stained cells were photographed using a light microscope (Microphot-FX, Nikon, Tokyo, Japan) equipped with a micro digital camera (FX-35DX, DS-5M, Nikon). The number of EOS in each region (i.e. *tunica muscularis*, *tunica serosa*, *tunica mucosa* and *tunica submucosa*) was counted in 3 serial sections per each oviduct and 3 different 0.01 mm<sup>2</sup> areas (100  $\times$  100  $\mu$ m=0.01 mm<sup>2</sup>) in a section per each region. Thus, 3 sections  $\times$  3 squares  $\times$  0.01 mm<sup>2</sup>=0.09 mm<sup>2</sup> area of each region were counted and averaged.

**Statistical analysis:** Data on EOS number in the different regions, layers and in ipsilateral vs contralateral oviducts were statistically analyzed with One-way ANOVA followed by Fisher's multiple comparison tests (for 3 groups) and Student's *t*-test (for 2 groups) using Stat View 5.0 (SAS Institute Inc.). Data are presented as the mean  $\pm$  SEM, and all results were considered to be statistically significant at  $P<0.05$ .

## RESULTS

**Number of EOS in the different regions of the oviduct during the estrous cycle:** As shown in Fig. 1, in the IDF and IOV oviducts, EOS accumulated to higher numbers in the infundibulum than in the isthmus and ampulla ( $P<0.05$ ). The number of EOS was higher in the infundibula of the IOV oviducts than those of the COV oviducts ( $P<0.05$ ). The

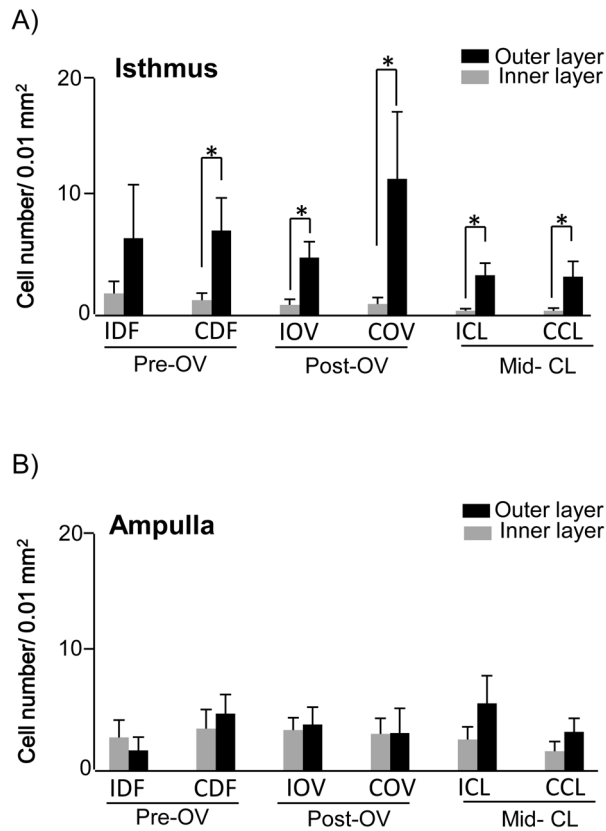


Fig. 2. Number of eosinophils in the different layers of the (A) isthmus and (B) ampulla during the estrous cycle. Pre-OV: preovulatory phase; Post-OV: postovulatory phase; Mid-CL: mid-cycle corpus luteum; IDF: oviducts ipsilateral to the preovulatory dominant follicle; CDF: oviducts contralateral to the preovulatory dominant follicle; IOV: oviducts ipsilateral to the ovulated ovary; COV: oviducts contralateral to the ovulated ovary; ICL: oviducts ipsilateral to the corpus luteum; CCL: oviducts contralateral to the corpus luteum; Inner layer: *tunica mucosa* and *tunica submucosa*, outer layer: *tunica muscularis* and *tunica serosa*. Data are presented as the mean  $\pm$  SEM. \* Indicates significantly different values between inner layer and outer layer ( $P < 0.05$ ).

numbers of EOS in the different regions (infundibulum, isthmus and ampulla) of CDF, COV and CCL oviducts were not affected by the estrous cycle. The numbers of EOS changed during the estrous cycle only in the infundibulum, significantly higher in the IDF than in the ICL oviducts. Moreover, the number of EOS was highest ( $P < 0.05$ ) in the infundibula of the IOV compared with those of the IDF and ICL.

*Number of EOS in the different layers of the oviduct during the estrous cycle:* The number of EOS in the isthmus (both ipsilateral and contralateral) was higher in the outer layers (i.e., the *tunica muscularis* and *tunica serosa*) than in the inner layers (*tunica mucosa* and *tunica submucosa*) at different stages of the estrous cycle (Fig. 2A,  $P < 0.05$ ). Moreover, the number of EOS in the different layers of the ampulla (inner vs. outer layers) was not significantly different during the estrous cycle (Fig. 2B).

## DISCUSSION

The present study indicates the higher numbers of EOS in the infundibula of the oviducts ipsilateral to the preovulatory dominant follicle than in the corresponding isthmus and ampulla regions. Valle *et al.* [17] also reported higher number of EOS in the infundibulum than isthmus and ampulla during the estrous. The reason for the higher number of EOS in the infundibula than isthmus and ampulla during preovulatory phase is not clear; further studies are required to determine the exact reason of this phenomenon. However, the smaller numbers of EOS in the isthmus (sperm reservoir) and ampulla (fertilization site) may reduce the capacity for unwanted immune responses, especially during the preovulatory and postovulatory phases.

Interestingly, in the postovulatory oviducts, the numbers of EOS were significantly higher in the infundibula of the oviducts ipsilateral to the ovulated ovary in comparison with those contralateral to the ovulated ovary. There may be 2 possibilities for this phenomenon. First, ovulation, along with the entry into the oviduct of ovulated follicular fluid containing eosinophilic chemokines, such as eotaxin, RANTES [2] and IL-8 [1, 20], could induce migration of EOS [4] toward the oviduct ipsilateral to the ovulated ovary. Second, the infundibulum is anatomically in a direct contact with the ovary and is exposed to the ovulation. Thus, ovulation, itself an inflammatory event with bleeding, may induce the infiltration of EOS into the infundibulum. It is reported that EOS infiltrates into the inflamed tissues rapidly [9]. Therefore, the present data suggest that ovulation has a profound effect on increase in number of EOS in the infundibulum ipsilateral to the ovulated ovary.

It has been shown that circulating E2 enhances the migration of EOS to the rat uterus [16] and P4 decreases estrogen-induced migration to the rat uterus [5] and cervix [11]. Therefore, it was hypothesized that ovarian steroids may regulate the number of EOS in the oviduct. To examine this possibility, we compared the oviducts from preovulatory phase (high E2/low P4, ipsilateral to the dominant follicle) and oviducts from mid luteal phase (high P4/low E2, ipsilateral to the CL). The data showed that number of EOS changed only in the ipsilateral infundibulum, but not in the ampulla and isthmus, with higher number of EOS in the preovulatory phase than in the mid luteal phase. This suggests that E2 from dominant follicle and P4 from CL may regulate the number of EOS in the ipsilateral infundibula. Although we previously reported the concentrations of ovarian steroids in the oviduct throughout estrous cycle [19], we did not measure the concentrations of the ovarian steroids in the infundibula in that study. Further investigations are necessary to confirm the effect of E2 and P4 on the migration and number of EOS in the bovine oviduct.

The present data showed the higher accumulation of EOS in the outer layers (*tunica muscularis* and *tunica serosa*) than in the inner layers (*tunica mucosa* and *tunica submucosa*) of the isthmus at all examined stages of the estrous cycle. However, this phenomenon was not observed in the ampulla. Since isthmus is a site for sperm reservoir, the lower number

of EOS in isthmus may reduce the direct contact of EOS with sperm in healthy oviducts.

The exact reason for the presence of EOS in the healthy oviduct remains unclear; however, it is suggestive that EOS may enhance luminal secretion *via* their secretions and also increase vascular permeability, mucus secretion and smooth muscle constriction [3], which could affect oviduct function and thus fertility.

The results of this study show a specific regional distribution of EOS in the healthy bovine oviduct throughout the estrous cycle. The number of EOS in the oviduct is profoundly affected by ovulation and may be regulated, in part, by ovarian steroids from the preovulatory follicle and mid-cycle corpus luteum.

## REFERENCES

1. Arici, A., Oral, E., Bukulmez, O., Buradagunta, S., Engin, O. and Olive, D. L. 1996. Interleukin-8 expression and modulation in human preovulatory follicles and ovarian cells. *Endocrinology* **137**: 3762–3769. [Medline]
2. Aust, G., Simchen, C., Heider, U., Hmeidan, F.A., Blumenauer, V. and Spanel-Borowski, K. 2000. Eosinophils in the human corpus luteum: the role of RANTES and eotaxin in eosinophil attraction into periovulatory structures. *Mol. Hum. Reprod.* **6**: 1085–1091. [Medline] [CrossRef]
3. Bandeira-Melo, C., Woods, L. J., Phoofolo, M. and Weller, P. F. 2002. Intracrine cysteinyl leukotriene receptor-mediated signaling of eosinophil vesicular transport-mediated interleukin-4 secretion. *J. Exp. Med.* **196**: 841–850. [Medline] [CrossRef]
4. Erger, R. A. and Casale, T. B. 1995. Interleukin-8 is a potent mediator of eosinophil chemotaxis through endothelium and epithelium. *Am. J. Physiol.* **268**: L117–122. [Medline]
5. Grunert, G., Porcia, M., Neumann, G., Sepúlveda, S. and Tchernitchin, A. N. 1984. Progesterone interaction with eosinophils and with responses already induced by oestrogen in the uterus. *J. Endocrinol.* **102**: 295–303. [Medline] [CrossRef]
6. Ireland, J. J., Murphee, R. L. and Coulson, P. B. 1980. Accuracy of predicting stage of bovine estrous cycle by gross appearance of the corpus luteum. *J. Dairy Sci.* **63**: 155–160. [Medline] [CrossRef]
7. Kroegel, C., Virchow, J. C. Jr., Luttmann, W., Walker, C. and Warner, J. A. 1994. Pulmonary immune cells in health and disease: the eosinophil leucocyte (Part I). *Eur. Respir. J.* **7**: 519–543. [Medline] [CrossRef]
8. Luna, L.G. 1968. Manual of Histologic Staining Methods of the Armed Forces, Institute of Pathology, 3rd ed., McGraw-Hill, New York.
9. Maltby, S., Wohlfarth, C., Gold, M., Zbytnuik, L., Hughes, M. R. and McNagny, K. M. 2010. CD34 is required for infiltration of eosinophils into the colon and pathology associated with DSS-induced ulcerative colitis. *Am. J. Pathol.* **177**: 1244–1254. [Medline] [CrossRef]
10. Miyamoto, A. and Schams, D. 1991. Oxytocin stimulates progesterone release from microdialyzed bovine corpus luteum in vitro. *Biol. Reprod.* **44**: 1163–1170. [Medline] [CrossRef]
11. Ramos, J. G., Varayoud, J., Kass, L., Rodriguez, H., Muñoz de Toro, M., Montes, G. S. and Luque, E. H. 2000. Estrogen and progesterone modulation of eosinophilic infiltration of the rat uterine cervix. *Steroids* **65**: 409–414. [Medline] [CrossRef]
12. Sanderson, C. J. 1992. Interleukin 5, eosinophils and disease. *Blood* **79**: 3101–3109. [Medline]
13. Schubert, H. J., Taylor, U., Zerbe, H., Webreski, D., Hunter, R. and Rath, D. 2008. Immunological responses to semen in the female genital tract. *Theriogenology* **70**: 1174–1181. [Medline] [CrossRef]
14. Hogan, S. P., Rosenberg, H. F., Moqbel, R., Phipps, S., Foster, P. S., Lacy, P., Kay, A. B. and Rothenberg, M. E. 2008. Eosinophils: Biological properties and role in health and disease. *Clin. Exp. Allergy* **38**: 709–750. [Medline] [CrossRef]
15. Suarez, S. S. and Pacey, A. A. 2006. Sperm transport in the female reproductive tract. *Hum. Reprod. Update* **12**: 23–37. [Medline] [CrossRef]
16. Tchernitchin, A., Roorijck, J., Tchernitchin, X., Vandenhende, J. and Gland, P. 1974. Dramatic early increase in uterine eosinophils after oestrogen administration. *Nature* **248**: 142–143. [Medline] [CrossRef]
17. Valle, G. R., Castro, A. C. S., Nogueira, J. C., Caliari, M. V., Graca, D. S. and Nascimento, E. F. 2009. Eosinophils and mast cells in the oviduct of heifers under natural and superovulated estrous cycles. *Anim. Reprod.* **6**: 386–391.
18. Wijayagunawardane, M. P. B. and Miyamoto, A. 2004. Tumor necrosis factor  $\alpha$  system in the bovine oviduct: A possible mechanism for embryo transport. *J. Reprod. Dev.* **50**: 57–62. [Medline] [CrossRef]
19. Wijayagunawardane, M. P. B., Miyamoto, A., Cerbito, W. A., Acosta, T. J., Takagi, M. and Sato, K. 1998. Local distributions of oviductal estradiol, progesterone, prostaglandins, oxytocin and endothelin-1 in the cow. *Theriogenology* **49**: 607–618. [Medline] [CrossRef]
20. Yoshino, O., Osuga, Y., Koga, K., Hirota, Y., Yano, T., Tsutsumi, O., Fujimoto, A., Kugu, K., Momoeda, M. and Fujiwara, T. 2003. Upregulation of interleukin-8 by hypoxia in human ovaries. *Am. J. Reprod. Immunol.* **50**: 286–290. [Medline] [CrossRef]