

Available online at www.sciencedirect.com

ScienceDirect

journal homepage: www.elsevier.com/locate/ihj

Case Report

Biventricular thrombi complicating acute myocardial infarction

Sanjeev Sanghvi^a, Anil Baroopal^{b,*}, Pawan Sarada^c^a Senior Professor and Head of Department, Department of Cardiology, Dr. S.N. Medical College, Jodhpur, Rajasthan, India^b Senior Resident, Department of Cardiology, Dr. S.N. Medical College, Jodhpur, Rajasthan, India^c Assistant Professor, Department of Cardiology, Dr. S.N. Medical College, Jodhpur, Rajasthan, India

ARTICLE INFO

Article history:

Received 4 January 2016

Accepted 24 February 2016

Available online 9 March 2016

Keywords:

Acute myocardial infarction

Biventricular thrombi

Echocardiography

ABSTRACT

A rare case of biventricular thrombi complicating acute myocardial infarction detected during echocardiography is described.

© 2016 Cardiological Society of India. Published by Elsevier B.V. This is an open access article under the CC BY-NC-ND license (<http://creativecommons.org/licenses/by-nc-nd/4.0/>).

1. Introduction

Ventricular thrombus, a potentially life-threatening condition, can complicate acute myocardial infarction. The detection of biventricular mural thrombi is rare during routine echocardiography, although this imaging modality is a valuable tool for their diagnosis.

2. Case report

A 34-year-old male was admitted with complaints of shortness of breath and sub-sternal chest pain for three days. He had no conventional risk factors such as family history of coronary

artery disease, smoking, diabetes mellitus, hyperlipidemia, and hypertension. On examination, his pulse was 66/min and blood pressure was 100/70 mm of mercury. A third heart sound was audible at apex and crepitations were heard over both lower lung fields but edema feet were absent. Laboratory finding revealed neutrophilic leucocytosis with total platelet count of 252,000/ μ L, normal liver function test, normal renal function test, serum T3 level of 111.54 ng/dl, serum T4 level of 8.65 μ g/dl, serum TSH level of 3.54 μ IU/ml, serum homocysteine level of 8.96 μ mol/L (normal range 5.46–16.20 μ mol/L), high sensitivity C reactive protein level of 24.7 mg/L, IgM antiphospholipid antibody level in serum of 3.2 U/ml (normal range <12 U/ml), IgM cardiolipin antibody level in serum of 0.88 U/ml (normal <12 U/ml), IgG cardiolipin antibody level in serum of 2.4 U/ml (normal <12 U/ml), negative IFA, HEP-2 antinuclear

* Corresponding author.

E-mail address: anisabarupal@yahoo.com (A. Baroopal).<http://dx.doi.org/10.1016/j.ihj.2016.02.020>0019-4832/© 2016 Cardiological Society of India. Published by Elsevier B.V. This is an open access article under the CC BY-NC-ND license (<http://creativecommons.org/licenses/by-nc-nd/4.0/>).

antibody (ANA), and absent lupus anticoagulant. The electrocardiogram revealed ST segment elevation in II, III and aVF and ST segment depression in V₄, V₅, and V₆ with normal QT interval. Echocardiogram was performed which revealed right ventricular hypokinesia, global left ventricular hypokinesia more in inferior wall, trivial tricuspid regurgitation, mild mitral regurgitation, and severe left ventricular systolic dysfunction with left ventricular ejection fraction of 20%. Diagnosis of acute right ventricular and inferior wall myocardial infarction was made but thrombolytic therapy was not given due to delayed presentation and the patient was managed conservatively along with enoxaparin in therapeutic dose of 1 mg/kg subcutaneously twice a day. As the patient was in left ventricular failure, a repeat echocardiogram was performed after two days which revealed global hypokinesia more in inferior wall with left ventricular ejection fraction of 20% along with biventricular thrombi of size 34 mm × 24 mm in left ventricle and 26 mm × 16 mm thrombus in right ventricle. Both thrombi were highly echogenic, acoustically distinct from underlying myocardium, immobile as shown in apical four-chamber view (Fig. 1) and in Movie. Enoxaparin was then bridged to nicoumalone oral anticoagulant. The patient refused for intervention and was discharged after seven days with target international normalized ratio (INR) between 2 and 3. The patient was reviewed after three weeks with marked improvement in general condition. A repeat echocardiogram was performed which revealed normal right ventricular function, hypokinesia in inferior wall, improved left ventricular function with left ventricular ejection fraction of 30%, and complete resolution of both left ventricular and right ventricular thrombi as shown in apical four chamber view (Fig. 2). Then the patient underwent coronary angiography, which revealed single vessel disease with 80% mid right coronary artery lesion. The patient refused for angioplasty and discharged on drug treatment.

Supplementary Movie related to this article can be found, in the online version, at [doi:10.1016/j.ihj.2016.02.020](https://doi.org/10.1016/j.ihj.2016.02.020).

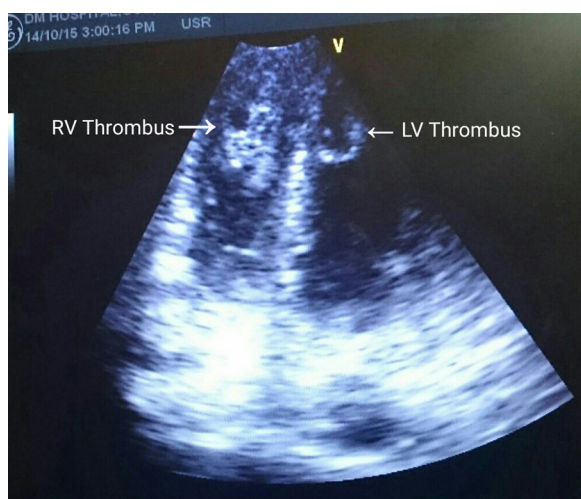


Fig. 1 – Two-dimensional transthoracic echocardiographic apical four-chamber view showing biventricular thrombi.

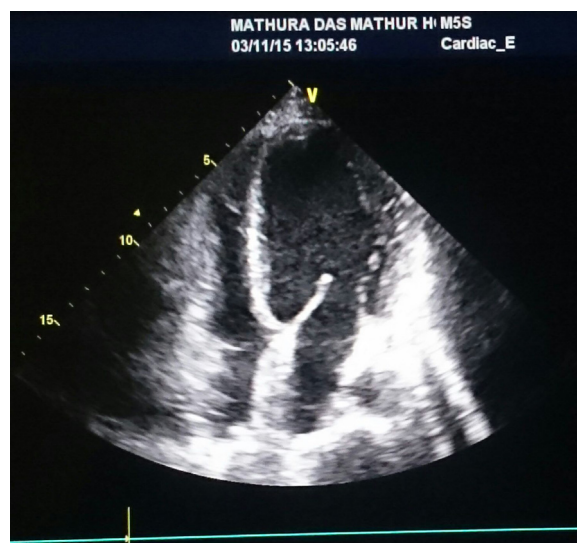


Fig. 2 – Two-dimensional transthoracic echocardiographic apical four-chamber view after resolution of biventricular thrombi.

3. Discussion

Isolated left ventricular or right ventricular thrombus formation is a well-described complication of acute myocardial infarction. Biventricular thrombi complicating acute myocardial infarction are rare and Friedman et al.¹ for the first time reported the presence of biventricular thrombi on echocardiography following acute myocardial infarction. In view of the diagnostic uncertainty, Keeble et al.² demonstrated biventricular apical thrombi by contrast-enhanced cardiac MRI following anteroapical STEMI and unsuccessful reperfusion therapy. Biventricular thrombi are generally seen in patients with a pro thrombotic state like anti-phospholipid antibody syndrome, heparin induced thrombocytopenia induced thrombosis, hypereosinophilic syndrome.³ Cases of biventricular thrombi in association with peripartum cardiomyopathy,^{4,5} nonischemic cardiomyopathy,³ dilated cardiomyopathy,⁶ myocarditis,^{7,8} and human immunodeficiency virus infection induced dilated cardiomyopathy⁹ were reported. The proposed mechanism responsible for global hypokinesia of left ventricle in our case was myocardial stunning “the transient left ventricular dysfunction that persists after reperfusion, despite the absence of irreversible damage and despite restoration of normal or near-normal coronary flow”.^{10,11} The RCA was superdominant in this patient. We speculate that in the present case, blood stasis due to severe biventricular dysfunction leads to the formation of biventricular thrombi. Furthermore, the thrombi resolved after three weeks of adequate anticoagulation with improved biventricular function. Daily careful echocardiographic evaluation is beneficial in management of acute myocardial infarction till discharge of the patient, as we did in our patient.

Conflicts of interest

The authors have none to declare.

REFERENCES

1. Friedman HZ, Buda AJ. Biventricular thrombus formation in association with acute myocardial infarction: diagnosis by two-dimensional echocardiography. *J Clin Ultrasound*. 1986;14:315-318.
2. Keeble W, Vondermuhll I, Paterson I. Biventricular apical thrombi demonstrated by contrast-enhanced cardiac MRI following anteroapical STEMI and unsuccessful reperfusion therapy. *Can J Cardiol*. 2008;24:e51-e53.
3. Adnan MM, Hashmi S. Biventricular thrombi of nonischemic cardiomyopathy. *Pan Afr Med J*. 2014;17:210.
4. Kim D-Y, Islam S, Mondal NT, Mussell F, Rauchholz M. Biventricular thrombi associated with peripartum cardiomyopathy. *J Health Popul Nutr*. 2011;29:178-180.
5. Nishi I, Ishimitsu T, Ishizu T, et al. Peripartum cardiomyopathy and biventricular thrombi. *Circ J*. 2002;66:863-865.
6. Jariwala P. Biventricular mural thrombi in patients with dilated cardiomyopathies: case reports and review. *Arch Cardiovasc Imaging*. 2014;2:e31986.
7. Thuny F, Avierinos J-F, Jop B, et al. Massive biventricular thrombosis as a consequence of myocarditis findings from 2-dimensional and real-time 3-dimensional echocardiography. *Circulation*. 2006;113:e932-e933.
8. Kaçık M, Yesin M, Gursoy MO, Ocal L, Cerşit S, Ozkan M. Biventricular and left atrial free floating thrombi in a patient diagnosed with fulminant myocarditis managed with thrombectomy and left ventricular assist device implantation. *J Cardiovasc Dis Diagn*. 2014;2:168.
9. Nkoke C, Kuate LM, Luchuo EB, Edie SD, Boombhi J, Menanga A. Biventricular thrombi in dilated cardiomyopathy in a patient with human immunodeficiency virus infection: a case report. *BMC Res Notes*. 2015;8:168.
10. Ferrari R, Ceconi C, Curello S, Benigno M, La Canna G, Visioli O. Left ventricular dysfunction due to the new ischemic outcomes: stunning and hibernation. *J Cardiovasc Pharmacol*. 1996;28:S18-S26.
11. Sakata K, Yoshida H, Ono N, et al. A clinical feature of myocardial stunning associated with acute myocardial infarction. *Ann Nucl Med*. 1994;8:153-157.