



Natural History and Clinical Manifestation of Pediatric Brain Arteriovenous Malformations

Adikarige Haritha Dulanka Silva,^{1,2} Greg James^{1,2}

Department of Neurosurgery,¹ Great Ormond Street Hospital for Children, London, UK
Great Ormond Street Institute of Child Health,² University College London, London, UK

Brain arteriovenous malformations (bAVMs) are aberrant arteriovenous shunts through a vascular nidus with no intervening capillary beds. They are one of the commonest causes of spontaneous intracranial haemorrhage in children and may be associated with significant morbidity and mortality in cases of rupture. Treatment strategies include microsurgical resection, endovascular embolisation, stereotactic radiosurgery, multimodality treatment with a combination thereof, and particularly in high-grade bAVMs, conservative management. Clinicians involved in treating bAVMs need to have familiarity with the natural history pertaining to bAVMs in terms of risk of rupture, risk factors elevating rupture risk as well as understanding the clinical manifestations of bAVMs. This invited review serves to provide a synthesis on natural history and clinical presentation of bAVMs with particular focus in children to inform decision-making pertaining to management.

Key Words : Arteriovenous malformations · Brain arteriovenous malformation · Haemorrhage · Natural history · Rupture.

INTRODUCTION

Brain arteriovenous malformations (bAVMs) are aberrant arteriovenous shunts through a vascular nidus with no intervening capillary beds^{8,14,56} and are rare with an incidence of one in 100000 people^{19,51} and prevalence of 10 per 100000 adults⁴⁹. This prevalence rate is reported to be higher in children (14–28 per 100000 children⁴³) with 3–20% of all AVMs occurring in this population⁷. Most commonly presenting with intracranial haemorrhage, their prevalence is increasing due to incidental discovery from widespread use of neuroradiology^{1,21}. Other manifestations include seizures, focal neurological deficits and headache⁵ (independent of cerebral haemorrhage). Rarely,

bAVMs can present with cardiac failure or hydrocephalus, particularly in neonates and infants, akin to pial arteriovenous fistulae (AVF) and vein of Galen aneurysmal malformations (VGAMs)²⁷.

Rupture and haemorrhage can be associated with significant mortality (10–30%)^{4,10} and neurological disability (20–40%)^{8,53}. Mortality rates in children are often thought to be higher (25%) in comparison to adults (6–10%)⁴⁰. Most physicians would recommend definitive treatment following bAVM presentation with haemorrhage/rupture^{4,12,23,26,50,54} but optimal management of unruptured bAVMs has been controversial since the ARUBA (A Randomised trial of Unruptured Brain Arteriovenous Malformations) study^{37,38}. Treatment

• Received : February 14, 2024 • Revised : April 4, 2024 • Accepted : April 16, 2024

• Address for correspondence : **Adikarige Haritha Dulanka Silva**

Department of Neurosurgery, Great Ormond Street Hospital for Children, Great Ormond Street, London WC1N 3JH, UK
Tel : +44-7919255483, E-mail : Dulanka.Silva@gosh.nhs.uk, ORCID : <https://orcid.org/0000-0001-5664-5615>

This is an Open Access article distributed under the terms of the Creative Commons Attribution Non-Commercial License (<http://creativecommons.org/licenses/by-nc/4.0>) which permits unrestricted non-commercial use, distribution, and reproduction in any medium, provided the original work is properly cited.

strategies to bAVM include microsurgical resection, endovascular embolisation, stereotactic radiosurgery, multimodality treatment with a combination thereof and (particularly in cases of high-grade bAVMs) and conservative management^{1,21,46}. This article serves to review the natural history of bAVMs and their clinical presentation to inform decision-making on management.

NATURAL HISTORY

A synthesis of current bAVM natural history data is critical in caring for these patients, informing treating clinicians to improve counselling of patients with regard to management options. The most pertinent question is whether or not the bAVM is unruptured or has ruptured with intracranial haemorrhage¹⁴. For many years, bAVMs were generally considered to carry a bleeding risk of ~2% per year for asymptomatic lesions and ~4% per year for symptomatic lesions. The data from which these estimates have been extrapolated are now often felt to be limited, based on a combination of retrospective and prospective studies (sometimes without clear distinction between symptomatic and asymptomatic bAVMs) and with some studies performed in the pre-magnetic resonance imaging (MRI) era¹¹. More recently, Stapf and colleagues⁵⁰ reported a 1.3% per year rate of haemorrhage in unruptured bAVMs and 5.9% in those that presented with haemorrhage. ARUBA trial data with

median follow-up of 33-month found the haemorrhage rate for unruptured bAVMs at around 2.2% per year³⁸.

Risk factors for haemorrhage from an unruptured bAVM

Various studies have sought to identify which combinations of patient and bAVM morphological and anatomical factors are most closely related to an elevated risk of future haemorrhage^{46,50} (Table 1). The risk factors postulated to be associated with highest risk of bleeding appear to be previous rupture and haemorrhage, deep bAVM location or brainstem location, and exclusively deep venous drainage, with rates varying from 0.9% for unruptured bAVMs without a single risk factor to 34.4% for those with all three risk factors⁵⁰. Other factors include the presence of a cerebral aneurysm on a feeding artery and restriction of venous drainage from the malformation²² (narrowing or occlusion of one or more principal draining veins). The latter is associated with the highest risk when the malformation has only a single draining vein⁴⁴.

Risk factors in paediatric patients

In a retrospective review of 46 children, Reitz identified small bAVM size and exclusive deep venous drainage as independent risk factors for haemorrhage⁴³. This was corroborated in another study evaluating 130 patients from two high volume centres with infratentorial location being an additional risk factor¹⁸. Another retrospective review of 85 patients con-

Table 1. Risk factors postulated to be associated with increasing haemorrhage rates in unruptured bAVM

	Value
3 key factors associated with elevated risk of haemorrhage from unruptured bAVM	
Previous rupture/haemorrhage	HR, 3.2; 95% CI, 2.1–4.3
Deep location or brainstem	HR, 2.4; 95% CI, 1.4–3.4
Exclusively deep venous drainage	HR, 2.4; 95% CI, 1.1–3.8
Modelling based on above 3 factors	
No. of risk factors	0, 1, 2, 3
Annual risk of haemorrhage	<1%, 3–5%, 8–15%, >30%
Risk	Very low, low, moderate, high
Other postulated factors	
Cerebral aneurysm on feeding artery	HR, 1.8; 95% CI, 1.6–2
Restriction of venous drainage from malformation	This factor was associated with the highest risk in circumstances where the malformation had a single draining vein

bAVM : brain arteriovenous malformation, HR : hazard ratio, CI : confidence interval

firmed the impact of pattern and number of draining veins with single draining vein and deep venous drainage all associated with higher risk of haemorrhage and worsening outcomes³¹. bAVM associated aneurysms (pre-nidal flow related, intra-nidal, venous) were reported in 16–29% of paediatric bAVMs. In a review of 77 children, it was a risk factor associated with haemorrhage in univariate analysis but not in multivariate analysis². Hoffman and colleagues²⁹, however in a smaller review of 30 patients noted that haemorrhage rates appeared to be similar with or without aneurysms but that emergent treatment was often required more when patients presented with associated aneurysms. In general however, previous haemorrhage does appear to remain the most significant risk factor in children for re-haemorrhage, especially in the first year in adults, but this risk may appear to be longer in children^{3,40}.

Calculating cumulative life risk of haemorrhage and rupture

It would be reasonable to estimate a realistic rate of haemorrhage for an unruptured bAVM without significant risk factors of 1–2% per year and this is mirrored in the America Stroke Association (AHA) guidelines with a synthesis of a combination of pooled patient cohort data, meta-analysis, review article and a randomised control trial¹⁴. Risk of haemorrhage in a previously ruptured bAVM is estimated at 4.5–4.8% per year.

To guide cumulative risk over a lifetime with regard to rupture and haemorrhage, a number of formulae have been proposed: Lifetime cumulative risk of rupture = $1 - (1 - R)^L$; R, yearly risk of rupture; L, years of life at risk (life expectancy).

This formula does rely on assumptions that the yearly risk of haemorrhage remains constant every year and that the risk in any year is independent of the risk in any other year³². A simpler calculation assuming an annual risk of haemorrhage of 3% per year is 105-age (years).

With a potential morbidity rate of 33% per haemorrhage (30-day rate of moderate to severe disability with Rankin 3–5)⁹, even utilising the lowest annual rupture rate (0.9% per year), this results to a very significant lifetime risk of rupture in children with a cumulative risk of morbidity and mortality among children over time^{13,47}.

Timing of treatment

Timing of definitive management of bAVM following haemorrhagic presentation is not standardised in the cerebrovascular community. Hyperacute surgery has advantages of treating the life-threatening intracranial pressure (ICP) complications, early definitive treatment of the bAVM with an immediate reduction in risk of re-haemorrhage, as well as the concept of ‘operating within the neurological deficit attributed to the haemorrhage’. The disadvantage is difficult operative conditions with secondary cerebral oedema and a risk of incomplete obliteration of bAVM due to concealment of the true morphology of the bAVM and vessels and an accurate understanding of its anatomical features.

In a cohort of 102 patients with ruptured bAVMs where the bAVM was definitively treated at least 4-week post haemorrhage⁴, the risk of re-haemorrhage was felt to be <1%. The authors therefore supported this paradigm of delaying definitive treatment of a ruptured bAVM for at least 4-week post-haemorrhage with the attendant advantages of reduced cerebral oedema, better visualisation of compressed vessels, more accurate anatomical delineation of the bAVM, superior operative conditions and lower risk of incomplete obliteration and residual bAVM outweighing the <1% risk of re-haemorrhage and its associated morbidity. This was only modified when a high-risk feature such as an associated intracranial aneurysm (IA) was identified where the re-haemorrhage rate was calculated at 11.4% per patient-month.

A larger more recent study assessed via a propensity score-matched analysis, timing of microsurgical resection in 195 pairs of ruptured bAVMs with early (<30 days) or delayed (>30 days) resection following haemorrhage⁵⁶. Short term neurological outcomes were better in the delayed resection group but there was no difference in long-term neurological outcomes, and favourable outcome and long-term disability were similar across both groups. Post-operative seizure, length of hospital stay and post-operative haemorrhage were similar across both groups. Delayed surgery however had a significantly better complete obliteration rate compared to early resection (99% vs. 91.3%; $p=0.001$).

These studies very much reflect the authors’ own personal paradigm where definitive treatment of a ruptured bAVM is performed in delayed fashion usually at least 6-weeks following haemorrhage. This allows more favourable microsurgical conditions, favourable planes of dissection, reduced complica-

tions with cerebral oedema, better delineation of bAVM angiographic morphology and therefore more accurate bAVM grading and risk stratification to design an optimal management strategy to achieve a higher possibility of complete obliteration (Fig. 1). Surgical treatment is primarily geared towards control of ICP complications and if surgical evacuation of intracranial haemorrhage is required, it should be tailored only

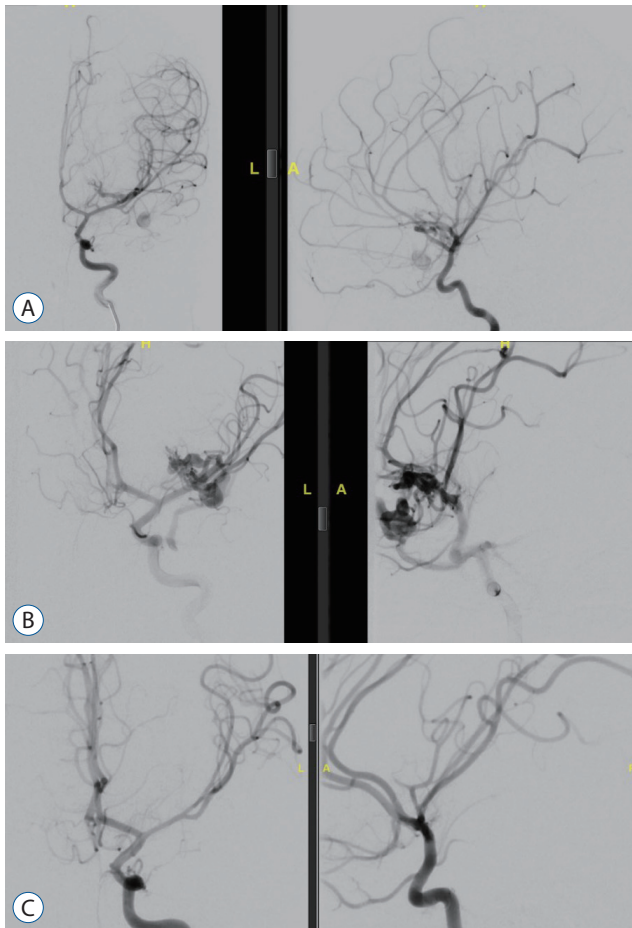


Fig. 1. Example of surgical treatment of brain arteriovenous malformation (bAVM) in a small child. Antero-posterior and lateral cerebral angiographic images of an 18-month-old girl with left deep, Sylvian/Antero-Insular bAVM rupture with haemorrhage. A : Demonstrates the initial angiographic pictures with intracerebral haemorrhage within the sylvian fissure and frontal parenchyma clearly compressing some of the nidus. B : Demonstrates the angiographic pictures performed 8-week following rupture which demonstrate the true morphology of the bAVM and its complexity. C : Demonstrates the post-operative angiographic pictures following microsurgical resection of the bAVM with complete obliteration and no residual arteriovenous shunting with preservation of all en-passant vasculature. The patient has made an excellent recovery with only persistent mild right upper limb paresis (sequela of the original intracranial haemorrhage) with no recurrence in 2-year follow-up. L : left, A : anterior.

to removal of haematoma and acute bleeding control. This is also supported by the AHA guidelines on management of bAVMs where small superficial bAVMs can be considered for removal during emergency surgery but resection of larger, deep bAVMs should be deferred for a period of 2 to 6 weeks at least¹⁴⁾, owing to the greater likelihood of neurological morbidity and mortality associated with immediate removal of a ruptured bAVM. High risk features for recurrence haemorrhage such as perinidal or intranidal aneurysms should be addressed immediately, most commonly by endovascular or rarely by surgical means in lieu of complete resection¹⁴⁾.

CLINICAL MANIFESTATIONS OF UNRUPTURED BAVM IN CHILDREN

The traditional conception of bAVM presentation is that they are clinically silent lesions until rupture – often described as a ‘ticking timebomb’. However, our experience is that, in children who harbour an unruptured bAVM, careful clinical, ophthalmological and radiological evaluation can often reveal symptomatic manifestations – perhaps not surprising when the large size and torrential blood flow of these lesions are considered.

Headache

Migraine headache is postulated to have a vascular aetiology and it is therefore unsurprising that bAVM has been recognised as a potential cause. It has been noted that migrainous cephalgia is often ipsilateral to radiological bAVM²⁵⁾. Interestingly, it appears that an occipital location for bAVM is particularly associated with headaches^{17,33,39)}. We have observed similar phenomena in our paediatric patients – Fig. 2 describes a 14-year-old girl who presented with intractable migraine-like headache ipsilateral to an unruptured parieto-occipital bAVM whose headaches resolved after microsurgical resection. Involvement of a paediatric neurologist with an interest in headache in the paediatric neurovascular service is very helpful when dealing with such patients.

Papilloedema

Papilloedema – pathological swelling of the optic nerve head due to intracranial hypertension – is an important ophthalmological condition which is untreated can lead to optic neuropathy

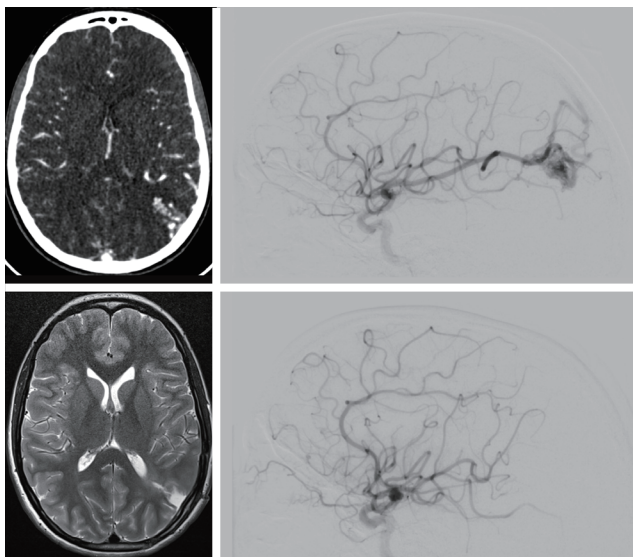


Fig. 2. Migrainous headache and unruptured brain arteriovenous malformation (bAVM). A 13-year-old girl presented to her paediatrician with intractable migraine headache, always on the left side of the head. computed tomography angiography and angiogram (pre-operative) demonstrated a left parieto-occipital bAVM, unruptured. Due to the symptoms the child and her family elected for craniotomy and resection, which achieved cure (post-operative). Her headaches resolved completely, and she is now studying nursing.

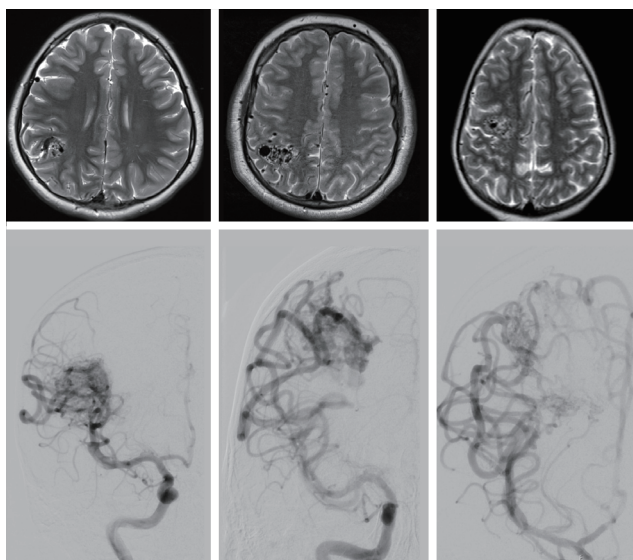


Fig. 3. Large brain arteriovenous malformation (bAVM) may cause papilloedema. In all three illustrated cases, the initial symptom triggering the magnetic resonance imaging scan and angiogram was detection of papilloedema on routine optometry. Interestingly, all were large, right hemisphere unruptured bAVM. Cases 1 and 2 were treated with microsurgical resection, case 3 was treated with stereotactic radiosurgery. In all three cases, the optic nerve swelling resolved after bAVM treatment.

thy and visual failure. Papilloedema has been rarely reported as a sequela of unruptured bAVM in children²⁰), however we have observed it in three of our patients – all teenagers with large unruptured parietal bAVMs (Fig. 3). The pathophysiology is presumably related to chronic venous hypertension due to intracranial arterio-venous shunting. In all three of our patients, the papilloedema resolved after surgical or radiosurgical treatment of the bAVM. We recommend baseline ophthalmology assessments for all children presenting with bAVM.

Vascular steal

Large bAVMs may shunt blood preferentially through the nidus resulting in vascular ‘steal’ of blood from eloquent brain regions – resulting in clinical symptoms and even radiological volume loss. This is a controversial concept, but seems to be more accepted as a phenomenon in children with bAVM than with adults, perhaps due to the relationship to the developing brain^{35,36,45}. We have seen several cases of children presenting with progressive lateralised neurological deficits, even developing white matter loss radiologically, as a result of often large, deep bAVM (Fig. 4). Treatment in these children is challenging, as surgical resection is often not feasible due to the high-grade nature of the bAVM. Consideration of haemodynamic augmentation (e.g., aspirin, hydration or even pial synangiosis) may be necessary and requires careful evaluation and discussion in a multi-disciplinary setting.

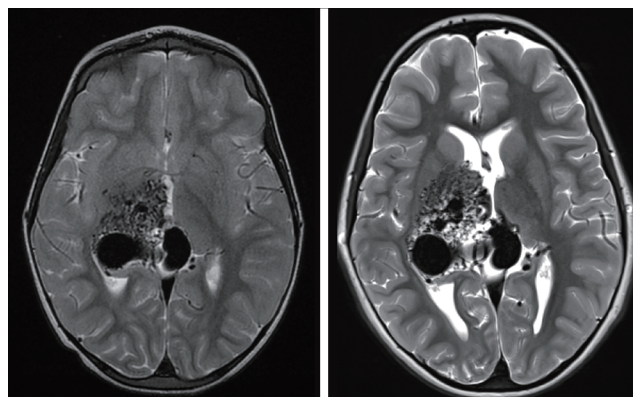


Fig. 4. Large, deep brain arteriovenous malformation (bAVM) causing progressive neurological deterioration. A 7-year-old boy presented with a high flow unruptured thalamic bAVM. The scan was performed due to gradual left hemiparesis. Staged stereotactic radiosurgery was offered but the family declined. At 5 years follow-up the hemiparesis had progressed clinically and there is evidence of white matter volume loss.

SYNDROMIC BAVM

Most bAVM encountered in paediatric neurosurgical practice will be sporadic, however a proportion are recognised to have an underlying genetic cause. The most important currently recognised conditions are hereditary hemorrhagic telangiectasia (HHT) and capillary malformation-arteriovenous malformation syndrome (CM-AVM). Patients with syndromic bAVM will often have other cutaneous or clinical features and our evaluation of all paediatric bAVM patients includes asking about epistaxis or gastro-intestinal haemorrhage and examination of the skin for birthmarks or capillary malformations. If syndromic bAVM is suspected, referral to a clinical geneticist for further testing is recommended. Routine genetic testing should include testing for mutations in endoglin (ENG) and activin receptor-like kinase 1 (ACVRL1; HHT type 1 and type 2 respectively), suppressor of mothers against decapentaplegic (SMAD4; juvenile polyposis/HHT) as well as Ras p21 protein activator 1 (RASA1; CM-AVM type 1).

As well as being useful information for screening of family members and for family planning, the genetic diagnosis informs the phenotype and natural history in bAVM. RASA1 mutation (CM-AVM type 1), for instance, is associated with a higher rate of spinal AVM and radiological follow up of these children should include MRI of the spine^{41,52}.

In the case of HHT, there is some evidence that bAVMs are more likely to be multiple, but that the rupture risk is perhaps lower⁵⁵, leading some to recommend conservative management in this group. It is important to remember that these children may also have pulmonary AVMs – which can lead to complications in the peri-operative period. Screening is recommended.

DISCUSSION

Recommendations for intervention in children

Risks associated with treatment of bAVMs must be balanced against the risks associated with no treatment⁴⁶. The goal of treatment with bAVM is preservation of neurological function, with complete elimination of the bAVM. In the context of ruptured bAVMs, besides emergency life-saving and ICP measures, most physicians would recommend definitive treatment to prevent re-haemorrhage and its associated mor-

bidity and mortality²³.

Treatment of unruptured bAVMs has garnered significant controversy following publication of results of ARUBA, a multicentre randomised trial of treatment versus medical observation of bAVMs in adults^{37,38}. A significant risk of stroke and death was associated with intervention led to early termination of the trial with superiority of observation demonstrated. A number of criticisms²³ of this trial include 1) lack of defined subgroup analyses with data not analysed according to the type of intervention, patient specific factors that predict risk associated with an intervention, or the anticipated risk of rupture on the basis of the characteristics of the lesion⁴⁴; 2) the trial did not address surgical outcome for patients with Spetzler-Martin (SM) grade 1 and 2 bAVMs who are the best candidates for surgery^{6,48}; 3) mean follow-up was only 33 months, a period too brief to assess long-term risk of rupture or complete therapeutic effects of radiosurgery; 4) high percentage of partially treated cases; and 5) outcomes of different but aggregated management options did not align with either results of previous retrospective studies or experience reported by neurovascular specialists that regular treat unruptured bAVMs^{8,28,30,34,42}.

A more recent study also identified an increased in incidence of ruptured bAVM since 2014 (13.3% vs. 34.4%; $p < 0.001$) as well as rates of in-hospital mortality (2% vs. 7.6%; $p < 0.001$) and multivariable regression analysis noted that the post-ARUBA trial era was independently associated with both bAVM rupture and in-hospital mortality and hypothesised to be reflective of a paradigm shift to conservative and non-interventional management strategies in patients with unruptured bAVM post-ARUBA¹⁵.

A recent single-centre study assessed outcome of 107 conservatively managed unruptured bAVMs in adults that were comparable to the patients in the medical management arm of the ARUBA study and noted an overall annual haemorrhage risk of 2.7% in the observation of period with 17% of patients having at least one haemorrhage¹⁶. The cumulative 1-, 5-, and 10-year overall haemorrhage rates were 3%, 11.3%, and 15.3% respectively with a long-term follow-up related mortality of 8% (compared to ARUBA's 0% mortality rate) and was felt to reflect a real-life cohort and to be an unacceptable mortality rate among conservatively managed bAVMs. The authors supported active treatment options recommended to patients with unruptured bAVMs taking into consideration lesion-

specific risk factors and identifying predictors for bAVM rupture to facilitate patient selection for active treatment.

Several factors support treatment of unruptured bAVM in children including : 1) very high lifetime risk of rupture with associated morbidity/mortality taking into consideration all formulae and rupture risk; 2) higher mortality from bAVM rupture in children; 3) higher plasticity and regenerative capacity of paediatric cerebral vasculature⁷; 4) results of ARUBA have no relevance to treatment of children, as they were excluded from the trial and the length of follow-up was too short to be of any utility in children²⁴; and 5) currently there are no randomised trials in the paediatric literature supportive conservative bAVM management.

In the authors' institution, each bAVM is assessed by a specialist neurovascular multidisciplinary team consisting of two specialist paediatric neurovascular neurosurgeons (AHDS/GJ), three paediatric neurovascular neurologists and two paediatric neurointerventional neuroradiologists and management decisions made on a case-by-case basis.

CONCLUSION

Average risk of rupture for an asymptomatic bAVM without significant angiographic risk factors for haemorrhage is probably 1–2% per year. Although many bAVM and patient factors have been associated, a history of prior haemorrhage has consistently and reliably been shown to be the strongest predictor of future haemorrhage. Cumulative risk of rupture and haemorrhage for a patient can be estimated utilising the equation $1 - (1 - R)^t$ or more simply 105-age (estimates utilising this formula closely resemble an annual rupture rate of 3%). Definitive treatment of ruptured bAVM is strongly recommended. Treatment of unruptured bAVM is controversial but excellent outcomes have been demonstrated in high volume centres with multidisciplinary neurovascular expertise and should be strongly considered in children owing to a significant lifetime risk of rupture and its associated morbidity and mortality.

AUTHOR'S DECLARATION

Conflicts of interest

No potential conflict of interest relevant to this article was

reported.

Informed consent

This type of study does not require informed consent.

Author contributions

Conceptualization : AHDS, GJ; Data curation : AHDS, GJ; Formal analysis : AHDS, GJ; Funding acquisition : AHDS, GJ; Methodology : AHDS, GJ; Project administration : AHDS, GJ; Visualization : AHDS, GJ; Writing - original draft : AHDS, GJ; Writing - review & editing : AHDS, GJ

Data sharing

None

Preprint

None

ORCID

Adikarige Haritha Dulanka Silva

<https://orcid.org/0000-0001-5664-5615>

Greg James

<https://orcid.org/0000-0003-3014-7428>

References

1. Abecassis JJ, Xu DS, Batjer HH, Bendok BR : Natural history of brain arteriovenous malformations: a systematic review. **Neurosurg Focus** 37 : E7, 2014
2. Anderson RC, McDowell MM, Kellner CP, Appelboom G, Bruce SS, Kotchetkov IS, et al. : Arteriovenous malformation-associated aneurysms in the pediatric population. **J Neurosurg Pediatr** 9 : 11-16, 2012
3. Aoun SG, Bendok BR, Batjer HH : Acute management of ruptured arteriovenous malformations and dural arteriovenous fistulas. **Neurosurg Clin N Am** 23 : 87-103, 2012
4. Beecher JS, Lyon K, Ban VS, Vance A, McDougall CM, Whitworth LA, et al. : Delayed treatment of ruptured brain AVMs: is it ok to wait? **J Neurosurg** 128 : 999-1005, 2018
5. Berman MF, Sciacca RR, Pile-Spellman J, Stapf C, Connolly ES Jr, Mohr JP, et al. : The epidemiology of brain arteriovenous malformations. **Neurosurgery** 47 : 389-396; discussion 397, 2000
6. Bervini D, Morgan MK, Ritson EA, Heller G : Surgery for unruptured arteriovenous malformations of the brain is better than conservative management for selected cases: a prospective cohort study. **J Neurosurg** 121 : 878-890, 2014

7. Bristol RE, Albuquerque FC, Spetzler RF, Rekate HL, McDougall CG, Zabramski JM : Surgical management of arteriovenous malformations in children. **J Neurosurg** **105(2 Suppl)** : 88-93, 2006
8. Chen CJ, Ding D, Derdeyn CP, Lanzino G, Friedlander RM, Southerland AM, et al. : Brain arteriovenous malformations: a review of natural history, pathobiology, and interventions. **Neurology** **95** : 917-927, 2020
9. Choi JH, Mast H, Sciacca RR, Hartmann A, Khaw AV, Mohr JP, et al. : Clinical outcome after first and recurrent hemorrhage in patients with untreated brain arteriovenous malformation. **Stroke** **37** : 1243-1247, 2006
10. Choi JH, Mohr JP : Brain arteriovenous malformations in adults. **Lancet Neurol** **4** : 299-308, 2005
11. Cockroft KM : Natural history of brain arteriovenous malformations in Harbaugh RE, Shaffrey C, Couldwell WT, Berger MS (eds) : **Neurosurgery Knowledge Update: A Comprehensive Review**, 1st ed. New York : Thieme, 2015, pp155-160
12. da Costa L, Wallace MC, Ter Brugge KG, O'Kelly C, Willinsky RA, Tymianski M : The natural history and predictive features of hemorrhage from brain arteriovenous malformations. **Stroke** **40** : 100-105, 2009
13. Darsaut TE, Guzman R, Marcellus ML, Edwards MS, Tian L, Do HM, et al. : Management of pediatric intracranial arteriovenous malformations: experience with multimodality therapy. **Neurosurgery** **69** : 540-556; discussion 556, 2011
14. Derdeyn CP, Zipfel GJ, Albuquerque FC, Cooke DL, Feldmann E, Sheehan JP, et al. : Management of brain arteriovenous malformations: a scientific statement for healthcare professionals from the American Heart Association/American Stroke Association. **Stroke** **48** : e200-e224, 2017
15. Dicipinigaitis AJ, Ogulnick JV, Mayer SA, Gandhi CD, Al-Mufti F : Increase in ruptured cerebral arteriovenous malformations and mortality in the united states: unintended consequences of the ARUBA trial? **Stroke Vasc Interv Neurol** **3** : e000442, 2023
16. Dodier P, Kranawetter B, Hirschmann D, Dogan M, Cho A, Untersteiner H, et al. : Outcome of 107 conservatively managed unruptured brain arteriovenous malformations: a single center's 30-year experience. **J Neurosurg** **139** : 1025-1035, 2023
17. Ellis JA, Mejia Munne JC, Lavine SD, Meyers PM, Connolly ES Jr, Solomon RA : Arteriovenous malformations and headache. **J Clin Neurosci** **23** : 38-43, 2016
18. Ellis MJ, Armstrong D, Vachhrajani S, Kulkarni AV, Dirks PB, Drake JM, et al. : Angioarchitectural features associated with hemorrhagic presentation in pediatric cerebral arteriovenous malformations. **J Neurointerv Surg** **5** : 191-195, 2013
19. Friedlander RM : Clinical practice. Arteriovenous malformations of the brain. **N Engl J Med** **356** : 2704-2712, 2007
20. Fung LW, Ganesan V : Arteriovenous malformations presenting with papilloedema. **Dev Med Child Neurol** **46** : 626-627, 2004
21. Goldberg J, Raabe A, Bervini D : Natural history of brain arteriovenous malformations: systematic review. **J Neurosurg Sci** **62** : 437-443, 2018
22. Gross BA, Du R : Natural history of cerebral arteriovenous malformations: a meta-analysis. **J Neurosurg** **118** : 437-443, 2013
23. Gross BA, Du R : Rate of re-bleeding of arteriovenous malformations in the first year after rupture. **J Clin Neurosci** **19** : 1087-1088, 2012
24. Gross BA, Storey A, Orbach DB, Scott RM, Smith ER : Microsurgical treatment of arteriovenous malformations in pediatric patients: the Boston Children's Hospital experience. **J Neurosurg Pediatr** **15** : 71-77, 2015
25. Haas DC : Arteriovenous malformations and migraine: case reports and an analysis of the relationship. **Headache** **31** : 509-513, 1991
26. Halim AX, Johnston SC, Singh V, McCulloch CE, Bennett JP, Achrol AS, et al. : Longitudinal risk of intracranial hemorrhage in patients with arteriovenous malformation of the brain within a defined population. **Stroke** **35** : 1697-1702, 2004
27. Haridas A, Dashti R, Shokunfar T, Shaibani A : Pediatric Arteriovenous Malformations in Di Rocco C, Pang D, Rutka JT (eds) : **Textbook of Pediatric Neurosurgery**. Cham : Springer, 2020, Vol 2, pp1135-1168
28. Hirschmann D, Goebel P, Witte FH, Gatterbauer B, Wang WT, Dodier P, et al. : Evaluation of the radiosurgical treatment of cerebral arteriovenous malformations: a retrospective single-center analysis of three decades. **J Neurointerv Surg** **12** : 401-406, 2020
29. Hoffman C, Riina HA, Stieg P, Allen B, Gobin YP, Santillan A, et al. : Associated aneurysms in pediatric arteriovenous malformations and the implications for treatment. **Neurosurgery** **69** : 315-322, 2011
30. Karlsson B, Jokura H, Yang HC, Yamamoto M, Martinez R, Kawagishi J, et al. : The NASSAU (new assessment of cerebral arteriovenous malformations yet unruptured) analysis: are the results from the ARUBA trial also applicable to unruptured arteriovenous malformations deemed suitable for Gamma Knife surgery? **Neurosurgery** **85** : E118-E124, 2019
31. Kellner CP, McDowell MM, Phan MQ, Connolly ES, Lavine SD, Meyers PM, et al. : Number and location of draining veins in pediatric arteriovenous malformations: association with hemorrhage. **J Neurosurg Pediatr** **14** : 538-545, 2014
32. Kondziolka D, McLaughlin MR, Kestle JR : Simple risk predictions for arteriovenous malformation hemorrhage. **Neurosurgery** **37** : 851-855, 1995
33. Kupersmith MJ, Vargas ME, Yashar A, Madrid M, Nelson K, Seton A, et al. : Occipital arteriovenous malformations: visual disturbances and presentation. **Neurology** **46** : 953-957, 1996
34. Magro E, Gentric JC, Darsaut TE, Ziegler D, Bojanowski MW, Raymond J : Responses to ARUBA: a systematic review and critical analysis for the design of future arteriovenous malformation trials. **J Neurosurg** **126** : 486-494, 2017
35. Mahalick DM, Ruff RM, Hoi SU : Neuropsychological sequelae of arteriovenous malformations. **Neurosurgery** **29** : 351-357, 1991
36. Mast H, Mohr JP, Osipov A, Pile-Spellman J, Marshall RS, Lazar RM, et al. : 'Steal' is an unestablished mechanism for the clinical presentation of cerebral arteriovenous malformations. **Stroke** **26** : 1215-1220, 1995
37. Mohr JP, Overbey JR, Hartmann A, Kummer RV, Al-Shahi Salman R, Kim H, et al. : Medical management with interventional therapy versus medical management alone for unruptured brain arteriovenous malformations (ARUBA): final follow-up of a multicentre, non-blinded, randomised controlled trial. **Lancet Neurol** **19** : 573-581, 2020

38. Mohr JP, Parides MK, Stapf C, Moquete E, Moy CS, Overbey JR, et al. : Medical management with or without interventional therapy for unruptured brain arteriovenous malformations (ARUBA): a multicentre, non-blinded, randomised trial. **Lancet** **383** : 614-621, 2014
39. Nagata S, Morioka T, Natori Y, Sasaki T : Surgical treatment of non-ruptured giant occipital arteriovenous malformations with frequent migraine-like headache. **Neurol Med Chir (Tokyo)** **46** : 441-445, 2006
40. Niazi TN, Klimo P Jr, Anderson RC, Raffel C : Diagnosis and management of arteriovenous malformations in children. **Neurosurg Clin N Am** **21** : 443-456, 2010
41. Plumptre I, Robertson F, Rennie A, James G, Syed SB : Atypical capillary malformations with subsequent diplegia: a difficult case of capillary malformation-arteriovenous malformation syndrome. **Pediatr Dermatol** **37** : 162-164, 2020
42. Pollock BE, Link MJ, Stafford SL, Garces YI, Foote RL : Stereotactic radiosurgery for arteriovenous malformations: the effect of treatment period on patient outcomes. **Neurosurgery** **78** : 499-509, 2016
43. Reitz M, von Spreckelsen N, Vettorazzi E, Burkhardt T, Grzyska U, Fiehler J, et al. : Angioarchitectural risk factors for hemorrhage and clinical long-term outcome in pediatric patients with cerebral arteriovenous malformations. **World Neurosurg** **89** : 540-551, 2016
44. Sahlein DH, Mora P, Becske T, Huang P, Jafar JJ, Connolly ES, et al. : Features predictive of brain arteriovenous malformation hemorrhage: extrapolation to a physiologic model. **Stroke** **45** : 1964-1970, 2014
45. Sheth RD, Bodensteiner JB : Progressive neurologic impairment from an arteriovenous malformation vascular steal. **Pediatr Neurol** **13** : 352-354, 1995
46. Solomon RA, Connolly ES Jr : Arteriovenous malformations of the brain. **N Engl J Med** **376** : 1859-1866, 2017
47. Soltanolkotabi M, Schoeneman SE, Alden TD, Hurley MC, Ansari SA, DiPatri AJ Jr, et al. : Onyx embolization of intracranial arteriovenous malformations in pediatric patients. **J Neurosurg Pediatr** **11** : 431-437, 2013
48. Spetzler RF, Ponce FA : A 3-tier classification of cerebral arteriovenous malformations. Clinical article. **J Neurosurg** **114** : 842-849, 2011
49. Stapf C, Mast H, Sciacca RR, Berenstein A, Nelson PK, Gobin YP, et al. : The New York Islands AVM Study: design, study progress, and initial results. **Stroke** **34** : e29-e33, 2003
50. Stapf C, Mast H, Sciacca RR, Choi JH, Khaw AV, Connolly ES, et al. : Predictors of hemorrhage in patients with untreated brain arteriovenous malformation. **Neurology** **66** : 1350-1355, 2006
51. Stapf C, Mohr JP, Pile-Spellman J, Solomon RA, Sacco RL, Connolly ES Jr : Epidemiology and natural history of arteriovenous malformations. **Neurosurg Focus** **11** : e1, 2001
52. Valdivielso-Ramos M, Martin-Santiago A, Azaña JM, Hernández-Nuñez A, Vera A, Perez B, et al. : Capillary malformation-arteriovenous malformation syndrome: a multicentre study. **Clin Exp Dermatol** **46** : 300-305, 2021
53. van Beijnum J, Lovelock CE, Cordonnier C, Rothwell PM, Klijn CJ, Al-Shahi Salman R, et al. : Outcome after spontaneous and arteriovenous malformation-related intracerebral haemorrhage: population-based studies. **Brain** **132** : 537-543, 2009
54. Yamada S, Takagi Y, Nozaki K, Kikuta K, Hashimoto N : Risk factors for subsequent hemorrhage in patients with cerebral arteriovenous malformations. **J Neurosurg** **107** : 965-972, 2007
55. Yang W, Liu A, Hung AL, Brăileanu M, Wang JY, Caplan JM, et al. : Lower risk of intracranial arteriovenous malformation hemorrhage in patients with hereditary hemorrhagic telangiectasia. **Neurosurgery** **78** : 684-693, 2016
56. Zhang Y, Chen Y, Han H, Ma L, Li R, Li Z, et al. : Timing of microsurgical resection for ruptured brain arteriovenous malformations: a propensity score-matched analysis using prospective single-center registry data. **J Neurosurg** **140** : 164-171, 2023