

## Secondary laryngeal tuberculosis revisited

Jaini V Lodha, Arpit Sharma, Nitish Virmani, Ameya Bihani, Jyoti P Dabholkar

Department of ENT and Head and Neck Surgery, Seth Gordhandas Sunderdas Medical College and King Edward Memorial Hospital, Mumbai, Maharashtra, India

### ABSTRACT

**Introduction:** Laryngeal tuberculosis is often misdiagnosed and is a highly contagious public health problem. The changing pattern of the clinical involvement of this disease poses a diagnostic challenge. The authors report four cases of laryngeal tuberculosis encountered in a short span of one month. **Materials and Methods:** All the four patients who presented to us with hoarseness had underlying active lesions in the lung. In spite of that they presented with mainly laryngeal symptoms and a multitude of findings on laryngeal examination. A diagnosis could be established owing to a high index of clinical suspicion, and due consideration given to the chest findings and positive sputum examination. The patients showed an excellent response to antituberculous therapy. **Results and Conclusions:** This study underlines the varied nature of laryngeal tuberculosis and the importance of addressing the hoarseness of a patient at the earliest, for the prompt diagnosis of this infectious condition.

**KEY WORDS:** Anti-tuberculosis treatment, laryngeal tuberculosis, pulmonary tuberculosis

**Address for correspondence:** Dr. Jaini V Lodha, Department of ENT and Head and Neck Surgery, Seth Gordhandas Sunderdas Medical College and King Edward Memorial Hospital, Parel, Mumbai, Maharashtra, India. E-mail: jainilodha@gmail.com

### INTRODUCTION

Tuberculosis is a chronic granulomatous disease caused by *Mycobacterium Bacilli*. Although it can affect all the tissues of the body, pulmonary tuberculosis is the most common type, representing 80% of all cases of tuberculosis.<sup>[1]</sup>

In the early twentieth century, laryngeal tuberculosis was the distressing terminal event in up to 84% of the cases of fatal pulmonary tuberculosis.<sup>[2]</sup> With the advent of anti-tubercular medications and improved socioeconomic conditions in the twentieth century, its incidence began to decrease in affluent countries, but it continues to be a public health hazard in developing countries like India.

In addition, the acquired immune deficiency syndrome (AIDS) and other immunosuppressive diseases or treatment add to this incidence.<sup>[3]</sup>

In the present study, we report the clinical characteristics and the management of laryngeal tuberculosis of four cases studied in a short period of one month.

### MATERIALS AND METHODS

The authors report four cases of laryngeal tuberculosis (three males and one female); who presented to the Outpatient Department of our institute in a period of one month [Table 1]. All the patients consulted otolaryngologists, due to symptoms of change in voice and a foreign body sensation in the throat. The mean duration of symptoms was 4.25 months. Two of the patients had a history of intermittent low-grade fever and generalized malaise. On enquiry, pulmonary symptoms were present in two patients in the form of cough with expectoration, since two months.

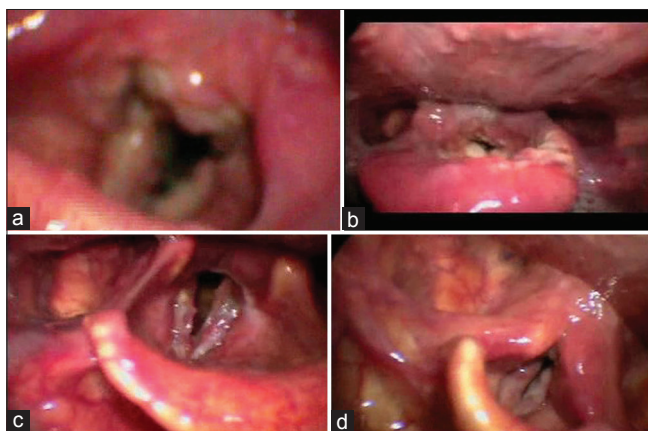
Laryngoscopy performed using a 70-degree rigid endoscope revealed inter-arytenoid granulations in two patients and diffuse thickening of the vocal cords in three patients; one of these patients had an ulcerative lesion on the aryepiglottic fold as well. Granulations were present over the bilateral true cords, along the entire length, in two patients [Figure 1].

Contrast-enhanced computerized tomography (CECT) scan of the neck highlighted mucosal irregularity and thickening over the bilateral vocal cords in three patients [Figure 2].

Access this article online	
<b>Quick Response Code:</b> 	<b>Website:</b> www.lungindia.com
	<b>DOI:</b> 10.4103/0970-2113.164163

**Table 1: Details of patients with laryngeal tuberculosis**

Age	Sex	Symptoms	Duration (months)	Laryngoscopic findings
26	Female	Hoarseness and foreign body sensation in throat, cough with expectoration	Three	Interarytenoid granulations; thickening, and irregularity of the bilateral true cords [Figure 1a]
65	Male	Hoarseness and foreign body sensation in throat; low-grade fever and malaise	Six	Interarytenoid granulations; thickened true cords; ulcerative lesions over the left aryepiglottic fold [Figure 1b]
53	Male	Hoarseness and foreign body sensation in throat; low-grade fever and malaise	Five	Granulations over the bilateral true cords [Figure 1c]
45	Male	Hoarseness and cough with expectoration and loss of weight	Three	Granulations and thickening of the bilateral true vocal cords [Figure 1d]

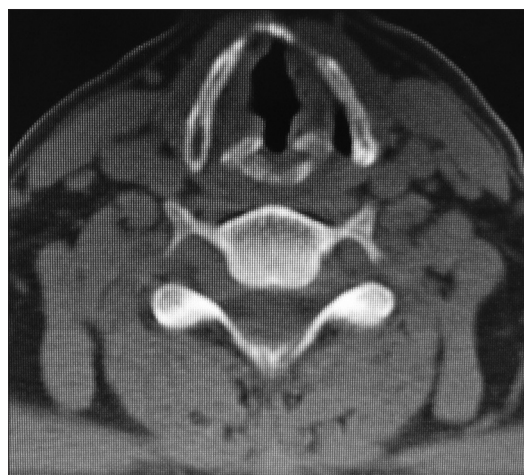

**Figure 1:** (a) Patient 1 with interarytenoid granulations, thickening, and irregularity of the bilateral true cords; (b) Patient 2 with Interarytenoid granulations, thickened true cords, and ulcerative lesions over the left aryepiglottic fold; (c) Patient 3 with granulations over the bilateral true vocal cords; (d) Patient 4 with granulations and thickening of the bilateral true cords

Chest x-ray and high-resolution computed tomography (HRCT) chest revealed cavitory lesions [Figure 3a and b]. The sputum smear was positive for acid fast bacilli (AFB) in all four patients. Considering the typical laryngeal diffuse findings clubbed with the chest x-ray and HRCT findings along with a positive sputum AFB report, all four patients were diagnosed to have secondary laryngeal tuberculosis, due to the seedlings of the bacilli in the larynx from the pulmonary lesion. They were started on category-1 antituberculous therapy. Category 1 consisted of isoniazid, rifampicin, pyrazinamide, and ethambutol for two months followed by isoniazid and rifampicin for another four months. The symptoms as well as laryngeal findings completely resolved within two months of starting the treatment and the patients' sputum AFB was negative at the end of two months of starting ATT, with moderately resolved cough and improved general condition.

## DISCUSSION

Laryngeal tuberculosis is a disease known to us since a long time. Although the incidence is decreasing in affluent countries with the advent of Anti-Tubercular Treatment and improved socioeconomic conditions, it still continues to be a public health hazard in developing countries.



**Figure 2:** CECT neck showing thickening and irregularity over the bilateral cords

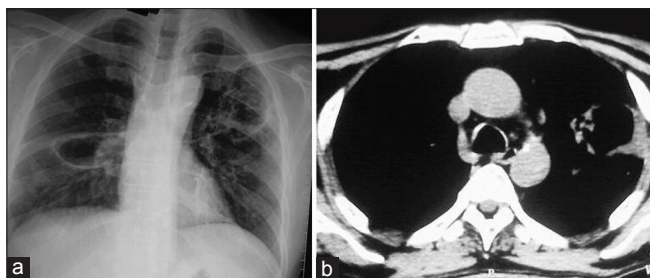
In our series, we had a total of four patients presenting to us in a short period of one month. The reason could be the increasing incidence of tuberculosis and also because the patients sought ENT assistance for hoarseness, ours being a tertiary care referral hospital.

Laryngeal TB is of two types — primary and secondary. Primary TB is caused by direct seeding of inhaled *Mycobacteria Bacilli* and secondary TB is caused by the seeding of bacilli in the larynx, from the lungs. Laryngeal involvement has been observed in 15–37% of the cases of pulmonary tuberculosis, but primary involvement is seen only in 19% of the tuberculosis cases.<sup>[4]</sup>

All our four cases revealed active pulmonary disease when they were thoroughly investigated using chest x-ray and HRCT chest, and this was confirmed by sputum AFB. However, surprisingly, in spite of having active foci in the lungs, they presented more with hoarseness and laryngeal symptoms than pulmonary symptoms like cough.

This emphasizes the fact that the onus of proper and early diagnosis of the laryngeal as well as the pulmonary disease lies on the ENT surgeons and thorough investigations with a chest HRCT is mandatory.

The classical finding of laryngeal TB is changing from involvement of the posterior glottis to true vocal cords. Localization in the anterior half of the larynx now occurs



**Figure 3:** (a) Chest x-ray suggestive of cavitory lesions in the lung. (b) HRCT chest suggestive of cavitory lesions in the lung

twice as often as in the posterior half. The various sites of affection include vocal cords (50–70%), false cords (40–50%) epiglottis, aryepiglottic folds, arytenoids, posterior commissure, and/or subglottis (10–15%).<sup>[5]</sup> In our series three out of the four patients had vocal cord involvement.

The laryngeal findings can again have a myriad of presentations, such as, whitish ulcerative lesions (40.9%), nonspecific inflammatory lesions (27.3%), polypoid lesions (22.7%), and ulcerofungative mass lesions (9.1%).<sup>[6]</sup> The granulomas can either be ulcerative or exudative.

In our series, the laryngeal findings ranged from granulations over the cords and interarytenoid region to diffuse thickening and polypoidal changes. In addition, one case had ulcerative lesions over the aryepiglottic fold.

This non-specific diffuse involvement of the larynx in tuberculosis, can lead one to a false suspicion of malignancy and it is of utmost importance to distinguish between the two, as a delay in diagnosis or improper diagnosis can significantly alter the management plan. Tuberculosis is amenable to medical management, whereas, malignancy warrants surgery to the extent of total laryngectomy. A CT scan and biopsy will help in differentiating between the two conditions.

One should be aware of the other granulomatous lesions of the larynx and their presentations, namely, rhinoscleroma, which presents as a smooth red swelling in the subglottis; leprosy, which has granulomatous swelling and ulceration, with destruction chiefly in the supraglottic region; Wegener's granulomatosis, which presents as an edematous mucosa, with a granular appearance in the subglottis; and sarcoidosis in which the epiglottis and false vocal cords are swollen, edematous, and pale.

A CT scan showing diffuse changes in the larynx, without cartilage erosion, in a case of pulmonary tuberculosis should raise the suspicion of laryngeal tuberculosis.

Early biopsy to rule out malignancy may not always be preferred if the above-mentioned investigations (chest x-ray, HRCT chest, sputum AFB) are positive for

tuberculosis and if there is prompt response to ATT. According to Kulkarni *et al.* response to ATT is an important diagnostic criteria for laryngeal tuberculosis.<sup>[7]</sup> If the response to ATT is not complete, then a biopsy is indicated at that stage. This approach is safe and logical, as giving general anesthesia (for performing a laryngeal biopsy) to an active pulmonary kochs case is not always practically possible, because of anesthesia concerns, drug interactions, and infectivity concerns.<sup>[8]</sup>

In our cases, the patients were not subjected to direct laryngoscopic biopsy, but a combination of typical laryngeal findings, sputum AFB, radiology of the chest, and prompt response to ATT confirmed the diagnosis of laryngeal TB.

## CONCLUSION

To conclude, it is important to highlight a few facts about laryngeal tuberculosis:

- Increasing incidence of laryngeal tuberculosis is possible
- The clinician must be prompt and thorough in evaluating the hoarseness in a patient with cough and malaise
- There must be knowledge about the changes in the larynx, suspicious of tuberculosis. The typical site of involvement changes from posterior glottis to true vocal cords
- Laryngeal tuberculosis mimics laryngeal cancer, hence, the two need to be differentiated
- Complete evaluation including chest imaging and sputum AFB is mandatory to rule out the underlying pulmonary tuberculosis.

## REFERENCES

1. World Health Organization. Global Tuberculosis Control. Geneva, Switzerland: WHO Report; 2010. p. 275.
2. Negus VE. Diseases of the Nose and Throat. 5<sup>th</sup> ed. London: Cassel and Company Ltd; 1948.
3. Kandiloros DC, Nikopoulos TP, Ferekididis EA, Tsangaroulakis A, Yiotakis JE, Davilis D. Laryngeal tuberculosis at the end of the 20<sup>th</sup> century. *J Laryngol Otol* 1995;109:5-13.
4. Harney M, Hone S, Timon C, Donnelly M. Laryngeal tuberculosis: An important diagnosis. *J Laryngol Otol* 2000;114:878-80.
5. Cleary KR, Batsakis JG. Mycobacterial disease of the head and neck: Current perspective. *Ann OtolRhinolLaryngol* 1995;104:830-3.
6. Shin JE, Nam SY, Yoo SJ, Kim SY. Changing trends in clinical manifestations of laryngeal tuberculosis. *Laryngoscope* 2000;110:1950-3.
7. Kulkarni NS, Gopal GS, Ghaisas SG, Gupte NA. Epidemiological considerations and clinical features of ENT tuberculosis. *J Laryngol Otol* 2001;115:555-8.
8. Jackson TA, Thomas JM. Tuberculosis: The implications for anaesthesia. *South Afr J Anaesth Analg* 2013;19:301-5.

**How to cite this article:** Lodha JV, Sharma A, Virmani N, Bihani A, Dabholkar JP. Secondary laryngeal tuberculosis revisited. *Lung India* 2015;32:462-4.

**Source of Support:** Nil, **Conflict of Interest:** None declared.