

Is Combined Ultrasound with Radiography Sufficient for the Diagnosis of Obstructive Ureteric Stone in Patients with Acute Flank Pain?

Pornprom Thungkatikajonkit¹, Sirote Wongwaisayawan^{1*}, Arrug Wibulpolprasert², Wit Viseshsindh³, Rathachai Kaewlai¹

¹Department of Diagnostic and Therapeutic Radiology, Faculty of Medicine, Ramathibodi Hospital, Mahidol University, Bangkok, Thailand, ²Department of Emergency Medicine, Faculty of Medicine, Ramathibodi Hospital, Mahidol University, Bangkok, Thailand, ³Department of Surgery, Division of Urology, Faculty of Medicine, Ramathibodi Hospital, Mahidol University, Bangkok, Thailand

Abstract

Context: Ultrasound (US) is excellent for detection of hydronephrosis but has poor sensitivity for stone detection. In contrast, radiography of the kidney–ureter–bladder has better sensitivity for detection of stone but limited sensitivity for hydronephrosis detection. A combination of these two modalities may improve both sensitivity and specificity for the diagnosis of obstructive ureteric stone. **Aims:** This study aims to investigate the diagnostic accuracy of combined US with radiography for the diagnosis of obstructive ureteric stone in adult patients. **Settings and Design:** Retrospective study with retrospective data collection performed in a 1500-bed university hospital. **Materials and Methods:** A total of 90 patients were included. The electronic medical record, radiological reports, laboratory results, and patient management were extracted and analyzed. **Statistical Analysis Used:** The diagnostic performance of US, radiography, and combined US with radiography were calculated and compared. The computed tomography was used as diagnostic reference. **Results:** US alone had a sensitivity of 73.5%, specificity of 92.7%, and negative predictive value (NPV) of 74.5% for hydronephrosis. When US showed both ureteric stone and hydronephrosis, sensitivity dropped to 14.3% but specificity increased to 100%. Radiography alone had a sensitivity of 34.7%, specificity of 100%, and NPV of 56.2% for the detection of ureteric stone. Combining radiography with US raised the sensitivity for diagnosis of obstructive ureteric stone to 88% with a specificity of 93% and accuracy of 90%. **Conclusions:** Combined US with radiography was accurate for the diagnosis of obstructive ureteric stone in patients presenting with acute flank pain.

Keywords: Computed tomography, hydronephrosis, ultrasound, ureteric stone

INTRODUCTION

Acute flank pain secondary to obstructive ureteric stone is a common condition necessitating attendance to the emergency department (ED). Noncontrast computed tomography (NCCT) is generally a standard reference for the diagnosis of ureteric stone and is currently the first-line imaging for most adults recommended by the American College of Radiology Appropriateness Criteria because it can accurately provide three variables critical for treatment selection in obstructive ureteric stone: size and site of stone, and the degree of obstruction.^[1-6] However, NCCT is costly and exposes patients to ionizing radiation. Other imaging means those may provide such information while

minimizing the cost and radiation exposure are radiography and ultrasound (US).

US has long been regarded as an excellent imaging technique for detection of urinary tract obstruction and is considered an appropriate means to evaluate ED patients given its wide availability, portability, and repeatability.^[7-9] Because most patients with acute flank pain are young adults, the lack of ionizing radiation of US makes the modality even more

Address for correspondence: Dr. Sirote Wongwaisayawan, Department of Diagnostic and Therapeutic Radiology, Faculty of Medicine, Ramathibodi Hospital, Mahidol University, 270 Rama VI Road, Ratchathewi, Bangkok 10400, Thailand.
E-mail: srww386@hotmail.com

Received: 30-05-2019 Revised: 17-07-2019 Accepted: 01-08-2019 Available Online: 10-12-2019

Access this article online

Quick Response Code:



Website:
www.jmuonline.org

DOI:
10.4103/JMU.JMU_49_19

This is an open access journal, and articles are distributed under the terms of the Creative Commons Attribution-NonCommercial-ShareAlike 4.0 License, which allows others to remix, tweak, and build upon the work non-commercially, as long as appropriate credit is given and the new creations are licensed under the identical terms.

For reprints contact: WKHLRPMedknow_reprints@wolterskluwer.com

How to cite this article: Thungkatikajonkit P, Wongwaisayawan S, Wibulpolprasert A, Viseshsindh W, Kaewlai R. Is combined ultrasound with radiography sufficient for the diagnosis of obstructive ureteric stone in patients with acute flank pain? J Med Ultrasound 2020;28:86-91.

attractive.^[10,11] However, US sensitivity for detection of stone is rather poor, particularly in emergency setting when there is suboptimal patient preparation.^[12]

Radiography of the kidney–ureter–bladder (KUB) has a better, albeit modest, sensitivity for detection of stone than US.^[1] Theoretically, a combination of these two modalities may improve both sensitivity and specificity for the diagnosis of obstructive ureteric stone and hydronephrosis. There have been only few prior reports that investigate performance of these two modalities together in the same patients but with promising results.^[13] Therefore, we performed this investigation to determine performance of combined US with KUB radiography in this specific patient population using NCCT as a reference standard.

MATERIALS AND METHODS

This study is a retrospective investigation with retrospective data collection in a 1500-bed university hospital. The study was in accordance to the ethical standard and was approved by the committee on human rights related to research involving human subjects Faculty of Medicine Ramathibodi hospital, Mahidol university (protocol number: ID 08-58-34) on September 1, 2015. The need of informed consent was waived.

From August 1, 2014, to July 31, 2015, there were 164 consecutive adult patients presenting with acute flank pain to the ED who received both US and radiography at the ED according to our hospital’s acute flank pain protocol [Figure 1]. The protocol dictates the use of US and radiography in all patients without previous episode of stone disease. The decision for NCCT was based on US and radiographic findings and a clinical probability stratification called STONE score [Appendix A].^[14] Ninety patients (45 men, mean age 45.6 years, range 16–90 years) underwent NCCT and constituted our study cohort. Figure 2 illustrates the patient selection process.

A definitive diagnosis of ureteric stone was made when there was a stone documented on reports of NCCT. The obstructive stone was defined as the stone that shows signs of obstruction or associated inflammation depicted on imaging, such as decreased or absent ureteric jet flow on color Doppler US, hydroureter, hydronephrosis, perinephric fluid, and inflammatory change of periureteric and perinephric fat (on NCCT). The degree of hydronephrosis was graded into mild degree: dilatation of

renal pelvis, moderate degree: dilatation of renal pelvis and calices, and severe degree: dilated collecting system with thin renal parenchyma. Hydroureter was diagnosed if the ureteric diameter was more than 3 mm.^[15] The proximal ureter was defined as the segment between ureteropelvic junction (UPJ) and above the upper border of sacroiliac joint. The middle ureter was the segment which overlaid the sacroiliac joint and the distal ureter lied between lower border of sacroiliac joint and the urinary bladder.^[16] Patients without ureteric stone on any imaging modalities or having an alternative diagnosis, with an unremarkable clinical follow-up for 6 months were considered negative for obstructive ureteric stone. We also reviewed the treatment given to patients who were diagnosed with ureteric stone.

One of the investigators reviewed all patient’s records for age, gender, clinical presentation, urinalysis result (red blood cells per high-power field), radiological reports, pathological reports, operative notes, and STONE score.

The plain KUB radiography was performed using a standard technique on a Philips machine (Philips Medical Systems, Amsterdam, Netherlands). The study was considered positive if stone was identified along the anatomic course of the ureter. All of the US examinations were performed by either radiology trainees or attending radiologists using an iU22 system (Philips Medical Systems, Amsterdam, Netherlands) with a C5-1 curved linear array transducer. Except for the instruction to avoid urination before the US examination, there were no specific prerequisites such as bladder filling or hydration requirement. All of the radiology trainees were 3rd year residents who were in their final year of residency training, of which their curriculum included hands-on abdominal US prerequisites, specific US and abdominal radiology rotations, and abdominal US experience of a minimum of 100 patients. Radiologists who performed US were practicing emergency radiology or body imaging with 2–10 years of experience. All of the US studies were interpreted before the computed tomography (CT) examination. The stone was defined as a hyperechoic focus in the pelvicalyceal system or ureter which may or may not cast posterior acoustic shadows, depending on its size. All CT scans were performed on a Toshiba Aquilion CX (Toshiba Medical Systems Corporation, Japan) without administration of intravenous contrast material. The scan extended from the upper pole of both kidneys to the pubic symphysis. Helical acquisition was used with the following parameters: 0.6 s tube rotation; collimation, 0.5 mm; pitch,

Findings on US and radiography	STONE score		
	0-5	6-9	10-13
No hydronephrosis and no alternative diagnosis	Clinical judgment	NCCT	NCCT
Hydronephrosis	NCCT	NCCT	Treat as renal colic
Hydronephrosis and ureterolithiasis	Treat as renal colic	Treat as renal colic	Treat as renal colic

Figure 1: Our institutional “acute flank pain protocol.” STONE score is adopted to stratify the patients into three groups of low, intermediate, and high probability of ureteric stone. The patient is managed according to STONE score and initial ultrasound/radiographic findings

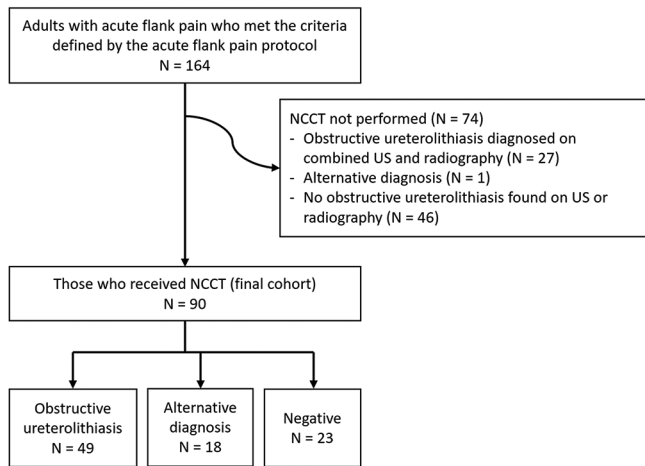


Figure 2: Patient flow chart

0.828; 100 kVp; noise index, 20; and tube current ranging from 70 to 250 mA determined by automatic tube current modulation. Both axial and coronal contiguous nonoverlapping 2-mm-thick image sections were reconstructed and transferred to the hospital picture archiving and communication system for interpretation.

Statistical analyses were performed on Microsoft Excel (Microsoft Corp, Redmond, WA, USA) and STATA version 13.0 (Stata Corp., College Drive, TX, USA) software. The performance of the US, KUB radiography, and combined US with radiography were compared.

RESULTS

There were 90 patients included in the analysis consisting of 45 men with a mean age of 45.6 years (standard deviation; [SD] 15, range 16–85 years). The STONE scores were low, intermediate, and high in 12, 51, and 27 patients, respectively. Forty-nine patients had obstructive ureteric stone (49/90, 54%) diagnosed on NCCT. The rest of the patients had alternative diagnosis (18 patients) and no reasons for flank pain (23 patients). Alternative diagnoses were pyelonephritis (five patients), dermoid cyst (two patients), ovarian cyst (two patients), and one patient each for recently passed stone, UPJ obstruction, bladder carcinoma with invasion of the ureterovesical junction (UVJ), pelvic mass, seroma, perforated diverticulitis, appendicitis, complicated aortic aneurysm, and uterine leiomyoma.

The size of stone was five mm or less in 41 patients (41/49, 83.7%). They were on the right side in 27 patients (27/49, 55.1%). There was no bilateral stone. The locations of stones were UPJ in one patient, proximal ureter in four patients, mid-ureter in seven patients, distal ureter in 12 patients, and UVJ in 25 patients, respectively.

The median time was 62 min (interquartile range; [IQR], 36–126 min) from presentation to US examination, 88.8 min (IQR, 51.5–160.5 min) from US study to CT

examination, and 172 min (IQR, 123–277 min) from presentation to final imaging diagnosis.

Using NCCT as the reference standard, sensitivity, specificity, positive predictive value, negative predictive value, positive likelihood ratio, negative likelihood ratio, diagnostic odds ratio, and accuracy of US, KUB radiography and combined US with radiography were provided in Table 1. The median effective dose for each patient was 5.9 mSv (IQR 4.3–8.9 mSv).

US had sensitivity of 73.5%, specificity of 92.7%, and accuracy of 82% for detection of hydronephrosis. For stone detection, KUB radiography had sensitivity of 34.7%, specificity of 100%, and accuracy of 34.7%. When combining these two modalities, the sensitivity, specificity, and accuracy for detection of obstructive ureteric stone were 87.8%, 92.7%, and 90%, respectively. The diagnostic odds ratio for combined modalities was 90.8. The examples of patients were provided in Figures 3 and 4.

There were six patients in whom obstructive ureteric stones were overlooked on both US and KUB radiography. These patients were all men with a mean age of 49 years (SD 13, range 36–68 years). Their STONE scores ranged from 8 to 11. Stones were present equally on the right and left sides (three each); all of them were <5 mm in size. Five out of six stones were in the UVJ; the other one was in the mid-ureter. No urologic intervention was required in any of these patients. Four of them reported spontaneously passed stones.

DISCUSSION

Although NCCT is now considered the first-line imaging for the evaluation of adult patients presenting with acute flank pain in the ED, there is growing concern about rising healthcare cost and cumulative radiation exposure to mostly young individuals associated with this imaging technique. Alternative imaging methods that expose less radiation to the patient at a lesser cost with an ability to provide important information for treatment of ureteric stone would be ideal and preferable.

KUB radiography is modestly sensitive for detection of ureteric stone, reportedly ranging from 29% to 59%.^[17,18] Our investigation is in line with this notion with radiography sensitivity of 34.7% and specificity of 100%. When stone is detected, radiography can provide information on the size and site of stone, which is crucial for selection of treatment and for follow-up of stone passage.^[19] KUB radiography has much lower radiation dose (0.5–1 mSv) than standard NCCT (7.3–14.4 mSv).^[19,20]

US is a useful tool for the evaluation for signs of urinary tract obstruction (hydronephrosis, ureteral dilatation, and perinephric fluid) as it has a reasonable accuracy for the detection of hydronephrosis (sensitivity 75%–90%), relatively easy to perform at great speed, and can be routinely performed in radiology or EDs.^[13,21] A large multicenter study also found that there were no significant differences in morbidity, ED revisit, or hospitalization between patients with initial US and

Table 1: Performance of ultrasound, radiography, and combined technique

Modality	Diagnosis	Sensitivity (%)	Specificity (%)	PPV (%)	NPV (%)	PLR	NLR	Diagnostic OR	Accuracy (%)
US	Hydronephrosis	73.5 (59-85)	92.7 (80-99)	92.3	74.5	10	0.29	35.1	82 (73-89)
	Hydronephrosis and ureteric stone	14.3 (6-27)	100 (91-100)	100	49.4	N/A*	0.86	N/A*	53 (43-64)
Radiography	Ureteric stone	34.7 (22-50)	100 (91-100)	100	56.2	N/A*	0.65	N/A*	64 (54-74)
Combined US with radiography	Hydronephrosis and ureteric stone	87.8 (75-95)	92.7 (80-99)	93.5	86.4	12	0.13	90.8	90 (82-95)

*The values cannot be calculated due to 100% specificity. Values in parentheses represent 95%CI. US: Ultrasound, PPV: Positive predictive value, NPV: Negative predictive value, PLR: Positive likelihood ratio, NLR: Negative likelihood ratio, CI: Confidence interval, OR: Odds ratio, NA: Not available

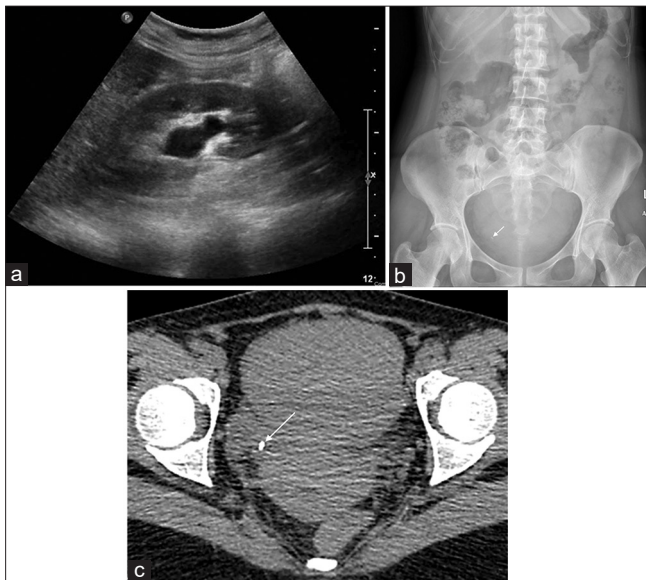


Figure 3: Obstructive right ureteric stone. Ultrasound (a) of a 43-year-old woman reveals mild hydronephrosis while radiography (b) shows distal ureteric stone (arrow). Computed tomography (c) confirms the diagnosis (arrow)

patient with initial CT, even in those who had point-of-care US performed by emergency physician.^[22] However, the detection rate of ureteric stone is rather poor, ranging in sensitivity from 12% to 98%.^[4,23-26] In a well-prepared patient cohort, sensitivity for US to detect ureteric stone is about 90%–98.3%.^[9,27,28] The results of our investigation support this notion that US has a rather high sensitivity (73.5%) for detection of hydronephrosis but poorly sensitive at detecting ureteric stone (14.3%). Moreover, the sensitivity of US is reduced if the stone is of <3 mm in size, in which it may not produce posterior acoustic shadowing.^[29] The use of twinkling artifact can also improve the detection rate and specificity of US by distinguishing stones from other hyperechoic structures.^[25,30] However, its use in detecting ureteric stone may be limited by overlying bowel gas.

These two techniques have their individual strengths and limitations but may be complementary to one another when combined. Ripollés *et al.* demonstrated a sensitivity of 78.6% and a specificity of 90% in a cohort of 66 patients who underwent combined US and radiography in comparison with NCCT.^[13] Another retrospective cohort in 160 patients also

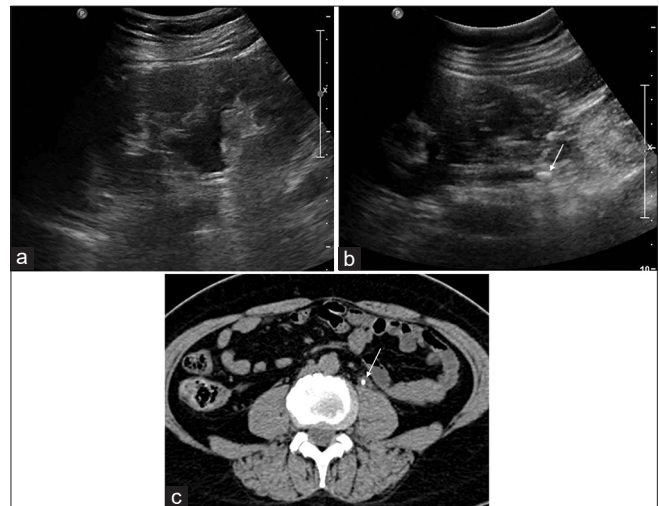


Figure 4: Obstructive left ureteric stone. Ultrasound (a and b) of a 57-year-old woman reveals mild hydronephrosis and proximal hydroureter with a stone (arrow) in the upper ureter. The diagnosis of left ureteric stone (arrow) is confirmed on computed tomography (c)

yielded a comparable sensitivity of 77.1% and a specificity of 92.7%.^[31] The results of our investigation further confirm that by combining the two, the strengths are additive and weaknesses are reduced as the sensitivity and accuracy are increased above individual modality's performance without sacrificing the specificity. Therefore, the combination is promising as a valuable diagnostic tool in the ED evaluation of acute flank pain.

Nevertheless, the combined technique still overlook several obstructive ureteric stones. Five UVJ stones and one ureteric stone were missed in our study. Four of five patients with missed UVJ stones had suboptimal bladder distension. These UVJ stones might have been picked up if US was performed in a more controlled manner, i.e., with adequate hydration or optimal bladder filling.^[32]

However, if ones focus on the ultimate endpoint for caring patients with acute flank pain, these small, spontaneously passed stones might not make a difference in treatment strategy.^[29,33] NCCT may, therefore, be reserved for specific patients when initial US and radiography are negative but the clinical pretest probability (i.e. STONE score) is high.

Our investigation is limited by its retrospective nature with a

small sample size. We extracted information from radiology reports rather than having the studies reinterpreted by radiologists to get real-world data and to avoid bias that may occur if US would be reinterpreted. This may be a reason that our diagnostic test sensitivity was in a rather low end of the reported spectrum. In more ideal settings, it is likely that the combined technique will have greater performance as the sensitivity of US and radiography becomes higher with advanced technology. Our acute flank pain protocol limits the use of NCCT, which is our reference standard, and could result in a cohort that skewed toward a higher clinical pretest probability of obstructive ureteric stone. Although the test sensitivity, specificity, and accuracy are generally not directly related to prevalence of disease, it should be kept in mind that diagnostic test performance is usually dependable on clinical pretest probability. In general practice, the US and KUB radiography are more likely to be interpreted by the attending physicians, which could result in different test characteristics than those found in our study.

CONCLUSIONS

Combined US with KUB radiography has promising result for the diagnosis of obstructive ureteric stone in patients presenting with acute flank pain to the ED. Initial US and KUB radiograph in these patients could help lower the need for CT scan and thus reduce the radiation exposure to the patient.

Declaration of patient consent

The authors certify that they have obtained all appropriate patient consent forms. In the form the patients have given their consent for their images and other clinical information to be reported in the journal. The patients understand that their names and initials will not be published and due efforts will be made to conceal their identity, but anonymity cannot be guaranteed.

Financial support and sponsorship

Nil.

Conflicts of interest

There are no conflicts of interest.

REFERENCES

- American College of Radiology. ACR Appropriateness Criteria® Acute Onset Flank Pain – Suspicion of Stone Disease (Urolithiasis). American College of Radiology; 2015. Available from: <https://acsearch.acr.org/docs/69362/Narrative/>. [Last accessed on 2017 Oct 25].
- Kennish SJ, Bhatnagar P, Wah TM, Bush S, Irving HC. Is the KUB radiograph redundant for investigating acute ureteric colic in the non-contrast enhanced computed tomography era? *Clin Radiol* 2008;63:1131-5.
- Masch WR, Cronin KC, Sahani DV, Kambadakone A. Imaging in urolithiasis. *Radiol Clin North Am* 2017;55:209-24.
- Sheafor DH, Hertzberg BS, Freed KS, Carroll BA, Keogan MT, Paulson EK, *et al.* Nonenhanced helical CT and US in the emergency evaluation of patients with renal colic: Prospective comparison. *Radiology* 2000;217:792-7.
- Tehey DU, Ha YS, Kim WT, Yun SJ, Lee SC, Kim WJ. Expectant management of ureter stones: Outcome and clinical factors of spontaneous passage in a single institution's experience. *Korean J Urol* 2011;52:847-51.
- Villa L, Giusti G, Knoll T, Traxer O. Imaging for urinary stones: Update in 2015. *Eur Urol Focus* 2016;2:122-9.
- Kanno T, Kubota M, Sakamoto H, Nishiyama R, Okada T, Higashi Y, *et al.* Determining the efficacy of ultrasonography for the detection of ureteral stone. *Urology* 2014;84:533-7.
- Nicolau C, Claudon M, Derchi LE, Adam EJ, Nielsen MB, Mostbeck G, *et al.* Imaging patients with renal colic-consider ultrasound first. *Insights Imaging* 2015;6:441-7.
- Park SJ, Yi BH, Lee HK, Kim YH, Kim GJ, Kim HC. Evaluation of patients with suspected ureteral calculi using sonography as an initial diagnostic tool: How can we improve diagnostic accuracy? *J Ultrasound Med* 2008;27:1441-50.
- Gaspari RJ, Horst K. Emergency ultrasound and urinalysis in the evaluation of flank pain. *Acad Emerg Med* 2005;12:1180-4.
- Serinken M, Karcioğlu O, Turkcuer I, Ozkan HI, Keysan MK, Bukiran A. Analysis of clinical and demographic characteristics of patients presenting with renal colic in the emergency department. *BMC Res Notes* 2008;1:79.
- Fowler KA, Locken JA, Duchesne JH, Williamson MR. US for detecting renal calculi with nonenhanced CT as a reference standard. *Radiology* 2002;222:109-13.
- Ripollés T, Agramunt M, Errando J, Martínez MJ, Coronel B, Morales M. Suspected ureteral colic: Plain film and sonography vs unenhanced helical CT. A prospective study in 66 patients. *Eur Radiol* 2004;14:129-36.
- Moore CL, Bomann S, Daniels B, Luty S, Molinaro A, Singh D, *et al.* Derivation and validation of a clinical prediction rule for uncomplicated ureteral stone – The STONE score: Retrospective and prospective observational cohort studies. *BMJ* 2014;348:g2191.
- Zelenko N, Coll D, Rosenfeld AT, Smith RC. Normal ureter size on unenhanced helical CT. *AJR Am J Roentgenol* 2004;182:1039-41.
- Assimos D, Krambeck A, Miller NL, Monga M, Murad MH, Nelson CP, *et al.* Surgical management of stones: American Urological Association/Endourological Society Guideline, PART I. *J Urol* 2016;196:1153-60.
- Jung SI, Kim YJ, Park HS, Jeon HJ, Park HK, Paick SH, *et al.* Sensitivity of digital abdominal radiography for the detection of ureter stones by stone size and location. *J Comput Assist Tomogr* 2010;34:879-82.
- Levine JA, Neitlich J, Verga M, Dalrymple N, Smith RC. Ureteral calculi in patients with flank pain: Correlation of plain radiography with unenhanced helical CT. *Radiology* 1997;204:27-31.
- Fulgham PF, Assimos DG, Pearle MS, Preminger GM. Clinical effectiveness protocols for imaging in the management of ureteral calculous disease: AUA technology assessment. *J Urol* 2013;189:1203-13.
- Kim BS, Hwang IK, Choi YW, Namkung S, Kim HC, Hwang WC, *et al.* Low-dose and standard-dose unenhanced helical computed tomography for the assessment of acute renal colic: Prospective comparative study. *Acta Radiol* 2005;46:756-63.
- Riddell J, Case A, Wopat R, Beckham S, Lucas M, McClung CD, *et al.* Sensitivity of emergency bedside ultrasound to detect hydronephrosis in patients with computed tomography-proven stones. *West J Emerg Med* 2014;15:96-100.
- Smith-Bindman R, Aubin C, Bailitz J, Bengiamin RN, Camargo CA Jr., Corbo J, *et al.* Ultrasonography versus computed tomography for suspected nephrolithiasis. *N Engl J Med* 2014;371:1100-10.
- Brisbane W, Bailey MR, Sorensen MD. An overview of kidney stone imaging techniques. *Nat Rev Urol* 2016;13:654-62.
- Jha P, Bentley B, Behr S, Yee J, Zagoria R. Imaging of flank pain: Readdressing state-of-the-art. *Emerg Radiol* 2017;24:81-6.
- Vallone G, Napolitano G, Fonio P, Antinolfi G, Romeo A, Macarini L, *et al.* US detection of renal and ureteral calculi in patients with suspected renal colic. *Crit Ultrasound J* 2013;5 Suppl 1:S3.
- Yilmaz S, Sindel T, Arslan G, Ozkaynak C, Karaali K, Kabaalioglu A, *et al.* Renal colic: Comparison of spiral CT, US and IVU in the detection of ureteral calculi. *Eur Radiol* 1998;8:212-7.
- Patlas M, Farkas A, Fisher D, Zaghal I, Hadas-Halpern I. Ultrasound vs CT for the detection of ureteric stones in patients with renal colic. *Br J Radiol* 2001;74:901-4.
- Ripollés T, Martínez-Pérez MJ, Vizuete J, Miralles S, Delgado F, Pastor-Navarro T. Sonographic diagnosis of symptomatic ureteral

- calculi: Usefulness of the twinkling artifact. *Abdom Imaging* 2013;38:863-9.
29. Ray AA, Ghiculete D, Pace KT, Honey RJ. Limitations to ultrasound in the detection and measurement of urinary tract calculi. *Urology* 2010;76:295-300.
 30. Ahmad SK, Abdallah MM. The diagnostic value of the twinkle sign in color Doppler imaging of urinary stones. *Egypt J Radiol Nucl Med* 2014;45:569-74.
 31. Catalano O, Nunziata A, Altei F, Siani A. Suspected ureteral colic: Primary helical CT versus selective helical CT after unenhanced radiography and sonography. *AJR Am J Roentgenol* 2002;178:379-87.
 32. Moesbergen TC, de Ryke RJ, Dunbar S, Wells JE, Anderson NG. Distal ureteral calculi: US follow-up. *Radiology* 2011;260:575-80.
 33. Preminger GM, Tiselius HG, Assimos DG, Alken P, Buck C, Gallucci M, *et al.* 2007 guideline for the management of ureteral calculi. *J Urol* 2007;178:2418-34.

Appendix A: STONE score

Factors	Points
Sex	
Female	0
Male	2
Timing (pain duration) (h)	
>24	0
6-24	1
<6	3
Origin	
Black	0
Nonblack	3
Nausea	
None	0
Nausea	1
Vomiting	2
Erythrocytes	
Absent	0
Present	3
Possible scores	0-13