

# Results of Operative and Nonoperative Treatment of Rockwood Types III and V Acromioclavicular Joint Dislocation

## A Prospective, Randomized Trial With an 18- to 20-Year Follow-up

Antti Joukainen,<sup>\*†</sup> MD, PhD, Heikki Kröger,<sup>†‡</sup> Prof., Lea Niemitukia,<sup>§</sup> MD, E. Antero Mäkelä,<sup>||</sup> MD, PhD, and Urho Väättäin,<sup>†¶</sup> MD, PhD

*Investigation performed at the Department of Orthopaedics, Traumatology and Hand Surgery, Kuopio University Hospital, Kuopio, Finland*

---

**Background:** The optimal treatment of acute, complete dislocation of the acromioclavicular joint (ACJ) is still unresolved.

**Purpose:** To determine the difference between operative and nonoperative treatment in acute Rockwood types III and V ACJ dislocation.

**Study Design:** Randomized controlled trial; Level of evidence, 2.

**Methods:** In the operative treatment group, the ACJ was reduced and fixed with 2 transarticular Kirschner wires and ACJ ligament suturing. The Kirschner wires were extracted after 6 weeks. Nonoperatively treated patients received a reduction splint for 4 weeks. At the 18- to 20-year follow-up, the Constant, University of California at Los Angeles Shoulder Rating Scale (UCLA), Larsen, and Simple Shoulder Test (SST) scores were obtained, and clinical and radiographic examinations of both shoulders were performed.

**Results:** Twenty-five of 35 potential patients were examined at the 18- to 20-year follow-up. There were 11 patients with Rockwood type III and 14 with type V dislocations. Delayed surgical treatment for ACJ was used in 2 patients during follow-up: 1 in the operatively treated group and 1 in the nonoperatively treated group. Clinically, ACJs were statistically significantly less prominent or unstable in the operative group than in the nonoperative group (normal/prominent/unstable: 9/4/3 and 0/6/3, respectively;  $P = .02$ ) and in the operative type III ( $P = .03$ ) but not type V dislocation groups. In operatively and nonoperatively treated patients, the mean Constant scores were 83 and 85, UCLA scores 25 and 27, Larsen scores 11 and 11, and SST scores 11 and 12 at follow-up, respectively. There were no statistically significant differences in type III and type V dislocations. In the radiographic analysis, the ACJ was wider in the nonoperative than the operative group (8.3 vs 3.4 mm;  $P = .004$ ), and in the type V dislocations (nonoperative vs operative: 8.5 vs 2.4 mm;  $P = .007$ ). There was no statistically significant difference between study groups in the elevation of the lateral end of the clavicle. Both groups showed equal levels of radiologic signs of ACJ osteoarthritis and calcification of the coracoclavicular ligaments.

**Conclusion:** Nonoperative treatment was shown to produce more prominent or unstable and radiographically wider ACJs than was operative treatment, but clinical results were equally good in the study groups at 18- to 20-year follow-up. Both treatment methods showed statistically significant radiographic elevations of the lateral clavicle when compared with a noninjured ACJ.

**Keywords:** acromioclavicular joint dislocation; operative; nonoperative; treatment; prospective randomized study

---

The acromioclavicular joint (ACJ) is susceptible to injury, particularly in young adults. The optimal treatment of Rockwood types III through V ACJ injuries is still controversial.<sup>3,18,25,29,31,32</sup> In the only published randomized

studies comparing operative and nonoperative treatments<sup>2,14</sup> including Rockwood types III through V (Tossy type III) injuries, the authors recommended nonoperative treatment. Some later retrospective studies have also advocated conservative treatment for Rockwood type III injuries,<sup>4</sup> while in other studies, operative treatment has produced better results.<sup>10</sup> Recent evidence suggests that patients with Rockwood type III injuries treated with early

---

The Orthopaedic Journal of Sports Medicine, 2(12), 2325967114560130  
DOI: 10.1177/2325967114560130  
© The Author(s) 2014

This open-access article is published and distributed under the Creative Commons Attribution - NonCommercial - No Derivatives License (<http://creativecommons.org/licenses/by-nc-nd/3.0/>), which permits the noncommercial use, distribution, and reproduction of the article in any medium, provided the original author and source are credited. You may not alter, transform, or build upon this article without the permission of the Author(s). For reprints and permission queries, please visit SAGE's Web site at <http://www.sagepub.com/journalsPermissions.nav>.

coracoclavicular (CC) ligament reconstruction have improved outcomes when compared with those initially treated nonoperatively and followed by operative treatment greater than 3 months postinjury.<sup>27,38</sup> Conservative treatment of Rockwood types IV to VI dislocation has not been recommended.<sup>3,37</sup> Over 150 different reconstruction techniques have been introduced,<sup>3</sup> without any certain knowledge whether it is necessary to treat a patient operatively for a good recovery.<sup>25,31</sup>

Long-term results of operative and nonoperative treatment of Rockwood type III ACJ dislocation are inadequate as well. In 1 study, 30 of 46 conservatively treated patients were reexamined 12.5 years after ACJ dislocation and, despite the subluxed or dislocated ACJ, all patients had a good outcome and functional adaptation was achieved in every case.<sup>23</sup> In a recent follow-up study of 21 years, Rockwood type III ACJ dislocations treated with Kirschner wire (K-wire) fixation and suturing of the ACJ ligaments had a satisfactory result in 92% of patients.<sup>17</sup> In another study, Rockwood type V dislocations were treated with open reduction and polydioxan sulfate (PDS) cerclage augmentation. After a mean follow-up time of 5.8 years, 90% of patients had a good or excellent result.<sup>9</sup>

There are no published long-term studies of nonoperative treatment in Rockwood type V dislocations or long-term prospective studies on the treatment of Rockwood types III and V ACJ dislocation using primary repair and K-wire fixation. We performed a randomized controlled trial to determine the differences in long-term outcomes between K-wire fixation and ACJ ligament suturing and nonoperative treatment of Rockwood types III and V ACJ dislocations. Our hypothesis was that operative and nonoperative treatment methods have different long-term results.

## MATERIALS AND METHODS

At the time of the study initiation, ACJ dislocations were classified using the method described by Tossy et al.<sup>34</sup> The inclusion criteria for the study were as follows: (1) acute, complete dislocation (type III) of the ACJ determined according to the classification described by Tossy et al<sup>34</sup>; (2) no more than 21 days of trauma; (3) no history of ACJ dislocation or other shoulder trauma; (4) no previous surgery on the shoulder; and (5) signed informed consent. Exclusion criteria were as follows: (1) other types (Tossy I-II) of ACJ dislocations and (2) no signed informed consent. After enrollment, patients were randomized into 2 groups, the operative treatment (OT) group and the nonoperative treatment (NOT) group, by a member of the study group (U.V.) using sealed, opaque envelopes.

The Committee on Research Ethics of the Hospital District of North-Savo approved the study. The 40 patients in this study were recruited between May 1989 and July 1991 at the Kuopio University Hospital, Kuopio, Finland. The flow-chart of the study patients is presented in Figure 1. Nineteen patients were randomized to the OT group and 21 to the NOT group.

## Treatment Groups

**Operative Treatment.** Patients were operated on by the orthopaedic surgeons of the Kuopio University Hospital. The OT consisted of an open reduction and fixation of the acromioclavicular joint with 2 smooth Kirschner wires (2 mm in diameter) across the ACJ. The K-wires were bent at the proximal ends, with suturing of the superior ACJ ligament. The positioning of the K-wires was confirmed using perioperative C-arm transillumination. Postoperatively, the shoulder was immobilized with a sling for 4 weeks, and mobilization of the shoulder was allowed after 4 to 6 weeks in a similar manner as in the nonoperative group. The K-wires were removed at 6 weeks postoperatively.

**Nonoperative Treatment.** The nonoperative treatment consisted of immobilizing the injured ACJ in a Kenny-Howard splint<sup>26</sup> for 4 weeks. Patients were encouraged to mobilize the elbow several times per day, and mobilization of the shoulder with pendulum type movements was initiated 4 weeks after injury. Active mobilization of the shoulder was allowed 6 weeks after injury.

## Follow-up

The patients were invited for a clinical follow-up examination at 6 weeks and again later if necessary. The K-wires were removed at 6 weeks postoperatively from patients in the OT group. Systematic follow-up visits were not performed until the long-term follow-up at 18 to 20 years.

All subjects provided informed consent to take part in the long-term follow-up study. The trial was registered at ClinicalTrials.gov (NCT00840593).

Five of 40 patients were deceased at the time of the follow-up, and their data could not be used for the study. Thirty-five patients were invited for follow-up with a letter accepted by the ethics committee. Patients were asked to contact the study nurse to settle the clinical follow-up visit. Twenty-eight patients replied to the request, including 18 in the OT group and 10 patients in the NOT group (Table 1). Seven patients did not reply in spite of repeated invitations for a follow-up visit. We did not have permission to analyze the medical records of patients we

\*Address correspondence to Antti Joukainen, MD, PhD, Department of Orthopaedics, Traumatology and Hand Surgery, Kuopio University Hospital, PO Box 100, 70029, KYS, Kuopio, Finland (e-mail: antti.joukainen@kuh.fi).

† Department of Orthopaedics, Traumatology and Hand Surgery, Kuopio University Hospital, Kuopio, Finland.

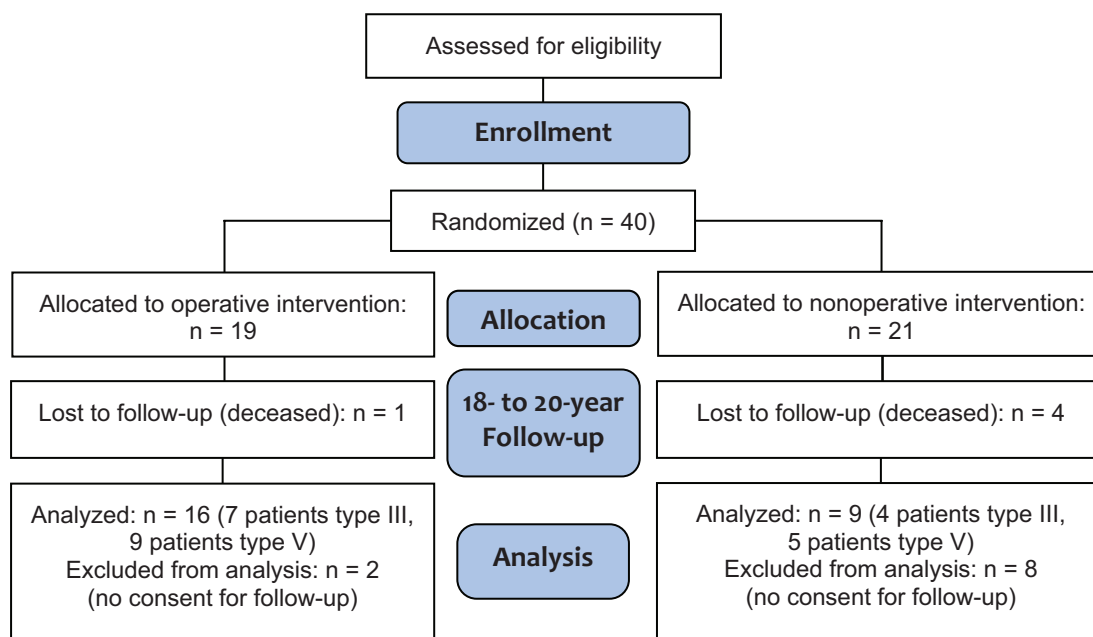
‡ BCRU, Institute of Clinical Medicine, University of Eastern Finland, Finland.

§ Department of Clinical Radiology, Kuopio University Hospital, Kuopio, Finland.

|| Terveystalo Private Hospital, Kuopio, Finland.

¶ Ite-Lasaretti Private Hospital, Kuopio, Finland.

One or more of the authors has declared the following potential conflict of interest or source of funding: A.J. was supported by a grant from the Research Fund of Kuopio University Hospital District (EVO-grant).



**Figure 1.** Flowchart of patients with acromioclavicular joint dislocation included in the 18- to 20-year follow-up study.

**TABLE 1**

Mechanism of Injury in the Acromioclavicular Dislocations for the Operative and Nonoperative Study Groups<sup>a</sup>

Mechanism of Injury, n	Operative Treatment (type III; type V)	Nonoperative Treatment (type III; type V)	Total (type III; type V)
Falling	5 (1; 4)	3 (1; 2)	8 (2; 6)
Bicycle accident	7 (4; 3)	3 (1; 2)	10 (5; 5)
Collision	2 (1; 1)	1 (1; 0)	3 (2; 1)
Traffic	1 (1; 0)	2 (1; 1)	3 (2; 1)
Other	1 (0; 1)	0 (0; 0)	1 (0; 1)

<sup>a</sup>P = not significant, chi-square test.

were unable to reach. Three patients (2 in the OT group and 1 in the NOT group) did not want to visit the hospital for the study, but their medical records were studied and they were interviewed by telephone regarding medical history, without clinical or radiographic studies.

The following data were registered from medical records: mechanism of AC dislocation injury, patient age at control visit, weight (kg), height (m), grading of work (light, heavy work, or retired), presence of delayed surgical treatment of ACJ, complications related to ACJ dislocation, presence of pathologic conditions, or operative treatments for the shoulder.

Patients available for long-term follow-up were interviewed by an educated research nurse, and they had a clinical examination by an orthopaedic surgeon not involved in the initial treatment of the study patients (A.J.).

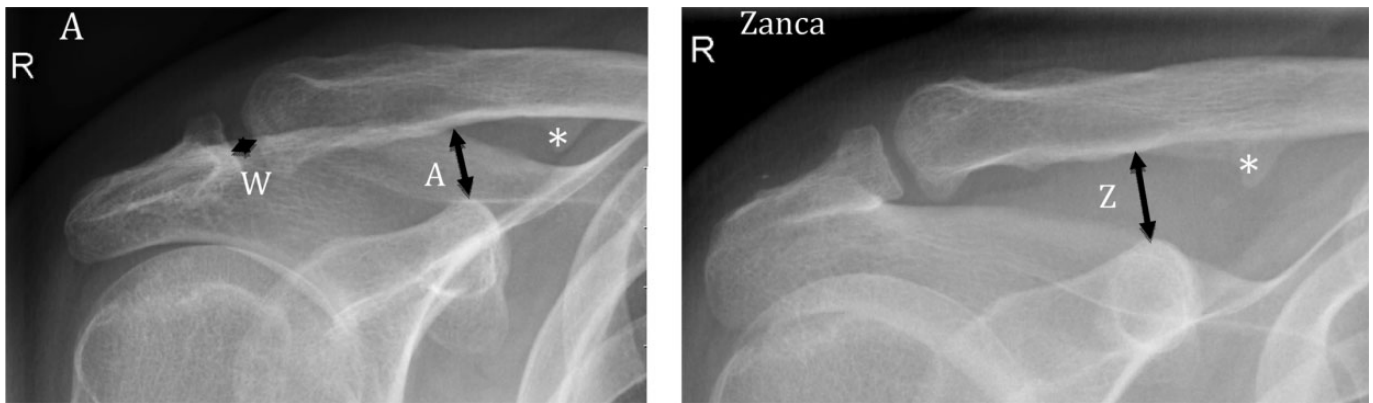Constant (CS),<sup>5,6</sup> University of California at Los Angeles Shoulder Rating Scale (UCLA),<sup>1</sup> Larsen,<sup>14</sup> and Simple Shoulder Test (SST)<sup>16</sup> scores were used to evaluate patients. For the blinded evaluation, the patients were

asked not to disclose their treatment groups. At the follow-up clinical examination, the area of the ACJ, including any scar, was covered by a bandage so that the examiner had no knowledge of the treatment used. In addition, patients were asked to describe their experiences with instability in the ACJ (none, occasionally [ $<10$  times a year], or frequently [ $>10$  times a year]).

The following clinical tests were performed: range of motion of the shoulder (flexion, abduction, and horizontal adduction), palpation of the ACJ (normal, prominent but stable, or unstable), pain on palpation (yes or no), and cross-arm test for pain over the ACJ with maximized passive horizontal adduction of the shoulder (yes/no).

A standardized radiographic evaluation of the injured and contralateral uninjured ACJ was used (Figure 2). The patients did not have a history of contralateral ACJ trauma. Radiographic imaging of the ACJ consisted of anteroposterior, lateral, axial, and Zanca views. The Zanca view was performed by tilting the x-ray beam 10° to 15° toward the cephalic direction and using 50% of the standard shoulder anteroposterior penetration strength.<sup>18</sup>

Radiographs were evaluated by a musculoskeletal radiologist (L.N.). The immediate posttraumatic radiographs were analyzed post hoc, and the Tossy type III ACJ dislocations were graded using Rockwood classifications.<sup>26</sup> Rockwood type III dislocation was defined as having a 100% displacement of the clavicle, type IV dislocation a significant posterior displacement viewed from axillary projection, and type V dislocation a superior displacement exceeding 100%. In the long-term radiographs, the radiologist analyzed the images in a blinded way, with no information as to the primary treatment group (operative or nonoperative). The following variables were analyzed in the radiographs: ACJ width (mm) in the middle of the joint, elevation (mm) of the lateral edge of the clavicle in both



**Figure 2.** A standardized radiograph showing the variables measured in the study patients: acromioclavicular joint (ACJ) width in the middle of the joint (W), elevation of the lateral edge of the clavicle in both anteroposterior (A) and Zanca projection (Z), osteoarthritis in the ACJ, the presence of osteolysis in the lateral clavicle, and the presence of calcification (\*) in coracoclavicular ligaments.

**TABLE 2**  
Characteristics of the 25 ACJ Rockwood Types III and V Dislocation Patients at the 18- to 20-Year Follow-up<sup>a</sup>

Characteristic	Operative Treatment (n = 16)	Nonoperative Treatment (n = 9)	Statistical Significance
Age, y, mean ± SD	53 ± 7.8	54 ± 8.8	NS
Sex, n, female/male	1/15	1/8	
Follow-up, y, mean ± SD	18.7 ± 0.73	19.1 ± 0.47	
Weight, kg, mean ± SD	85 ± 19	86 ± 17	
Height, m, mean ± SD	1.74 ± 0.07	1.75 ± 0.10	
Dominant hand (right/left), n	14/2	8/1	
Dislocated ACJ (right/left), n	10/6	7/2	
Grading of work (light/heavy/retired/without job), <sup>b</sup> n	4/7/4/1	2/4/3/0	
Rockwood classification (type III/V), No. of patients	7/9	4/5	

<sup>a</sup>ACJ, acromioclavicular joint; NS, not significant.

<sup>b</sup>Occupation was divided into 3 groups: (1) retired or not actively working, (2) clerical work, and (3) physically demanding work.

anteroposterior and Zanca projection, osteoarthritis in the ACJ (modified Kellgren-Lawrence [KL] classification, grades 0-4),<sup>12</sup> presence of osteolysis of the lateral clavicle (none, mild, moderate, or severe), and presence of calcification of CC ligaments (yes/no) (Figure 2).

Patient data were collected in the ArtuX database (BCB Medical) and analyzed using methods suitable for a clinical trial regarding comparisons of parallel treatment groups. For independent samples, the Mann-Whitney test was used for parametric variables with no normal distribution. To compare continuous variables in injured and contralateral shoulder radiographs, the Wilcoxon test was applied. The chi-square test was used for nonparametric variables. Statistical significance was set at  $P \leq .05$ . The statistical software used for the analysis was SPSS 19.0 (IBM Corp).

A power analysis was not performed before the initiation of the study, but a post hoc power calculation was performed to recognize appropriate group size. The power calculations were based on the CS values observed in the final analysis. Given that the mean CSs in the study groups were 83 and 85 (SD, ±13) and using  $\alpha = 0.05$  and power = 0.80, we calculated a study group to be statistically significant if the number of subjects per group was 15 or more.

## RESULTS

Twenty-eight patients were successfully contacted, including 18 who underwent OT (2 women) and 10 patients in the NOT group (1 woman), with a mean age of 55 years in both groups. Three of 28 patients did not want to attend the long-term clinical and radiographic follow-up. To our knowledge, on the basis of telephone interviews and medical records, none of these patients had complaints with their injured shoulders. Twenty-five of 35 patients (71%) were examined clinically and radiographically. There were 16 patients in the OT group and 9 in the NOT group.

No statistically significant differences were found in patient characteristics between study groups (Table 2). The right limb was injured in 17 of 25 (68%) cases, and the reason for injury was a bicycle accident or fall in 18 cases (72%).

There was 1 patient in both the operative and nonoperative groups treated with delayed surgery for ACJ: 1 male patient in the operative group needed a reoperation to remove deeply positioned K-wires, and 1 male patient in the nonoperative group was operated on for an unsatisfactory result with the initiated conservative

treatment, having an ACJ resection 1 year after the original ACJ dislocation. None of the other patients needed late ACJ ligament reconstruction or acromioclavicular resection during the 18- to 20-year follow-up. Three patients had shoulder surgery for other reasons: 2 patients in the operative group were operated on for a torn rotator cuff and 1 patient in the nonoperative group had acromioplasty for impingement syndrome.

Complications were reported in medical records and/or in the context of the patient interview at follow-up in 6 cases in the OT group: loss of the optimal position of the K-wire ( $n = 4$ ), broken K-wires ( $n = 1$ ), and superficial wound infection ( $n = 1$ ), which healed with local therapy and peroral antibiotics. The broken K-wires in 1 patient were left inside the clavicle without any long-term harm and could be seen inside the clavicle in the follow-up radiographs. One patient in the nonoperative group had persistent shoulder pain needing ACJ resection 1 year after ACJ dislocation.

In the post hoc radiographic analysis of the initial post-traumatic radiography of the dislocated Tossy type III ACJs, 11 ACJs were determined to have Rockwood type III dislocations and 14 had type V dislocations. There were no Rockwood type IV dislocations. There was no statistical difference in the distribution of the different Rockwood classes between the operative and nonoperative study groups (Table 2). In the statistical analysis of the clinical evaluation, the only variable differentiating between the study groups was the ACJ palpation finding: ACJs were prominent or unstable more commonly in the nonoperative group than in the operative group ( $P = .02$ ) (Table 3) and in the nonoperative subgroup type III ( $P = .03$ ). Two of 16 patients in the operative group had pain on palpation of the ACJ, and these same patients had a positive cross-arm test during clinical examination.

No statistically significant differences in shoulder scores on the CS, UCLA, Larsen, or SST scales were noted between the study groups or between the type III and V subgroups (Table 4). The age- and sex-correlated Constant scores were  $93\% \pm 14\%$  and  $96\% \pm 6.6\%$  in the OT and NOT groups, respectively. Correlated CSs for the OT and NOT groups are also available for subgroups type III ( $88\% \pm 24\%$  and  $99\% \pm 7.4\%$ , respectively) and type V ( $98\% \pm 11\%$  and  $94\% \pm 9.5\%$ , respectively).

In the radiographic analysis, the mean width of the ACJ at long-term follow-up was statistically significantly greater after nonoperative treatment than in the operative group (8.3 vs 3.4 mm, respectively;  $P = .004$ ) (Table 5) and in the type V dislocation subgroup (nonoperative vs operative: 8.5 vs 2.4;  $P = .007$ ). No other statistically significant differences in radiographic variables were noticed between study groups. Radiographic analysis measures were compared with contralateral ACJ measures. ACJ width and elevation of the lateral clavicle, both in anteroposterior and Zanca projection, proved to be significantly greater in the study groups than contralateral ACJs. The presence of ACJ osteoarthritis, osteolysis of the lateral clavicle, or calcification of CC ligaments did not differ significantly between the injured and contralateral ACJ.

## DISCUSSION

In this randomized study, we aimed to examine the difference in long-term results of OT with K-wire fixation and coracoacromial ligament suturing or NOT in Rockwood types III and V ACJ dislocations. The NOT group produced a clinically more prominent or unstable and radiographically wider ACJ than the OT method 18 to 20 years after injury. However, clinical scoring results were equally good, and the occurrence of shoulder disability was no different between the study groups. Our study is the first with a long follow-up time to include both OT and NOT method groups.

In our study, delayed surgical intervention for ACJ dislocation was needed in 1 patient in both the operative and nonoperative study groups (Table 3). In another randomized study comparing operative and conservative treatment of ACJ dislocation, 3 of 40 (8%) patients needed later operative treatment for ACJ dislocation.<sup>14</sup> In the study of Bannister et al,<sup>2</sup> 4 of 33 (12%) conservatively treated and 5 of 27 (19%) operatively treated patients needed delayed operative treatment during 4 years of follow-up. In a large review of 1172 patients, further surgery was needed in 59% of operatively and 6% of nonoperatively treated patients.<sup>22</sup> Our follow-up time was extended, and late surgeries for ACJ concerns were rare in our series.

The modified technique used for operative treatment in this study was first described 70 years ago.<sup>21</sup> Since then, myriad different ACJ reconstruction techniques have been developed.<sup>3</sup> Novel anatomic repairs have been compared with nonanatomic ones in 2 studies favoring anatomic reconstruction<sup>8,33</sup> and autologous graft compared with synthetic graft.<sup>7</sup> Biomechanically, the strongest reconstruction technique has been shown to be locking hook plate fixation.<sup>20</sup> However, there is no clear difference in results to recommend one type of operative repair over another for dislocated ACJ.<sup>3,25</sup> The preferred methods to repair acute ACJ dislocation at our institute are anatomic coracoclavicular reconstruction with bone channels or hook-plate fixation, and for delayed or failed conservative cases, augmentation of the anatomic coracoclavicular ligament reconstruction with an autologous semitendinosus graft and AC ligament reconstruction.<sup>3</sup> The K-wire fixation technique used in the OT group in this study is not used anymore because it has proven to have inadequate stability for fixation.<sup>22</sup>

The nonoperative group of ACJ dislocation patients was treated using a Kenny-Howard reduction splint, which is designed to reduce the dislocated ACJ.<sup>30</sup> Today, the use of the Kenny-Howard splint has declined because of poor patient compliance and lack of evidence of its superiority in conservative treatment.<sup>25</sup> In our study, no complications associated with the use of the reducing splint were noted, but all nonoperatively treated ACJs analyzed showed exceptionally prominent or unstable though painless joints (Table 3).

The Tossy classification<sup>34</sup> was applied in the inclusion criteria for this study. We did a post hoc analysis of the classification of the study patients using the Rockwood classification system.<sup>26</sup> The distribution of Rockwood types III and V dislocations (11 and 14, respectively) in our study was similar to the material in another study including

TABLE 3  
Clinical Results at the 18- to 20-Year Follow-up in Patients With AC Dislocations  
in the Operative and Nonoperative Treatment Groups<sup>a</sup>

	Operative Treatment (n = 16)	Nonoperative Treatment (n = 9)	P Value
Delayed additional surgical treatment for AC joint			NS <sup>b</sup>
No. of patients (%)	1 (6)	1 (11)	
Rockwood type	III	III	
Complications <sup>c</sup>			NS <sup>b</sup>
No. of patients (%)	6 (38)	1 (11)	
Subgroups by Rockwood type, n	III: 2 V: 4	III: 1 V: 0	
Subjective instability experience of the AC joint (none/occasional/frequent)			NS <sup>b</sup>
No. of patients	12/3/1	8/0/1	
Subgroups by Rockwood type, n	III: 4/2/1 V: 8/1/0	III: 4/0/0 V: 4/0/1	
AC joint on clinical examination (normal/prominent/unstable)			
No. of patients	9/4/3	0/6/3	.02 <sup>b</sup>
Subgroups by Rockwood type, n	III: 4/0/3 V: 5/4/0	III: 0/3/1 V: 0/3/2	III: .03 <sup>b</sup> V: NS <sup>b</sup>
Painful AC joint on clinical examination (yes/no)			NS <sup>b</sup>
No. of patients	2/14	0/9	
Subgroups by Rockwood type, n	III: 2/5 V: 0/9	III: 0/4 V: 0/5	
Painful cross-arm test (yes/no)			NS <sup>b</sup>
No. of patients	2/14	0/9	
Subgroups by Rockwood type, n	III: 2/5 V: 0/9	III: 0/4 V: 0/5	
Active flexion, deg, mean ± SD			NS <sup>d</sup>
No. of patients	173 ± 19	177 ± 7.1	
Subgroups by Rockwood type, n	III: 167 ± 26 V: 177 ± 10	III: 178 ± 5.0 V: 176 ± 8.9	
Active abduction, deg, mean ± SD			NS <sup>d</sup>
No. of patients	171 ± 24	174 ± 15	
Subgroups by Rockwood type, n	III: 167 ± 34 V: 174 ± 13	III: 178 ± 5.1 V: 171 ± 20	

<sup>a</sup>AC, acromioclavicular; NS, not significant.

<sup>b</sup>Chi-square test.

<sup>c</sup>Complications: In the operative group: loss of position of the Kirschner wire in 4 cases, broken Kirschner wires in 1 case, superficial wound infection in 1 case. Nonoperative group: AC joint resection due to pain in 1 case 1 year after the injury.

<sup>d</sup>Mann-Whitney test.

patients with Tossy type III dislocation.<sup>28</sup> The mechanisms of injury and demographics of the ACJ dislocation patients were also analyzed and were similar to those in other studies.<sup>4,35,36</sup>

The 18- to 20-year follow-up clinical examinations showed the only statistically significant differing variable to be in the palpation of the ACJ. ACJs were prominent and unstable in all (n = 9) patients in nonoperative treatment, whereas 9 of 16 operatively treated ACJ dislocations were stable on clinical examination. This is in concordance with the results of another study.<sup>4</sup> In the subgroup analysis, nonoperatively treated type III ACJ dislocations were statistically significantly more unstable and prominent, but not in the type V ACJ dislocations. However, the number of patients in these subgroups was less than 15, and given the post hoc power analysis, too small to prove statistical significance. No other variables measured were different between the treatment groups, and patients were

equally satisfied when evaluated according to clinical shoulder scores. Unfortunately, no ACJ-specific scores such as the Taft or ACJ instability scores were used, nor did the authors<sup>4</sup> assess possible cervical and scapular problems, which have been connected to ACJ instability.<sup>11</sup> None of the nonoperative group ACJs were painful, but 2 of the patients in the OT group had painful ACJs, both with palpation and the cross-arm test. These 2 patients in the operative group had KL 0 and KL 1 radiological osteoarthritic classifications in their ACJs and radiographically observed calcification of the AC ligaments but no osteolysis of the lateral clavicle.

In earlier follow-up studies of ACJ dislocations, a 6- to 10-year follow-up of temporary K-wire fixation in Rockwood type III injuries was reported to give good functional results. The mean Constant score was 88 in the follow-up groups of 19 patients.<sup>15</sup> In another recent long-term study, at least 15 years of retrospective analysis of Rockwood

TABLE 4  
Long-Term (18- to 20-Year) Clinical Scoring in Study Patients<sup>a</sup>

Measure	Operative Treatment (n = 16)	Nonoperative Treatment (n = 9)	Total Patients (N = 25)
Constant score (0-100, 100 being the best)	83 ± 16 Type III: 78 ± 21 Type V: 87 ± 9.6	85 ± 7.5 Type III: 87 ± 6.5 Type V: 83 ± 8.4	84 ± 13 Type III: 81 ± 17 Type V: 86 ± 9.2
UCLA score (0-35, 35 being the best)	25 ± 5.4 Type III: 23 ± 6.7 Type V: 27 ± 3.9	27 ± 2.5 Type III: 28 ± 2.6 Type V: 27 ± 2.7	26 ± 4.6 Type III: 25 ± 5.8 Type V: 27 ± 3.4
Larsen score (1-12, 12 being the best)	11 ± 1.0 Type III: 11 ± 1.1 Type V: 11 ± 0.7	11 ± 0.8 Type III: 12 ± 0.6 Type V: 11 ± 0.8	11 ± 0.9 Type III: 11 ± 1.0 Type V: 11 ± 0.8
Simple Shoulder Test (0-12, 12 being the best)	10 ± 2.8 Type III: 9.1 ± 3.8 Type V: 11 ± 1.0	12 ± 0.7 Type III: 12 ± 0.5 Type V: 11 ± 0.9	11 ± 2.3 Type III: 10 ± 3.2 Type V: 11 ± 0.9

<sup>a</sup>Values are reported as mean ± SD. There were no statistically significant differences between the groups (Mann-Whitney test). UCLA, University of California Los Angeles Shoulder Rating Scale.

TABLE 5  
Radiographic Analysis Results of AC Dislocations<sup>a</sup>

	Operative Treatment (n = 16)	Nonoperative Treatment (n = 9)	P Value <sup>b</sup>	Difference Between Contralateral and Injured AC Joint (n = 25)
Measurement, mm, mean ± SD				
AC joint width in the middle of the joint	3.4 ± 2.9 Type III: 4.8 ± 3.9 Type V: 2.4 ± 1.2	8.3 ± 2.3 Type III: 8.1 ± 4.3 Type V: 8.5 ± 8.9	.004 Type III: NS Type V: .007	2.8 ± 3.1 <sup>c</sup>
Elevation of lateral edge of clavicle, AP projection	12.5 ± 3.6 Type III: 11.0 ± 3.4 Type V: 13.6 ± 3.4	13.6 ± 6.2 Type III: 13.0 ± 5.1 Type V: 14.1 ± 7.6	NS	8.2 ± 2.9 <sup>c</sup>
Elevation of lateral edge of clavicle, Zanca projection	11.9 ± 4.3 Type III: 11.7 ± 3.6 Type V: 12.0 ± 5.0	11.1 ± 5.7 Type III: 11.8 ± 7.1 Type V: 10.5 ± 5.1	NS	7.8 ± 3.7 <sup>c</sup>
Osteoarthrosis in the AC joint (KL grade 0/1/2/3/4), n	5/7/3/1/0	0/7/1/1/0	NS	5/14/4/2/0 <sup>d</sup>
Osteolysis of lateral clavicle (none/mild/moderate/severe), n	13/2/0/1	8/1/0/0	NS	21/3/0/1 <sup>d</sup>
Presence of calcification of coracoclavicular ligaments (yes/no), n	6/10	2/7	NS	8/17 <sup>d</sup>

<sup>a</sup>AC, acromioclavicular; AP, anteroposterior; KL, Kellgren-Lawrence; NS, not significant.

<sup>b</sup>Mann-Whitney test.

<sup>c</sup>P ≤ .005, Wilcoxon signed-rank test.

<sup>d</sup>P = not significant, chi-square test.

type V dislocations treated mainly with temporary K-wire fixation showed successful functional results and a mean CS of 90 in both the injured and uninjured contralateral shoulder.<sup>36</sup> Our result, with a mean CS of 84, is slightly lower than in the previous studies. In a long-term study by Lizaar et al,<sup>17</sup> the mean UCLA scores were 31 for the injured and 32 for the uninjured shoulder; these values were also higher than in our study (mean UCLA score, 25 for operative and 27 for nonoperative groups). Mean SST values were at the same level in the study by Lizaar et al<sup>17</sup> and in our study (11.5 vs 11, respectively). We could

not find any other long-term comparative studies including groups with both operative and nonoperative treatment.

Conservative treatment was recommended for ACJ dislocation of Rockwood type I to III in several recent reviews.<sup>3,24,25</sup> There are no long-term studies of Rockwood types IV to V dislocations including a conservative treatment group, but in 1 study with a 6-year follow-up, half of the patients (8/16) with Rockwood type IV or V dislocation who were initially treated conservatively needed late ACJ reconstruction.<sup>19</sup> In another retrospective analysis concerning Rockwood type III dislocations, conservative

treatment resulted in inferior results compared with operative treatment after a mean follow-up of 36 months: The mean CS was 81 in the conservative group and 90 in the operatively treated group.<sup>10</sup> In contrast, a report exists with a 12.5-year follow-up that includes Rockwood type III ACJ dislocations treated nonoperatively with good functional results.<sup>23</sup> Our long-term results with the NOT group are in concordance with the results of Rawes and Dias.<sup>23</sup>

The present study showed that the nonoperative treatment produced a wider ACJ space than the operative treatment, and there was also a statistically significant difference in the type V subgroups (see Table 5). No differences between the OT and NOT groups were found in the vertical position of the lateral end of the clavicle in long-term follow-up. There were no significant differences in ACJ osteoarthritis, osteolysis of the lateral clavicle, or calcinosis of CC ligaments between the study groups in either the injured or the contralateral noninjured shoulder (see Table 5).

Both treatment methods showed a statistically significant radiographic rise of the lateral clavicle when compared with the uninjured ACJ. Obviously, temporary fixation of the ACJ with Kirschner wire was insufficient to restore normal acromioclavicular stability, and an anatomical method of reconstruction may yield different, more satisfying anatomic results.

In our study, complications were more common in the OT group than in the NOT group, but the difference was not statistically significant. In another study with a short follow-up,<sup>4</sup> the most common complications in the operative treatment group were pin migration and unattractive scar, and in the NOT group, all patients were considered to have deformity in the ACJ. In our study, we did not define ACJ deformity as a complication, but using this definition from the other study,<sup>4</sup> all the patients in the NOT group could be described as having a complication of ACJ deformity. However, the deformity did not bother the patients at long-term follow-up. The complication of pin migration was common in our study as in other studies concerning this surgical method of ACJ reconstruction.<sup>4,14</sup>

### Strengths and Limitations

The strengths of this study are its prospective and randomized setup, long follow-up, and comparison groups of OT and NOT methods. Follow-up analysis was strictly conducted.

There are some limitations to the study. The study was underpowered and therefore unable to yield definitive evidence for differences in the treatment groups. The inclusion criteria included all Tossy type III dislocations, meaning variable types of ACJ injuries (Rockwood types III and V), which reduces the subgroups and obscures analysis of the results. Stress panorama views, which have been proposed to better indicate the different classes of ACJ dislocation,<sup>13</sup> were not performed in our study. The shoulder scores selected for this study may not be sensitive for disorders of the ACJ, and other scores such as the Taft or ACJ instability scores developed specifically for ACJ pathology

may have indicated more evident differences between the study groups.

We were unable to examine all patients who were eligible, and so there is a risk of selection bias. Ten of 35 (29%) potential patients were lost to follow-up. Most of these (8/10) were from the nonoperative group. Three patients could be contacted and did not have complaints about their injured shoulder. Seven of 10 could not be contacted at all in spite of repeated invitations to the follow-up visit.

There is no published material on this trial from earlier follow-up time points. The follow-up data were inadequate to include early and mid-term results for this study report. There is therefore a possibility of differences in the results between the study groups in earlier phases, but this cannot be confirmed from our material.

### CONCLUSION

Rockwood types III and V ACJ dislocation treatment with either operative K-wire fixation and coracoacromial ligament suturing or nonoperative treatment gave good long-term functional results. Nonoperative treatment more frequently produced a bony prominence or unstable ACJ still detectable 18 years after injury, but with no additional functional disability for the patient. Further level 1 studies with larger samples of patient material, specifically planned inclusion criteria, anatomic reconstruction techniques, and well-conducted follow-up are needed to determine the optimal treatment method for high-grade ACJ dislocations.

### ACKNOWLEDGMENT

The authors thank research nurse Marja-Liisa Sutinen for her invaluable assistance.

### REFERENCES

1. Amstutz HC, Sew Hoy AL, Clarke IC. UCLA anatomic total shoulder arthroplasty. *Clin Orthop Relat Res.* 1981;(155):7-20.
2. Bannister GC, Wallace WA, Stableforth PG, Hutson MA. The management of acute acromioclavicular dislocation. A randomized prospective controlled trial. *J Bone Joint Surg Br.* 1989;71:848-850.
3. Beitzel K, Cote MP, Apostolakis J, et al. Current concepts in the treatment of acromioclavicular joint dislocations. *Arthroscopy.* 2013; 29:387-397.
4. Calvo E, Lopez-Franco M, Arribas IM. Clinical and radiologic outcomes of surgical and conservative treatment of type III acromioclavicular joint injury. *J Shoulder Elbow Surg.* 2006;15:300-305.
5. Constant CR, Murley AH. A clinical method of functional assessment of the shoulder. *Clin Orthop Relat Res.* 1987;(214):160-164.
6. Constant CR, Gerber C, Emery RJ, Søjbjerg JO, Gohlke F, Boileau P. A review of the Constant score: modifications and guidelines for its use. *J Shoulder Elbow Surg.* 2008;17:355-361.
7. Fauci F, Merolla G, Paladini P, Campi F, Porcellini G. Surgical treatment of chronic acromioclavicular dislocation with biologic graft vs synthetic ligament: a prospective randomized comparative study. *J Orthop Traumatol.* 2013;14:283-290.
8. Fracchini G, Ciampi P, Scotti C, Ballis R, Peretti GM. Surgical treatment of chronic acromioclavicular dislocation: comparison between two surgical procedures for anatomic reconstruction. *Injury.* 2010; 41:1103-1106.



9. Greiner S, Braunsdorf J, Perka C, Herrmann S, Scheffler S. Mid to long-term results of open acromioclavicular-joint reconstruction using polydioxansulfate cerclage augmentation. *Arch Orthop Trauma Surg.* 2009;129:735-740.
10. Gstettner C, Tauber M, Hitzl W, Resch H. Rockwood type III acromioclavicular dislocation: surgical versus conservative treatment. *J Shoulder Elbow Surg.* 2008;17:220-225.
11. Gumina S, Carbone S, Postacchini F. Scapular dyskinesia and SICK scapulas syndrome in patients with chronic type III acromioclavicular dislocation. *Arthroscopy.* 2009;25:40-45.
12. Kellgren JH, Jeffrey MR, Ball J. *The Epidemiology of Chronic Rheumatism, Vol II. Atlas of Standard Radiographs of Osteoarthritis.* Oxford, England: Blackwell Scientific; 1963:1-13.
13. Kim AC, Matcuk G, Patel D, et al. Acromioclavicular joint injuries and reconstructions: a review of expected imaging findings and potential complications. *Emerg Radiol.* 2012;19:399-413.
14. Larsen E, Bjerg-Nielsen A, Christensen P. Conservative or surgical treatment of acromioclavicular dislocation. A prospective, controlled, randomized study. *J Bone Joint Surg Am.* 1986;68:552-555.
15. Leidel BA, Braunstein V, Kirchoff C, Pilotto S, Mutschler W, Biberthaler P. Consistency of long-term outcome of acute Rockwood grade III acromioclavicular joint separations after K-wire transfixation. *J Trauma.* 2009;66:1666-1671.
16. Lippitt S, Harryman DI, Matsen FI. A practical tool for evaluating function: the Simple Shoulder Test. In: L Matsen FA, Fu FH, Hawkins RJ, eds. *The Shoulder: A Balance of Mobility and Stability.* Rosemont, IL: American Academy of Orthopaedic Surgeons; 1992:501-518.
17. Lizaar A, Sanz-Reig J, Gonzalez-Parreno S. Long-term results of the surgical treatment of type III acromioclavicular dislocations: an update of a previous report. *J Bone Joint Surg Br.* 2011;93:1088-1092.
18. Mazzocca AD, Arciero RA, Bicos J. Evaluation and treatment of acromioclavicular joint injuries. *Am J Sports Med.* 2007;35:316-329.
19. Mulier T, Stuyck J, Fabry G. Conservative treatment of acromioclavicular dislocation. Evaluation of functional and radiological results after six years follow-up. *Acta Orthop Belg.* 1993;59:255-262.
20. Nuchtern JV, Sellenschloh K, Bishop N, et al. Biomechanical evaluation of 3 stabilization methods on acromioclavicular joint dislocations. *Am J Sports Med.* 2013;41:1387-1394.
21. Phemister P. The treatment of dislocation of the acromioclavicular joint by open reduction and threaded wire fixation. *J Bone Joint Surg.* 1942;24:166-168.
22. Phillips AM, Smart C, Groom AF. Acromioclavicular dislocation. Conservative or surgical therapy. *Clin Orthop Relat Res.* 1998;(353):10-17.
23. Rawes ML, Dias JJ. Long-term results of conservative treatment for acromioclavicular dislocation. *J Bone Joint Surg Br.* 1996;78:410-412.
24. Reid D, Polson K, Johnson L. Acromioclavicular joint separations grades I-III: a review of the literature and development of best practice guidelines. *Sports Med.* 2012;42:681-696.
25. Ristevski B, McKee MD. Acromioclavicular joint. In: Bhandari M, ed. *Evidence-Based Orthopedics.* Chichester, England: Blackwell; 2012:325-331.
26. Rockwood C, Matsen FI. *Disorders of the Shoulder.* Philadelphia, PA: W. B. Saunders; 1990.
27. Rolf O, Hann von Weyhern A, Ewers A, Boehm TD, Gohlke F. Acromioclavicular dislocation Rockwood III-V: results of early versus delayed surgical treatment. *Arch Orthop Trauma Surg.* 2008;128:1153-1157.
28. Salem KH, Schmelz A. Treatment of Tossy III acromioclavicular joint injuries using hook plates and ligament suture. *J Orthop Trauma.* 2009;23:565-569.
29. Smith TO, Chester R, Pearse EO, Hing CB. Operative versus non-operative management following Rockwood grade III acromioclavicular separation: a meta-analysis of the current evidence base. *J Orthop Traumatol.* 2011;12:19-27.
30. Taft TN, Wilson FC, Oglesby JW. Dislocation of the acromioclavicular joint. An end-result study. *J Bone Joint Surg Am.* 1987;69:1045-1051.
31. Tamaoki MJ, Belloti JC, Lenza M, Matsumoto MH, Gomes Dos Santos JB, Faloppa F. Surgical versus conservative interventions for treating acromioclavicular dislocation of the shoulder in adults. *Cochrane Database Syst Rev.* 2010;(8):CD007429.
32. Tauber M. Management of acute acromioclavicular joint dislocations: current concepts. *Arch Orthop Trauma Surg.* 2013;133:985-995.
33. Tauber M, Gordon K, Koller H, Fox M, Resch H. Semitendinosus tendon graft versus a modified Weaver-Dunn procedure for acromioclavicular joint reconstruction in chronic cases: a prospective comparative study. *Am J Sports Med.* 2009;37:181-190.
34. Tossy JD, Mead NC, Sigmund HM. Acromioclavicular separations: useful and practical classification for treatment. *Clin Orthop Relat Res.* 1963;28:111-119.
35. Verdano MA, Pellegrini A, Zanelli M, Paterlini M, Ceccarelli F. Modified Phemister procedure for the surgical treatment of Rockwood types III, IV, V acute acromioclavicular joint dislocation. *Musculoskelet Surg.* 2012;96:213-222.
36. Virtanen KJ, Remes VM, Tulikoura IT, et al. Surgical treatment of Rockwood grade-V acromioclavicular joint dislocations: 50 patients followed for 15-22 years. *Acta Orthop.* 2013;84:191-195.
37. Warth RJ, Martetschläger F, Gaskill TR, Millett PJ. Acromioclavicular joint separations. *Curr Rev Musculoskelet Med.* 2013;6:71-78.
38. Weinstein DM, McCann PD, McIlveen SJ, Flatow EL, Bigliani LU. Surgical treatment of complete acromioclavicular dislocations. *Am J Sports Med.* 1995;23:324-331.