

CASE REPORT

Open Access

Multiple dermoid sinuses of type Vb and IIIb on the head of a Saint Bernard dog

Anna Perazzi^{1*}, Michele Berlanda¹, Massimo Bucci¹, Silvia Ferro², Roberta Rasotto², Roberto Busetto¹ and Ilaria Iacopetti¹

Abstract

Dermoid sinus, a congenital malformation of neural tube development, has been reported in humans and several animal species including dogs. It is typically found in the dorsal midline and commonly occurs in the Rhodesian Ridgeback breed. A case of multiple dermoid sinuses in the fronto-occipital region is described. An 11-month-old, intact female Saint Bernard dog was presented with a 2 day history of discharge from a large irregular subcutaneous mass in the fronto-occipital region. The dog was otherwise healthy. The dog had two circular skin lesions (approximately 4 × 4 and 4 × 2 cm diameter) surrounded by multiple irregular elevated masses. The masses had multiple small openings on the skin surface with tufts of hair protruding from the apertures. The masses were surgically removed, and the diagnosis of multiple dermoid sinuses was confirmed by histological examination. Histopathological examination showed multiple, variably sized, spherical to tubular cysts expanding the dermis and subcutis. Cysts were filled with hair shafts and lamellar keratin and were lined by a stratified squamous epithelium. Sebaceous and apocrine gland adnexal structures were also observed. To the best of our knowledge, this is the first reported case of multiple dermoid sinuses of two different types in the head of a Saint Bernard dog.

Keywords: Dermoid sinus, Fronto-occipital region, Saint Bernard dog

Background

Dermoid sinus (DS) is a congenital malformation caused by an incomplete separation of the skin and neural tube during embryonic development [1]. This abnormality occurs in humans [2-8], dogs [9-40], cats [32,41-44], horses [45], cattle [46], goats [47], sheep [48] buffalo [49] and camels [50]. A review of canine cases is presented in Table 1. Cutaneous DS has been well-documented in Rhodesian and Thai Ridgeback dogs and their cross breeds [51]. DS is thought to be inherited in Rhodesian Ridgebacks. Some studies concluded that the ridge is an autosomal dominant trait that predisposes for DS [51,52]. Isolated cases of DS have also been reported in other breeds (Table 1) [9-40], without evidence of a genetic predisposition [34,51]. Several authors have reported that DSes are found most frequently in the cervical and thoracic regions [11,14,38] with possible extension to the meninges and subarachnoid

space [9,21,23,32,33,35-37,39,40]. They are less frequently found in the sacral region [38]. Neurological signs may be present if there is communication with the dura mater and subsequent inflammation of the spinal cord [16]. DSes in dogs have also been reported to occur only on the parieto-occipital region of the cranium [14] and on the nose [9-12]. This case report describes an unusual combination of multiple DSes of two different types on the head (fronto-occipital region) of a Saint Bernard dog.

Case presentation

An 11-month-old, 42 kg, intact female Saint Bernard dog was presented with a 2 day history of discharge from a large, irregular swelling in the fronto-occipital region. The owner reported that the dog had scratched the head on trees almost daily since it was a puppy. Palpation of the head elicited a marked pain reaction, but no other clinical signs were observed. The discharge was submitted for bacterial culture and antimicrobial sensitivity test, and a growth of coagulase positive staphylococci was obtained. Routine haematology revealed only a mild leucocytosis ($17.5 \times 10^3/\mu\text{L}$, normal range 5 to $13 \times 10^3/\mu\text{L}$)

* Correspondence: anna.perazzi@gmail.com

¹Department of Animal Medicine, Production and Health, University of Padova, Padova, Italy

Full list of author information is available at the end of the article

Table 1 Clinical cases of canine dermoid sinus reported in the veterinary literature

Location	Breed affected	Type and subtype	References
Nose	American Cocker Spaniel	IVc°	[9]
	American Cocker Spaniel	Ic°	[10]
	Brittany Spaniel	Ic°	[10]
	Dalmatian	Vc*	[11]
	English Bull Terrier	Ic°	[12]
	Golden Retriever	Ic°	[10]
	Shih-tzu	Ic°	[13]
	Springer Spaniel	Ic°	[10]
Head	Rottweiler	IIb and IIIb*	[14]
Cervical region	Borboel	IIa°	[15]
	Chow-Chow	IIa and IIIa°	[16]
	Golden Retriever	IIa°	[17]
	Great Pyrenees dog	IIIa°	[18]
	Rhodesian Ridgeback	Ia, IIa and IIIa°	[19]
	Rhodesian Ridgeback	IIa°	[20]
	Rhodesian Ridgeback	Iva°	[21]
	Rhodesian Ridgeback	IIa°	[22]
	Rhodesian Ridgeback	Iva°	[23]
	Rhodesian Ridgeback	Vla°	[24]
	Rhodesian Ridgeback	IIa°	[25]
	Rhodesian Ridgeback	Va*	[26]
	Rhodesian Ridgeback	Ia°	[27]
	Rhodesian Ridgeback	IIa°	[28]
	Rhodesian Ridgeback	IIa*	[29]
	Rhodesian Ridgeback	Ia°	[30]
	Thoracic region	Boxer	IVa°
Chinese Crested dog		IVa*	[32]
Chow-Chow		IIIa and IIa°	[16]
Rhodesian Ridgeback		Ia, IIa and IIIa°	[19]
Shih-tzu		IVa°	[31]
Shih-tzu		IVa*	[33]
Siberian Husky		IIa°	[34]
Swedish Vallhunds		IVa*	[32]
Swedish Vallhunds		Vla*	[32]
Victorian Bulldog		IVa*	[35]
Yorkshire Terrier		IVa°	[36]
Yorkshire Terrier		IVa*	[37]
Lumbosacral region		English Springer Spaniel	Vla°
Sacrococcygeal region	Rhodesian Ridgeback	Iva°	[39]
	Rhodesian Ridgeback	Ia, IIa and IIIa°	[19]
	Rhodesian Ridgeback	IVa°	[40]

Reported cases of dermoid sinus with anatomical location, breed and type and classification [* = stated by the authors; ° = deduced from the text according with the classifications of Kiwiranta [32] and Bornard [14]].

and biochemistry was unremarkable. Hair was clipped from the area, revealing abnormal skin which covered the area between the right supraorbital rim, the base of the right ear and nape, extending partially into the left fronto-occipital portion of the skull (Figure 1a and 1b). Two large circular skin lesions of approximately 4 × 4 and 4 × 2 cm diameter with serous and purulent exudate were located in the central part of this area. These lesions were surrounded by multiple irregular swollen masses containing multiple small openings on the skin surface with tufts of hair protruding from the apertures. The region overlying the right ear was characterized by a thin and hairless skin (Figure 1a and 1b). A tentative diagnosis of multiple cutaneous DSes was made despite the atypical location, breed and the large number of lesions. The dog was treated with amoxicillin-clavulanic acid (Synulox, Pfizer A.H., New York, USA) at a dose of 20 mg/kg twice daily *per os*, combined with enrofloxacin (Baytril, Bayer, Leverkusen, Germany) at a dose of 5 mg/kg once daily *per os* starting 3 days before surgical removal of the abnormal tissue. General anaesthesia with the dog positioned in ventral recumbency were induced and the area aseptically prepared and draped. An incision allowing wide exposure of the tissue and blunt dissection was made. After complete excision of the lesion, two Penrose drains were placed and the wound was sutured. A small part of the incision overlying the right ear had to be left to heal by secondary intention to avoid excessive traction of sutures.

Postoperative analgesia and antibiotic treatment were administered and a light bandage was applied for the first two weeks.

The excised tissue appeared on cut section to be formed by multiple adjacent dermal and subcutaneous cysts with no apparent connections (Figure 2). Cysts were filled with hair, keratin, and waxy purulent fluid. The overlying skin had several epidermal invaginations with a dense tuft of hairs frequently protruding from them. Resected tissue was processed for routine histopathology.

Multiple, variably sized, spherical to tubular cysts expanding the dermis and subcutis were seen histologically. Cysts were filled with hair shafts and lamellar keratin and were lined by a stratified squamous epithelium with the granular layer occasionally evident (Figure 3). Cysts were surrounded by a thin rim of collagen bundles that tended to run parallel to the cyst walls (Figure 4). Within this collagen, multiple folliculosebaceous units radiated perpendicularly from the cyst walls. Occasionally, cysts communicated with the overlying epidermis via a pore (Figure 5). The surrounding epidermis was slightly compressed, atrophic, and multifocally ulcerated. The dermis at the periphery showed moderate fibrosis, dislocation of adnexa, and moderate multifocal granulomatous inflammation with a few foreign body type multinucleated giant cells surrounding keratin debris. A final histopathologic diagnosis of multiple DSes was made.

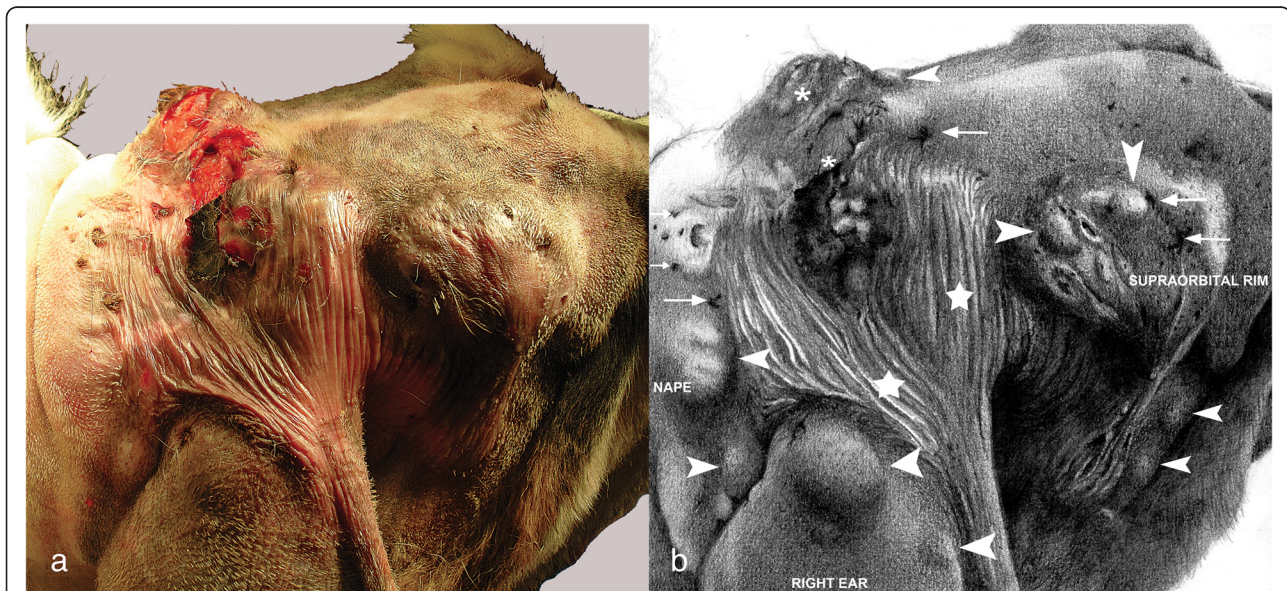

Figure 1 Photograph and illustration of fronto-occipital region of the dog. **a)** Dorso-lateral view of head of dog (mouth on the right side, neck on the left side). The lesions involve an area between the right supraorbital rim, the base of the right ear and nape, extending partially into the fronto-occipital area on the left. **b)** Illustration of the same photograph that better shows the distribution and the tridimensional characters of the nodular lesions. In the center are two big circular skin lesions (*asterisks*) draining serous and purulent material, surrounded by multiple irregular swollen masses (*arrow heads*) and multiple small openings on the skin surface with tufts of hair protruding from the skin apertures (*arrows*). There is an extensive area around and under the ulceration characterized by thin and translucent glabrous epidermis (*stars*).

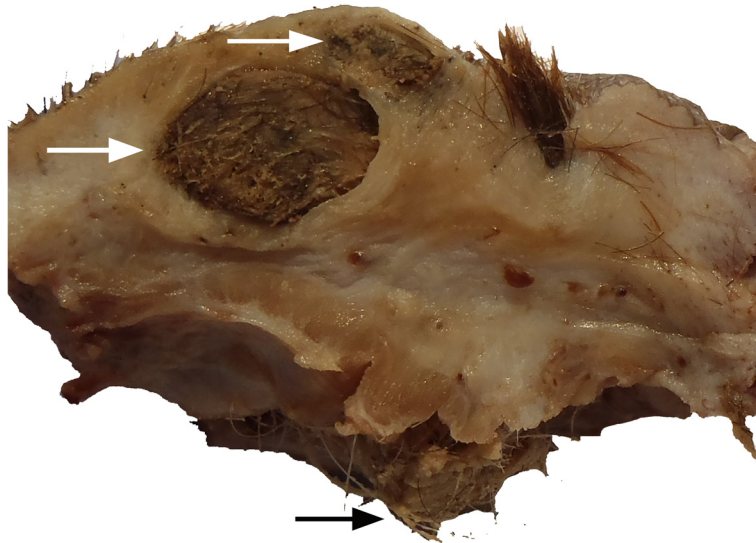

Figure 2 Macroscopic aspect of the cystic skin at cut surface. Formalin fixed specimen. White arrows indicate two subcutaneous cysts. At the right of the cysts a tuft of hair protruding from a sinus toward the surface is evident. Ectopic hairs are evident (black arrow) in the subcutaneous tissue. Skin and subcutis, dog.

At a 6-month follow-up, the patient appeared to be in good health and the owner reported no further problems with head scratching or skin sensitivity.

Discussion and conclusions

The term DS is generally considered to be synonymous with dermoid cyst and pilonidal cyst [16,23,26,53-55]. However, some authors recently proposed that a distinction should be made in dogs and cats, as it is done in humans, between dermoid cysts and DSes based on the presence in

the latter of a connection to the skin [4,27,56,57]. Similarly, other authors identified different types of DS in dogs and considered dermoid cyst as a specific type of DS lacking an opening on the skin [19,26,35,55]. Based on the extent of penetration into the subcutaneous tissue, four types of DSes were initially recognized in veterinary medicine: type I extends ventrally as a cylindrical sac attached to the supraspinous ligament, type II consists of a sac-like portion that is more superficial than that of type I and is attached to the ligament by a fibrous band, type III is made up of a

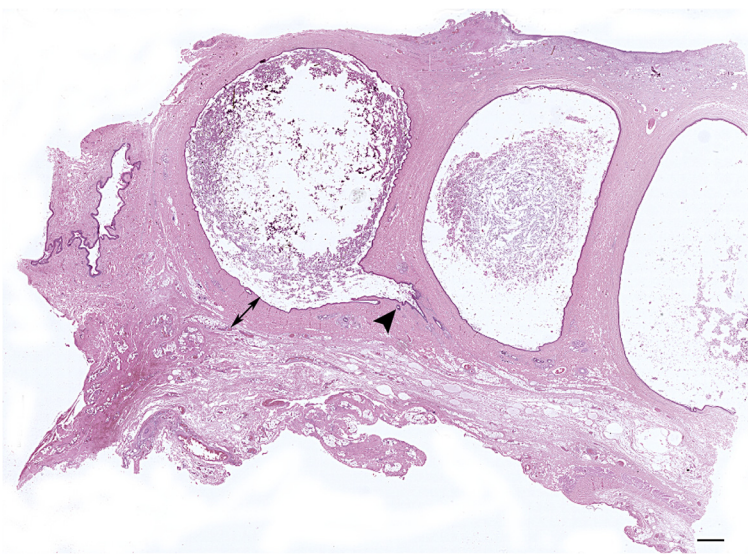


Figure 3 Microphotograph of adjacent dermoid cysts. The figure shows multiple subcutaneous cysts embedded in underling dermis (double headed arrow). The arrow head point at a follicular unit opening in the cyst. The overlying skin is ulcerated with no adnexa. Skin and subcutis, dog. Bar = 1000 μ m, haematoxylin and eosin stain.

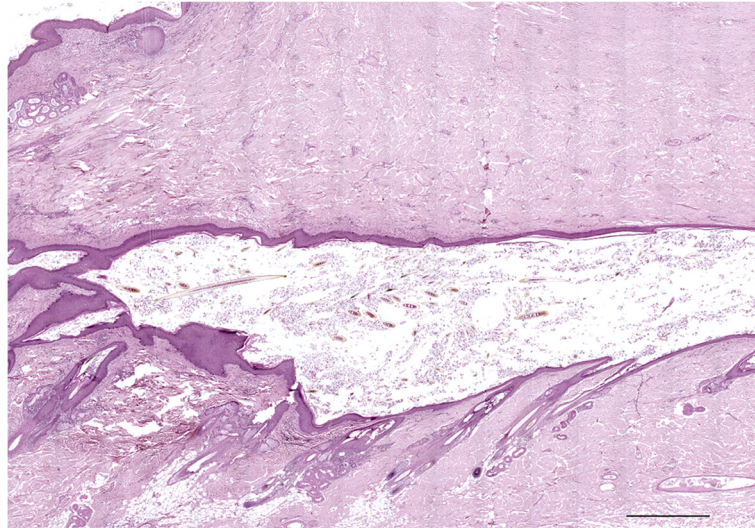


Figure 4 Histological characteristics of the wall cyst. A portion of a cyst with keratin and several hair shafts in the lumen. The cyst wall at the bottom of the figures contains numerous radial folliculosebaceous units that open in to the cyst. The dermis over the cyst is fibrotic without hair follicles. On the upper left corner is evident a small portion of the wall of another cyst. Deep dermis and subcutis, dog. Bar = 1000 μ m, haematoxylin and eosin stain.

superficial sac with no attachment to the supraspinous ligament and type IV extends to the spinal canal and is attached to the dura mater [19]. Later, two other types of DS, type V [16] and type VI [32], were introduced. Type V was described as a true dermoid cyst consisting of a closed epithelial-lined sac difficult to detect via palpation of the skin [57]. This can be considered a more accurate use of the term 'dermoid cyst' since fistulous tract formation or connection to the epidermis is absent. In type VI the open sinus tract reaches the level of the supraspinous ligament and connects via a fibrous cord without a lumen to the

dura mater [35]. Based on the anatomical location, all these types of DS were recently further classified in three subtypes: subtype "a" (dorsal midline), subtype "b" (head, excluding nose), and subtype "c" (nose) [14]. DSes described in veterinary literature according to classifications of Kiwiranta [32] and Bornard [14], their localization, and affected breeds are summarized in Table 1 [9-40].

Based on the multiplicity of the lesions and atypical localization, we classified the present case as a combination of DSes type Vb and type IIIb. To the best of our knowledge, this is the first report of a case of different

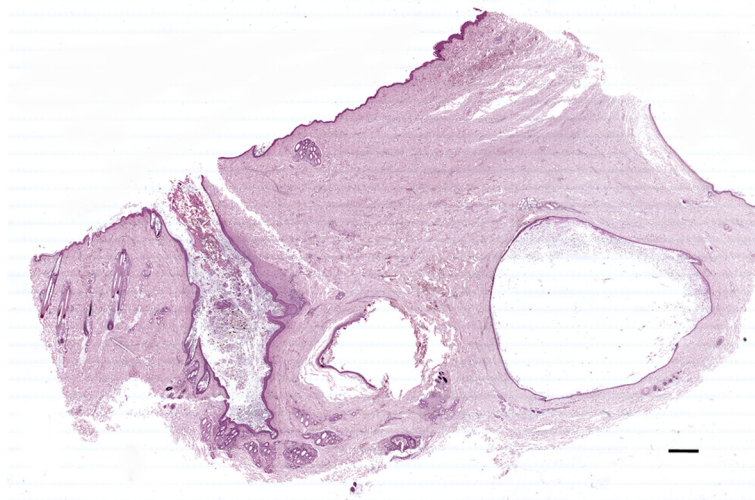


Figure 5 Microphotograph of a dermoid sinus. The figure shows on the left an open sinus surrounded by follicular units, and on the right two deep cysts. The dermis above the cysts contains few or no adnexa, and the epidermis is thin with an abrupt transition to hyperplastic epidermis on the right of the section. Skin and sub-cutis, dog. Bar = 1000 μ m, haematoxylin and eosin stain.

types of DS on the head in a Saint Bernard dog. In the veterinary literature, there are only two other studies that described true cutaneous dermoid cysts (DS type V) in dogs [11,26] and neither of them were of subtype b. Our case is also unusual for its presentation on the head, for the breed affected and the multiplicity of the lesions, a pattern rarely described in dogs or humans [6,14,16,19]. DS is reported as a congenital or acquired lesion [3,6,41]. Considering that the dog described here was 11-months-old, a congenital disorder was suspected. Even if DSeS are usually diagnosed at birth, in some cases they are asymptomatic initially and discovered later in life when they become distended or infected [41]. The owner in this case complained about the swelling only when the discharge became visible, and the external openings were seen only after shaving the area.

Histopathology was necessary to confirm the clinical impression [58]. The most important differential diagnoses were follicular infundibular cyst, folliculosebaceous hamartoma and trichofolliculoma [53]. Folliculosebaceous hamartoma was ruled out because randomly distributed sebaceous lobules are usually more evident. In a trichofolliculoma, the epithelium lining the cyst should have some signs of isthmus/matrical differentiation that was lacking in our case. Distinction from a follicular infundibular cyst can sometimes be problematic. In this case a DS was diagnosed because the folliculosebaceous units radiating from the cyst wall were oriented perpendicular to it, while hair follicles surrounding follicular infundibular cysts usually maintain the normal perpendicular orientation to the epidermis. In addition, the concentric arrangement of the surrounding collagen, well evident in our case, is typical of DS and not present in infundibular cysts [53]. In conclusion, this appears to be the first report of multiple DSeS types IIIb and Vb in a young Saint Bernard dog.

Competing interests

The authors declare that they have no competing interests.

Authors' contributions

AP and MBe conceived of the study and participated in its design and coordination and helped to draft the manuscript. Mbu did the clinical investigation. SF and RR performed the histopathologic examination and interpretation. Il made an intellectual contribution and reviewed the paper. RB has given final approval of the version to be published. All authors read and approved the final manuscript.

Acknowledgements

Dr. L. Finotti is acknowledge for the illustration and Dr. D Gillette for her technical assistance in editing our manuscript.

Author details

¹Department of Animal Medicine, Production and Health, University of Padova, Padova, Italy. ²Department of Comparative Biomedicine and Food Science, University of Padova, Padova, Italy.

Received: 31 May 2013 Accepted: 22 August 2013

Published: 5 September 2013

References

1. Miller WH, Griffin CE, Campbell K: **Congenital and hereditary defects**. In *Muller & Kirk's small animal dermatology*. 7th edition. Edited by Miller WH, Griffin CE, Campbell K. Philadelphia, PA, USA: W. B. Saunders; 2012:583–584.
2. Rinna C, Reale G, Calafati V, Calvani F, Ungari C: **Dermoid cyst: unusual localization**. *J Craniofac Surg* 2012, **23**:392–394.
3. Tari AS, Eshraghi B, Toraci HR: **Dermoid cyst of the frontal bone: a case report**. *Iran J Ophthalmol* 2011, **23**:57–59.
4. Parag P, Prakash PJ, Zachariah N: **Temporal dermoid – an unusual presentation**. *Pediatric Surg Int* 2001, **17**:77–79.
5. Hong SW: **Deep frontotemporal dermoid cyst presenting as a discharging sinus: a case report and review of literature**. *Br J Plast Surg* 1998, **51**:255–257.
6. Yamaki T, Higuchi R, Sasaki K, Nozaki M: **Multiple dermoid cysts on the forehead**. *Scand J Plast Reconstr Hand Surg* 1996, **30**:321–324.
7. Niederhagen B, Reich RH, Zentner J: **Temporal dermoid with intracranial extension: report of a case**. *J Oral Maxillofac Surg* 1998, **56**:1352–1354.
8. Meyer DR, Lessner AM, Yeatts RP, Linberg JV: **Primary temporal fossa dermoid cysts**. *Ophthalmology* 1999, **106**:342–349.
9. Bailey TR, Holmberg DL, Yager JA: **Nasal dermoid sinus in an American Cocker Spaniel**. *Can Vet J* 2001, **42**:213–215.
10. Anderson DM, White RAS: **Nasal dermoid sinus cysts in the dog**. *Vet Surg* 2002, **31**:303–308.
11. Van der Peijl GJW, Schaeffer IGF: **Nasal dermoid cyst extending through the frontal bone with no sinus tract in a Dalmatian**. *J Small Anim Pract* 2011, **52**:117–120.
12. Burrow RD: **A nasal dermoid sinus in an English Bull Terrier**. *J Small Anim Pract* 2004, **45**:572–574.
13. Sturgeon C: **Nasal dermoid sinus cyst in a Shih Tzu**. *Vet Rec* 2008, **163**:219–220.
14. Bornard N, Pin D, Carozzo C: **Bilateral parieto-occipital dermoid sinuses in a Rottweiler**. *J Small Anim Pract* 2007, **48**:107–110.
15. Penrith ML, Van Schouwenburg S: **Dermoid sinus in a Boerboel bitch**. *J S Afr Vet Assoc* 1994, **65**:38–39.
16. Booth MJ: **Atypical dermoid sinus in a Chow Chow dog**. *J S Afr Vet Assoc* 1998, **69**:102–104.
17. Corneigliani L, Jommi E, Vercelli A: **Dermoid sinus in a golden retriever**. *J Small Anim Pract* 2001, **42**:514–516.
18. Camacho AA, Lau JL, Valeri V, Valeri FV, Nunes N: **Dermoid sinus in a Great Pyrenees dog**. *Brazil J Vet Res Anim Sci* 1995, **32**:170–172.
19. Mann GE, Stratton J: **Dermoid sinus in the Rhodesian Ridgeback**. *J Small Anim Pract* 1966, **7**:631–642.
20. Antin IP: **Dermoid sinus in a Rhodesian Ridgeback dog**. *J Am Vet Med Assoc* 1970, **157**:961–962.
21. Gammie JS: **Dermoid sinus removal in a Rhodesian Ridgeback dog**. *Can Vet J* 1986, **27**:250–251.
22. Marks SL, Harari J, Dernel WS: **Dermoid sinus in a Rhodesian Ridgeback**. *J Small Anim Pract* 1993, **34**:356–358.
23. Lambrechts N: **Dermoid sinus in a crossbred Rhodesian Ridgeback dog involving the second cervical vertebra**. *J S Afr Vet Assoc* 1996, **67**:155–157.
24. Lambrechts N: **Dermoid sinus requiring partial dorsal laminectomy in two crossbred Rhodesian Ridgeback dogs**. *Proc 8th Ann Meet ECVS: 2–4 July 1999; Brugge 1999*:203.
25. Lanore D, Debut C, Colnard S: **Dermoid sinuses on a Rhodesian Ridgeback bitch**. *Point Vet* 1999, **30**:55–57.
26. Tshamala M, Moens Y: **True dermoid cyst in a Rhodesian Ridgeback**. *J Small Anim Pract* 2000, **41**:352–353.
27. Miwa Y, Nishimura R, Ishida Y, Sasaki Y, Ogawa N: **Dermoid sinus in a Rhodesian Ridgeback**. *Jpn J Vet An Surg* 2002, **33**:9–13.
28. Davies ESS, Fransson BA, Gavin PR: **A confusing magnetic resonance imaging observation complicating surgery for a dermoid cyst in a Rhodesian Ridgeback**. *Vet Radiol Ultrasound* 2004, **45**:307–309.
29. Lepera SD, Bellezza E: **Il seno dermoide nel Rhodesian Ridgeback**. *Bollettino AIVPA* 2007, **3**:13–19.
30. Rahal S, Mortari AC, Yamashita S, Filho MM, Hatschbac E, Sequeira JL: **Magnetic resonance imaging in the diagnosis of type 1 dermoid sinus in two Rhodesian Ridgeback dogs**. *Can Vet J* 2008, **49**:871–876.
31. Selcer EA, Helman RG, Selcer RR: **Dermoid sinus in a Shih Tzu and a Boxer**. *J Am Anim Hosp Assoc* 1984, **20**:634–636.
32. Kiviranta AM, Lappalainen AK, Hagner K, Jokinen T: **Dermoid sinus and spina bifida in three dogs and a cat**. *J Small Anim Pract* 2011, **52**:319–324.

33. Colon JA, Maritato KC, Mauterer JV: **Dermoid sinus and bone defects of the fifth thoracic vertebrae in a Shih-Tzu.** *J Small Anim Pract* 2007, **48**:180.
34. Corneigliani L, Ghibaudo G: **A dermoid sinus in a Siberian Husky.** *Vet Dermatol* 1999, **10**:47–49.
35. Motta L, Skerritt G, Denk D, Leeming G, Saulnier F: **Dermoid sinus type IV associated with spina bifida in a young Victorian Bulldog.** *Vet Rec* 2012, **170**:127.
36. Fatone G, Brunetti A, Lamagna F, Potena A: **Dermoid sinus and spinal malformations in a Yorkshire Terrier: diagnosis and follow-up.** *J Small Anim Pract* 1995, **36**:178–180.
37. Bowens AL, Ducote JM, Early PJ: **What is your neurologic diagnosis?** *J Am Vet Med Assoc* 2005, **227**:713–715.
38. Pratt JNJ, Knottenbelt CM, Welsh EM: **Dermoid sinus at the lumbosacral junction in an English Springer Spaniel.** *J Small Anim Pract* 2000, **41**:24–26.
39. Lord LH, Cawley AJ, Gilray J: **Mid-dorsal dermoid sinuses in Rhodesian Ridgeback dogs - a case report.** *J Am Vet Med Assoc* 1957, **131**:515–518.
40. Kása F, Kása G, Kussinger S: **Dermoid sinus in a Rhodesian Ridgeback.** *Tierarztl Prax* 1992, **20**:628–631.
41. Akhtardanesh B, Kheirandish R, Azari O: **Dermoid cyst in a Domestic Shorthair cat.** *Asian Pac J Trop Biomed* 2012, **2**:247–249.
42. Fleming JM, Platt SR, Kent M, Freeman AC, Schatzberg SJ: **Cervical dermoid sinus in a cat: case presentation and review of the literature.** *J Feline Med Surg* 2011, **13**:992–996.
43. Tong T, Simpson DJ: **Case report: spinal dermoid sinus in a Burmese cat with paraparesis.** *Aust Vet J* 2009, **87**:450–454.
44. Rochat MC, Campbell GA, Panciera RJ: **Dermoid cysts in cats: two cases and a review of the literature.** *J Vet Diagn Invest* 1996, **8**:505–507.
45. Hillyer LL, Jackson AP, Quinn GC, Day MJ: **Epidermal (infundibular) and dermoid cysts in the dorsal midline of a three-year-old Thoroughbred-cross gelding.** *Vet Dermatol* 2003, **14**:205–209.
46. Baird AN, Wolfe DF, Groth AH: **Dermoid cyst in a bull.** *J Am Vet Med Assoc* 1993, **202**:298.
47. Gamlem T, Crawford TB: **Dermoid cysts in identical locations in a doe goat and her kid.** *Vet Med Small Anim Clin* 1977, **72**:616–617.
48. Stelmann UJP, da Silva AA, De Souza BG, De Oliveira GF, De Mello EFRB, De Souza GCJ, Calderon Gonçalves R, Hess TM: **Dermoid cyst in sheep - a case report.** *Rev Bras Med Vet* 2012, **34**:133–136.
49. Dhablania DC, Gupta PP: **Cutaneous dermoid cyst in a buffalo heifer.** *Indian Vet J* 1979, **56**:798–799.
50. Oryan A, Hashemnia M, Mohammadalipour A: **Dermoid cyst in camel: a case report and brief literature review.** *Comp Clin Pathol* 2012, **21**:555–558.
51. Hillbertz NH, Isaksson M, Karlsson EK, Hellmén E, Rosengren Pielberg G, Savolainen P, Wade CM, Von Euler H, Gustafson U, Hedhammar A, Nilsson M, Lindblad-Toh K, Andersson L, Andersson G: **Duplication of FGF3, FGF4, FGF19 and ORAOV1 causes hair ridge and predisposition to dermoid sinus in Ridgeback dogs.** *Nat Genet* 2007, **39**:1318–1320.
52. Hillbertz NH, Andersson G: **Autosomal dominant mutation causing the dorsal ridge predisposes for dermoid sinus in Rhodesian Ridgeback dogs.** *J Small Anim Pract* 2006, **47**:184–188.
53. Gross TL, Ihrke PJ, Walder EJ, Affolter VK: **Epidermal tumors.** In *Skin disease of the dog and cat. Clinical and histopathologic diagnosis*. 2nd edition. Edited by Gross TL, Ihrke PJ, Walder EJ, Affolter VK. Oxford, UK: Blackwell Science; 2005:566–567.
54. Weiss E, Frese K: **Tumors of the skin.** *Bull World Health Organ* 1974, **50**:79–100.
55. Miller L, Tobias K: **Dermoid sinuses: description, diagnosis, and treatment.** *Compend Contin Edu Pract Vet* 2003, **25**:295–301.
56. Shehadi JA, Alorainy IA, Johnston KM: **Temporal dermoid cyst with a partial dermal sinus tract.** *Can J Neurol Sci* 1999, **26**:321–324.
57. Hillbertz NH: **Inheritance of dermoid sinus in the Rhodesian Ridgeback.** *J Small Anim Pract* 2005, **46**:71–74.
58. Abramo F, Pratesi F, Cantile C, Sozzi S, Poli A: **Survey of canine and feline follicular tumors and tumor-like lesions in central Italy.** *J Small Anim Pract* 1999, **40**:479–481.

doi:10.1186/1751-0147-55-62

Cite this article as: Perazzi et al.: Multiple dermoid sinuses of type Vb and IIIb on the head of a Saint Bernard dog. *Acta Veterinaria Scandinavica* 2013 **55**:62.

Submit your next manuscript to BioMed Central and take full advantage of:

- Convenient online submission
- Thorough peer review
- No space constraints or color figure charges
- Immediate publication on acceptance
- Inclusion in PubMed, CAS, Scopus and Google Scholar
- Research which is freely available for redistribution

Submit your manuscript at
www.biomedcentral.com/submit

