

Predominance of caudate nucleus lesions in acute ischaemic stroke patients with impairment in language and speech

E. O. Grönholm^a, M. C. Roll^b, M. A. Horne^b, P. C. Sundgren^c and A. G. Lindgren^{a,d}

^aDepartment of Clinical Sciences Lund, Neurology, Lund University, Lund; ^bDepartment of Linguistics and Phonetics, Lund University, Lund; ^cDepartment of Diagnostic Radiology, Lund University, Lund; and ^dDepartment of Neurology and Rehabilitation Medicine, Skåne University Hospital, Lund, Sweden

Keywords:

basal ganglia, caudate nucleus, language, MRI, speech, stroke

Received 1 April 2015

Accepted 2 July 2015

European Journal of Neurology 2016, **23**: 148–153

doi:10.1111/ene.12822

Background and purpose: Whereas traditional views of language processing in the brain have assumed that the language function is concentrated to a limited number of cortical areas (Broca's and Wernicke's areas), current knowledge points at a much more complex system of language and speech processing involving many brain areas, both cortical and subcortical. The purpose of the current study was to make an unbiased assessment of which cerebral areas are affected in first-ever acute ischaemic stroke patients identified as having language and speech impairments according to the National Institutes of Health Stroke Scale (NIHSS).

Methods: Data from 34 patients with language and speech impairment, with a score of 1–3 on item 9 of the NIHSS, following ischaemic stroke were collected from the Lund Stroke Register. Magnetic resonance images acquired up to 20 days after stroke onset were used to create an overlap lesion image using MRICron software.

Results: The classical language areas, Wernicke's and Broca's areas, were affected in less than one-fourth of the patients. The most frequently affected region was a subcortical region – the left caudate nucleus and the adjacent corona radiata.

Conclusions: These findings contribute to the growing body of evidence that the basal ganglia have a crucial role in the control over language and speech processing.

Introduction

Stroke and consequential damage to the brain can cause disturbances in different language functions. Lesions to Wernicke's area (the posterior section of the superior temporal gyrus in the dominant hemisphere) have long been known to impair language comprehension [1], whilst damage to Broca's area (part of the inferior frontal gyrus of the dominant hemisphere) has been observed to impair the production of language [2–4]. However, in recent decades studies have shown that several other areas of the brain, including both right and left hemispheres of the

cerebral cortex as well as subcortical areas such as the basal ganglia, are involved in language and speech processing [3,5–9]. Indeed, it has been proposed that different kinds of cognitive and motor processing that take place in the cerebral cortex are controlled by corresponding structures in the basal ganglia that are connected to the cortex by discrete neural circuits [10]. A model of language processing assuming this kind of connectivity between cortical and subcortical areas has been presented [11].

The aim of the current study was to make an unbiased assessment of the brain areas affected in patients reported to have difficulties processing language and speech as a consequence of ischaemic stroke. To do this, magnetic resonance (MR) brain images from patients included in a randomly selected

Correspondence: A. G. Lindgren, Department of Clinical Sciences Lund, Neurology, Lund University, Lund S-221 85, Sweden (tel.: 046 17 14 24; fax: 046 15 89 19; e-mail: Arne.Lindgren@med.lu.se).

group of individuals with first-ever ischaemic stroke and a positive score for language impairment in the National Institutes of Health Stroke Scale (NIHSS) were evaluated.

Methods

Subjects

Thirty-four patients with a first-ever ischaemic stroke were included in this retrospective study which was approved by the Regional Ethics Committee in Lund, Sweden. Subjects' data were retrieved from a 2-year period of the Lund Stroke Register at Skåne University Hospital, Lund. The Lund Stroke Register includes all first-ever stroke patients in the local catchment area of Skåne University Hospital who have been referred to the hospital with a stroke [12]. The criteria for inclusion in the present study were as follows: (i) ischaemic stroke, (ii) written informed consent, (iii) diffusion-weighted magnetic resonance imaging (DW-MRI) examination within 20 days of stroke onset and (iv) a score of 1–3 on item 9 of the NIHSS. The NIHSS is routinely used in the acute stage of patient treatment to quantify the degree of impairment caused by an ischaemic stroke. Item 9 concerns language functions, where a score of 0 represents no obvious language deficit and a score of 3 represents complete inability to speak or produce speech. It does not, however, further categorize the language deficit. Exclusion criteria were as follows: (i) no ischaemic stroke confirmed by DW-MRI or (ii) the patient was deemed comatose in the acute stage, thereby automatically being assigned a score of 3 on item 9 of the NIHSS. After applying the inclusion and exclusion criteria, 34 patients of an initial total of 925 patients remained.

Imaging methods

The structural MR images analysed in the present study were from scans carried out as part of a routine clinical investigation of the patients' strokes. All included patients underwent conventional MRI of the brain without contrast administration on a 1.5 T MR scanner (Philips Medical Systems, Best, The Netherlands) with the sequences sagittal T2-weighted images (SE, TR/TE 4240/100 ms), axial fluid-attenuated inversion recovery (FLAIR) (IR, TR/TE 11 000/140 ms), axial T2-weighted fast field echo (FFE) (TR/TE 699/23 ms, flip angle 18°), DW imaging ($b = 0$ ms, $b = 1000$ ms, TR/TE 2751/83 ms, flip angle 90°, acquisition matrix 128, slice thickness 5 mm, slice distance 6 mm) or on a 3.0 T MR scanner (Philips Medi-

cal Systems) with the sequences sagittal T2-weighted images (SE, TR/TE 3000/80 ms), axial FLAIR (TR/TE 12 000/140 ms), axial T2-weighted FFE (TR/TE 504/16 ms), DW imaging ($b = 0$ ms, $b = 1000$ ms, TR/TE 2255/55 ms, flip angle 90°, acquisition matrix 140, slice thickness 5 mm, slice distance 6 mm).

Image interpretation

The MR images were reviewed by three of the authors, one of whom is an experienced neuroradiologist, and lesion location was determined by consensus. The identified lesions were defined on the DW sequences and were manually drawn on the ICBM 2009a Nonlinear Symmetric $1 \times 1 \times 1$ mm T1-weighted template supplied by McConnell Brain Imaging Center (Montreal, Canada), using MRICron software [13]. For each patient, lesions on the MR image were drawn onto the closest corresponding slice on the template, using slices -40, -32, -24, -16, -8, 0, 8, 16, 24, 32, 40, 50, 60. An overlap lesion plot of all patients was created using MRICron. The method is illustrated in Fig. 1.

Results

Thirty-four patients meeting the criteria were identified. Sixteen were female and 18 male. The median age was 72 (range 20–77) years. The median time between onset of stroke and examination with DW-MRI was 3 days, with a minimum of 1 and a maximum of 20 days. The median time between onset of stroke and NIHSS assessment was 2 days, with a minimum of 0 and a maximum of 15 days. The number of patients with a score of 1, 2 and 3 on item 9 of the NIHSS was 10, 8 and 6, respectively. The mean total NIHSS score was 6.1 (range 1–21).

In 30 of these patients, ischaemic lesions were identified exclusively in the left hemisphere. In two patients, ischaemic lesions were identified exclusively in the right hemisphere, and two patients had ischaemic lesions in both hemispheres.

Nine patients had lesions involving an area in the superior part of the body of the left caudate nucleus and the adjacent corona radiata. Amongst these patients, five had lesions limited only to the caudate nucleus and the adjacent white matter. There was no significant difference in average NIHSS scores (item 9 and total) between patients with lesions in the identified part of the caudate nucleus and those without. Seven patients had lesions involving the caudal part of the left superior temporal sulcus, which corresponds to Wernicke's area and adjacent brain areas. Lesions in the proximity of Broca's area were found

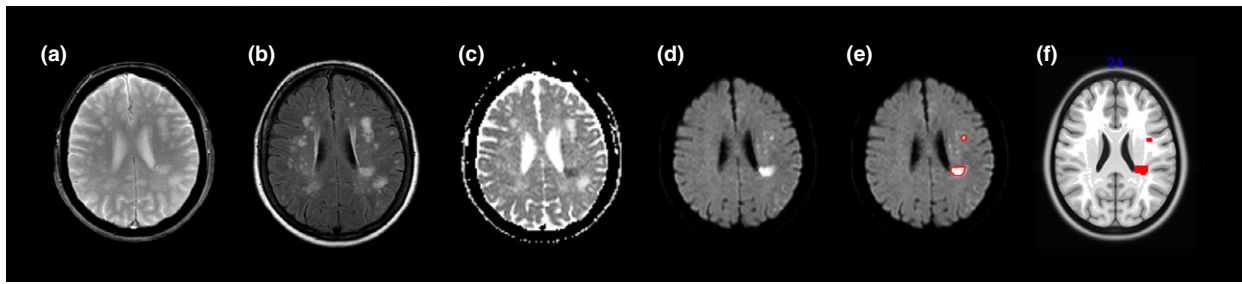


Figure 1 Illustration of the method. Axial T2-weighted (a) and axial fluid inversion recovery (FLAIR) (b) images from one patient demonstrate multiple focal hyperintensity lesions in the subcortical, periventricular and deep white matter of both hemispheres. Axial apparent diffusion coefficient (ADC) (c) and diffusion weighted trace image ($b = 1000 \text{ mm}^2$) (d) demonstrate restricted diffusion in one lesion adjacent to the left lateral ventricle as well as a few scattered punctuate lesions with restricted diffusion in the white matter of the left frontal lobe consistent with acute ischaemic lesions. Illustrations of the manually drawn region of interest (ROI) around two of the acute ischaemic lesions on the diffusion-weighted image (e) and the ROI drawn in MRIcron on the T1 template (f).

in only two patients, one of whom had extensive lesions involving major parts of the left temporal lobe, including Wernicke's area. The lesion focus did not overlap with any of the nerve fibre tracts involved in suggested dorsal and ventral streams associated with language processing, e.g. the superior longitudinal fasciculus, the arcuate fasciculus and the inferior frontooccipital fasciculus [14,15].

The overlap image representing all the patients' lesions is presented in Fig. 2.

Discussion

Even though patients in this study had disturbances of language and speech according to the NIHSS item 9, lesions to the traditional language areas,

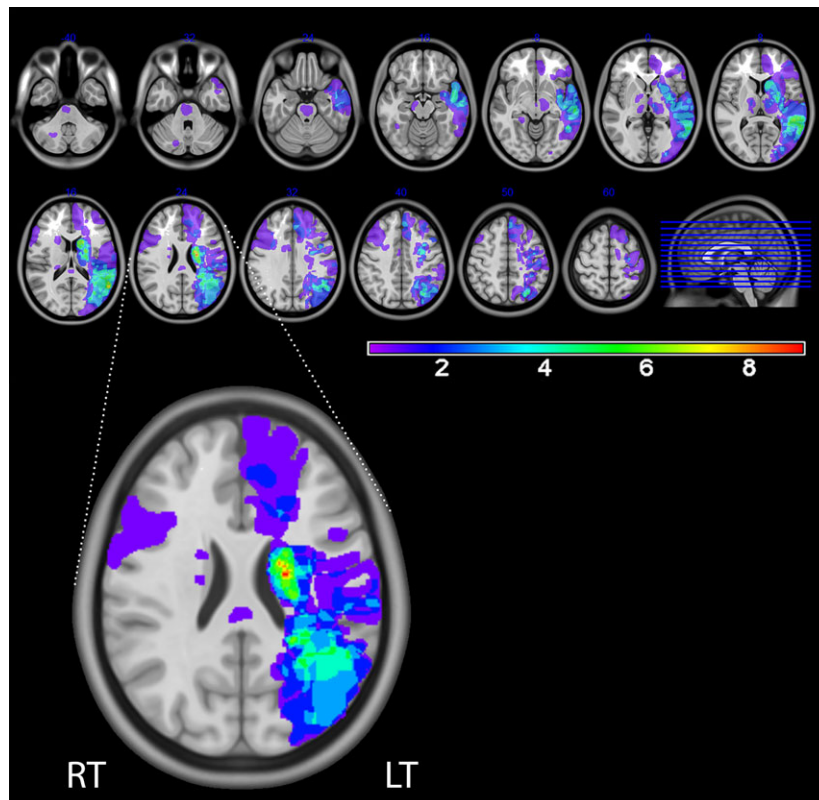


Figure 2 Lesion overlap image. The colour bar indicates the number of overlapping lesions (e.g. red values indicate that, in nine of 34 subjects, tissue was affected by stroke). The enlarged picture shows in detail the slice containing the maximum number of overlapping lesions ($n = 9$).

i.e. Wernicke's and Broca's areas, were identified in less than one-fourth of the patients. A somewhat unexpected finding was that the region of most convergence of lesions was subcortical, in the body of the caudate nucleus. Nine patients were found to have lesions in an overlapping area in this region. Although it has not been definitively established what specific role the caudate nucleus plays in the function of language, there is a growing body of evidence which points to its involvement in controlling cognitive processes [11,16]. Since it is known that there are fibre tracts connecting the caudate nucleus with frontal and temporal lobes, damage to this area could give rise to different kinds of language processing deficits [17]. Evidence from clinical neurophysiology has shown that the basal ganglia are specifically important for grammar processing [18]. Therefore, a crucial role in language processing might be in selecting between different grammatical patterns by enhancing activation of the most relevant pattern and inhibiting irrelevant ones [3]. Case studies have also shown that the caudate nucleus and the neighbouring putamen are involved in regulation of sequencing of articulation patterns for speech sounds [19,20]. Specific damage to the left caudate nucleus has been related to perseverative errors in speech in a study on aphasia by Kreisler *et al.* [8]. In another study by Robles *et al.* [16], electrical stimulation of the head of the caudate nucleus during a picture naming task induced perseveration (repetition of a previous word whilst the next picture was shown). Following the assumption [10] of two separate basal ganglia systems involved in cognitive and motor processing, respectively, Robles *et al.* [16] hypothesize that the head of the caudate constitutes an 'epicentre' of cognitive control including control over the language network, in particular selection/inhibition. Motor control, e.g. coordination of articulation, seems to be controlled more by the putamen. Stimulation of the putamen has been observed to induce dysarthria and anarthria [16]. Indeed, the basal ganglia have been assumed to be involved in selection of relevant motor programmes in general [21].

It might further be considered that the lesion focus in the caudate nucleus in the present study could be due to the fact that this structure is particularly susceptible to ischaemic injury, not only in patients who develop language impairments. A previous study found that 24 of 102 (23.5%) consecutive stroke patients had lesions involving the striatum [22]. However, that study did not provide details on the frequency of damage to the different components of the striatum (e.g. the caudate nucleus). The occurrence of stroke involving only the caudate nucleus seems overall rather uncommon. In one register study [23], it

was reported that patients with caudate stroke constituted only 1% of a total number of 3050 stroke patients (2450 ischaemic stroke and 600 haemorrhagic stroke). In the present study, at least nine of the 925 patients initially included in the investigation had lesions involving an area in the superior part of the body of the left caudate nucleus and the adjacent corona radiata. Of the 34 patients with language and speech impairments that were studied in detail, five (15%) had lesions limited only to the caudate nucleus and adjacent white matter. This finding thus provides reason to believe that the caudate nucleus does in fact play a role in the processing of language. Indeed, in Duffau *et al.*'s model [11], the caudate nucleus is assumed to play an important executive role in language and speech processing as well as in other cognitive processes. Its function is assumed to be 'amodal' – controlling language as well as other functions. Thus, the effects on language caused by lesions in the caudate nucleus could be due to impairment of basic functions that are necessary for fluent language processing but that are not necessarily language-specific. Although item 9 on the NIHSS is primarily intended to test language function, it cannot be ruled out that dysarthria may have biased our evaluation of this item. This may especially have been the case for the five patients who scored 2 on item 10 on the NIHSS, indicating severe dysarthria which can result in mutism/anarthria. Patients with lesions to the caudate nucleus received an average score of 1 for speech (mild to moderate dysarthria), and thus it can be assumed that at least some of them had problems with articulation of speech sounds. Moreover, as an anonymous reviewer has pointed out, it is not impossible that the language and speech disturbance in some of the patients studied here could have been affected by some more general cognitive deficiency such as abulia.

It should be pointed out that the lesion focus in the present investigation differs somewhat from that found in a previous study by Saur *et al.* [9] on language outcome after stroke. In that study of a group of 21 aphasic stroke patients with embolic left hemispheric infarctions caused by a middle cerebral artery stem or branch occlusion, a lesion focus in 12 of 21 patients was found in a rather extensive subcortical region; however, the region was situated more ventrolateral and frontal than that of the present study. The discrepancy between the locations of the lesion focus might be due to the fact that Saur *et al.* included only subjects with moderate to severe aphasia (score >1 in the Aachen Aphasia Test) whereas our study included all acute stroke patients who received a score for language and speech impairment in the NIHSS item 9. Another reason for the discrep-

ancy between Saur *et al.*'s study and the present investigation could be that Saur *et al.* used average data of normalized DW images to obtain their lesion focus. Anatomical differences between subjects might cause displacement of the localization of group effects when automated normalization is used. This is especially the case when brain lesions are present [24]. In the present study, however, the first author together with an experienced neuroradiologist identified lesions in each patient and manually located the corresponding regions in a standard brain. This is a time-consuming process but gives a possible advantage in the certainty of lesion localization compared to an automated procedure.

In view of the findings in our study, a follow-up investigation of the group of acute stroke patients with lesions to the caudate nucleus and neighbouring areas could be carried out to determine the scope of language processing impairments in these patients. On the basis of the results in the above mentioned studies by Kreisler *et al.* [8] and Robles *et al.* [16], one could perhaps expect that this group's language might be characterized by problems with perseverations and even verbal paraphasias when the lesion extends through the white matter towards Wernicke's area. Even dysarthria could be expected, particularly in the patients with damage involving not only the caudate nucleus but extending also to the putamen. Answering this and other more specific questions, however, would require more refined methods of selection and has not been the aim of this study.

Conclusions

The results of the present study indicate that the classical language regions of the brain, Broca's and Wernicke's areas, might be less affected in patients with language processing deficits after stroke than might be expected. The most frequently affected region observed in the present study was instead a subcortical region, the caudate nucleus and the adjacent corona radiata. These results thus contribute to the growing body of evidence that supports the view that the basal ganglia play a crucial role in controlling language and speech processing in the brain.

Acknowledgements

This research has been supported by grant 421-2011-2284 from the Swedish Research Council, as well as with funding from the Humanities and Medicine Program, Lund University, the Elisabeth Rausing Memorial Fund for Research at Lund University, Region Skåne, the Kocks Foundation, Alfred Österlund's

Foundation, the Swedish Heart and Lung Foundation, Skåne University Hospital, the Freemasons Lodge of Instruction EOS in Lund, King Gustaf V's and Queen Victoria's Foundation, Lund University, and the Swedish Stroke Association.

Disclosure of conflicts of interest

The authors declare no financial or other conflicts of interest.

References

1. Wernicke C. *Der aphasische Symptomenkomplex: eine psychologische Studie auf anatomischer Basis*. Breslau: Cohn and Weigert, 1874.
2. Broca PP. Perte de la parole, ramollissement chronique et destruction partielle du lobe antérieur gauche du cerveau [Loss of speech, chronic softening and partial destruction of the anterior left lobe of the brain]. *Bull Soc Anthropol* 1861; **2**: 235–238.
3. Crosson B, McGregor K, Gopinath KS, *et al.* Functional MRI of language in aphasia: a review of the literature and the methodological challenges. *Neuropsychol Rev* 2007; **17**: 157–177.
4. Roll M, Martensson F, Sikstrom S, Apt P, Arnlings-Baath R, Horne M. Atypical associations to abstract words in Broca's aphasia. *Cortex* 2012; **48**: 1068–1072.
5. Ford AA, Triplett W, Sudhyadhom A, *et al.* Broca's area and its striatal and thalamic connections: a diffusion-MRI tractography study. *Front Neuroanat* 2013; **7**: 8.
6. Hillis AE. Aphasia: progress in the last quarter of a century. *Neurology* 2007; **69**: 200–213.
7. Tomasi D, Volkow ND. Resting functional connectivity of language networks: characterization and reproducibility. *Mol Psychiatry* 2012; **17**: 841–854.
8. Kreisler A, Godefroy O, Delmaire C, *et al.* The anatomy of aphasia revisited. *Neurology* 2000; **54**: 1117–1123.
9. Saur D, Ronneberger O, Kummerer D, Mader I, Weiller C, Kloppel S. Early functional magnetic resonance imaging activations predict language outcome after stroke. *Brain* 2010; **133**: 1252–1264.
10. Middleton FA, Strick PL. Basal ganglia and cerebellar loops: motor and cognitive circuits. *Brain Res Rev* 2000; **31**: 236–250.
11. Duffau H, Moritz-Gasser S, Mandonnet E. A re-examination of neural basis of language processing: proposal of a dynamic hodotopical model from data provided by brain stimulation mapping during picture naming. *Brain Lang* 2014; **131**: 1–10.
12. Hallstrom B, Jonsson AC, Nerbrand C, Petersen B, Norrving B, Lindgren A. Lund Stroke Register: hospitalization pattern and yield of different screening methods for first-ever stroke. *Acta Neurol Scand* 2007; **115**: 49–54.
13. Rorden C, Brett M. Stereotaxic display of brain lesions. *Behav Neurol* 2000; **12**: 191–200.
14. Kummerer D, Hartwigsen G, Kellmeyer P, *et al.* Damage to ventral and dorsal language pathways in acute aphasia. *Brain* 2013; **136**: 619–629.

15. Saur D, Kreher BW, Schnell S, *et al.* Ventral and dorsal pathways for language. *Proc Natl Acad Sci U S A* 2008; **105**: 18035–18040.
16. Robles SG, Gatignol P, Capelle L, Mitchell M-C, Duffau H. The role of dominant striatum in language: a study using intraoperative electrical stimulations. *J Neurol Neurosurg Psychiatry* 2005; **76**: 940–946.
17. Hillis AE, Barker PB, Wityk RJ, *et al.* Variability in subcortical aphasia is due to variable sites of cortical hypoperfusion. *Brain Lang* 2004; **89**: 524–530.
18. Frisch S, Kotz SA, von Cramon DY, Friederici AD. Why the P600 is not just a P300: the role of the basal ganglia. *Clin Neurophysiol* 2003; **114**: 336–340.
19. Pickett ER, Kuniholm E, Protopapas A, Friedman J, Lieberman P. Selective speech motor, syntax and cognitive deficits associated with bilateral damage to the putamen and the head of the caudate nucleus: a case study. *Neuropsychologia* 1998; **36**: 173–188.
20. Watkins KE, Vargha-Khadem F, Ashburner J, *et al.* MRI analysis of an inherited speech and language disorder: structural brain abnormalities. *Brain* 2002; **125**: 465–478.
21. Mink JW. The basal ganglia: focused selection and inhibition of competing motor programs. *Prog Neurobiol* 1996; **50**: 381–425.
22. Delavaran H, Sjunnesson H, Arvidsson A, *et al.* Proximity of brain infarcts to regions of endogenous neurogenesis and involvement of striatum in ischaemic stroke. *Eur J Neurol* 2013; **20**: 473–479.
23. Kumral E, Evyapan D, Balkir K. Acute caudate vascular lesions. *Stroke* 1999; **30**: 100–108.
24. Brett M, Johnsrude IS, Owen AM. The problem of functional localization in the human brain. *Nat Rev Neurosci* 2002; **3**: 243–249.