

# Hemianopia and visual loss due to progressive multifocal leukoencephalopathy in natalizumab-treated multiple sclerosis

Tina Rike Herold<sup>1</sup>  
Veronika Jaki<sup>3</sup>  
Anno Graser<sup>4</sup>  
Kirsten Eibl-Lindner<sup>1,2</sup>

<sup>1</sup>Department of Ophthalmology, <sup>2</sup>Department of Ophthalmology, Campus Innenstadt, <sup>3</sup>Department of Neurology, <sup>4</sup>Department of Clinical Radiology, Campus Grosshadern, University of Munich, Ludwig-Maximilians University, Munich, Germany

**Abstract:** This case describes typical ophthalmic findings as a key feature for diagnosis of progressive multifocal leukoencephalopathy (PML) and its possible differential diagnosis. A 58-year-old female patient with relapsing-remitting multiple sclerosis on immunotherapy with natalizumab developed visual disturbance, reading problems, and visual field defects due to PML. PML is a reactivation of latent infection with the John Cunningham virus, which is a type of polyomavirus acquired in childhood or adolescence and is quite common in the general population. PML so far has been mostly associated with other immunodeficiency disorders, such as acquired immunodeficiency syndrome, but is also gaining importance in association with the increasing use and duration of treatment with natalizumab in patients suffering from multiple sclerosis. Natalizumab is a highly specific  $\alpha$ 4-integrin antagonist approved for treatment of patients with active relapsing-remitting multiple sclerosis.

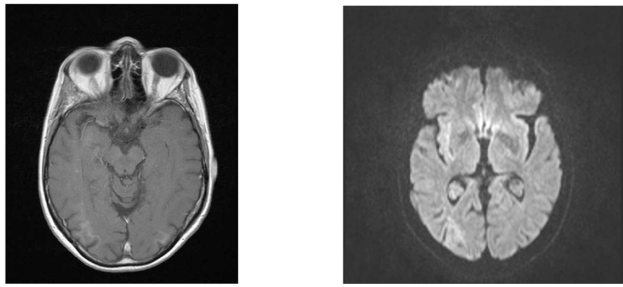
**Keywords:** progressive multifocal leukoencephalopathy, natalizumab, multiple sclerosis, hemianopia

## Case report

A 58-year-old female patient with relapse-remitting multiple sclerosis since 1992 had been treated from 1999 until 2007 with interferon beta-1a at two different doses. Because of leukopenia and increasing relapses, immunomodulatory therapy was switched to natalizumab (Tysabri®) in 2007. After only one relapse while on this treatment, she presented to an external neurological department in August 2010 with a reading disorder, deterioration in visual acuity, and weakness and spasm in her right leg. After intravenous treatment with methylprednisolone 1000 mg per day for 5 days, her clinical neurological symptoms partly recovered, but an ophthalmological deficit characterized by visual loss and visual field defects was unresponsive to this treatment (see Figure 1). Although ataxia and weakness on the right side increased, a lumbar puncture was negative for John Cunningham virus (by polymerase chain reaction [PCR]) at that time.

In October 2010, the patient was referred to the neurological department of the Ludwig-Maximilians University in Munich with suspicion of progressive multifocal leukoencephalopathy (PML) because the John Cunningham virus PCR was now positive in the cerebrospinal fluid (468 copies/mL). The ophthalmologic examination at our clinic in October 2010 showed a best corrected visual acuity of 20/100 Snellen equivalent in the right eye and in the left eye. The anterior segment was unremarkable in both eyes, as was the pupillary reaction. Examination of the fundus showed slight paleness of the optic nerve head bilaterally. The macular region and retinal periphery

Correspondence: Kirsten Eibl-Lindner  
Department of Ophthalmology,  
Ludwig-Maximilians University,  
University of Munich, Campus  
Innenstadt, Mathildenstrasse 8,  
Munich 80336, Germany  
Tel +49 89 5160 3811  
Fax +49 89 5160 5160  
Email [kirsten.eibl@med.uni-muenchen.de](mailto:kirsten.eibl@med.uni-muenchen.de)



**Figure 1** Cranial T1-weighted magnetic resonance imaging at the end of September 2010 revealed nodular contrast enhancement with subcortical diffuse restriction in the right parieto-occipital region which is not typical for multiple sclerosis.

**Note:** Also, the left side already showed a small subcortical lesion with diffusion restriction.

were normal. The visual field (Octopus 101, 30°, Haag Streit, Germany) displayed a homonymous hemianopia on the left side (Figure 2). Cranial T1-weighted magnetic resonance imaging revealed a nodular contrast enhancement with subcortical diffuse restriction in the right parieto-occipital region, consistent with the diagnosis of PML, in addition to white matter lesions typical of multiple sclerosis (Figure 1). Lumbar puncture showed normal white blood cell count, glucose of 52 mg/dL and protein of 60 mg/dL in the spinal fluid. A PCR for John Cunningham virus was positive (431 copies/mL) and confirmed the diagnosis of PML.

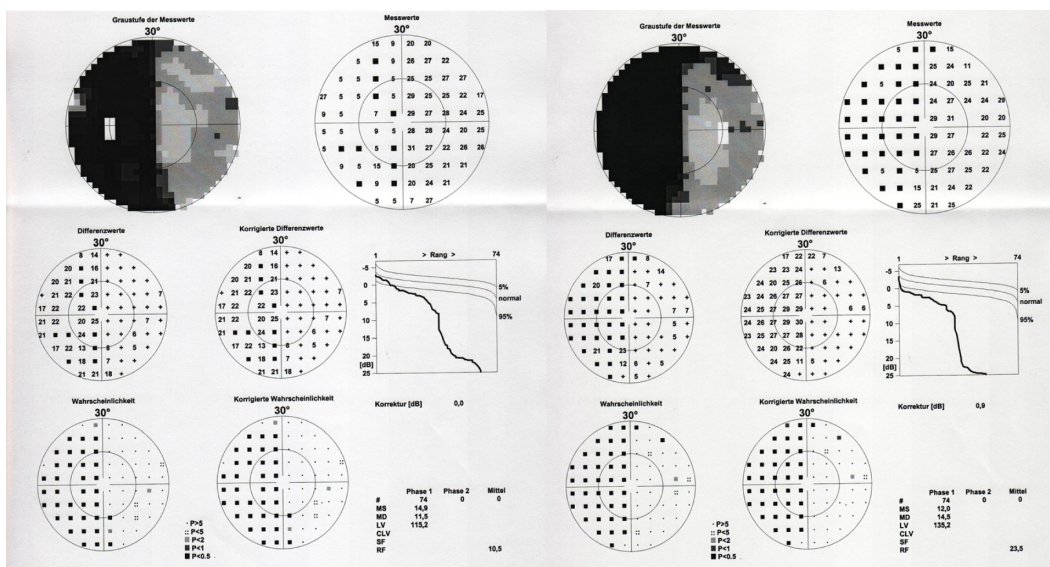
Within one month, general ataxia, reduction of free walking distance to 165 m, and weakness in the left leg worsened (Expanded Disability Score 5.5), whereas the findings on visual field testing remained stable. Follow-up magnetic resonance imaging revealed new subcortical temporo-occipital

lesions with hyperintense signals in native T1-weighted images with diffuse restriction and contrast enhancement at a size of 1.3 cm. The left side showed a small subcortical lesion with diffusion restriction.

The patient then underwent combination therapy of immunoadsorption (five times), mirtazapine 45 mg/day, mefloquine 250 mg for 7 days, and immunoglobulins 25 mg/day on two consecutive days, starting in October 2010. Cyclosporin 150 mg/day was added in order to suppress potential immune reconstitution inflammatory syndrome, which has been described in almost all patients with natalizumab-associated PML so far. Immune reconstitution inflammatory syndrome refers to clinical worsening in patients with opportunistic infections due to recovery of the immune system. Despite one month of therapy and repeat high-dose methylprednisolone, the patients' clinical and neurological status steadily worsened. As a result, the ophthalmological parameters, including visual acuity and visual field, were not evaluable due to the poor clinical condition of the patient. According to the patients' subjective symptoms and enlarging PML lesions on magnetic resonance imaging, it can be assumed that these parameters were further deteriorating. A biopsy was performed demonstrating that the PML was the leading pathological finding in this patient and not immune reconstitution inflammatory syndrome.<sup>1</sup>

### Comment

This case demonstrates the difficulty in diagnosis and treatment of natalizumab-associated PML due to the subtle clinical



**Figure 2** Visual field testing in October 2010 demonstrated a homonymous hemianopia to the left (Octopus 101, 30°, Haag Streit, Germany).

**Note:** Follow-up visual field testing during natalizumab cessation and PML treatment did not show any change in these findings.

signs in different functional systems. PML is primarily known to occur in association with immunodeficiency disorders, such as acquired immunodeficiency syndrome, treatment with highly immunosuppressive agents such as rituximab, or rare congenital disorders like Wiskott-Aldrich syndrome.<sup>2,3</sup> However, PML is gaining importance in association with the increasing use and duration of natalizumab therapy in patients with multiple sclerosis. Natalizumab is generally well tolerated and has sustained safety and efficacy in patients with active multiple sclerosis.<sup>4</sup> On the other hand, the expected benefits of natalizumab have to be weighed against the risk of PML, and patients need to be selected and monitored carefully.<sup>5</sup>

With regard to multiple sclerosis, most of the ophthalmological symptoms can be explained by optic nerve head disturbances. However, cortical involvement has to be taken into consideration in patients with nonspecific neurological signs and progression of the disease. The ophthalmologist plays a crucial role in being able to detect any deterioration clinically without too much effort even at the bedside. Visual acuity and visual field examination are possible even in a very immunocompromised patient, and are completely noninvasive and cost-effective clinical measures.

In this case, the main features leading to diagnosis of PML were detection of reactivated John Cunningham virus in the spinal fluid, in combination with deteriorating clinical symptoms and findings on magnetic resonance imaging. There are data showing that natalizumab-associated PML and consecutive immune reconstitution inflammatory syndrome can be well managed in some cases.<sup>5</sup> However, recent publications on this topic emphasize the critical importance of the time interval between diagnosis of PML, natalizumab cessation, and implementation of treatment for PML, resulting in a more favorable clinical course for this devastating disease.<sup>6</sup>

This case demonstrates that highly vigilant ophthalmological observation of patients with multiple sclerosis on natalizumab can contribute to a fast diagnosis of natalizumab-associated PML.<sup>7-9</sup> We suggest that visual acuity and visual

field testing should be performed every 3 months in patients treated with natalizumab for multiple sclerosis for longer than one year. In close cooperation, neurologists and ophthalmologists could thus prevent an unnecessary delay in diagnosing natalizumab-associated PML and initiate early treatment of this severe complication. Atypical clinical signs and unusual morphological findings on magnetic resonance imaging should raise the suspicion of PML in a natalizumab-treated patient with multiple sclerosis.

## Disclosure

The authors report no conflicts of interest in this work.

## References

1. Metz I, Radue EW, Oterino A, et al. Pathology of immune reconstitution inflammatory syndrome in multifocal sclerosis with natalizumab-associated progressive leukoencephalopathy. *Acta Neuropathol.* 2012;123:235–245.
2. Downes S, Black GC, Hyman N, Simmonds M, Morris J, Barton C. Visual loss due to progressive multifocal leukoencephalopathy in a congenital immunodeficiency disorder. *Arch Ophthalmol.* 2001;119:1376–1378.
3. Clifford DB, De Luca A, Simpson DM, Arendt G, Giovannoni G, Nath A. Natalizumab-associated progressive multifocal leukoencephalopathy in patients with multiple sclerosis: lessons from 28 cases. *Lancet Neurol.* 2010;9:438–446.
4. Holmen C, Piehl F, Hillert J, et al. A Swedish national post-marketing surveillance study of natalizumab treatment in multiple sclerosis. *Mult Scler.* 2011;17:708–719.
5. Kappos L, Bates D, Edan G, et al. Natalizumab treatment for multiple sclerosis: updated recommendations for patient selection and monitoring. *Lancet Neurol.* 2011;10:745–758.
6. Schröder A, Lee DH, Hellwig K, Lukas C, Linker RA, Gold R. Successful management of natalizumab-associated progressive multifocal leukoencephalopathy and immune reconstitution syndrome in a patient with multiple sclerosis. *Arch Neurol.* 2010;67:1391–1394.
7. Vermersch P, Kappos L, Gold R, et al. Clinical outcomes of natalizumab-associated progressive multifocal leukoencephalopathy. *Neurology.* 2011;76:1697–1704.
8. Warnke C, Menge T, Hartung HP, et al. Natalizumab and progressive multifocal leukoencephalopathy: what are the causal factors and how can it be avoided? *Arch Neurol.* 2010;67:923–930.
9. O'Connor PW, Goodman A, Kappos L, et al. Disease activity return during natalizumab treatment interruption in patients with multiple sclerosis. *Neurology.* 2011;76:1858–1865.
10. Schaaf SM, Pitt D, Racke MK. What happens when natalizumab therapy is stopped? *Expert Rev Neurother.* 2011;11:1247–1250.

### Clinical Ophthalmology

#### Publish your work in this journal

Clinical Ophthalmology is an international, peer-reviewed journal covering all subspecialties within ophthalmology. Key topics include: Optometry; Visual science; Pharmacology and drug therapy in eye diseases; Basic Sciences; Primary and Secondary eye care; Patient Safety and Quality of Care Improvements. This journal is indexed on

Submit your manuscript here: <http://www.dovepress.com/clinical-ophthalmology-journal>

Dovepress

PubMed Central and CAS, and is the official journal of The Society of Clinical Ophthalmology (SCO). The manuscript management system is completely online and includes a very quick and fair peer-review system, which is all easy to use. Visit <http://www.dovepress.com/testimonials.php> to read real quotes from published authors.