

This is an Open Access article licensed under the terms of the Creative Commons Attribution-NonCommercial 3.0 Unported license (CC BY-NC) ([www.karger.com/OA-license](http://www.karger.com/OA-license)), applicable to the online version of the article only. Distribution permitted for non-commercial purposes only.

## Surgery for Severe Ulcerative Colitis during Pregnancy: Report of Two Cases

Motoi Uchino<sup>a</sup> Hiroki Ikeuchi<sup>a</sup> Hiroki Matsuoka<sup>a</sup> Toshihiro Bando<sup>a</sup>  
Kei Hirose<sup>a</sup> Akihiro Hirata<sup>a</sup> Teruhiro Chohno<sup>a</sup> Hirofumi Sasaki<sup>a</sup>  
Yoko Yokoyama<sup>a</sup> Shiro Nakamura<sup>a</sup> Yuko Nakamura<sup>c</sup> Yoshio Takesue<sup>b</sup>

<sup>a</sup>Department of Inflammatory Bowel Disease and <sup>b</sup>Division of Infection Control and Prevention, Hyogo College of Medicine, Nishinomiya, and <sup>c</sup>Department of Gastroenterology, Kakogawa West City Hospital, Kakogawa City Hospital Foundation, Kakogawa, Japan

### Key Words

Pregnancy · Surgical procedure · Ulcerative colitis · Cesarean section · Colectomy

### Abstract

Refractory ulcerative colitis (UC) that does not respond to medical therapy often requires surgery even during pregnancy. Although surgical cases of UC during pregnancy were reported previously, the standard surgical strategy for both colitis and pregnancy was unclear. Herein, fetal and maternal safety as well as the strategy for this unusual surgical procedure during pregnancy in patients with UC are considered. A 28-year-old woman was diagnosed with left-sided moderate UC at 12 weeks of pregnancy; toxic megacolon was suspected, and surgery was required. Although the baby's gestational age was 23 weeks and 3 days, a cesarean section was performed before the colectomy. In a next case, a 28-year-old woman had a 2-year history of left-sided UC. Her colitis flared up at 11 weeks of pregnancy. Colectomy was performed because her colitis was unresponsive to conservative therapy, and the pregnancy was continued, with a transvaginal delivery at 36 weeks. In patients with UC, the need for surgery should be determined promptly based on disease severity, whether or not the patient is pregnant. The need for surgery should not be affected by pregnancy. The pregnancy should be continued for as long as possible when there are no fetal and maternal complications. Both cesarean section and colectomy should be performed independently if necessary.

© 2015 S. Karger AG, Basel

## Introduction

Although the etiology of ulcerative colitis (UC) remains unknown, a systemic immune disorder might be involved in its development. Patients with UC are treated with anti-inflammatory or immunosuppressive treatments, including 5-aminosalicylic acid (5-ASA), corticosteroids, immunomodulators or biologics. However, surgery for UC is often performed in patients with a flare-up and refractory disease unresponsive to medical therapy.

It has been reported that female sex appears to be a risk factor for frequent UC flare-ups, and the disease is often exacerbated with flare-ups during pregnancy [1, 2]. Medical treatments are restricted when flare-ups occur during pregnancy due to concern about fetal safety. According to statements by the United States Food and Drug Administration (FDA), 5-ASA, corticosteroids and cytopheresis (CAP) have been proven safe and are recommended treatments during pregnancy. With immunomodulators and biologics, although thiopurine is not recommended for treatment during pregnancy and thiopurines belong to FDA pregnancy category D, some studies have reported no evidence for an increased risk in pregnancy except in the period before birth [3–6]. On the other hand, biologics and tacrolimus have been given a B category, which means that studies in animals do not show fetal risks, but there have been no controlled studies in humans, or adverse effects have been observed in animal studies, but these have not been confirmed in controlled studies [7].

Although there are reports of successful treatment of UC with immunomodulators, biologics and CAP during pregnancy, one should consider surgical treatment for severe UC when medical treatment fails to induce remission [3–5, 8, 9]. Dozois et al. [10] previously reported 38 cases of UC managed with surgery during pregnancy. Surgical intervention coincided with cesarean section or delivery in 16 patients, with the pregnancy continuing after surgery in the remaining 22 cases. These surgical interventions, which included total colectomy, subtotal colectomy, ileostomy alone or ileostomy and colostomy, were performed according to each patient's condition. Therefore, the strategy of surgical procedure during pregnancy remains unclear. In this study, two cases of severe UC during pregnancy unresponsive to medical therapy are described, and the standard surgical procedure for severe UC during pregnancy is considered with regard to both fetal and maternal safety.

## Case 1

A 28-year-old woman developed bloody mucous stools at 12 weeks of pregnancy. A diagnosis of left-sided UC was made on the basis of colonoscopic findings and confirmed by the typical histological features of biopsy samples (fig. 1). She presented with moderate colitis, having frequent loose, bloody stools less than 10 times a day, mild anemia, abdominal pain that was not severe and low-grade fever. She was initially started on oral corticosteroid therapy at 0.5 mg/kg/day of prednisolone (20 mg/day) with 90 mg/kg/day of 5-ASA (3,600 mg of mesalazine daily). Despite 8 days of this treatment, her condition was not cured, and she required increased doses of prednisolone intravenously (1.5 mg/kg/day). However, she was referred to our hospital for further treatment 24 days after onset of UC at 22 weeks and 0 days of her pregnancy because her symptoms had worsened, with frequent bloody stools and abdominal pain. Although she was treated with high-dose prednisolone and intensive CAP that was performed once every 2 days in our institution, she had moderately severe colitis, with frequent loose stools more than 10 times per day, abdominal cramps, high-grade fever and a high C-reactive protein value of 20.4 mg/dl on laboratory blood testing. Abdominal ultrasound examination at 34 days from the onset of UC

(at 23 weeks and 3 days of pregnancy) showed a thin wall with dilatation of the colonic lumen, consistent with megacolon (fig. 2). Urgent surgery was indicated for the colitis that was unresponsive to medical therapy with suspected toxic megacolon. Since the fetus showed no growth abnormalities and even though it was at a gestational age of 23 weeks, a cesarean section was performed before the colectomy. Although the neonate required treatment for retinopathy of prematurity in the neonatal intensive care unit, both the baby and mother improved without any postoperative complications. The patient finally underwent restorative proctocolectomy with ileal pouch anal anastomosis 8 months after the initial surgery.

## Case 2

A 28-year-old woman who had a 2-year history of left-sided UC and was treated with 60 mg/kg/day of 5-ASA (2,400 mg of mesalazine daily) was referred to our hospital for a flare-up of symptoms with increasing loose bloody stools at 11 weeks and 1 day of pregnancy. Rectosigmoid colonoscopy showed moderately inflamed UC that corresponded to Mayo endoscopic subscore 3. She was started on corticosteroid therapy at a dose of 1.0 mg/kg/day of prednisolone with 80 mg/kg/day of 5-ASA and CAP. Since her symptoms did not change during the 3 weeks of initial treatment, the next step involved 5 mg/kg of infliximab. After 7 days of infliximab administration, she complained of abdominal distension, cramps and increased loose stools. Abdominal radiography showed accumulated small intestinal and colonic gas shadows without megacolon. Although laboratory blood tests showed no evidence of sepsis, the white blood cell count increased to 23,130/ $\mu$ l and the hemoglobin count decreased from 8.3 to 6.4 g/dl within 1 day. Urgent surgery was performed at 15 weeks of pregnancy because she had refractory disease unresponsive to medical therapy, with suspected megacolon and bowel obstruction. Total colectomy with Hartmann's procedure and end ileostomy was performed as initial surgery without interruption of the pregnancy (fig. 3). She improved without any complications and was delivered transvaginally at 36 weeks of pregnancy. Restorative proctocolectomy was performed 6 months after delivery.

## Discussion

At present, the standard surgical procedure for UC is restorative proctocolectomy with ileal pouch reconstruction. Although emergent surgery that includes only colectomy without manipulation of the rectum can be performed for patients with penetration, toxic megacolon or fulminant disease, urgent surgery that includes total proctocolectomy with pouch reconstruction could be selected for patients with refractory disease depending on the presence of systemic sepsis. The most important issue, regardless of pregnancy, is to determine promptly whether emergent/urgent surgical intervention is required based on the severity of the colitis and the general maternal condition. Namely, it should be recognized that delayed surgery can result in sepsis, which can adversely affect both the mother and the fetus. Furthermore, surgery and the severity of UC should never be the determining factors for discontinuing pregnancy. In general, in non-pregnant patients, urgent surgery for refractory disease unresponsive to medical therapy as in the two cases presented could include two-stage restorative proctocolectomy with diverting ileostomy.

However, we should consider some fetal and maternal issues during pregnancy before surgery. The size of the uterus and its effect on the surgical procedure should be considered. Generally, during the first trimester, the uterus rises out of the pelvic cavity and reaches the

level of the umbilicus by week 20 [11]. Proctectomy without touching the uterus to avoid stimulating the baby is impossible even in other rectal surgery and pouch surgery. Therefore, total colectomy with ileostomy should be performed as initial surgery in a staged approach, and ileal pouch reconstruction should be performed a sufficient time after delivery. It has been reported that reducing the uterus to normal size, as before pregnancy, takes at least 4–6 weeks [11]. Thus, secondary surgery for restorative proctocolectomy is desirable at that time.

Although we recommended the creation of a mucous fistula with colectomy rather than Hartmann's procedure due to its safety for pelvic abscess in a previous report, the presence of a mucous fistula is a contraindication in pregnant patients who are continuing pregnancy after colectomy because of uterine and fetal growth after surgery [12].

We should consider whether cesarean section should be done or whether the pregnancy should be continued before surgery. Generally, cesarean section should be considered when there are fetal or maternal issues, such as previous cesarean section, dystocia, breech presentation or fetal distress, as mentioned above [13]. The indication for cesarean section or abortion cannot be determined based on UC severity. Furthermore, the grown uterus does not decrease in size soon after cesarean section. It takes at least 6–8 weeks to reach the same size as before pregnancy [11]. Therefore, cesarean section to allow for proctectomy and pouch reconstruction should not be considered before urgent/emergent colectomy. Furthermore, although abortion is legal up to 24 weeks of pregnancy in the United Kingdom or up to 22 weeks of pregnancy in Japan, abortion should not be considered in anticipation of later proctocolectomy even in early pregnancy within the above weeks when no fetal abnormalities are found.

Recently, premature babies have been defined as those born before 37 weeks of gestational age. Extremely premature infants are those born before 32 weeks, and moderately premature infants are those born between 32 and 37 weeks. High-level neonatal intensive care units have been shown to provide benefits for both extremely premature and moderately premature infants [14]. Infant morbidity rates in Japan are recognized as among the lowest in the world. It has been reported that more than 99% of mildly premature infants at 33–38 weeks are expected to survive today. However, morbidity can be increased up to approximately 10%, and mild or severe morbidity can reach over 50% in extremely premature infants born at 23–30 weeks of gestation [15]. Given this, it is clearly better for the infant to avoid an early birth as much as possible, and cesarean section should generally be avoided until at least 26 weeks of pregnancy. However, cesarean section prior to colectomy should be considered with severe colitis after 26 weeks of pregnancy because the severe UC could easily result in maternal morbidity. It is important to perform cesarean section and colectomy emergently at any time during pregnancy when the maternal and fetal conditions deteriorate and sepsis with perforative peritonitis develops to at least save the mother's life.

## Conclusion

In conclusion, regardless of pregnancy, the need for emergent/urgent surgical intervention should be determined promptly based on the severity of colitis and the general maternal condition. Surgery and the severity of UC should never be the determining factors for discontinuing pregnancy. The pregnancy can be continued for as long as possible without fetal and maternal problems in surgery for severe UC.

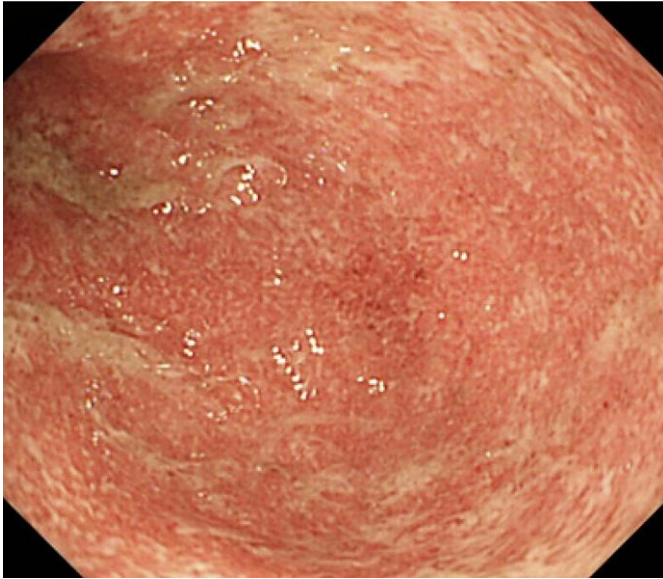
## Disclosure Statement

The authors declare that they have no competing interests.

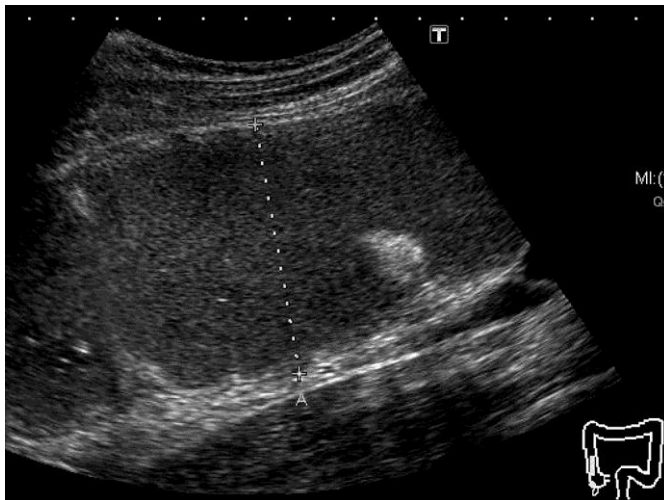
## References

- Höie O, Wolters F, Riis L, Aamodt G, Solberg C, Bernklev T, Odes S, Mouzas IA, Beltrami M, Langholz E, Stockbrügger R, Vatn M, Moum B; European Collaborative Study Group of Inflammatory Bowel Disease (EC-IBD): Ulcerative colitis: patient characteristics may predict 10-yr disease recurrence in a European-wide population-based cohort. *Am J Gastroenterol* 2007;102:1692–1701.
- Mizushima T, Tanida S, Mizoshita T, Hirata Y, Murakami K, Shimura T, Kataoka H, Kamiya T, Joh T: A complicated case of tacrolimus-induced rapid remission after cesarean section in the early third trimester for refractory severe ulcerative colitis flaring in the initial period of gestation. *Case Rep Gastroenterol* 2011;5:144–151.
- Francella A, Dyan A, Bodian C, Rubin P, Chapman M, Present DH: The safety of 6-mercaptopurine for childbearing patients with inflammatory bowel disease: a retrospective cohort study. *Gastroenterology* 2003;124:9–17.
- Goldstein LH, Dolinsky G, Greenberg R, Schaefer C, Cohen-Kerem R, Diav-Citrin O, Malm H, Reuvers-Lodewijks ME, Rost van Tonningen-van Driel MM, Arnon J, Ornoy A, Clementi M, Di Gianantonio E, Koren G, Braunstein R, Berkovitch M: Pregnancy outcome of women exposed to azathioprine during pregnancy. *Birth Defects Res A Clin Mol Teratol* 2007;79:696–701.
- Cleary BJ, Källén B: Early pregnancy azathioprine use and pregnancy outcomes. *Birth Defects Res A Clin Mol Teratol* 2009;85:647–654.
- Akbari M, Shah S, Velayos FS, Mahadevan U, Cheifetz AS: Systematic review and meta-analysis on the effects of thiopurines on birth outcomes from female and male patients with inflammatory bowel disease. *Inflamm Bowel Dis* 2013;19:15–22.
- Casanova MJ, Chaparro M, Domènech E, Barreiro-de Acosta M, Bermejo F, Iglesias E, Gomollón F, Rodrigo L, Calvet X, Esteve M, García-Planella E, García-López S, Taxonera C, Calvo M, López M, Ginard D, Gómez-García M, Garrido E, Pérez-Calle JL, Beltrán B, Piqueras M, Saro C, Botella B, Dueñas C, Ponferrada A, Mañosa M, García-Sánchez V, Maté J, Gisbert JP: Safety of thiopurines and anti-TNF- $\alpha$  drugs during pregnancy in patients with inflammatory bowel disease. *Am J Gastroenterol* 2013;108:433–440.
- Steenholdt C, Al-Khalaf M, Ainsworth MA, Brynskov J: Therapeutic infliximab drug level in a child born to a woman with ulcerative colitis treated until gestation week 31. *J Crohns Colitis* 2012;6:358–361.
- Takahashi H, Sugawara K, Sugimura M, Iwabuchi M, Mano Y, Ukai K, Tadokoro K: Flare up of ulcerative colitis during pregnancy treated by adsorptive granulocyte and monocyte apheresis: therapeutic outcomes in three pregnant patients. *Arch Gynecol Obstet* 2013;288:341–347.
- Dozois EJ, Wolff BG, Tremaine WJ, Watson WJ, Drellichman ER, Carne PW, Bakken JL: Maternal and fetal outcome after colectomy for fulminant ulcerative colitis during pregnancy: case series and literature review. *Dis Colon Rectum* 2006;49:64–73.
- Uterine Growth During Pregnancy And Parturation: Review of MEDICAL EMBRYOLOGY Book by BEN PANSKY, PhD, MD. Alameda, CA, Embryome Sciences, Inc. Accessible online at: <http://discovery.lifemapsc.com/library/review-of-medical-embryology/chapter-36-uterine-growth-during-pregnancy-and-parturation>.
- Uchino M, Ikeuchi H, Matsuoka H, Takahashi Y, Tomita N, Takesue Y: Surgical site infection and validity of staged surgical procedure in emergent/urgent surgery for ulcerative colitis. *Int Surg* 2013;98:24–32.
- Soliman SR, Burrows RF: Cesarean section: analysis of the experience before and after the National Consensus Conference on Aspects of Cesarean Birth. *CMAJ* 1993;148:1315–1320.
- Lorch SA, Baiocchi M, Ahlberg CE, Small DS: The differential impact of delivery hospital on the outcomes of premature infants. *Pediatrics* 2012;130:270–278.
- Ge WJ, Mirea L, Yang J, Bassil KL, Lee SK, Shah PS; Canadian Neonatal Network: Prediction of neonatal outcomes in extremely preterm neonates. *Pediatrics* 2013;132:e876–e885.

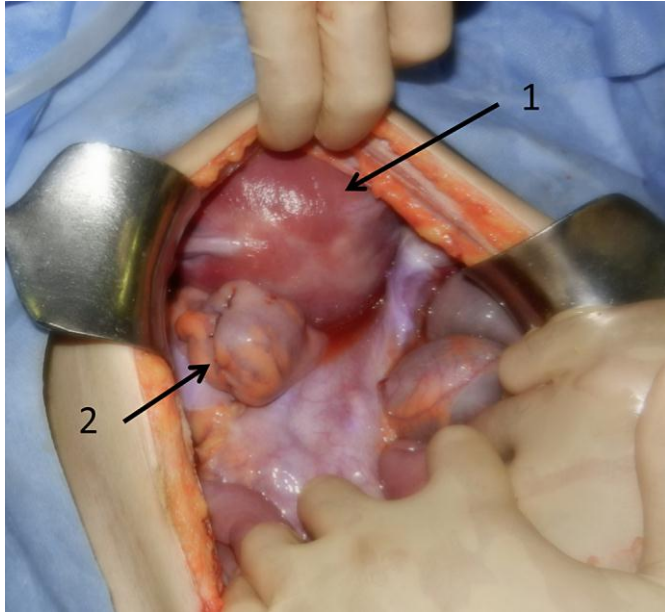




**Fig. 1.** Endoscopic examination of case 1. Mucosal friability, loss of vascular pattern, erythema and edema circumferentially are shown at the rectum.



**Fig. 2.** Ultrasonography of the transverse colon in case 1. A thin wall and dilated transverse colon (with the dotted line measuring 65 mm) suggest megacolon.



**Fig. 3.** Intraoperative findings of case 2. The pregnant uterus is smaller than fist size. Arrow 1 shows the 14-week pregnant uterus. Arrow 2 shows the resected distal rectal stump.