




Since January 2020 Elsevier has created a COVID-19 resource centre with free information in English and Mandarin on the novel coronavirus COVID-19. The COVID-19 resource centre is hosted on Elsevier Connect, the company's public news and information website.

Elsevier hereby grants permission to make all its COVID-19-related research that is available on the COVID-19 resource centre - including this research content - immediately available in PubMed Central and other publicly funded repositories, such as the WHO COVID database with rights for unrestricted research re-use and analyses in any form or by any means with acknowledgement of the original source. These permissions are granted for free by Elsevier for as long as the COVID-19 resource centre remains active.



# ACTAS Dermo-Sifiliográficas

Full English text available at  
[www.actasdermo.org](http://www.actasdermo.org)



## REVIEW

# Cutaneous Manifestations in Patients With COVID-19: Clinical Characteristics and Possible Pathophysiologic Mechanisms<sup>☆</sup>



F González González,<sup>a,\*</sup> C Cortés Correa,<sup>b,c</sup> E Peñaranda Contreras<sup>c,d</sup>

<sup>a</sup> Dermatología, Facultad de Medicina, Universidad Nacional de Colombia, Bogotá, Colombia

<sup>b</sup> Dermatología, Facultad de Medicina, Universidad Nacional de Colombia, Bogotá, Colombia

<sup>c</sup> Hospital Universitario de la Samaritana E.S.E., Bogotá, Colombia

<sup>d</sup> Dermatología - Oncología, Facultad de Medicina, Universidad Nacional de Colombia, Bogotá, Colombia

Received 6 May 2020; accepted 15 November 2020

Available online 28 January 2021

### KEYWORDS

Coronavirus;  
COVID-19;  
Severe acute  
respiratory  
syndrome-related  
coronavirus;  
Skin

**Abstract** The rapid spread of severe acute respiratory syndrome coronavirus 2 (SARS-CoV-2) infections soon led to a pandemic with serious health, economic, political, and cultural repercussions across the globe. The disease caused by SARS-CoV-2, coronavirus disease 2019 (COVID-19), is a multisystemic disease that requires a multidisciplinary approach involving specialists from all fields and levels of care. In this article, we review the literature on the diverse cutaneous manifestations associated with COVID-19. We also describe the pathophysiologic mechanisms proposed to date and their possible association with these manifestations. Finally, we propose a system for classifying the cutaneous manifestations of COVID-19 according to their underlying pathophysiologic mechanisms and prognosis.

© 2020 AEDV. Published by Elsevier España, S.L.U. This is an open access article under the CC BY-NC-ND license (<http://creativecommons.org/licenses/by-nc-nd/4.0/>).

### PALABRAS CLAVES

Coronavirus;  
infecciones por  
coronavirus  
COVID-19;  
virus del Síndrome

### Manifestaciones cutáneas en pacientes con COVID-19: características clínicas y mecanismos fisiopatológicos postulados

**Resumen** La infección por SARS-CoV-2 se ha convertido rápidamente en una pandemia con importantes implicaciones en ámbitos sanitarios, económicos, políticos y culturales en todo el planeta. La enfermedad que produce, llamada COVID-19, es considerada actualmente una patología florida y de obligatorio manejo multidisciplinario por todas las especialidades médicas y de servicios de salud.

<sup>☆</sup> Please cite this article as: González González F, Cortés Correa C, Peñaranda Contreras E. Manifestaciones cutáneas en pacientes con COVID-19: características clínicas y mecanismos fisiopatológicos postulados. Actas Dermosifiliogr. 2021;112:314–323.

\* Corresponding author.

E-mail address: [fegonzalezg@unal.edu.co](mailto:fegonzalezg@unal.edu.co) (F. González González).

Respiratorio Agudo Severo; piel

Este artículo presenta una revisión bibliográfica de las variadas manifestaciones cutáneas a causa de la COVID-19. Posteriormente, se mencionan los diversos engranajes fisiopatológicos que se han postulado hasta el momento y su posible relación con los hallazgos de la enfermedad en la piel. Por último, se propone una clasificación de las manifestaciones cutáneas según mecanismos fisiopatológicos de base y pronóstico de la enfermedad.

© 2020 AEDV. Publicado por Elsevier España, S.L.U. Este es un artículo Open Access bajo la licencia CC BY-NC-ND (<http://creativecommons.org/licenses/by-nc-nd/4.0/>).

## Introduction

In December 2019, the Chinese health authorities reported multiple cases of acute respiratory illness in the province of Wuhan, mostly affecting workers at a small seafood market.<sup>1</sup> It was not long before the causative agent was identified: a virus from the *Coronaviridae* family of likely zoonotic origin and whose original reservoir is the bat.<sup>2</sup> Soon afterwards, the virus was named *severe acute respiratory syndrome coronavirus 2* (SARS-CoV-2) to distinguish it from the other *Coronaviridae* viruses responsible for 2 other pandemics this century: SARS-CoV-1 and Middle East Respiratory Syndrome coronavirus (MERS-CoV).<sup>3,4</sup>

Although SARS-CoV-2 is associated with a case fatality rate of 2.3%,<sup>5</sup> lower than that of SARS-CoV-1 (9.5%) and MERS-CoV (34.4%),<sup>6</sup> it is highly contagious and quickly spread outside China; its high transmissibility—higher than that of SARS-CoV-1<sup>7</sup>—can be partly explained by the higher viral loads in the respiratory tract. SARS-CoV-2 can also survive in aerosols for more than 3 hours, remains viable on a variety of surfaces for 72 hours, and has a relatively short incubation period (< 2 weeks).<sup>8</sup>

Early reports of coronavirus disease 2019 (COVID-19), the disease caused by SARS-CoV-2, indicated that most patients experienced fever, rhinorrhea, a cough without expectoration, asthenia, and adynamia.<sup>9</sup> A small proportion required hospitalization due to severe pneumonia. In a cohort of 70 000 patients with SARS-CoV-2 infection in China, Wu et al.<sup>3</sup> reported that 14% of patients developed severe pneumonia (dyspnea, tachypnea, desaturation, and a decreased arterial oxygen partial pressure to fractional inspired oxygen ratio) and that 5% required critical care. The case fatality rate was 2.3% for the general population and 14% for patients aged 80 years or older. Their findings were corroborated by later reports from Europe.<sup>10</sup>

The main risk factors for severe COVID-19 include male sex, diabetes, high blood pressure, chronic lung disease, and cardiovascular disease.<sup>11,12</sup> Children younger than 10 years have mild symptoms and are much less likely than adults to develop complications or die.<sup>13</sup>

Reports from Asia, Europe, and the United States have described a wide range of cutaneous manifestations associated with COVID-19. Although these manifestations were initially considered to be nonspecific, the publication of an increasing number of cases revealed an apparent pattern and possibly even an association with prognosis. In this article, we review the literature on the diverse cutaneous manifestations described to date in patients with COVID-19. We then outline the different pathophysiologic

mechanisms and hypotheses proposed so far to explain their occurrence.

## Results

### Cutaneous Manifestations in COVID-19

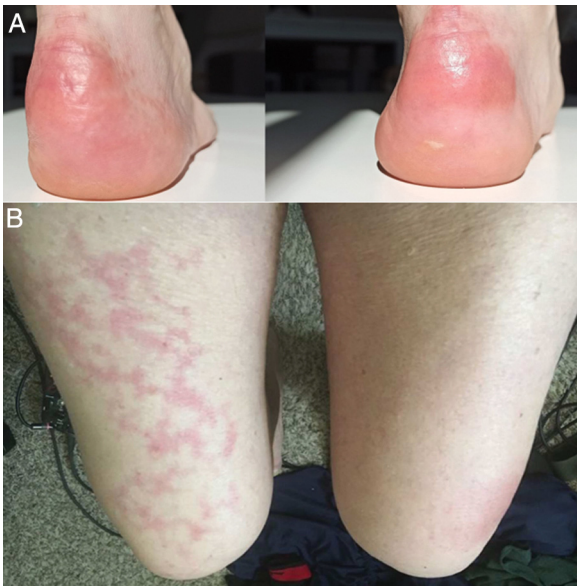
#### SARS-CoV-2 Infection and Onset of Nonspecific Rashes

There are 39 coronavirus species. Seven of these, including SARS-CoV-1, SARS-CoV-2, and MERS-CoV, affect humans.<sup>14</sup> The other viruses—HCoV-229E, HCoV-OC43, HCoV-NL63, and HCoV-HKU1—cause mild respiratory conditions such as the common cold. Like other respiratory viruses, many coronaviruses probably also cause viral rashes that go undetected because of the lack of specific testing.

The first report mentioning cutaneous manifestations in patients with COVID-19 was published by Guan et al.<sup>15</sup> in February 2020. The authors analyzed data for 1099 patients infected with SARS-CoV-2 and described 2 cases of skin lesions. They did not, however, specify the type of lesions or describe their clinical characteristics or time of onset, probably explaining why this early report was somewhat overlooked. The publication was followed by a report of a patient in Thailand presenting with a “morbilliform rash and multiple petechiae” and a low platelet count who was initially diagnosed with dengue and assigned to outpatient care.<sup>16</sup> The patient, however, returned with respiratory symptoms and was diagnosed with SARS-CoV-2 infection by reverse-transcript polymerase chain reaction (PCR). This report alerted physicians to the importance of investigating cutaneous manifestations in patients with COVID-19.<sup>17,18</sup>

The first large report of cutaneous manifestations in COVID-19 came from a cohort of 88 patients in Italy.<sup>19</sup> Of these, 18 (20.4%) had developed cutaneous manifestations: 8 during hospitalization and 10 following discharge. There were 14 cases of “erythematous rash”, 3 of “widespread urticaria”, and 1 of “chickenpox-like vesicles”. The vast majority of patients had trunk lesions, which were largely asymptomatic, resolved spontaneously, and did not appear to be associated with disease severity. Unfortunately, no photographs were taken due to the hospital policies in place at the time of the study.

As the days passed, new reports emerged of patients with confirmed SARS-CoV-2 infection and a range of very different cutaneous manifestations, including pruritic erythematous-yellowish plaques on the heels (Fig. 1A),<sup>20</sup> a morbilliform rash sparing acral sites,<sup>21</sup> a generalized maculopapular morbilliform rash with cephalocaudal progress,<sup>22</sup> urticaria-like



**Figure 1** A, Hardened erythematous-yellowish plaques on the heels. Source: Estébanez et al.<sup>20</sup> B, 67-year-old man with unilateral livedo reticularis on the right thigh. The patient also had gross hematuria. The hematuria and livedo both resolved within 24 hours. Source: Manalo et al.<sup>26</sup>

lesions,<sup>23,24</sup> a rash reminiscent of symmetrical drug-related intertriginous flexural exanthema,<sup>25</sup> and even livedo reticularis on the lower extremities (Fig. 1B).<sup>26</sup> As in the previous

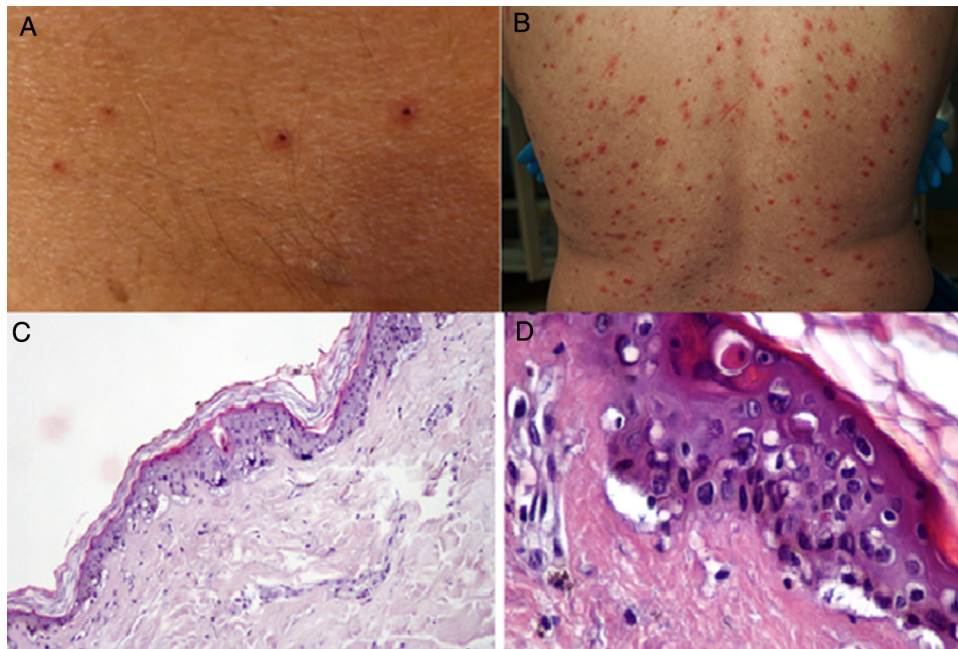
cases, biopsies were not performed due to hospital policies and the mild, self-limiting nature of the lesions.

In April, the *Journal of the American Academy of Dermatology* published a series of 22 patients with COVID-19 who developed a mild varicella-like rash after a median of 3 days from the onset of systemic symptoms; the rash cleared after a median of 8 days, leaving no residual scarring.<sup>27</sup> Most of the patients were male (72.7%) and the mean age was 60 years. The varicella-like lesions were predominantly vesicles and were scattered in 72.7% of cases and diffuse in 27.3%. The trunk was affected in all cases. None of the reports mentioned facial or mucosal involvement (Fig. 2A and B). The most common symptom, present in almost half of the patients, was mild pruritus. A skin biopsy performed in 7 patients showed findings consistent with an acute viral infection (Fig. 2C and D). The authors suggested that this type of rash might be a specific manifestation of SARS-CoV-2 infection and as such could be useful for raising suspicion of COVID-19 in patients with mild disease.

A later publication described the case of a man in the fourth decade of life with PCR-confirmed SARS-CoV-2 infection, fever, and concomitant nonpruritic, annular, circinate, erythematous-edematous fixed plaques on the neck, thorax, abdomen, and upper limbs (symmetric distribution) (Fig. 3A-C).<sup>28</sup> The lesions cleared after 7 days. The biopsy findings were consistent with a viral rash (Fig. 3D).

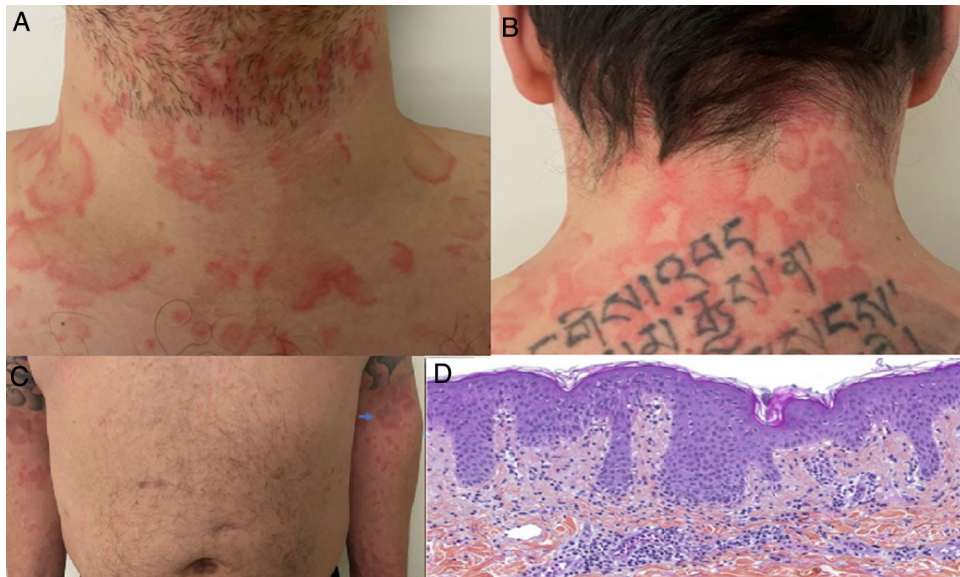
#### Cutaneous Manifestations Associated With Thrombosis or Microangiopathic Changes and Chilblain-like Lesions

The Chinese group led by Zhang<sup>29</sup> published a retrospective review of 7 patients with COVID-19 and pneumonia treated



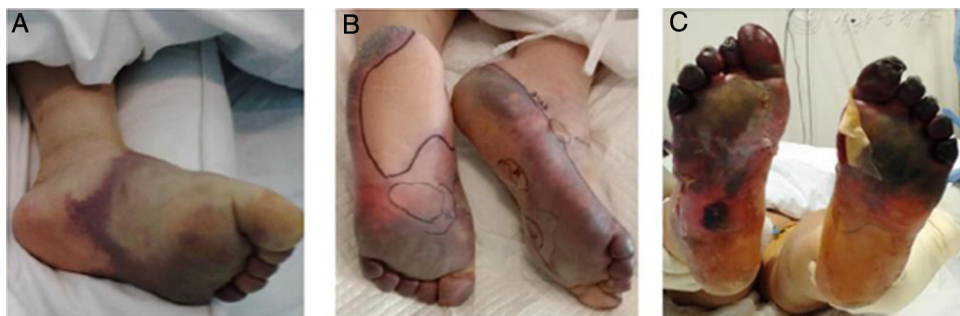**Figure 2** A and B, Patients with coronavirus disease 19 (COVID-19) with a papulovesicular rash on the trunk. Note the vesicles with a central varicella-like crust in the photograph on the left (A). C and D, Histopathologic changes in patients with COVID-19 and a varicella-like rash. C, Slightly atrophic epidermis, basket-weave hyperkeratosis, vacuolar degeneration of the basal layer with multinucleated, dyskeratotic hyperchromatic keratinocytes (hematoxylin-eosin, original magnification  $\times 10$ ). D, At higher magnification (hematoxylin-eosin, original magnification  $\times 40$ ), note the vacuolar alteration with disorganized keratinocytes with altered maturation and multinucleated keratinocytes with dyskeratotic cells.

Source: Marzano et al.<sup>27</sup>



**Figure 3** A and B, Erythematous-edematous annular and circinate plaques on the anterior and posterior neck. C, Note the symmetric distribution on the upper limbs. D, Superficial perivascular lymphocytic infiltrate, papillary dermal edema, mild spongiosis, lichenoid and vacuolar interface dermatitis, occasional polymorphonuclear cells in the dermal infiltrate (hematoxylin-eosin, original magnification  $\times 10$ ).

Source: Amatore et al.<sup>28</sup>



**Figure 4** Progressive worsening in a patient with coronavirus disease 2019 and acro-ischemic manifestations who developed bullae and finally dry gangrene on his feet.

Source: Zhang et al.<sup>29</sup>

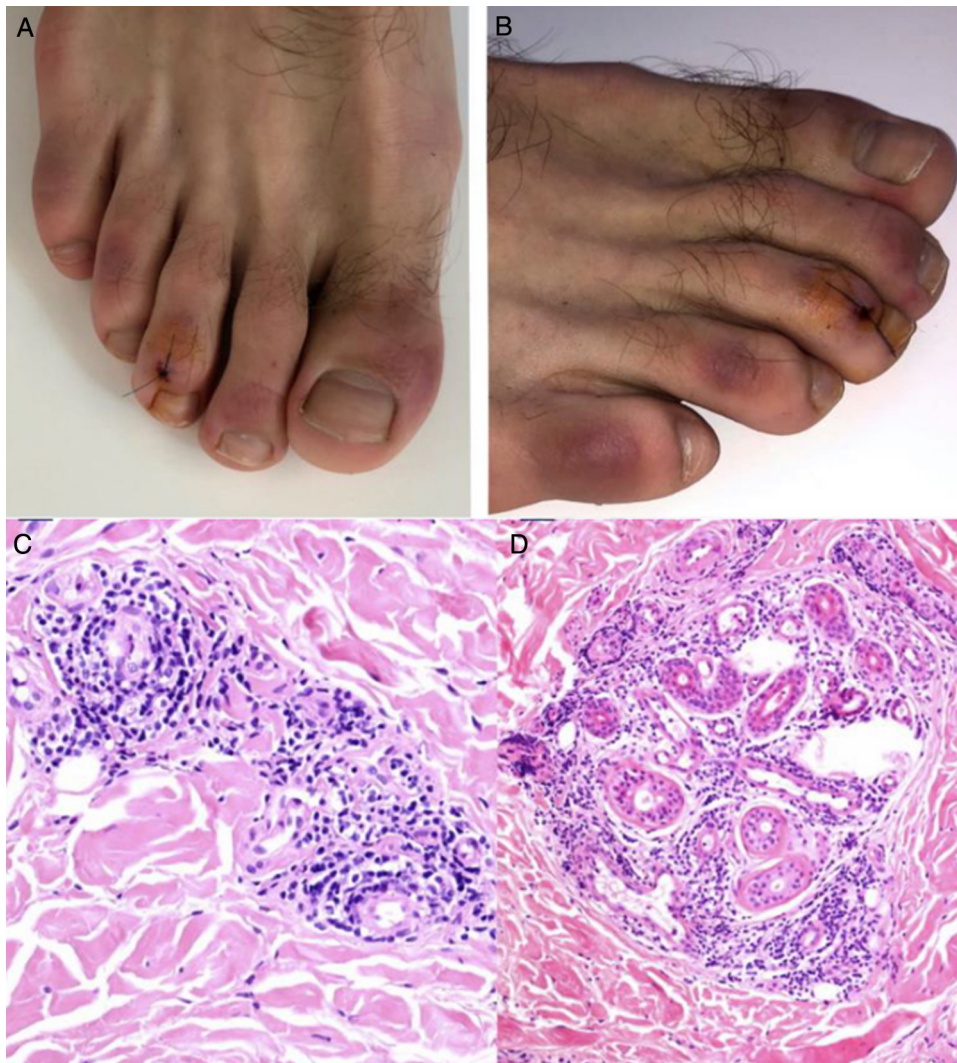
at an intensive care unit in Wuhan. The patients had multiple acro-ischemic manifestations, including acrocyanosis, retiform purpura, and gangrene (Fig. 4). Clinical and laboratory data were evaluated on admission to hospital, at the onset of the cutaneous manifestations, and after the use of anticoagulation therapy. They showed D-dimer, fibrinogen, and fibrinogen degradation product alterations related to the sequential events described. Five of the patients (71.42%) died. This was the first step in the formulation of a hypothesis on the existence of a hypercoagulable state per se in patients with SARS-CoV-2 infection.

Around the same time, multiple reports began to emerge from Europe, the Middle East, and the United States of chilblain-like lesions in young people who had been in close contact with a patient with confirmed or probable SARS-CoV-2 infection. The symptoms varied, but the chief complaints were pain and a burning sensation in the skin; the lesions

resolved spontaneously and none of the patients developed SARS-CoV-2 pneumonia.<sup>30–32</sup>

Kolivras et al.<sup>33</sup> reported the case of a young man who developed painful, acute-onset, violaceous plaques on the toes and lateral aspect of the feet (Fig. 5A and B) 3 days after the onset of upper respiratory symptoms. A skin biopsy showed findings consistent with chilblain lupus (Fig. 5C and D). The nasopharyngeal swab collected on admission was positive for SARS-CoV-2.

In view of the enormous impact of the pandemic on the European continent, numerous groups started to publish studies aimed at characterizing the chilblain-like lesions observed in patients with COVID-19.<sup>34</sup> In Italy, Recalcati et al.<sup>31</sup> and Tosti et al.<sup>35</sup> reported that these lesions were more common in younger patients (especially children [78.5%]), predominantly involved the feet (71% of cases), were self-limiting, and were associated with normal blood tests and an absence of systemic symptoms. A



**Figure 5** A and B, Hardened violaceous plaques against an erythematous background on the dorsal aspect of the toes and sides of the feet. C and D, Biopsy of lesion on third toe of right foot (hematoxylin-eosin). C, Note the lymphocytic infiltrate with occasional plasma cells in close contact with the vessels and no evidence of fibrin or thrombi (hematoxylin-eosin, original magnification  $\times 40$ ). D, Perieccrine infiltrate (hematoxylin-eosin, original magnification  $\times 40$ ).

Source: Kolivras et al.<sup>33</sup>

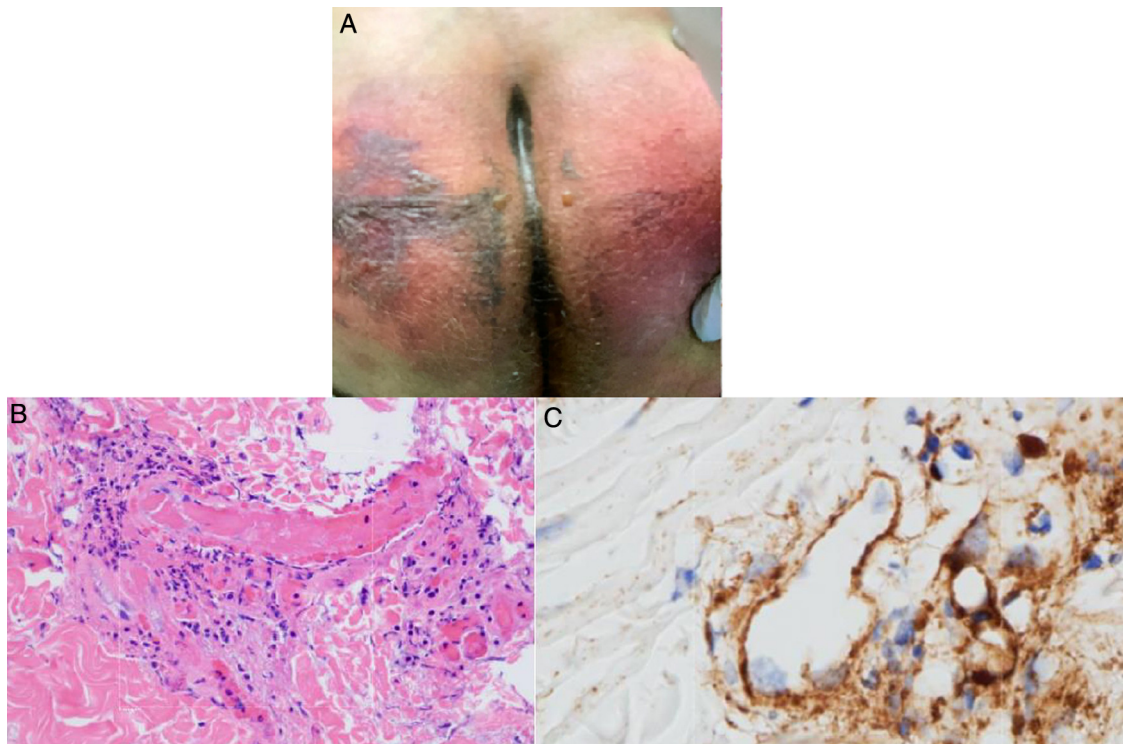
French study of skin lesions observed in 277 patients during 3 weeks of the COVID-19 pandemic found that 142 patients had acral lesions and that 106 of these (75%) were painful erythematous-violaceous edematous macules and papules consistent with chilblain lupus.<sup>36</sup> Fernández-Nieto et al<sup>37</sup> studied 132 nonhospitalized patients who consulted for acroischemic lesions over a period of 5 weeks. The mean age of the patients was 19.9 years; 40.9% had been in close contact with a patient with confirmed SARS-CoV-2 infection and 14.4% tested positive. Over 90% of the lesions affected the fingers or toes, but mostly the toes (81.8%). Similarly to the other cases reported, the patients experienced mild disease.

Magro et al.<sup>38</sup> reported on patients with COVID-19 who developed cutaneous manifestations consistent with a procoagulant or microangiopathic state. A skin biopsy was performed in 3 patients who developed retiform purpura or livedo racemosa (Fig. 6A) associated with elevated D-

dimer levels during the course of their respiratory illness, with findings showing pauci-inflammatory thrombogenic vasculopathy and C5b-9 and C4d deposition (Fig. 6B and C). This observation sparked the hypothesis of a link between mechanisms dependent on the alternative or lectin complement pathways and thrombotic events in patients with SARS-CoV-2 infection, and subsequently provided an explanation for the existence of procoagulant states in other organs.<sup>39</sup>

#### Spanish Consensus on the Classification of Cutaneous Manifestations of COVID-19

The *British Journal of Dermatology* published the results of a Spanish consensus study of 375 patients with confirmed or suspected SARS-CoV-2 infection who developed cutaneous manifestations without a clear explanation.<sup>40</sup> Numerous factors were evaluated over a period of 2 weeks, including clinical manifestations, time of onset in relation to other symptoms, demographics, and associations with



**Figure 6** A, 32-year-old man with coronavirus disease 2019 who developed retiform purpura on his buttocks 4 days after initiation of mechanical ventilation due to acute respiratory failure. B, Skin biopsy showing extensive pauci-inflammatory vascular thrombosis with endothelial cell injury (hematoxylin-eosin, original magnification  $\times 40$ ). C, C5b-9 deposits in microvessels (diaminobenzidine, original magnification  $\times 40$ ).

Source: Magro et al.<sup>3</sup>

disease course and outcomes. The group, led by Galván Casa, divided the manifestations into 5 clinical patterns: 1) pseudo-chilblains (19%), 2) vesicular eruptions (9%), 3) urticarial lesions (19%), 4) maculopapular eruptions (47%), and 5) livedoid or necrotic lesions (6%). They found that livedoid and necrotic lesions affected older patients (mean age, 63 years) with severe disease (mortality rate, 10%), while pseudo-chilblain lesions (acral areas of erythema and edema with vesicles or pustules) were more common after the onset of respiratory symptoms (59% of cases) and occurred in young patients (mean age, 21.8 years) with mild COVID-19. The survival rate of patients with maculopapular eruptions was 98%. The Spanish findings were consistent with reports from other authors, especially in terms of the mild nature of these chilblain-like lesions.<sup>30–33</sup>

## Pathophysiological Findings

### Pathophysiology of SARS-CoV-2 Infection and Possible Association With Cutaneous Manifestations

Laboratory findings in patients with severe SARS-CoV-2 infection include leukocytosis, neutrophilia, lymphopenia, thrombocytopenia, increased lactate dehydrogenase and procalcitonin levels, and D-dimer and fibrinogen degradation product alterations.<sup>41</sup> In some cases, these findings overlap with those observed in disseminated intravascular coagulation syndrome.<sup>42</sup> Lippi and Favoro<sup>43</sup> reported a directly proportional association between D-dimer levels

and severe respiratory illness in patients with SARS-CoV-2 infection, supporting previous reports showing a link between elevated D-dimer levels and mortality in COVID-19.<sup>42</sup>

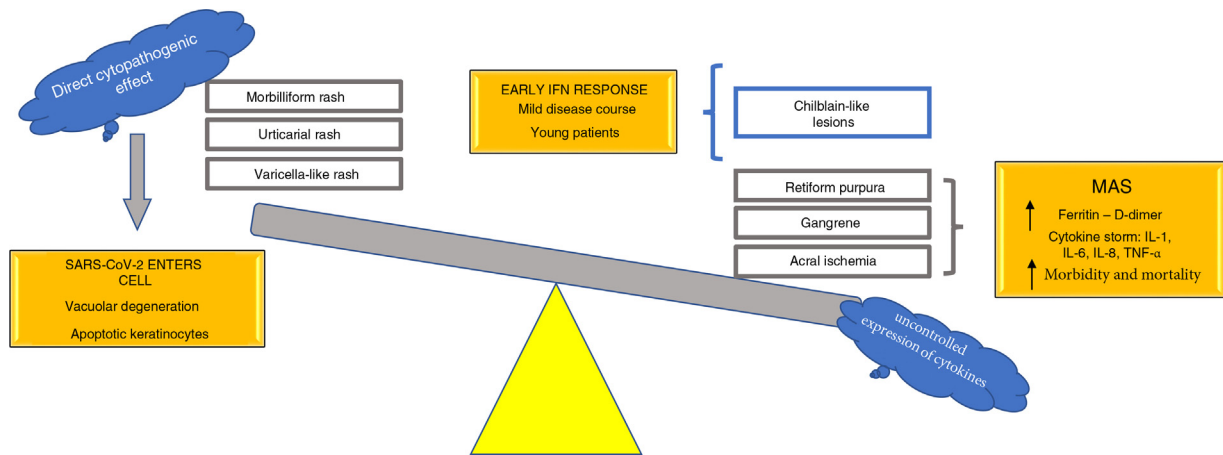
In humans, ferritin exerts a protective function during infection by limiting the amount of iron available to numerous pathogens,<sup>44</sup> explaining also why ferritin levels increase during inflammatory states.<sup>45</sup> Very high ferritin levels have been observed in patients with severe COVID-19 and linked to high morbidity and mortality.<sup>46</sup>

As mentioned, COVID-19 is characterized by a diverse range of biochemical changes. These changes, however, are reminiscent of findings observed in macrophage activation syndrome<sup>47</sup> and highlight the important role of white blood cells, in particular T cells and macrophages, in the exaggerated cytokine and thrombotic immune response associated with COVID-19.

### Macrophages and T Cells at the Root of Acro-Ischemic Lesions in COVID-19

Preliminary studies characterizing the novel coronavirus identified the angiotensin converting enzyme 2 (ACE<sub>2</sub>) receptor as the main receptor in SARS-CoV-2 infection.<sup>2</sup> SARS-CoV-2 uses the ACE<sub>2</sub> receptor to enter human cells and has no affinity for receptors used by other coronavirus families, such as the dipeptidyl peptidase 4 receptor.<sup>48</sup>

The ACE<sub>2</sub> receptor is found on the surface of pulmonary epithelial cells, in enterocytes of the small intestine, in arterial and venous endothelial cells, and in arterial



**Figure 7** Pathophysiological hypothesis on the spectrum of cutaneous manifestations associated with SARS-CoV-2 infection. IFN indicates interferon; IL, interleukin; MAS, macrophage activation syndrome; SARS-CoV-2, severe acute respiratory syndrome coronavirus 2; TNF- $\alpha$ , tumor necrosis factor alpha.

smooth muscle cells in numerous organs, including the skin.<sup>49</sup> Viral replication within cells causes direct cell injury, triggering the release of proinflammatory alarmins (direct viral effect). Viral particles can also trigger innate immune responses, including the activation of alveolar macrophages and the complement cascade through the lectin pathway.<sup>38,50</sup>

Complement activation and diverse immune responses promote the recruitment of leukocytes and an exaggerated proliferation of lymphocytes and massive release of proinflammatory cytokines (interleukin [IL] 1B, IL-6, IL-8), interferon-gamma (IFN- $\gamma$ ), and tumor necrosis factor alpha (TNF- $\alpha$ ), among others. IFN- $\gamma$ , in large quantities, drives macrophage activation and ferritin production,<sup>45</sup> IL-6 causes fever,<sup>51</sup> and hemophagocytosis causes pancytopenia.<sup>47,52</sup> Macrophages also release plasminogen activator, and this is possibly one of the many mechanisms that would explain the thrombotic events and elevated D-dimer levels observed in severe COVID-19.<sup>53</sup> It could also explain other findings such as the presence of antiphospholipid antibodies in patients with severe disease in the absence of comorbidities.<sup>54</sup> Bowles et al.<sup>55</sup> in the United Kingdom and Connel et al.<sup>56</sup> in the United States confirmed the presence of antiphospholipid antibodies (especially lupus anticoagulant) in patients with SARS-CoV-2 infection. This might be linked to the observation of acro-ischemic presentations (other than chilblain-like lesions), necrosis, and even livedo reticularis and racemosa in certain patients with COVID-19 and concomitant multisystemic thrombotic responses.

Viral sepsis has also been proposed to explain the systemic and cutaneous changes associated with COVID-19.<sup>57</sup> This hypothesis, which came about following multiple reports of multiorgan damage in autopsy studies of patients who had died of severe COVID-19,<sup>58</sup> holds that the massive release of cytokines, in particular TNF- $\alpha$ , would promote the death of infected cells via apoptosis-dependent pathways. In addition, SARS-CoV-2 may also be capable of infecting T cells, leading to lymphopenia.

There is sufficient evidence to support direct viral injury to endothelial cells followed by diffuse endothelial inflammation and consequently vascular endothelial apoptosis,<sup>59</sup>

raising the question of whether COVID-19 may actually be an endothelial disease.<sup>60</sup> This theory is supported by reports of death in patients with COVID-19 who had a history of diabetes mellitus or chronic cardiovascular disease and the observation of ischemic cutaneous manifestations, particularly at acral sites.

#### Association Between IFN and Chilblain-like Lesions

Patients with chilblain-like lesions,<sup>30-32</sup> apart from being apparently younger, experience mild COVID-19, while those with severe acro-ischemic manifestations, such as gangrene<sup>29</sup> and retiform purpura,<sup>38</sup> develop more severe disease. The milder forms of disease associated with chilblain-like lesions may be linked to type I IFN.

Kolivras et al.<sup>33</sup> highlighted the robust activation of type I IFN in SARS-CoV-2 infection, stating that a similar response was induced in many other acute viral infections.<sup>61</sup> Type I IFN levels are elevated in lupus erythematosus and interferonopathies such as Aicardi-Goutières syndrome, which is also characterized by microangiopathic changes at acral sites.<sup>62</sup> The authors hypothesized that these changes are the result of early type I IFN responses, which would also explain the mild disease course, as IFN exerts an antiviral effect. In addition, because early type I IFN responses are capable of suppressing the uncontrolled release of diverse proinflammatory cytokines, they would reduce the risk of a cytokine storm. Elderly patients, however, or patients with comorbidities that alter the functioning of the immune system, would generate a delayed type I IFN response, leading to the release of cytokines, macrophage activation syndrome, elevated ferritin and D-dimer levels, true acro-ischemic lesions, and a much worse prognosis.

## Discussion

The COVID-19 pandemic has created enormous challenges for health care professionals, including the need to keep abreast with the vast spectrum of clinical manifestations associated with this disease. COVID-19 is a multisystemic disease that affects multiple organs, including the skin. The



occurrence of cutaneous manifestations, however, represents an advantage, as their recognition can lead to early suspicion of disease in some cases and provide clues about individual immune responses or complications in others.

Based on the pathophysiological mechanisms hypothesized, we propose classifying the various cutaneous manifestations of COVID-19 into 2 groups: 1) manifestations primarily linked to a direct cytopathogenic effect on cells such as keratinocytes, which are involved in many known viral infections (morbilliform or urticarial rashes, reactions similar to drug eruptions, varicella-like lesions) and 2) manifestations linked to an uncontrolled release of cytokines due to alterations in specific white blood cells, such as T cells and macrophages. This second group could be divided into a further 2 groups: 1) manifestations characterized by features similar to those seen in macrophage activation syndrome (acral ischemia, gangrene, retiform purple, livedo racemosa) and associated with poor outcomes in terms of morbidity and mortality and 2) cutaneous manifestations with a mild, self-limiting disease course, observed in young patients and linked to the activation of an early type I IFN response (chilblain-like lesions) (Fig. 7). This hypothesis is one of the first in the literature to provide a possible explanation of the pathophysiological mechanisms underlying the main cutaneous manifestations of COVID-19; it also provides a means of classifying these manifestations and establishing their possible prognostic value.

We believe that it is paramount for physicians, nurses, respiratory therapists, health care professionals still in training, and even members of the general population to be aware of the relationship between SARS-CoV-2 infection and the skin and its various manifestations. Heightened awareness will promote an active search for manifestations and a detailed study of cases, adding to the scientific knowledge and our understanding of the pathophysiology of COVID-19 and ultimately contributing to the development of effective treatments and protocols that will mitigate the complications of this infection.

## Funding

This study did not receive any specific funding from public sector bodies or commercial or nonprofit entities.

## Conflicts of Interest

The authors declare that they have no conflicts of interest.

## Acknowledgments

To all the frontline health care professionals involved in caring for patients with COVID-19; their contribution to the history of medicine is invaluable.

## References

- Zhu N, Zhang D, Wang W, Li X, Yang B, Song J, et al. A novel coronavirus from patients with pneumonia in China, 2019. *N Engl J Med*. 2020;382:727–33, <http://dx.doi.org/10.1056/NEJMoa2001017>.
- Zhou P, Yang X, Wang X, Hu B, Zhang L, Zhang W, et al. A pneumonia outbreak associated with a new coronavirus of probable bat origin. *Nature*. 2020;579:270–3, <http://dx.doi.org/10.1038/s41586-020-2012-7>.
- Wu Z, McGoogan JM. Characteristics of and important lessons from the coronavirus disease 2019 (COVID-19) outbreak in China: Summary of a report of 72 314 cases from the Chinese Center for Disease Control and Prevention. *JAMA*. 2020;323(13):1239–42, <http://dx.doi.org/10.1001/jama.2020.2648>.
- Perlman S. Another decade, another coronavirus. *N Engl J Med*. 2020;382:760–2, <http://dx.doi.org/10.1056/NEJMe2001126>.
- Novel Coronavirus Pneumonia Emergency Response Epidemiology Team. The epidemiological characteristics of an outbreak of 2019 novel coronavirus diseases (covid-19) in China. *Zhonghua Liu Xing Bing Xue Za Zhi*. 2020;41(2):145–51, <http://dx.doi.org/10.3760/cma.j.issn.0254-6450.2020.02.003>.
- Petrosillo N, Viceconte G, Ergonul O, Ippolito G, Petersen E. COVID-19, SARS and MERS: Are they closely related? *Clin Microbiol Infect*. 2020;26(6):729–34, <http://dx.doi.org/10.1016/j.cmi.2020.03.026>.
- van Doremalen N, Bushmaker T, Morris DH, Holbrook MG, Gamble A, Williamson BN, et al. Aerosol and surface stability of SARS-CoV-2 as compared with SARS-CoV-1. *N Engl J Med*. 2020;382:1564–7, <http://dx.doi.org/10.1056/NEJMc2004973>.
- Lauer SA, Grantz KH, Bi Q, Jones F, Zheng Q, Meredith H, et al. The incubation period of coronavirus disease 2019 (COVID-19) from publicly reported confirmed cases: Estimation and application. *Ann Intern Med*. 2020;172(9):577–82, <http://dx.doi.org/10.7326/M20-0504>.
- Zhou F, Yu T, Du R, Fan G, Liu Y, Liu Z, et al. Clinical course and risk factors for mortality of adult inpatients with COVID-19 in Wuhan, China: A retrospective cohort study. *Lancet*. 2020;395(10229):P1054-1062. [https://doi.org/10.1016/S0140-6736\(20\)30566-3](https://doi.org/10.1016/S0140-6736(20)30566-3).
- Lescure FX, Bouadma L, Nguyen D, Parisey M, Wicky P, Behillil S, et al. Clinical and virological data of the first cases of COVID-19 in Europe: A case series. *Lancet Infect Dis*. 2020;20(6):697–706, [http://dx.doi.org/10.1016/S1473-3099\(20\)30200-0](http://dx.doi.org/10.1016/S1473-3099(20)30200-0).
- Jordan RE, Adab P, Cheng KK. Covid-19: Risk factors for severe disease and death. *BMJ*. 2020;368:m1198, <http://dx.doi.org/10.1136/bmj.m1198>.
- Yang J, Zheng Y, Gou X, Pu K, Chen Z, Guo Q, et al. Prevalence of comorbidities and its effects in coronavirus disease 2019 patients: A systematic review and meta-analysis. *Int J Infect Dis*. 2020;94:91–5, <http://dx.doi.org/10.1016/j.ijid.2020.03.017>.
- Shi Y, Yu X, Zhao H, Wang H, Zhao R, Sheng J, et al. Host susceptibility to severe COVID-19 and establishment of a host risk score: Findings of 487 cases outside Wuhan. *Crit Care*. 2020;24:242, <http://dx.doi.org/10.1186/s13054-020-2833-7>.
- Millán-Oñate J, Rodríguez-Morales A, Camacho-Moreno G, Mendoza-Ramírez H, Rodríguez-Sabogal I, Álvarez-Moreno C. A new emerging zoonotic virus of concern: The 2019 novel Coronavirus. *Infectio*. 2020;24(3):187–92, <http://dx.doi.org/10.22354/in.v24i3.848>.
- Guan W, Ni Z, Hu Y, Liang W, Ch Ou, He J, et al. Clinical characteristics of coronavirus disease 2019 in China. *N Engl J Med*. 2020, <http://dx.doi.org/10.1056/NEJMoa2002032>.
- Joob B, Wiwanitkit V. COVID-19 can present with a rash and be mistaken for Dengue. *J Am Acad Dermatol*. 2020;82(5):e177, <http://dx.doi.org/10.1016/j.jaad.2020.03.036>.
- Joob B, Wiwanitkit V. Various forms of skin rash in COVID-19: A reply. *J Am Acad Dermatol*. 2020, <http://dx.doi.org/10.1016/j.jaad.2020.04.035>.
- Chen Y, Pradhan S, Xue S. What are we doing in the dermatology outpatient department amidst the raging of the

- 2019 novel coronavirus? *J Am Acad Dermatol.* 2020;82(4):1034, <http://dx.doi.org/10.1016/j.jaad.2020.02.030>.
19. Recalcati S. Cutaneous manifestations in COVID-19: A first perspective. *J Eur Acad Dermatol Venereol.* 2020;34(5), e212-213. [10.1111/jdv.16387](https://doi.org/10.1111/jdv.16387).
  20. Estébanez A, Pérez-Santiago L, Silva E, Guillen-Climent S, García-Vázquez A, Ramón MD. Cutaneous manifestations in COVID-19: a new contribution. *J Eur Acad Dermatol Venereol.* 2020;34(6), e250-251. [10.1111/jdv.16474](https://doi.org/10.1111/jdv.16474).
  21. Hunt M, Koziatek C. A case of COVID-19 pneumonia in a young male with full body rash as a presenting symptom. *Clin Pract Cases Emerg Med.* 2020;4(2):219–21, <http://dx.doi.org/10.5811/cpcem.2020.3.47349>.
  22. Avellana Moreno R, Villa E, Avellana Moreno V, Estela Villa C, Aparicio M, Fontanella A. Cutaneous manifestation of COVID-19 in images: A case report. *J Eur Acad Dermatol Venereol.* 2020;34(7), e307-309. <https://doi.org/10.1111/jdv.16531>.
  23. Henry D, Ackerman M, Sancelme E, Finon A, Esteve E. Urticarial eruption in COVID-19 infection. *J Eur Acad Dermatol Venereol.* 2020;34(6), e244-245. <https://doi.org/10.1111/jdv.16472>.
  24. Van Damme C, Berlingin E, Saussez S, Accaputo O. Acute urticaria with pyrexia as the first manifestations of a COVID-19 infection. *J Eur Acad Dermatol Venereol.* 2020;34(7), e300-301. <https://doi.org/10.1111/jdv.16523>.
  25. Mahé A, Birckel E, Krieger S, Merklen C, Bottlaender L. A distinctive skin rash associated with Coronavirus Disease 2019? *J Eur Acad Dermatol Venereol.* 2020;34(6), e246-247. <https://doi.org/10.1111/jdv.16471>.
  26. Manalo IF, Smith MK, Cheeley J, Jacobs R. A Dermatologic Manifestation of COVID-19: Transient Livedo Reticularis. *Journal of the American Academy of Dermatology.* 2020;83(2):P700, <http://dx.doi.org/10.1016/j.jaad.2020.04.018>.
  27. Marzano AV, Genovese G, Fabbrocini G, Pigatto P, Monfrecola G, Piraccini BM, et al. Varicella-like exanthem as a specific COVID-19-associated skin manifestation: multicenter case series of 22 patients [published online ahead of print, 2020 Apr 16]. *J Am Acad Dermatol.* 2020;83(1):280–5, <http://dx.doi.org/10.1016/j.jaad.2020.04.044>.
  28. Amatore F, Macagno N, Mailhe M, Demarez B, Gaudy-Marqueste C, Grob JJ, et al. SARS-CoV-2 infection presenting as a febrile rash. *J Eur Acad Dermatol Venereol.* 2020;34(7):304–6, <http://dx.doi.org/10.1111/jdv.16528>.
  29. Zhang Y, Cao W, Xiao M, Li YJ, Yang Y, Zhao J, et al. Clinical and coagulation characteristics of 7 patients with critical COVID-2019 pneumonia and acro-ischemia. *Zhonghua Xue Ye Xue Za Zhi.* 2020;41(0):E006, [10.3760/cma.j.issn.0253-2727.2020.0006](https://doi.org/10.3760/cma.j.issn.0253-2727.2020.0006).
  30. Alramthan A, Aldaraji W. A case of COVID-19 presenting in clinical Picture resembling chilblains disease. First report from the Middle East. *Clin Exp Dermatol.* 2020;45(6):746–8, <http://dx.doi.org/10.1111/ced.14243>.
  31. Recalcati S, Barbagallo T, Frasin LA, Prestinari F, Cogliardi A, Provero MC, et al. Acral Cutaneous Lesions in the Time of COVID-19. *J Eur Acad Dermatol Venereol.* 2020;34(8):346–7, <http://dx.doi.org/10.1111/jdv.16533>.
  32. Piccolo V, Neri I, Filippeschi C, Oranges T, Argenziano G, Battarra VC, et al. Chilblain-like lesions during COVID-19 epidemic: A preliminary study on 63 patients. *J Eur Acad Dermatol Venereol.* 2020;34(7):291–3, <http://dx.doi.org/10.1111/jdv.16526>.
  33. Kolivras A, Dehavay F, Delplace D, Feoli F, Meiers I, Milone L, et al. Coronavirus (COVID-19) infection-induced chilblains: a case report with histopathological findings. *JAAD Case Reports.* 2020;6(6):489–92, <http://dx.doi.org/10.1016/j.jdc.2020.04.011>.
  34. Carrascosa JM, et al. Manifestaciones cutáneas en el contexto de la infección por SARS-CoV-2 (COVID-19). *Actas Dermosifiliogr.* 2020, <http://dx.doi.org/10.1016/j.ad.2020.08.002>.
  35. Tosti G, Barisani A, Queirolo P, Pennacchioli E, Villa L, Lodeserto AM, et al. Skin Signs Resembling Vascular Acrosyndromes During the COVID-19 Outbreak in Italy. *Clin Exp Dermatol.* 2020;45(6):757–8, <http://dx.doi.org/10.1111/ced.14267>.
  36. de Masson A, Bouaziz J-D, Sulimovic L, Cassius C, Jachiet M, Lonescu M-A, et al. Chilblains are a common cutaneous finding during the COVID-19 pandemic: a retrospective nationwide study from France. *J Am Acad Dermatol.* 2020;83(2):667–70, <http://dx.doi.org/10.1016/j.jaad.2020.04.161>.
  37. Fernandez-Nieto D, Jimenez-Cauhe J, Suarez-Valle A, Moreno-Arrones OM, Saceda-Corralo D, Arana-Raja A, et al. Characterization of acute acro-ischemic lesions in non-hospitalized patients: a case series of 132 patients during the COVID 19 outbreak. *J Am Acad Dermatol.* 2020;83(1):61–3, <http://dx.doi.org/10.1016/j.jaad.2020.04.093>.
  38. Magro C, Mulvey J, Berlin D, Nuovo G, Salvatore S, Harp J, et al. Complement associated microvascular injury and thrombosis in the pathogenesis of severe COVID-19 infection: A report of five cases. *Translational Research.* 2020;220:1–13, <http://dx.doi.org/10.1016/j.trsl.2020.04.007>.
  39. Cui S, Chen S, Li X, Liu S, Wang F. Prevalence of venous thromboembolism in patients with severe novel coronavirus pneumonia. *J Thromb Haemost.* 2020;18(6):1421–4, <http://dx.doi.org/10.1111/jth.14830>.
  40. Galván Casas C, Català A, Carretero Hernández G, Rodríguez-Jiménez P, Fernández Nieto D, Rodríguez-Villa Lario A, et al. Classification of the cutaneous manifestations of COVID-19: a rapid prospective nationwide consensus study in Spain with 375 cases. *Br J Dermatol.* 2020;183(1):71–7, <http://dx.doi.org/10.1111/bjd.19163>.
  41. Lippi G, Plebani M. Laboratory abnormalities in patients with COVID-2019 infection. *Clin Chem Lab Med.* 2020;58(7), <http://dx.doi.org/10.1515/cclm-2020-0198>.
  42. Wang YD, Zhang SP, Wei QZ, Zhao MM, Mei H, Zhang ZL, et al. COVID-19 complicated with DIC: 2 cases report and literatures review. *Zhonghua Xue Ye Xue Za Zhi.* 2020;41(0):E001, <http://dx.doi.org/10.3760/cma.j.issn.0253-2727.2020.0001>.
  43. Lippi G, Favaloro EJ. D-dimer is Associated with Severity of Coronavirus Disease 2019: A Pooled Analysis. *Thromb Haemost.* 2020;120(5):876–8, <http://dx.doi.org/10.1055/s-00401709650>.
  44. Pieracci FM, Barie PS. Iron and the risk of infection. *Surg Infect (Larchmt).* 2005;6. S41-6. [10.1089/sur.2005.6.s1-41](https://doi.org/10.1089/sur.2005.6.s1-41).
  45. Kernan KF, Carcillo JA. Hyperferritinemia and inflammation. *Int Immunol.* 2017;29(9):401–9, [10.1093/intimm/dxx031](https://doi.org/10.1093/intimm/dxx031).
  46. Zhou B, She J, Wang Y, Ma X. Utility of Ferritin, Procalcitonin, and C-reactive Protein in Severe Patients with 2019 Novel Coronavirus Disease. *Research Square.* 2020, <http://dx.doi.org/10.21203/rs.3.rs18079/v1>.
  47. Bracaglia C, Prencipe G, De Benedett F. Macrophage Activation Syndrome: different mechanisms leading to a one clinical syndrome. *Pediatr Rheumatol.* 2017;15(5), <http://dx.doi.org/10.1186/s12969-016-0130-4>.
  48. Raj VS, Mou H, Smits SL, Dekkers DH, Müller MA, Dijkman R, et al. Dipeptidyl peptidase 4 is a functional receptor for the emerging human coronavirus-EMC. *Nature.* 2013;495(7440):251–4, <http://dx.doi.org/10.1038/nature12005>.
  49. Hamming I, Timens W, Bulthuis ML, Lely AT, Navis G, van Goor H. Tissue distribution of ACE2 protein, the functional receptor for SARS coronavirus. A first step in understanding SARS pathogenesis. *J Pathol.* 2004;203(2):631–7, <http://dx.doi.org/10.1002/path.1570>.
  50. Ciceri F, Beretta L, Scandroglio AM, Colombo S, Landoni G, Ruggeri A, et al. Microvascular COVID-19 lung vessels obstructive thromboinflammatory syndrome (Micro-CLOTS): An atypical acute respiratory distress syndrome

- working hypothesis. *Crit Care Resusc.* 2020;31(5):685–90, <http://dx.doi.org/10.1080/09537104.2020.1775189>.
51. Eskilsson A, Mirrasekhian E, Dufour S, Schwaninger M, Engblom D, Blomqvist A. Immune-induced fever is mediated by IL-6 receptors on brain endothelial cells coupled to STAT3-dependent induction of brain endothelial prostaglandin synthesis. *J Neurosci.* 2014;34(48):15957–61, <http://dx.doi.org/10.1523/JNEUROSCI.3520-14.2014>.
  52. Gauna M, Bernava J. Recomendaciones diagnósticas y terapéuticas ante la Respuesta Inmune Trombótica Asociada a Covid-19 (RITAC). *CorSalud.* 2020;12(1) <http://www.revcorsalud.sld.cu/index.php/cors/article/view/615>
  53. Tang N, Bai H, Chen X, Gong J, Li D, Sun Z. Anticoagulant treatment is associated with decreased mortality in severe coronavirus disease 2019 patients with coagulopathy. *J. Thromb. Haemost.* 2020;18(5), 1094-99. [10.1111/jth.14817](https://doi.org/10.1111/jth.14817).
  54. Zhang Y, Xiao M, Zhang S, Xia P, Cao W, Jiang W, et al. Coagulopathy and antiphospholipid antibodies in patients with Covid-19. *N Engl J Med.* 2020;382(17):e38, <http://dx.doi.org/10.1056/NEJMc2013656>.
  55. Bowles L, Platton S, Yartey N, Dave M, Lee K, Hart D, et al. Lupus anticoagulant and abnormal coagulation tests in patients with Covid-19. *N Engl J Med.* 2020. [NEJMc2013656. 10.1056/NEJMc2013656](https://doi.org/10.1056/NEJMc2013656).
  56. Connell N, Battinelli E, Connors J. Coagulopathy of COVID-19 and Antiphospholipid Antibodies. *J Thromb Haemost.* 2020, <http://dx.doi.org/10.1111/jth.14893>.
  57. Li H, Liu L, Zhang D, Xu J, Dai H, Tang N, et al. SARS-CoV-2 and viral sepsis: Observations and hypotheses. *The Lancet.* 2020;395(10235):1517–20, [http://dx.doi.org/10.1016/S0140-6736\(20\)30920-X](http://dx.doi.org/10.1016/S0140-6736(20)30920-X).
  58. Yao XH, Li TY, He ZC, Ping YF, Liu HW, Yu SC, et al. A pathological report of three COVID-19 cases by minimally invasive autopsies. *Chinese Journal of Pathology.* 2020;49(5):411–7, <http://dx.doi.org/10.3760/cma.j.cn112151-20200312-00193>.
  59. Varga Z, Flammer AJ, Steiger P, Haberecker M, Andermatt R, Zinkernagel AS, et al. Endothelial cell infection and endotheliitis in COVID-19. *Lancet.* 2020;395(10234):1417–8, [http://dx.doi.org/10.1016/S0140-6736\(20\)30937-5](http://dx.doi.org/10.1016/S0140-6736(20)30937-5).
  60. Sardu C, Gambardella J, Morelli MB, Wang X, Marfella R, Santulli G. Is COVID-19 an Endothelial Disease? *Clinical and Basic Evidence. Preprints.* 2020, [2020040204. 10.20944/preprints202004.0204.v1](https://doi.org/10.20944/preprints202004.0204.v1).
  61. Ivashkiv L, Donlin L. Regulation of type I interferon responses. *Nat Rev Immunol.* 2014;14:36–49, <http://dx.doi.org/10.1038/nri3581>.
  62. Kolivras A, Aebly A, Crow YJ, Rice GI, Sass U, André J. Cutaneous histopathological findings of Aicardi-Goutières syndrome, overlap with chilblain lupus. *J Cutan Pathol.* 2008;35(8):774–8, <http://dx.doi.org/10.1111/j.1600-0560.2007.00900.x>.