



Contents lists available at ScienceDirect

International Journal of Surgery Case Reports

journal homepage: www.casereports.com

Extreme oncoplastic breast surgery: A case report

Daniele Bordoni^a, Pierfrancesco Cadenelli^b, Giuseppe Falco^c, Nicola Rocco^{d,*}, Paola Manna^e, Ariel Tessone^f, Matteo Ornelli^g, Cesare Magalotti^a^a Department of Senology, Asur Marche Area Vasta 1, Santa Maria della Misericordia, Via Comandino 70, Urbino, Italy^b Department of Plastic and Reconstructive Surgery, San Gerardo Hospital, Monza, Italy^c Breast Surgery Unit, IRCCS-Arcispedale Santa Maria Nuova, Viale Risorgimento 80, 42123 Reggio Emilia, Italy^d Department of Clinical Medicine and Surgery, University of Naples "Federico II", Naples, Italy^e Department of Radiology, Asur Marche Area Vasta 1, Santa Maria della Misericordia Hospital, Via Comandino 70, Urbino, Italy^f Department of Plastic and Reconstructive Surgery, The Talpiot Medical Leadership Program, Sheba Medical Center, Israel^g Department of Plastic Surgery, Polytechnic University of Marche, Ancona, Italy

ARTICLE INFO

Article history:

Received 12 July 2016

Received in revised form

24 September 2016

Accepted 25 September 2016

Available online 28 September 2016

Keywords:

Breast cancer

Breast surgery

Oncoplastic surgery

Case report

ABSTRACT

INTRODUCTION: So called "extreme oncoplastic surgery" is emerging as a new promising concept in breast cancer surgery allowing successful breast conservation in selected patients with multicentric tumors.**PRESENTATION OF CASE:** We report the case of a 48-year-old woman presenting with a multicentric breast cancer and successfully treated with an oncoplastic technique consisting in three radical lumpectomies followed by breast reshaping and simultaneous contralateral symmetrization.**DISCUSSION:** According to our experience, oncoplastic conserving breast surgery could represent a better option than the combination of mastectomy, reconstruction and radiation therapy, in terms of quality of life for selected patients affected by multicentric breast cancer.**CONCLUSION:** The surgical treatment for multicentric breast cancers remains controversial even though emerging evidences show good oncological and aesthetic outcomes following oncoplastic conserving breast surgery.© 2016 The Authors. Published by Elsevier Ltd on behalf of IJS Publishing Group Ltd. This is an open access article under the CC BY-NC-ND license (<http://creativecommons.org/licenses/by-nc-nd/4.0/>).

1. Introduction

Tumor excision achieving free margins represented the only goal for breast surgeons for many years. Nowadays Breast Conserving Surgery (BCS) represents the gold standard for early stage breast cancer surgical treatment allowing the same long term survival rates as for patients treated with radical mastectomy [1,2].

The modern approach of Oncoplastic Breast Surgery (OPBS) combines the oncological radicality of BCS with the optimal aesthetic result.

The breast reshaping after wide excision is followed by contralateral breast symmetrization in order to reach a pleasant final aesthetic result in a one-stage procedure.

Many oncoplastic approaches have been proposed during the last decades but few cases have been described for multifocal or multicentric cancers [3–9].

So called "extreme oncoplastic surgery" is emerging as a new promising concept in breast cancer surgery.

It allows successful breast conservation in selected patients with multicentric tumors.

According to some authors' experience, it could represent a better option than the combination of mastectomy, reconstruction and radiation therapy, from a quality of life point of view [10].

Moreover we must consider that a good cosmetic result following breast conservation allows the patient to live her life with a normal breast with almost completely preserved sensitivity.

We present an extreme application of oncoplastic breast surgery in a case of multicentric breast cancer, in accordance with the SCARE Statement criteria [11].

2. Case report

In January 2015 a 48-year-old woman presented at our observation for breast cancer surgical treatment. She had her breast cancer diagnosis after a screening mammographic examination.

Mammography showed typical features of breast cancer while ultrasonography did not show any typical pattern of neoplasia. Irregular calcifications were detected by mammographic examination in three breast quadrants: infero-central (18 mm), middle-outer (19 mm) and supero-central (8 mm) (Figs. 1–3).

A stereotactic biopsy was performed at the level of the three mammographic suspected areas. Histological findings demonstrated the evidence of malignancy in all the mentioned areas (B5, low grade ductal carcinoma in situ).

* Corresponding author.

E-mail address: nicolarocco2003@gmail.com (N. Rocco).

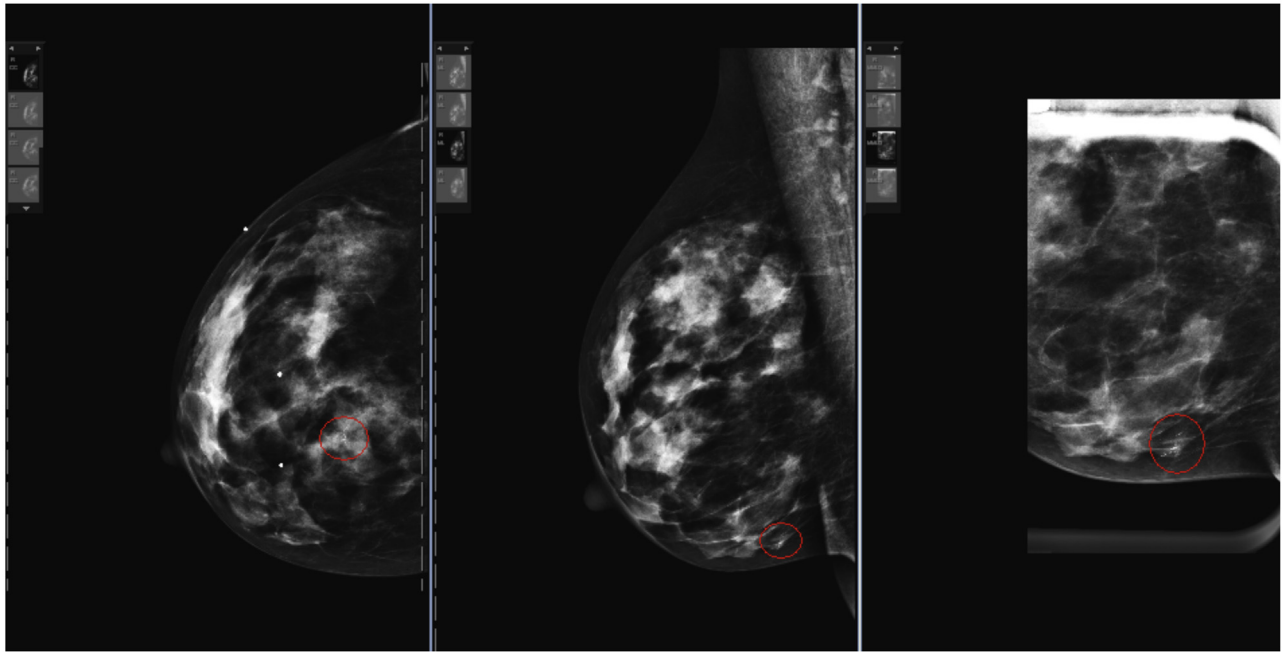


Fig. 1. Mammography shows the infero-central micro-calcifications. (a: cranio-caudal projection, b: medio-lateral projection, c: oblique magnification detail)

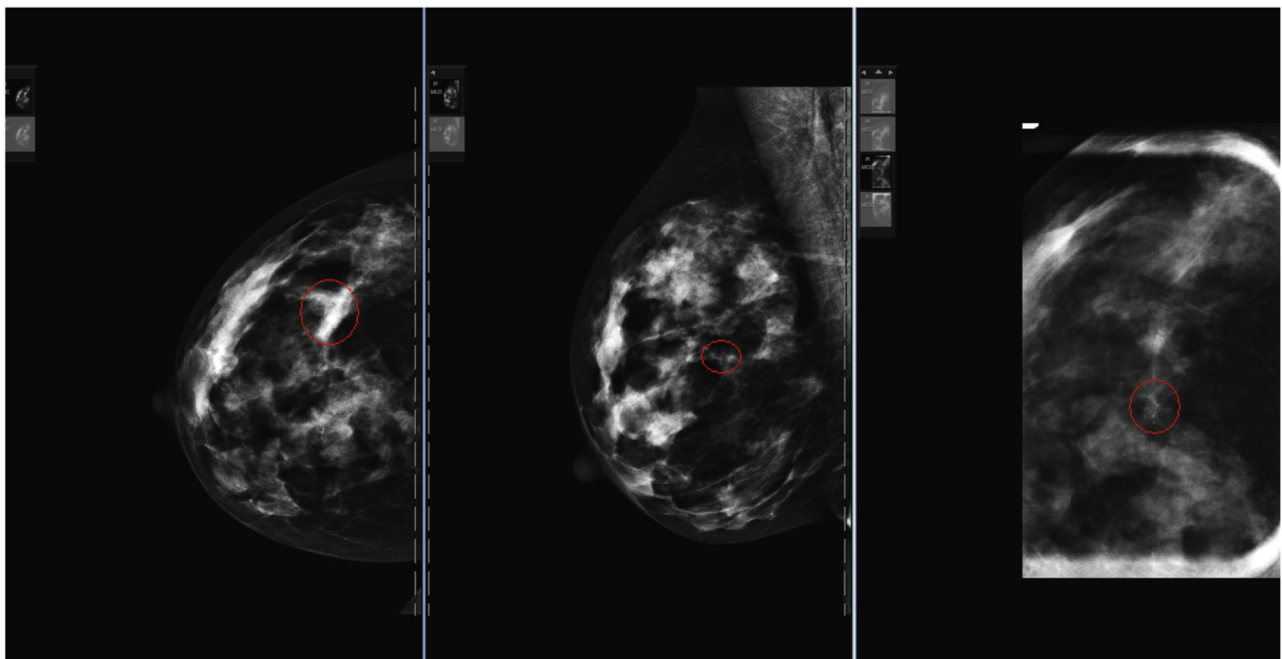


Fig. 2. Mammography shows the middle-outer micro-calcifications. (a: cranio-caudal projection, b: medio-lateral projection, c: cranio-caudal magnification detail)

Patient's general conditions were good and no systemic pathologies were noted.

Breast volume was considered adequate to perform breast conserving surgery (BCS). Physical examination did not reveal any palpable lesion; axillary lymphadenopathy and skin infiltration were not observed.

In order to perform BCS we localized the three lesions using Tc99-MAA (Technetium 99m Albumin Aggregated); the sentinel lymph node was localized pre-operatively injecting Tc99m-nanocoll.

We performed three radio-guided cancer resections with wide margins (more than 10 mm). All specimens were sent for

radiographic examination showing the radicality of the excision (Figs. 4–6).

A therapeutic inferior pedicle mammoplasty was performed achieving radical resection of the three clusters of microcalcifications.

Then we performed sentinel lymph-node biopsy (SNLB) that was found to be negative for metastasis at intra-operative frozen section and finally we approached the breast reshaping and the contralateral breast symmetrization with a reduction mastoplasty with a supero-medial pedicle (Fig. 7).

The definitive histopathological examination revealed for all the three excised lesions low grade ductal carcinoma in situ (DCIS).

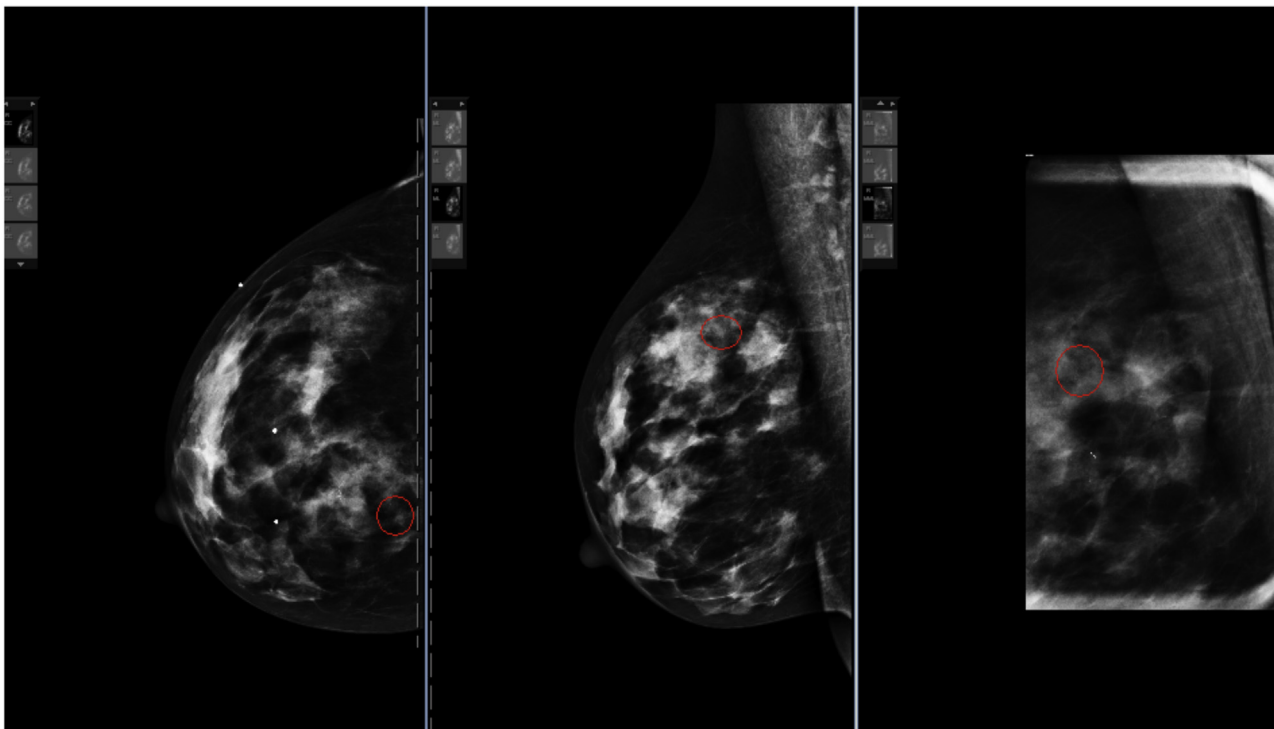


Fig. 3. Mammography shows the supero-central micro-calcifications.

(a: cranio-caudal projection, b: medio-lateral projection, c: oblique magnification detail)

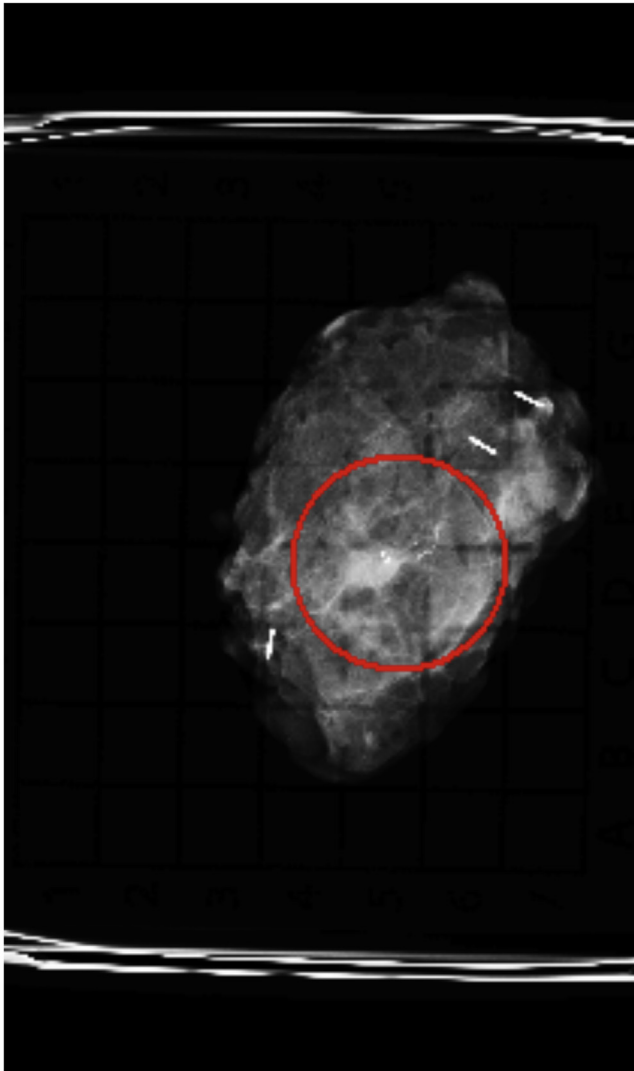


Fig. 4. Radiographic examination showing the radicality of the infero-central lumpectomy.

One day after surgery we discharged the patient who showed clinical stability and a pleasant aesthetic result at 1 month (Fig. 8).

3. Discussion

The conserving surgical approach represents over 70% of breast cancer surgical treatment in many European countries; breast surgeons should consider breast conserving surgery as the treatment of choice when technically feasible and oncologically safe [12–15].

BCS followed by radiotherapy presents outcomes and overall survival comparable with patients treated with mastectomy [16–20].

In cases requiring large excisions, the oncoplastic techniques represent the only way to avoid major deformities of the breast. Clough et. al developed a suitable oncoplastic atlas offering a quadrant per quadrant solution [7].

OPBS leads to better cosmetic results if compared with standard conserving approaches and the immediate positive psychological impact on the patient is evident.

Moreover some authors presented better results in terms of quality of life with breast conservation when compared with mastectomy, reconstruction and radiation therapy, because the patients have a better-perceived body image [21].

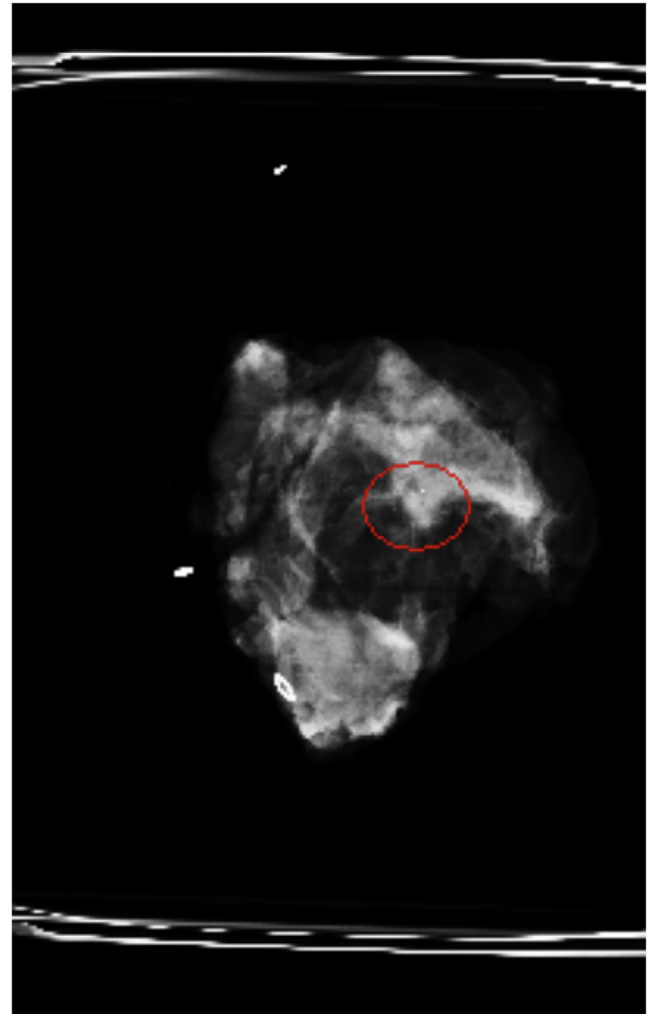


Fig. 5. Radiographic examination showing the radicality of the middle-outer lumpectomy.

Positive margins seem to be less frequent following oncoplastic breast surgery when compared with traditional BCS [22–24].

However, we do not have long-term data on oncological outcome of so-called “extreme oncoplastic surgery”.

Breast conserving therapy bases its rationale on the historical randomized controlled trials of the 1970s [16–20], where the maximum allowed tumor size was 5 cm, so we do not have level I evidences about breast preservation in patients with tumors larger than 5 cm.

Nowadays the use of oncoplastic techniques allows the complete excision of tumors even larger than 5 cm with an acceptable aesthetic result. Moreover the standard for adequate surgical margins is nowadays no ink on tumor [25], so the probability of an oncologically safe procedure increases.

Post-mastectomy radiation therapy (PMRT) could increase the complication rate of implant-based breast reconstruction. Timing of reconstruction in relation of the radiation therapy timing still remains issue of debate [26].

Autologous flap reconstructions could improve outcomes in radiotreated patients, but not all patients would like to undergo complex and longer interventions with possible significant morbidity and a longer hospital stay.

Furthermore avoiding the use of breast implants allows an inferior number of surgical interventions with obvious economical implications.

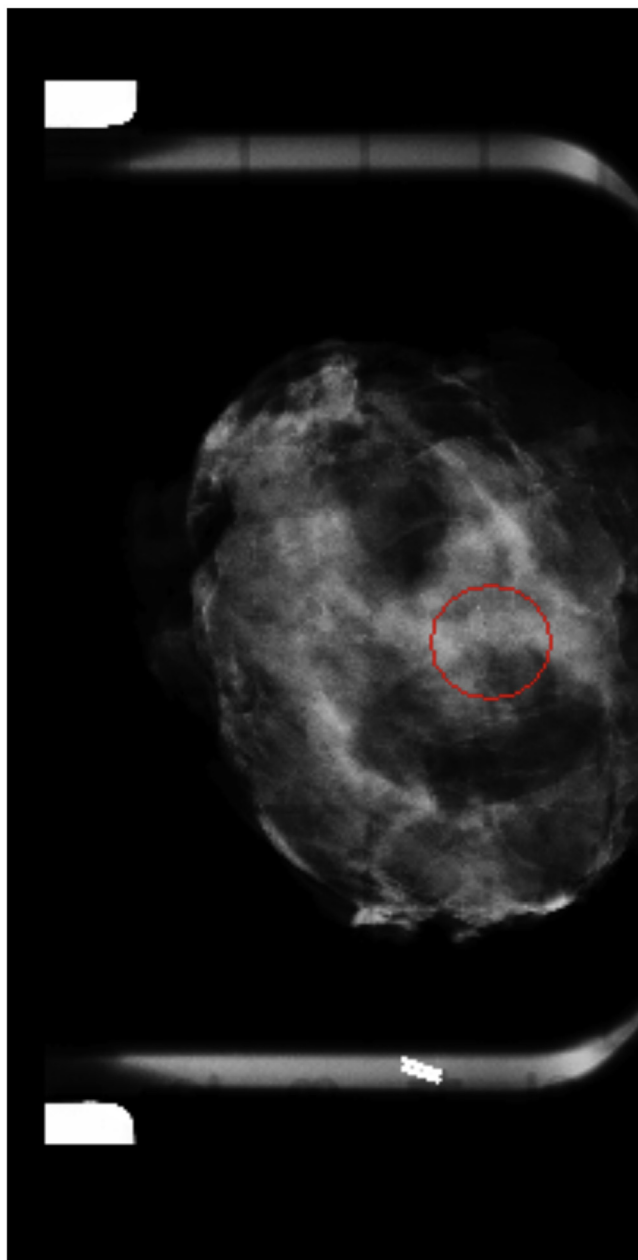


Fig. 6. Radiographic examination showing the radicality of the supero-central lumpectomy.

Multifocal (MF) and multicentric (MC) breast cancers are known to be more aggressive if compared with unifocal disease. In fact the biological patterns of malignancy (age, grade, HER-2 status, hormone receptor status, lymphovascular invasion) seem to be more aggressive in this group of patients such as the lymph node status [27–29].

The surgical treatment for MF and MC cancers remains controversial [30,31]. Lynch et al. presented data about MC and MF breast cancers treated by BCS, showing no statistically significant differences in term of local recurrence when compared with patients treated with mastectomy [32]. Currently the management of this kind of cancers changed considerably: BCS is considered now a worth alternative to mastectomy [32–34]. A recent paper by Shaikh et al. confirms that MF and MC breast cancers local recurrence rates are not related to the primary surgical approach [35].

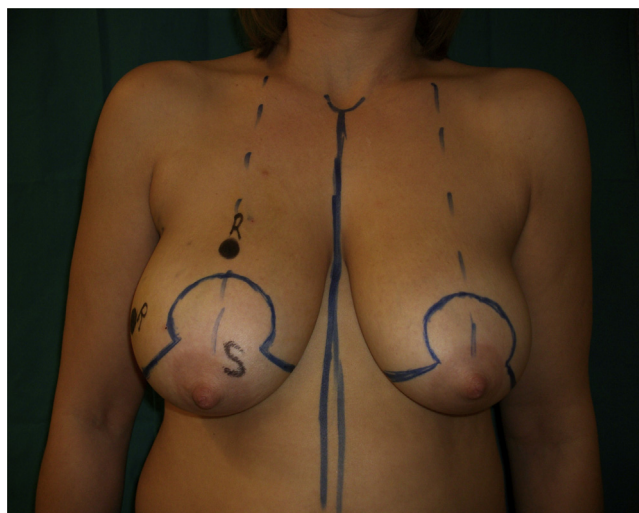


Fig. 7. The patient was marked for a standard reduction with three lumpectomies and contralateral symmetrization reduction. Pre-operative planning of the inverted-T mastoplasty.

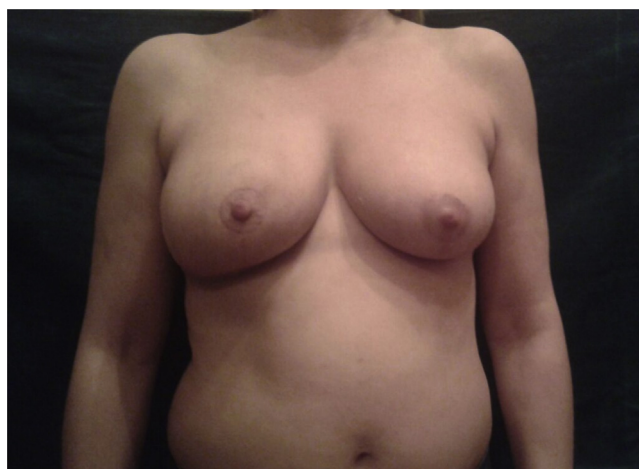


Fig. 8. One-month post-operative results.

We are sure that MF and MC breast cancer need a multidisciplinary approach, but in our opinion oncoplastic breast conserving surgery could be considered a safe surgical approach for selected patients, even though randomized controlled trials on larger cohorts should be auspicious in order to obtain higher levels of evidence about the use of oncoplastic breast conserving surgery in multicentric breast cancer.

Conflict of interest

The authors declare to have no conflict of interest.

Ethical approval

Ethical approval was not necessary, since the patient in the study has been treated according to guidelines and no experimental procedures or medications have been used.

Sources of funding

All authors have no source of funding.

Acknowledgement

We acknowledge Elisabetta Duranti for pictures management.

References

- [1] U. Veronesi, N. Cascinelli, L. Mariani, M. Greco, R. Saccozzi, A. Luini, M. Aguilari, E. Marubini, Twenty-year follow-up of a randomized study comparing breast-conserving surgery with radical mastectomy for early breast cancer, *N. Engl. J. Med.* 347 (2002) 1227–1232.
- [2] B. Fisher, S. Anderson, J. Bryant, M. Margolese, R. Deutsch, N. Fisher, Er Jeong, Jh Wolmark, Twenty-year follow-up of a randomized trial comparing total mastectomy, lumpectomy, and lumpectomy plus irradiation for the treatment of invasive breast cancer, *N. Engl. J. Med.* 347 (2002) 1233–1241.
- [3] B. Anderson, R. Masetti, M. Silverstein, Oncoplastic approaches to partial mastectomy: an overview of volume displacement techniques, *Lancet Oncol.* 6 (2005) 145–157.
- [4] M.J. Silverstein, The van nuys Breast Center—The first freestanding multidisciplinary breast center, *Surg. Oncol. Clin. N. Am.* 9 (2000) 159–175.
- [5] M.J. Silverstein, N. Handel, R. Hoffman, P. Gamagami, E. Gierson, The Breast Center—A multidisciplinary model, in: L.A. Paterson, AHG (Eds.), *Fundamental Problems in Breast Cancer*, Martinus Nijhoff, Boston, MA, 1987, pp. 47–58.
- [6] K. Clough, J.S. Lewis, B. Couturald, A. Fitoussi, C. Nos, M.C. Falcou, Oncoplastic techniques allow extensive resections for breast conserving therapy of breast carcinomas, *Ann. Surg.* 237 (2003) 26–34.
- [7] K. Clough, G. Kaufman, C. Nos, I. Buccimazza, I. Sarfati, Improving breast cancer surgery: a classification and quadrant per quadrant atlas for oncoplastic surgery, *Ann. Surg. Oncol.* 17 (2010) 1375–1391.
- [8] A.D. Baildam, Oncoplastic surgery of the breast, *Br. J. Surg.* 89 (2002) 532–533.
- [9] D.A. Rew, Towards a scientific basis for oncoplastic breast surgery, *Eur. J. Surg. Oncol.* 29 (2003) 105–106.
- [10] M.J. Silverstein, N. Savalia, S. Khan, J. Ryan, Extreme oncoplasty: breast conservation for patients who need mastectomy, *The Breast Journal* 21 (1) (2015) 52–59.
- [11] R.A. Agha, A.J. Fowler, A. Saetta, I. Barai, S. Rajmohan, D.P. Orgill, for the SCARE Group, The SCARE statement: consensus-based surgical case report guidelines, *Int. J. Surg.* (2016) (article in press).
- [12] F.D. Cutuli, P.H. Cottu, J. Gligorov, J.P. Guastalla, T. Petit, A. Amrate, Caractéristiques histopathologiques et modalités thérapeutiques des cancers du sein infiltrants: analyse comparative de deux observatoires nationaux réalisés en 2001–2002 et 2007–2008, *La lettre du Senologue* 45 (2009) 31–34.
- [13] S. Gathion, F. Lancon, J. Viguier, V. Mazeau-Woynar, Y a-t-il Une Augmentation Des Mastectomies Totales? Evolution Des Pratiques De Chirurgie Pour Cancer Du Sein En France Entre 2005 Et 2009 Is There an Increase in Mastectomies? *Cancer Du Sein: Surdiagnostic, Surtraitement*, Springer Paris, Paris, France, 2012, pp. 208–211.
- [14] C.A. Garcia-Etienne, M. Tomatis, J. Heil, et al., Mastectomy trends for early-stage breast cancer: a report from the EUSOMA multi-institutional European database, *Eur. J. Cancer* 48 (2012) 1947–1956.
- [15] W. Truin, R.M. Roumen, S. Siesling, et al., Patients with invasive lobular breast cancer are less likely to undergo breast-conserving surgery: a population based study in The Netherlands, *Ann. Surg. Oncol.* 22 (5) (2015) 1471–1478.
- [16] U. Veronesi, A. Banfi, R. Saccozzi, et al., Conservative treatment of breast cancer. A trial in progress at the Cancer Institute of Milan, *Cancer* 39 (6 Suppl) (1977) 2822–2826.
- [17] U. Veronesi, R. Saccozzi, M. Del Vecchio, et al., Comparing radical mastectomy with quadrantectomy, axillary dissection, and radiotherapy in patients with small cancers of the breast, *N. Engl. J. Med.* 305 (1981) 6–11.
- [18] B. Fisher, S. Anderson, C.K. Redmond, et al., Re-analysis and results after 12 years of follow-up in a randomized clinical trial comparing total mastectomy with lumpectomy with or without irradiation in the treatment of breast cancer, *N. Engl. J. Med.* 333 (1995) 1456–1461.
- [19] J.A. Jacobson, D.N. Danforth, K.H. Cowan, et al., Ten-year results of a comparison of conservation with mastectomy in the treatment of stage I and II breast cancer, *N. Engl. J. Med.* 332 (1995) 907–911.
- [20] U. Veronesi, A. Banfi, M. Del Vecchio, et al., Comparison of Halsted mastectomy with quadrantectomy, axillary dissection, and radiotherapy in early breast cancer: long-term results, *Eur. J. Cancer Clin. Oncol.* 22 (1986) 1085–1089.
- [21] E. Hau, L. Browne, A. Capp, et al., The impact of breast cosmetic and functional outcomes on quality of life: long-term results from the St. George and Wollongong randomized breast boost trial, *Breast Cancer Res. Treat.* 139 (2013) 115–123.
- [22] A.D. Fitoussi, M.G. Berry, F. Fama, et al., Oncoplastic breast surgery for cancer: analysis of 540 consecutive cases outcomes article, *Plast. Reconstr. Surg.* 125 (2010) 454–462.
- [23] M. Rietjens, C.A. Urban, P.C. Rey, et al., Long-term oncological results of breast conservative treatment with oncoplastic surgery, *Breast* 16 (2007) 387–395.
- [24] N. Kaur, J.Y. Petit, M. Rietjens, et al., Comparative study of surgical margins in oncoplastic surgery and quadrantectomy in breast cancer, *Ann. Surg. Oncol.* 12 (July (7)) (2005) 539–545.
- [25] B. Amato, C. Rispoli, L. Iannone, et al., Surgical margins of resection for breast cancer: current evidence, *Minerva Chir.* 67 (5) (2012) 445–452.
- [26] M.B. Nava, A.E. Pennati, L. Lozza, A. Spano, M. Zambetti, G. Catanuto, Outcome of different timings of radiotherapy in implant-based breast reconstructions, *Plast. Reconstr. Surg.* 128 (2) (2011 Aug) 353–359.
- [27] T.M. Weissenbacher, M. Zschage, W. Janni, et al., Multicentric and multifocal versus unifocal breast cancer: is the tumor-node metastasis classification justified? *Breast Cancer Res. Treat.* 122 (2010) 27–34.
- [28] R. Yerushalmi, S. Tyldesley, R. Woods, et al., Is breast-conserving therapy a safe option for patients with tumor multicentricity and multifocality? *Ann. Oncol.* 23 (2012) 876–881.
- [29] R. Wolters, A. Wockel, W. Janni, et al., Comparing the outcome between multicentric and multifocal breast cancer: what is the impact on survival, and is there a role for guideline-adherent adjuvant therapy? A retrospective multicenter cohort study of 8,935 patients, *Breast Cancer Res. Treat.* 142 (2013) 579–590.
- [30] J.M. Kurtz, J. Jacquemier, R. Amalric, et al., Breast-conserving therapy for macroscopically multiple cancers, *Ann. Surg.* 212 (1990) 38–44.
- [31] T. Tot, M. Gere, G. Pekar, et al., Breast cancer multifocality, disease extent, and survival, *Hum. Pathol.* 42 (2011) 1761–1769.
- [32] S.P. Lynch, X. Lei, L. Hsu, et al., Breast cancer multifocality and multicentricity and locoregional recurrence, *Oncologist* 18 (11) (2013) 1167–1173.
- [33] O. Gentilini, E. Botteri, N. Rotmensz, et al., Conservative surgery in patients with multifocal/multicentric breast cancer, *Breast Cancer Res. Treat.* 113 (2009) 577–583.
- [34] C. Spinelli, P. Berti, E. Ricci, et al., Multicentric breast tumour: an anatomical-clinical study of 100 cases, *Eur. J. Surg. Oncol.* 18 (1992) 23–26.
- [35] T. Shaikh, T.Y. Tam, T. Li, S.B. Hayes, et al., Multifocal and multicentric Breast cancer is associated with increased local recurrence regardless of surgery type, *Breast J.* 21 (2) (2015) 121–126.

Open Access

This article is published Open Access at sciendo.com. It is distributed under the [IJSCR Supplemental terms and conditions](#), which permits unrestricted non commercial use, distribution, and reproduction in any medium, provided the original authors and source are credited.