

Management of spontaneous and iatrogenic perforations, leaks and fistulae of the upper gastrointestinal tract

Jamal Al-Asiry , Richard Lord  and Noor Mohammed

Ther Adv Gastrointest Endosc

2019, Vol. 12: 1–12

DOI: 10.1177/

2631774519895845

© The Author(s), 2019.
Article reuse guidelines:
sagepub.com/journals-permissions

Abstract: Upper gastrointestinal perforations, leaks and fistulae are relatively common occurrences with a growing number of these complications occurring as a result of therapeutic advancement and adoption of newer and bolder endoscopic therapies. Historically, these were predominantly managed surgically; however, owing to high morbidity and mortality associated with surgical repair, endoscopic options are preferable. Over the past decade, vast expansion in the endoscopic armamentarium for the management of perforations, leaks and fistulae has led to endoscopic management now being the first-line treatment. Here, we will review the endoscopic modalities including through-the-scope clips, over-the-scope clips, stents, vacuum therapy, endoscopic sutures and sealants. In addition, we will discuss nonendoscopic approach to management including early recognition of perforations, ways to reduce septic complications and format algorithms to guide therapy for different scenarios. However, it is important to stress that there is a lack of high-quality randomised studies to clearly guide management of such complications, resulting in a wide variation of approaches in management by specialists. Each case requires some degree of individualisation due to the potential array of problems encountered and patient-specific co-morbidities. In the future, more robust studies are clearly required to better guide specialist management.

Keywords: acute perforation, endoscopic management, endoscopy vacuum therapy, leaks and fistulae, over-the-scope clips, stents

Received: 18 May 2019; revised manuscript accepted: 27 November 2019.

Introduction

Historically, upper gastrointestinal (UGI) perforations were predominantly managed surgically. However, morbidity and mortality associated with surgical repair are high.¹ Over the past decade, vast expansion in the endoscopic armamentarium for the management of perforations, leaks and fistulae has led to endoscopic management now being considered the first-line treatment option. Endoscopic therapy is less invasive, avoids general anaesthesia in most cases and potentially reduces extraluminal contamination if the perforation is dealt with acutely.

Perforations of the UGI tract may be spontaneous (e.g. Boerhaave syndrome, peptic ulcer disease, malignancy) or iatrogenic as a result of endoscopic or laparoscopic procedures. The

overall incidence of perforation from diagnostic UGI endoscopic procedures is low.² However, there is a rising demand on endoscopic services due to surveillance and screening programmes, as well as the ever-burgeoning indications for therapeutic endoscopies such as endoscopic mucosal resection (EMR), endoscopic submucosal dissection (ESD), endoscopic retrograde cholangio-pancreatography (ERCP) and therapeutic endoscopic ultrasound scan (EUS). Therefore, while perforations during UGI endoscopy are rare, there is an increase in the absolute number of perforations with evolving indications of therapeutic endoscopy. In this review article, we will be discussing perforations related to only luminal UGI procedures, leaks and fistulae. Complications and management of hepatobiliary procedures are not discussed.

Correspondence to:

Richard Lord
Department of
Gastroenterology, Leeds
Teaching Hospitals NHS
Trust, Leeds LS97TF, UK.
richard.lord2@nhs.net

Jamal Al-Asiry
Department of
Gastroenterology, Leeds
Teaching Hospitals NHS
Trust, Leeds, UK

Richard Lord
Noor Mohammed
Department of
Gastroenterology, Leeds
Teaching Hospitals NHS
Trust, Leeds, UK
University of Leeds, Leeds,
UK

Perforations related to endoscopic procedures

Low-risk procedures

A typical diagnostic gastroscopy and EUS is associated with a perforation risk of approximately 0.03% and 0.01%, respectively.^{2,3} Most perforations in a diagnostic gastroscopy occur in the thoracic oesophagus, whereas for diagnostic UGI EUS, they more commonly occur in the duodenum.⁴ Duodenal perforation during routine gastroscopy is exceedingly rare but when they occur they are often caused by muscular trauma during multiple biopsies from the same site. More commonly, perforations of the duodenum are secondary to ERCP, and while the majority can be managed conservatively, a minority of ERCP-related perforations carry significant morbidity and mortality risk.⁵

High-risk procedures

The perforation risk from EMR and ESD is dependent on the site in the UGI tract where the procedure is performed. In the oesophagus, most experience with EMR is for the treatment of Barrett's oesophagus and Barrett's associated neoplasia and the rates of perforation range from 0% to 3%.^{6,7} Oesophageal ESD is often the first-line therapeutic intervention for patients with superficial oesophageal squamous cell carcinomas (SCC) and for patients with Barrett's neoplasia with unfavourable characteristics for EMR such as large tumour size (>15 mm), poor 'lift' and those with suspected submucosal (sm1) invasion. The risk of perforation from oesophageal ESD is improving with increasing uptake and clinical expertise but has slightly increased rates of perforation when compared to EMR (range 0–4%).^{8,9}

Gastric EMR is a safe procedure which was the first alternative treatment for early gastric cancer (EGC). Approximately 0.5% of gastric EMR's are complicated by perforation compared to around 4% of gastric ESD.^{10,11} Several risk factors for perforation in gastric ESD have been identified including long procedural time, tumour location (upper stomach associated with increased risk due to a thinner mucosa), tumour size, advanced age (>80 years), damaged tissue (i.e. previously irradiated) and the presence of an ulcer.^{10–12}

Endoscopic resection of duodenal tumours by EMR or ESD carries higher risk compared to

oesophageal or gastric resections. EMR appears safer than ESD in the duodenum which carries the highest risk of both immediate (1.6% *versus* 12%) and delayed perforation (0.6% *versus* 4.0%).¹³ This is likely secondary to the practical difficulties of manoeuvring in the relatively narrow duodenal lumen along with the fact that the duodenal mucosa is particularly thin compared to other sites in the GI tract. However, there is a role for duodenal ESD in selected patients as the procedure is associated with a higher en bloc resection rate and lower risk of disease recurrence.

Endoscopic dilations in the UGI tract are among the most hazardous procedures with a perforation rate of 2–3%.¹⁴ The risks are lower in simple benign strictures when compared to malignant strictures (4–6%), complex strictures, caustic strictures and for patients with achalasia (0–8%).^{14,15} The rates of complications in endoscopic dilations of duodenal strictures are significantly higher. There are two types of oesophageal dilators: the bougie (or push) dilator and balloon dilator. Clinical outcomes between these two techniques do not differ in terms of safety or efficacy; therefore, the choice of dilator used is often dependent on clinician preference, equipment availability, reusability and cost. Although, with respect to bougie dilatation, the non-wire-guided bougie oesophageal dilators (e.g. Maloney dilator) have largely been superseded by wire-guided techniques (e.g. Savary-Gilliard and Puestow) due to a superior safety profile.¹⁶

Anastomotic leaks and fistulae

Leakage from the UGI tract is a feared and life-threatening complication of UGI surgery. Surgical re-intervention for leaks and fistulae is associated with significant mortality.¹⁷ The incidence of anastomotic leakage following gastro-oesophageal anastomosis occurs in up to 40% of cervical anastomoses compared to 7% of thoracic anastomoses but morbidity and mortality are greater in the latter.^{18,19} Risk factors for anastomotic leakage can be categorised into modifiable risk factors such as smoking, alcohol misuse, steroid use, malnutrition and nonmodifiable risk factors such as age, diabetes, tumour stage, emergency surgery and renal failure.²⁰ A review of the anastomotic leak rate for each UGI procedure is beyond the scope of this article. However, anastomotic leaks which are contained or follow a more indolent course may form a fistula.

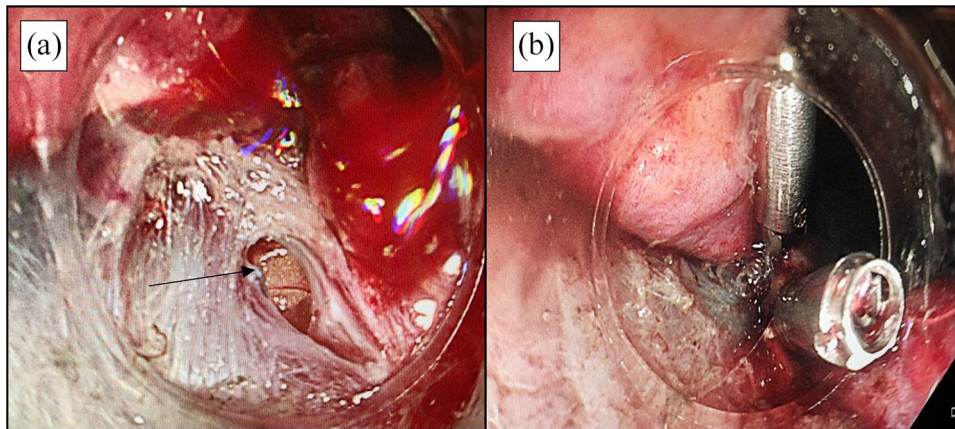


Figure 1. (a) Acute perforation identified during ESD. Omentum is seen (orange colour–arrow) through the muscles fibres (white colour). (b) Through-the-scope clip closure. ESD, endoscopic submucosal dissection.

Oesophageal fistulas in adults are predominantly acquired and present with recurrent aspiration pneumonia. They occur primarily as a consequence of malignancy, but other causes include trauma, infection, iatrogenic (i.e. oesophageal stenting, gastroscopy, tracheal tubes), foreign bodies (button batteries) and corrosive fluid ingestion. The most common site of fistulous tracts includes the trachea (trachea-oesophageal), less commonly the bronchus (broncho-oesophageal) and scarcely the lung parenchyma (oesophago-pulmonary).

Gastroduodenal fistulas are a relatively rare form of gastrointestinal fistulae. They arise primarily as a result of UGI surgery (85–90%) but can form spontaneously as a consequence of malignancy, trauma, inflammatory bowel disease and infection. Gastrocutaneous fistula can occur if the tract persists following removal of a percutaneous endoscopic gastrostomy (PEG) tube. Fistulae between duodenum and biliary system are very rare.²¹

Endoscopic armamentarium for UGI perforations, leaks and fistulas

Endoscopic clips

Endoscopic clips are commonly used for iatrogenic perforations during the acute setting when little or no extraluminal contamination is present. There are two main types of clips, through-the-scope (TTS) and over-the-scope clips (OTSC).

TTS clips. TTS clips, widely known as haemostatic, were introduced initially for the management of

gastrointestinal bleeding. However, due to ease of their use, they have become essential part of the endoscopic armamentarium from mucosal defect closure after EMR to closure of full-thickness perforations. Endoscopic clips are mainly used to close small perforations, with best success at closing perforations <1 cm.²² Over the last decade, the choice of TTS clips has expanded, with a range of commercial clips which differ in their functional properties such as size, rotation, tensile and closure strength.²³

As the name suggests, TTS clips are placed directly through the biopsy channel. The majority of the available clips have additional functionality of opening and closing the prongs multiple times and can also be rotated in order to achieve ideal position (see Figures 1 and 2). Additional tips in order to achieve maximal placement include applying gentle suction in order to draw the edges of the defect closer and applying a generous number of clips in order to achieve a ‘zipper’ fashion closure. Their success, however, seems to be limited by the size of the perforation, due to the limited wing-span of the prongs.

In addition, the ‘omental patch’ technique is feasible in larger gastric perforations where the omentum is visible through the defect (see Figure 2). The omentum is suctioned through the perforation and then clipped to the edges to form a seal. Minami and colleagues²⁴ reported in a large series of 117 patients with gastric perforation following EMR/ESD a clinical success of closure using TTSC of 98.3% with only two patients requiring emergency surgery.

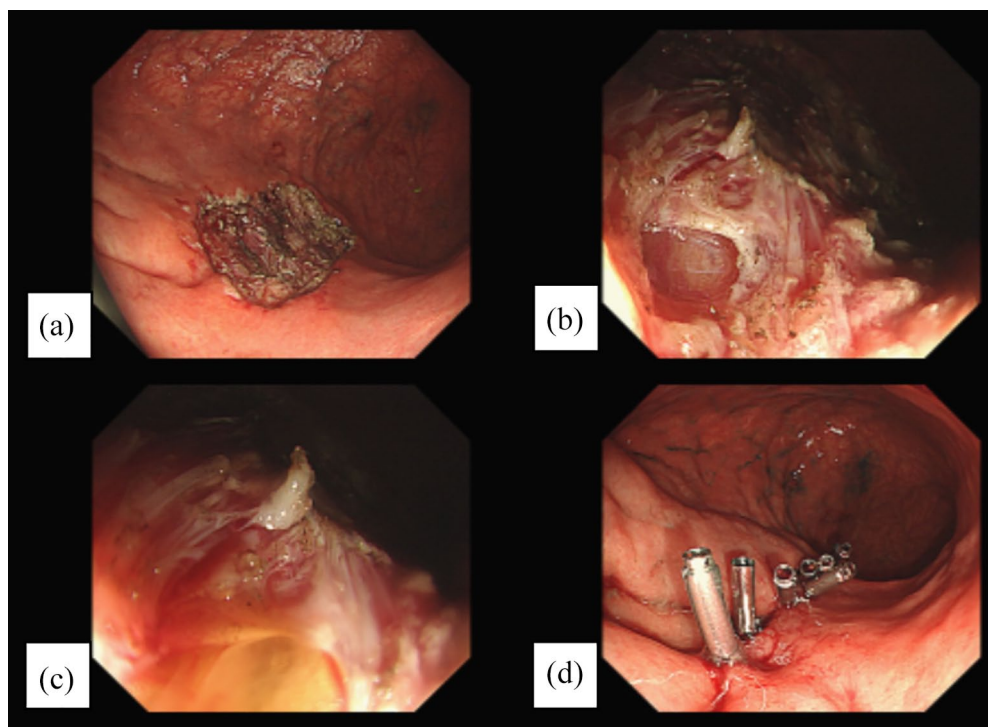


Figure 2. (a) The mucosal defect following ESD is shown. (b) On close examination, a microperforation is seen. (c) Omentum seen (orange colour) through the muscles fibres (white) is then drawn into the endoscope by continuous suction before deploying TTS clips to close the perforation. (d) Complete closure of the mucosal defect in a 'zipper' fashion is shown.

ESD, endoscopic submucosal dissection; TTS, through-the-scope.

OTSC. OTSCs have been designed to close GI perforations/defects of varying sizes. A metal clip is mounted on the distal tip of the endoscope which is then manoeuvred to the concerned area. Approximation of the mucosal edges is a key step and can be achieved usually with gentle suction before deploying the clip using an external handle. In larger defects, suction alone is less effective and the mucosal edges can be apposed using graspers or anchors, *via* a double-channel endoscope, prior to clip deployment.

The Ovesco clip (Ovesco Endoscopy AG) is a commonly used OTSCs, which have a similar principle but vastly different in design to that used in the 'Padlock' clip (Diagmed Healthcare). Generally, OTSCs are considered superior to TTS clips because of their ability to grasp more tissue, closing larger defects and providing a more compressive force compared with TTS clips. However, there are limitations for its use; it requires the endoscope to be removed from the patient to mount the clip and is cumbersome to negotiate difficult bends sometimes causing

mucosal lacerations during re-intubation. The best results for OTSCs seem to be for defects <2cm and a further advantage is their ability to close chronic well-established leaks and fistulae.

Numerous case studies and cohort studies have been published but tend to include small numbers and no randomised control trials exist. A prospective international study involving acute perforations showed a success rate of 89%.³ Furthermore, a multicentre retrospective study has shown success rates of 90% for perforations, 73.3% for leaks and 42.9% for fistula closure.²⁵ Examples of Ovesco usage are shown in Figure 3.

The OTSCs are designed as durable implants, but occasionally removal of the clips is required for complications such as local inflammation, ulceration, obstruction and misplaced clips. Removal of the Ovesco clip can be achieved by application of direct current (DC) to the bridges of the clip with specific graspers to fragment it into pieces. The pieces are then extracted using a cap to protect the mucosa from laceration.

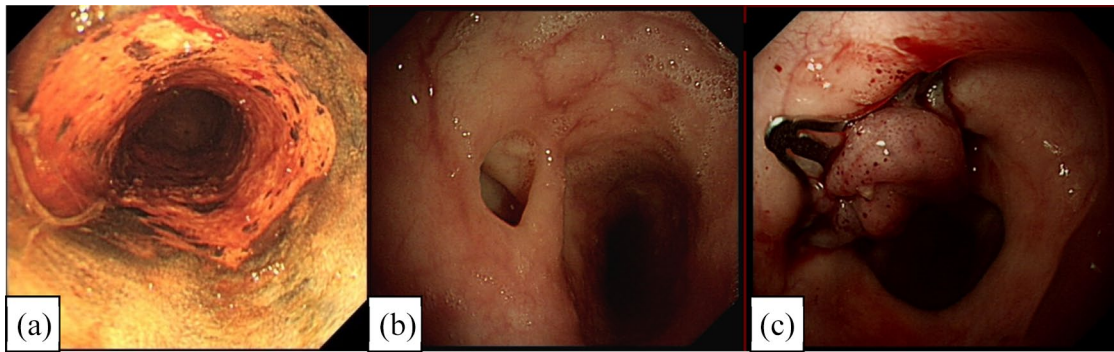


Figure 3. (a) An endoscopic diagnosis of Squamous cell cancer of the oesophagus, which was treated with endoscopic resection followed by radiotherapy. (b) A chronic trachea-oesophageal fistula is seen several years after the treatment while investigating chronic cough. (c) A over-the-scope clip (padlock clip) is used to close the defect successfully.

In summary, endoscopic clips are an effective method of closing mucosal defects. There is a lack of large prospective studies evaluating clip closure of perforations. Verlaan and colleagues performed a systematic review of the literature and found overall successful closure was achieved in 90.2% [$n = 359$; 95% confidence interval (CI): 87–93%] of cases by using TTSCC and in 87.8% ($n = 58$; 95% CI: 78–95%) by using the OTSCs.

Stents. Stents are used to bridge defects and to direct luminal contents into the UGI tract. There are several types of covered stents used in the treatment of perforations, leaks and fistulae. These include fully covered self-expandable metal stents (FCSEMS), partially covered self-expandable metal stents (PCSEMS) and self-expandable plastic stents (SEPS). They come in different lengths and diameters and should be long enough to cover 3–5 cm proximal and distal to the defect. Stent placement is performed over a guide-wire under fluoroscopy usually with endoscopic visualisation. Following successful deployment, most studies perform a contrast swallow at 48–72 h to confirm no residual leak, allowing commencement of oral nutrition.²⁶ For successful treatment of GI defects, tissue around the defect needs to be viable and success is more likely when defects are less than 3 cm in size and limited angulation proximal and distal to the defect.²⁷ Stents are more commonly used for mid- and lower oesophageal defects, as cervical placement is challenging and poorly tolerated by patients. Where perforations and leaks are not contained, stent placement will interfere in the treatment of the collection, and therefore,

concomitant percutaneous or surgical drainage will also be required.²⁸ Regular chest X-rays may be required in order to exclude stent displacement and gastroscopy is required at around 4 weeks to assess the defect.²⁹

FCSEMS tend to be used in most cases. However, partially covered stents may be placed at gastro-oesophageal leaks due to the higher risk of stent migration with FCSEMS. Tissue ingrowth at the proximal end allows anchoring of the stent; however, this can make removal of the stents difficult once the fistula/leak has healed.³⁰ Success of defect closure in most studies seems to be around 80%.^{30–33} The main complication is stent migration which can vary according to the type of stent placed. One study suggested the risk of migration being 31% with plastic stents, 26% with FCSEMS and 12% with PCSEMS.³¹

Endoscopy vacuum therapy. Endoscopy vacuum therapy (EVT) therapy is based on the original vacuum-assisted therapy used to close external wounds. Initially, EVT therapy was trialled for rectal leaks and was found to be extremely successful.³⁴ Soon after, this technology was adopted for managing perforations and leaks within the upper GI tract.^{35–37} The most commonly used device is the Eso-Sponge® system (B. Braun Melsungen Ltd., Melsungen, Germany). It consists of a porous polyurethane sponge which is placed endoscopically into the cavity or sometimes intraluminally next to the defect, if the cavity is small. The sponge works by promoting new granulation tissue, while the vacuum removes secretions, reduces oedema and promotes healing (see Figure 4).

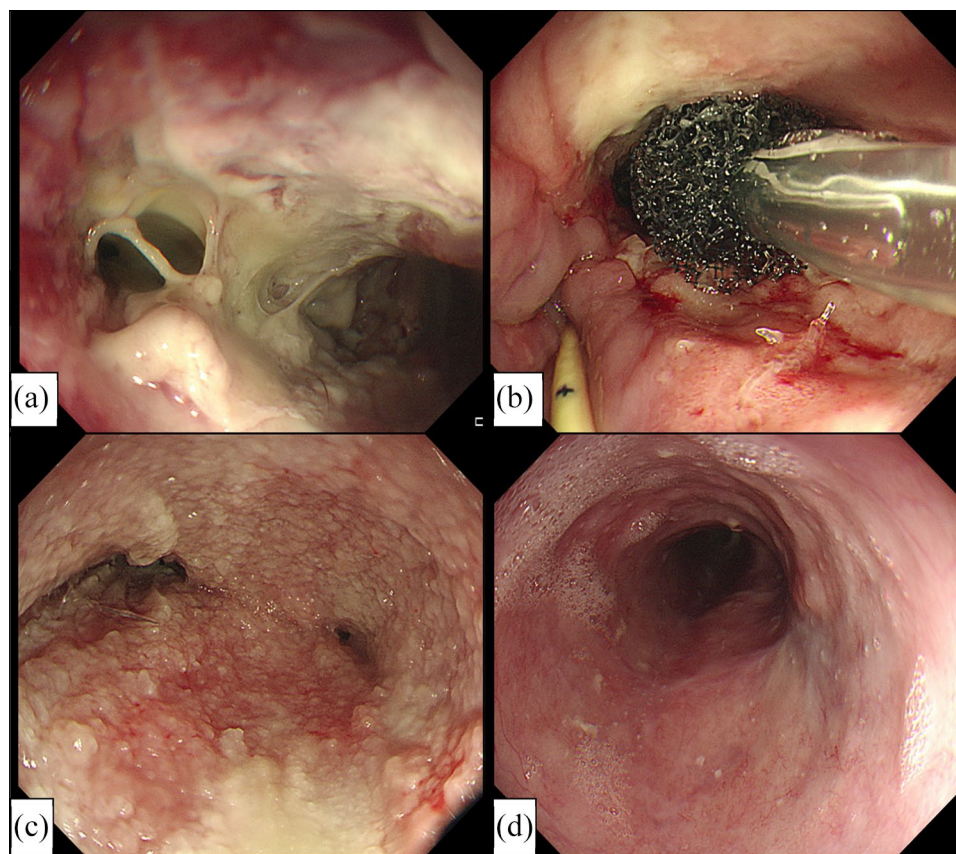


Figure 4. (a) Chronic perforation with a cavity. (b) Placement of esophageal sponge within the cavity (NJ feeding tube *in situ*). (c) Granulation tissue within the cavity during esophageal sponge exchange. (d) Complete healing of cavity following esophageal sponge therapy.

Endoscopy is initially performed to assess the size of the cavity, and then, an overtube is slid down the shaft of the gastroscope and the tip of the overtube is placed under direct vision into the cavity. The endoscope is then withdrawn, and the sponge is placed down the overtube into the cavity using a pusher device. The overtube/pusher device is then withdrawn, and the tube is redirected through the nose, followed by connection to the vacuum. Endoscopy is then performed to confirm correct placement, with the vacuum being switched on under direct endoscopic vision, maintaining a negative pressure between 100 and 125 mmHg. Sponge exchange should take place every 72 h to avoid ingrowth of granulation tissue into the sponge. To remove the sponge, 10 ml of saline can be flushed down the tube, and then, the tube is pulled out through the mouth, or if this fails, then grasping forceps close to the sponge end can help.³⁴

Clinical success ranges in studies from 70% to 100% and mortality has shown to be reduced

when compared with additional surgery.³⁸ A major benefit of using EVT is that the source of sepsis is being removed and direct assessment of the cavity is observed during each sponge change. Concomitant feeding can also be achieved by placing a naso-jejunal tube. Although some advocate enteral feeding to start once the sponge is in place, we would recommend caution and to use this guidance on a case-by-case basis.

Some drawbacks of EVT include the number of procedures a patient has to undertake. On average, five to seven procedures are required before the cavity is healed. Other challenges include technical difficulties/training and difficulty in removing the sponge if it has been left for too long.^{35,36}

Endoscopic suturing. More recently, significant advances have been made with endoscopic suturing technology, with several brands on the market. Technically, these devices are more challenging to use. The Overstitch (Apollo Endosurgery Inc) is a

disposable suturing device that is attached at the end of a double-channel endoscope and allows placement of full-thickness sutures across the defect. Several case reports have shown its effectiveness in the closure of oesophageal perforations.³⁹ However, larger series have shown less favourable results in the long-term closure, particularly fistulae after bariatric surgery. In one study, 71 patients underwent endoscopic suturing (EndoCinch; C.R. Bard, Inc), with initial results of 95% achieving complete primary closure. However, fistula reopening was seen in 65%, predominantly in those with large defects (>20 mm).⁴⁰ With limited data and small case series, it is difficult to determine the exact place of endoscopic suturing devices in the algorithm.

Tissue sealants. Tissue sealants such as fibrin glue and cyanoacrylate have been used with some success at closing UGI leaks and fistulas.²⁷ They can be applied as monotherapy or more commonly as part of combined therapy with clips, stents or mesh.⁴¹ As with other techniques, the fistula epithelium is often abraded or treated with argon plasma coagulation (APC) prior to application of the glue to promote fistula closure.

General principles in the management of UGI perforations

Most studies examining endoscopic management of UGI defects are predominantly case reports or retrospective/prospective cohorts, resulting in significant selection and publication bias. Lack of high-quality studies, such as randomised controlled trials, has consequently led to challenges in drawing consensus and clear guidelines to adhere to. Below is a pragmatic approach to dealing with perforations.

Recognition

The key to successful management of this complication is early recognition. Iatrogenic perforations can be identified at the index procedure by visualisation of an obvious mucosal defect or by more subtle signs such as abdominal distension and loss of luminal distension.⁴² During EMR or hybrid-ESD, the 'target sign', which is characterised by a white/grey circular disc on the resected specimen, identifies the muscularis propria and is a marker of iatrogenic perforation. Swan and colleagues⁴³ demonstrated that meticulous inspection of the resection specimen for the target sign can result in

early recognition of gastrointestinal perforation and facilitates endoscopic management. Perforations noted at the time of endoscopy should be recorded accurately with the site, size, contamination risk, and attempts at endoscopic closure along with the success and where possible photo-documented.

Early clinical features suggestive of UGI perforation include abdominal pain, chest pain, pneumoperitoneum, surgical emphysema and shortness of breath. At a later stage, they include peritonitis, systemic inflammatory response syndrome, shock and mental obtundation which are associated with worse clinical outcomes.⁴⁴ Patients with an UGI perforation are admitted to hospital for close monitoring. Computed tomography (CT) is superior to plain abdominal/chest X-rays in identifying perforations and allows the use of oral contrast to evaluate the size of the leak along with the efficacy of endoscopic closure. However, it should be emphasised that the volume of extraluminal air does not correlate well with the size of the perforation.⁴⁵

General management of perforations

The key to management is by adopting a multidisciplinary collaboration from gastroenterologists, surgeons and radiologists. The majority of UGI perforations which occur as a result of endoscopy can be managed endoscopically; however, this is dependent on location, size and length of time the defect has been present and the expertise of the endoscopist in managing such complications. General supportive measures for patients with an UGI perforation include keeping the patient nil by mouth, analgesia, nasogastric or nasoduodenal tubes, broad-spectrum intravenous antibiotics and high-dose intravenous acid suppression and for patients who are malnourished or expected to have a prolonged period nil by mouth (>7 days) parenteral nutrition. Once a perforation has been identified, intra-procedurally switching to carbon dioxide insufflation is recommended to reduce the formation of tension pneumothorax or pneumo-mediastinum.⁴⁶ However, urgent needle decompression is indicated in patients with haemodynamic compromise who develop these life-threatening conditions.

The decision to close the defect endoscopically is dependent on the timing of the perforation (acute

Table 1. Initial general management of an acute upper gastrointestinal perforation.

• Early recognition
• Confirm insufflation is with CO ₂
• Decompress any extraluminal air under pressure
• Determine if endoscopic closure possible: <ul style="list-style-type: none"> ○ Size of defect ○ Location ○ Extraluminal contamination ○ Skill set of endoscopist
• Consider insertion of NJ tube at the time of procedure and commence post-pyloric feeding once radiological confirmation of closed perforation
• Nil-by-mouth
• Intravenous antibiotics and proton pump inhibitor
• Admission and close observations
• Inform UGI surgeons of admission
• Radiological imaging with oral contrast to confirm closure or to assess for complications
NJ, nasojeunal; UGI, upper gastrointestinal.

perforation defined as occurring within 24 h), site of perforation, contamination of luminal contents, the expertise/skill of the endoscopist and the stability of the patient. Generally, surgery is advocated in patients who present late with sepsis, deteriorating condition, and large defects or with an active leak on CT scan. Patients who develop collections should have these drained percutaneously where possible and radiological examination is likely required to confirm closure of defect, either with gastrograffin or CT with oral contrast. A summary of management of perforations can be seen in Table 1.

Acute perforations

Treatment of acute perforations is dependent on several factors as described above. For acute oesophageal perforations, the site of the defect is particularly important. Treatment of cervical oesophageal perforations can be particularly challenging due to anatomical reasons, resulting in poor views and unstable position to achieve closure and conservative management may be successful here.⁴⁷ Thoracic and abdominal oesophageal perforations are more amenable to the various endoscopic modalities discussed earlier within the paper.

Within the stomach and duodenum, the size of the perforation is more likely to direct endoscopic management. Small perforations <1 cm tend to be easily managed with TTS clips. Larger defects within the stomach maybe closed by the ‘omental patch’ technique or OTSC. Omental patch technique is described in Figure 2. The advantage of this technique is the perforation closure can take place without any significant delay, thereby avoiding peritoneal contamination. It is performed with the TTS clips, without having to remove the endoscope from the area of perforations. However, use of OTSCs for closing perforations will require the endoscope to be removed from the area of perforation to mount the clip on the tip of the endoscope before it is re-introduced. With skilled technician, the delay could be reduced; however, the peritoneal contamination could not be underestimated. Hence, our practice is to suction any excess fluid from the lumen and withdraw the endoscope only when the OTSC is ready to be mounted.

Figures 5–7 describe flow diagrams for acute perforations of the oesophagus, stomach and duodenum. They provide a pragmatic approach to management complimenting the general management described in Table 1.

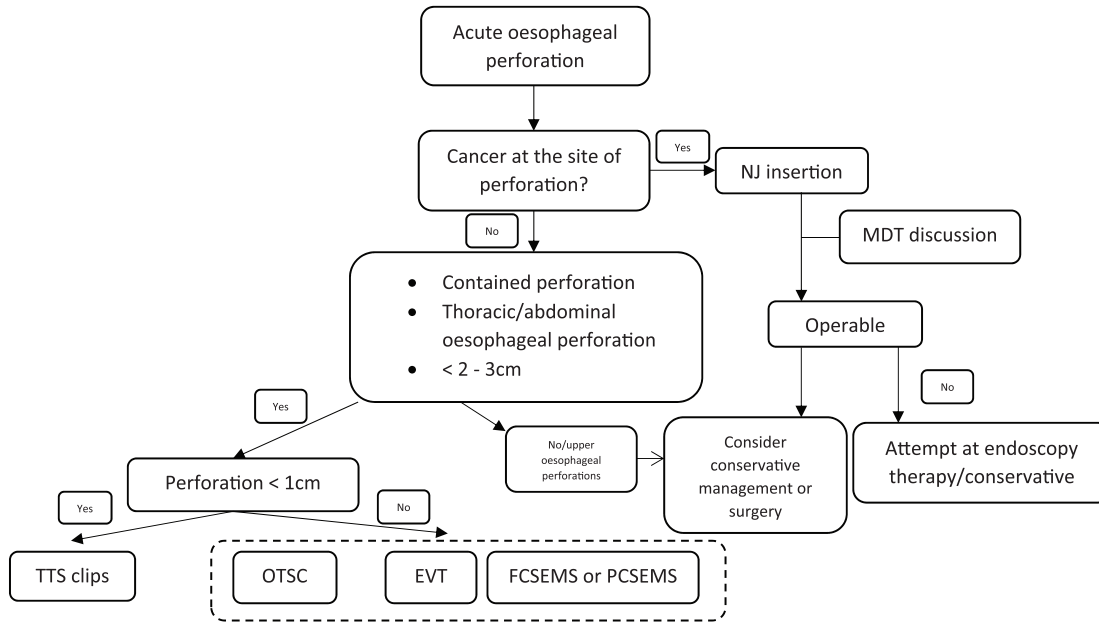


Figure 5. Flow diagram for the management of an acute oesophageal perforation. EVT, endoscopic vacuum therapy; FCSEMS, fully covered self-expandable metal stent; OTSC, over-the-scope clip; PCSEMS, partially covered self-expandable metal stent; TTS, through-the-scope.

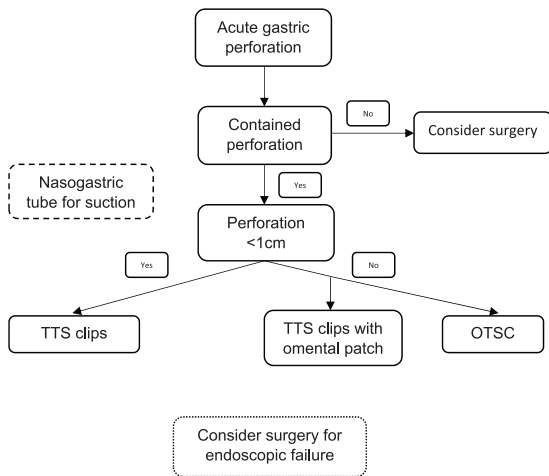


Figure 6. Flow diagram for the management of an acute gastric perforation. OTSC, over-the-scope clips; TTS, through-the-scope.

Chronic perforations, leaks and fistulae

Chronic perforations and anastomotic leaks can generally be managed similarly. Decision on treatment will be dependent on the chronicity, viability of the underlying tissue, location and the presence of any undrained sepsis. EVT is helpful in the presence of undrained sepsis and eventual closure; however, if percutaneous drainage is already *in situ*, then OTSC, stents or EVT therapy may be equally effective. Larger defects >2 cm may also be better managed with EVT or stents.

Fistulae in general represent the refractory disorder to most endoscopic therapy. They may be associated with malignancy or radiation therapy rendering treatment challenging. For oesophago-respiratory fistulae, stenting is likely to be the best option, especially as most are related to malignancy, and therefore, unlikely to heal, and associated with the best palliative option.⁴⁸ Gastric fistulae relating to PEG removal are best managed with OTSCs; however, recurrence can occur.⁴⁹ A flow diagram for the management is seen in Figure 8.

Conclusion

UGI perforations, leaks and fistulae are relatively common occurrences with a growing number of these complications occurring as the adoption of newer and bolder endoscopic therapies continues. The key to managing these complications include early recognition, commencement of endoscopic therapy, reducing septic complications, promoting nutritional status and implementing a multidisciplinary approach. At present, there is a lack of high-quality randomised studies to clearly guide management of such complications, resulting in a wide variation of approaches in the management by specialists. However, each case requires some degree of individualisation due to the array of potential problems encountered and patient-specific comorbidities. More robust studies are required in the future to better guide specialist management.

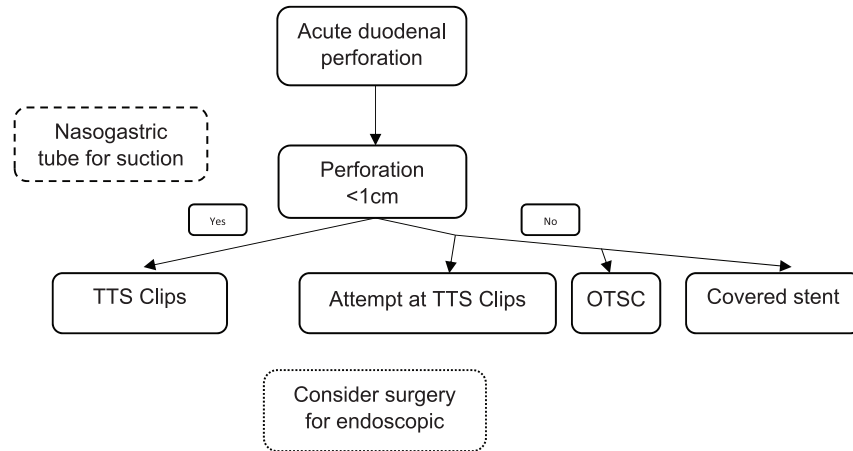


Figure 7. Flow diagram for the management of acute duodenal perforations. OTSC, over-the-scope clips; TTS, through-the-scope.

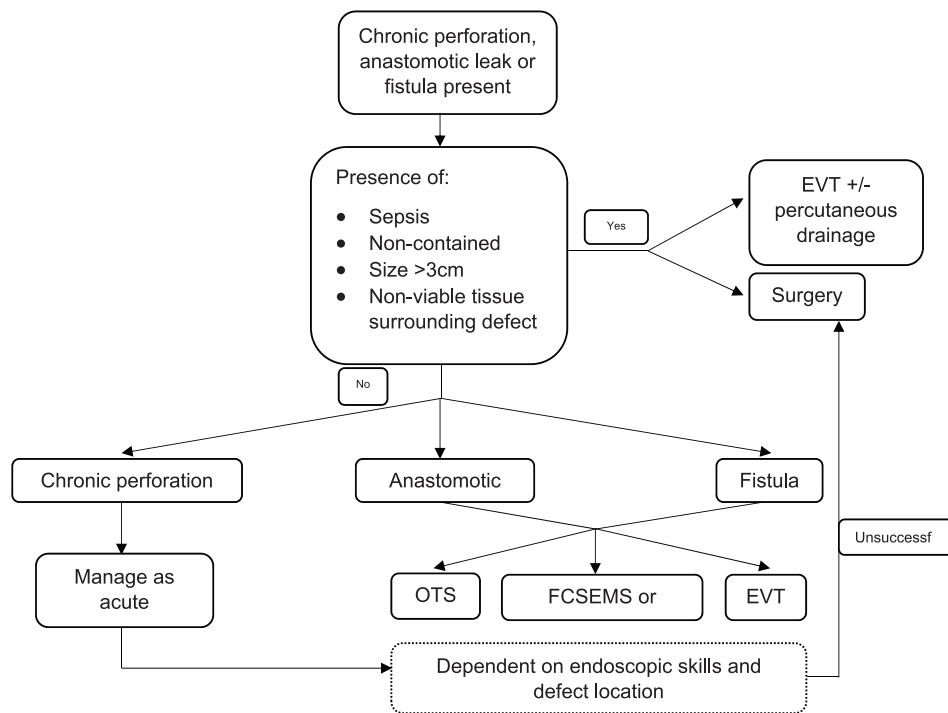


Figure 8. Flow diagram for the management of chronic perforations, anastomotic leaks and fistulae. EVT, endoscopic vacuum therapy; FCSEMS, fully covered self-expandable stents; OTSC, over-the-scope clips; PCSEMS, partially covered self-expandable stents.

Conflict of interest statement

The authors declared no potential conflicts of interest with respect to the research, authorship and/or publication of this article.

Funding

The authors received no financial support for the research, authorship and/or publication of this article.

ORCID iDs

Jamal Al-Asiry <https://orcid.org/0000-0002-1818-5918>

Richard Lord <https://orcid.org/0000-0002-8356-7824>

Supplemental material

Supplemental material for this article is available online.

References

1. Verlaan T, Voermans RP, van Berge Henegouwen MI, *et al.* Endoscopic closure of acute perforations of the GI tract: a systematic review of the literature. *Gastrointest Endosc* 2015; 82: 618–628.e5.
2. Eisen GM, Baron TH, Dominitz JA, *et al.* Complications of upper GI endoscopy. *Gastrointest Endosc* 2002; 55: 784–793.
3. Voermans RP, Le Moine O, von Renteln D, *et al.* Efficacy of endoscopic closure of acute perforations of the gastrointestinal tract. *Clin Gastroenterol Hepatol* 2012; 10: 603–608.
4. Jenssen C, Faiss S and Nurnberg D. [Complications of endoscopic ultrasound and endoscopic ultrasound-guided interventions: results of a survey among German centers]. *Z Gastroenterol* 2008; 46: 1177–1184.
5. Fujii L, Lau A, Fleischer DE, *et al.* Successful nonsurgical treatment of pneumomediastinum, pneumothorax, pneumoperitoneum, pneumoretroperitoneum, and subcutaneous emphysema following ERCP. *Gastroenterol Res Pract* 2010; 2010: 289135.
6. Moss A, Bourke MJ, Hourigan LF, *et al.* Endoscopic resection for Barrett's high-grade dysplasia and early esophageal adenocarcinoma: an essential staging procedure with long-term therapeutic benefit. *Am J Gastroenterol* 2010; 105: 1276–1283.
7. Pouw RE, Seewald S, Gondrie JJ, *et al.* Stepwise radical endoscopic resection for eradication of Barrett's oesophagus with early neoplasia in a cohort of 169 patients. *Gut* 2010; 59: 1169–1177.
8. Repici A, Hassan C, Carlino A, *et al.* Endoscopic submucosal dissection in patients with early esophageal squamous cell carcinoma: results from a prospective Western series. *Gastrointest Endosc* 2010; 71: 715–721.
9. Hoteya S, Matsui A, Iizuka T, *et al.* Comparison of the clinicopathological characteristics and results of endoscopic submucosal dissection for esophagogastric junction and non-junctional cancers. *Digestion* 2013; 87: 29–33.
10. Abe Y, Inamori M, Iida H, *et al.* Clinical characteristics of patients with gastric perforation following endoscopic submucosal resection for gastric cancer. *Hepatogastroenterology* 2009; 56: 921–924.
11. Imagawa A, Okada H, Kawahara Y, *et al.* Endoscopic submucosal dissection for early gastric cancer: results and degrees of technical difficulty as well as success. *Endoscopy* 2006; 38: 987–990.
12. Yoo JH, Shin SJ, Lee KM, *et al.* Risk factors for perforations associated with endoscopic submucosal dissection in gastric lesions: emphasis on perforation type. *Surg Endosc* 2012; 26: 2456–2464.
13. Shibagaki K, Ishimura N and Kinoshita Y. Endoscopic submucosal dissection for duodenal tumors. *Ann Transl Med* 2017; 5: 188.
14. Quine MA, Bell GD, McCloy RF, *et al.* Prospective audit of perforation rates following upper gastrointestinal endoscopy in two regions of England. *Br J Surg* 1995; 82: 530–533.
15. Karnak I, Tanyel FC, Buyukpamukcu N, *et al.* Esophageal perforations encountered during the dilation of caustic esophageal strictures. *J Cardiovasc Surg* 1998; 39: 373–377.
16. Sami SS, Haboubi HN, Ang Y, *et al.* UK guidelines on oesophageal dilatation in clinical practice. *Gut* 2018; 67: 1000–1023.
17. Rutegard M, Lagergren P, Rouvelas I, *et al.* Intrathoracic anastomotic leakage and mortality after esophageal cancer resection: a population-based study. *Ann Surg Oncol* 2012; 19: 99–103.
18. Pierie JP, de Graaf PW, van Vroonhoven TJ, *et al.* Healing of the cervical esophagogastric anastomosis. *J Am Coll Surg* 1999; 188: 448–454.
19. Giuli R and Gignoux M. Treatment of carcinoma of the esophagus. Retrospective study of 2,400 patients. *Ann Surg* 1980; 192: 44–52.
20. Tabatabai A, Hashemi M, Mohajeri G, *et al.* Incidence and risk factors predisposing anastomotic leak after transhiatal esophagectomy. *Ann Thorac Med* 2009; 4: 197–200.
21. Mohammed N, Godfrey EM and Subramanian V. Cholecysto-duodenal fistula as the source of upper gastrointestinal bleeding. *Endoscopy* 2013; 45(Suppl. 2): E250–E251.
22. Mangiavillano B, Viaggi P and Masci E. Endoscopic closure of acute iatrogenic perforations during diagnostic and therapeutic endoscopy in the gastrointestinal tract using metallic clips: a literature review. *J Dig Dis* 2010; 11: 12–18.
23. Wang TJ, Aihara H, Thompson AC, *et al.* Choosing the right through-the-scope clip: a rigorous comparison of rotatability, whip, open/close precision, and closure strength (with videos). *Gastrointest Endosc* 2019; 89: 77–86.e1.
24. Minami S, Gotoda T, Ono H, *et al.* Complete endoscopic closure of gastric perforation induced by endoscopic resection of early gastric cancer using endoclips can prevent surgery (with video). *Gastrointest Endosc* 2006; 63: 596–601.
25. Haito-Chavez Y, Law JK, Kratt T, *et al.* International multicenter experience with an over-the-scope clipping device for endoscopic management of GI defects (with video). *Gastrointest Endosc* 2014; 80: 610–622.

26. Abulfaraj MM, Mathavan V and Arregui M. Therapeutic flexible endoscopy replacing surgery: part 1—leak and fistula. *Tech Gastrointest Endoscopy* 2013; 15: 191–199.
27. Freeman RK and Ascoti AJ. Esophageal stent placement for the treatment of perforation, fistula, or anastomotic leak. *Semin Thorac Cardiovasc Surg* 2011; 23: 154–158.
28. Willingham FF and Buscaglia JM. Endoscopic management of gastrointestinal leaks and fistulae. *Clin Gastroenterol Hepatol* 2015; 13: 1714–1721.
29. Blackmon SH, Santora R, Schwarz P, *et al.* Utility of removable esophageal covered self-expanding metal stents for leak and fistula management. *Ann Thorac Surg* 2010; 89: 931–936; discussion 936–937.
30. Eisendrath P, Cremer M, Himpens J, *et al.* Endotherapy including temporary stenting of fistulas of the upper gastrointestinal tract after laparoscopic bariatric surgery. *Endoscopy* 2007; 39: 625–630.
31. van Boeckel PG, Sijbring A, Vleggaar FP, *et al.* Systematic review: temporary stent placement for benign rupture or anastomotic leak of the oesophagus. *Aliment Pharmacol Ther* 2011; 33: 1292–1301.
32. Bakken JC, Wong Kee Song LM, de Groen PC, *et al.* Use of a fully covered self-expandable metal stent for the treatment of benign esophageal diseases. *Gastrointest Endosc* 2010; 72: 712–720.
33. Senousy BE, Gupte AR, Draganov PV, *et al.* Fully covered Alimaxx esophageal metal stents in the endoscopic treatment of benign esophageal diseases. *Dig Dis Sci* 2010; 55: 3399–3403.
34. Weidenhagen R, Gruetzner KU, Wiecken T, *et al.* Endoscopic vacuum-assisted closure of anastomotic leakage following anterior resection of the rectum: a new method. *Surg Endosc* 2008; 22: 1818–1825.
35. Moschler O, Nies C and Mueller MK. Endoscopic vacuum therapy for esophageal perforations and leakages. *Endosc Int Open* 2015; 3: E554–E558.
36. Brangewitz M, Voigtlander T, Helfritz FA, *et al.* Endoscopic closure of esophageal intrathoracic leaks: stent versus endoscopic vacuum-assisted closure, a retrospective analysis. *Endoscopy* 2013; 45: 433–438.
37. Kuehn F, Schiffmann L, Rau BM, *et al.* Surgical endoscopic vacuum therapy for anastomotic leakage and perforation of the upper gastrointestinal tract. *J Gastrointest Surg* 2012; 16: 2145–2150.
38. Schniewind B, Schafmayer C, Voehrs G, *et al.* Endoscopic endoluminal vacuum therapy is superior to other regimens in managing anastomotic leakage after esophagectomy: a comparative retrospective study. *Surg Endosc* 2013; 27: 3883–3890.
39. Henderson JB, Sorser SA, Atia AN, *et al.* Repair of esophageal perforations using a novel endoscopic suturing system. *Gastrointest Endosc* 2014; 80: 535–537.
40. Fernandez-Esparrach G, Lautz DB and Thompson CC. Endoscopic repair of gastrogastic fistula after Roux-en-Y gastric bypass: a less-invasive approach. *Surg Obes Relat Dis* 2010; 6: 282–288.
41. Kotzampassi K and Eleftheriadis E. Tissue sealants in endoscopic applications for anastomotic leakage during a 25-year period. *Surgery* 2015; 157: 79–86.
42. Singh RR, Nussbaum JS and Kumta NA. Endoscopic management of perforations, leaks and fistulas. *Transl Gastroenterol Hepatol* 2018; 3: 85.
43. Swan MP, Bourke MJ, Moss A, *et al.* The target sign: an endoscopic marker for the resection of the muscularis propria and potential perforation during colonic endoscopic mucosal resection. *Gastrointest Endosc* 2011; 73: 79–85.
44. Baron TH, Wong Kee Song LM, Zielinski MD, *et al.* A comprehensive approach to the management of acute endoscopic perforations (with videos). *Gastrointest Endosc* 2012; 76: 838–859.
45. Paspatis GA, Vardas E, Theodoropoulou A, *et al.* Complications of colonoscopy in a large public county hospital in Greece. A 10-year study. *Dig Liver Dis* 2008; 40: 951–957.
46. Wang WL, Wu ZH, Sun Q, *et al.* Meta-analysis: the use of carbon dioxide insufflation vs. room air insufflation for gastrointestinal endoscopy. *Aliment Pharmacol Ther* 2012; 35: 1145–1154.
47. Kuppasamy MK, Hubka M, Felisky CD, *et al.* Evolving management strategies in esophageal perforation: surgeons using nonoperative techniques to improve outcomes. *J Am Coll Surg* 2011; 213: 164–171; discussion 171–172.
48. Kim KR, Shin JH, Song HY, *et al.* Palliative treatment of malignant esophagopulmonary fistulas with covered expandable metallic stents. *AJR Am J Roentgenol* 2009; 193: W278–W282.
49. Manta R, Caruso A, Cellini C, *et al.* Endoscopic management of patients with post-surgical leaks involving the gastrointestinal tract: a large case series. *United European Gastroenterol J* 2016; 4: 770–777.