



Computed Tomography–Guided Spinal Biopsy in Suspected Infective Spondylodiscitis: An Institutional Review of Its Utility

Raj Chendur Abhishek Ravichandran¹, Rohit Amritanand², Vinu Moses³
 Madhavi Kandagaddala³, Venkatesh Krishnan², Kenny Samuel David², Justin Arockiaraj²
 Harini Kulasekaran², Maya Pavalasseril Ganesan⁴, Anne Jennifer Prabhu⁵
 Shyamkumar Nidugala Keshava³

¹ Christian Medical College, Vellore, Chennai, India

² Department of Spine Surgery, Christian Medical College, Vellore, Chennai, India

³ Department of Interventional Radiology, Division of Clinical Radiology, Christian Medical College, Vellore, Chennai, India

⁴ Department of Biostatistics, Christian Medical College, Vellore, Chennai, India

⁵ Department of Pathology, Christian Medical College, Vellore, Chennai, India

Address for correspondence Shyamkumar Nidugala Keshava, DMRD, DNB, FRCR, FRANZCR, Department of Interventional Radiology, Division of Clinical Radiology, Christian Medical College, Vellore 632004, Chennai, India (e-mail: shyamkumar.n.keshava@gmail.com).

Indian J Radiol Imaging 2023;33:289–294.

Abstract

Background Infectious spondylodiscitis is a debilitating condition and evidence-based medicine dictates confirming the diagnosis before treatment. Computed tomography–guided spinal biopsy plays a major role and hence we would like to determine its utility in current clinical practice.

Purpose The purpose of this study is to determine the percentage of confirmatory positives of CT-guided spinal biopsy in patients who were clinicoradiologically diagnosed with infectious spondylitis.

Material and Methods A retrospective analysis of patients who underwent CT-guided biopsy for suspected infectious spondylodiscitis from 2017 to 2021 in a tertiary medical center was done. The data were filtered and obtained from the electronic database of the institution.

Results In all, 259 patients underwent CT-guided biopsy of the spine. The procedure provided confirmatory results in 149 (57.5%) biospecimens. Histopathology examination was confirmatory in 95 (36.6%) of the 241 biospecimens sent. The Mycobacteria Growth Indicator Tube (MGIT) was confirmatory in 51 (19.9%) of the 250 biospecimens sent and drug resistance was seen in 6/51 (11.7%) biospecimens. Xpert TB provided confirmatory results in 72 (27.8%) of the 254 biospecimens sent and rifampicin resistance was seen in 16/72 (22.2%) biospecimens. Bacterial culture was confirmatory

Keywords

- ▶ spine biopsy
- ▶ CT
- ▶ infectious spondylodiscitis
- ▶ tuberculous spondylodiscitis
- ▶ pyogenic spondylodiscitis
- ▶ antitubercular therapy

article published online
May 6, 2023

DOI <https://doi.org/10.1055/s-0043-1764491>.
ISSN 0971-3026.

© 2023. Indian Radiological Association. All rights reserved.
This is an open access article published by Thieme under the terms of the Creative Commons Attribution-NonDerivative-NonCommercial-License, permitting copying and reproduction so long as the original work is given appropriate credit. Contents may not be used for commercial purposes, or adapted, remixed, transformed or built upon. (<https://creativecommons.org/licenses/by-nc-nd/4.0/>)
Thieme Medical and Scientific Publishers Pvt. Ltd., A-12, 2nd Floor, Sector 2, Noida-201301 UP, India

in 29 (11.2%) of the 250 biospecimens sent. The complication documented in this study was 0.3%.

Conclusion CT-guided spinal biopsy for suspected vertebral osteomyelitis is a safe and effective minimally invasive procedure. It demonstrates a positive yield in more than half of the patients. Knowing the outcome, the patients can be appropriately counseled prior to the procedure. CT-guided biopsy results were affected by prior administration of ATT (antitubercular therapy) in suspected tuberculous spondylitis patients.

Introduction

Vertebral osteomyelitis is one of the leading debilitating conditions in medical practice very often encountered by spine surgeons. Vertebral osteomyelitis usually presents with acute to chronic back pain that results in worsening of the quality of life. It is important to confirm the diagnosis to avoid empirical treatment with antibiotics, especially in suspected cases of tuberculosis (TB), to avoid long-term side effects of the therapy. Even though advanced imaging like magnetic resonance imaging (MRI) has improved the sensitivity and specificity of diagnosing vertebral spondylitis, the confirmatory diagnosis of this disease has been a challenge to physicians for many years.

Open biopsy is the gold standard of diagnosis. Open biopsies are diagnostic in more than 80% of patients.¹⁻³ Waheed et al reported a 96.9% improvement and stabilization of patients treated via surgery and antibiotic treatment with a mortality rate of 4.5%, average hospital stay of 23 days, complication rate of 28.1%, and yield of 84.3%.⁴ Martin-Alonso et al reported improvement of pain or neurological defect and stabilization in 96.3% patients with deterioration in 2.4%, complications in 43.2% with a median postoperative stay of 14 days and mortality rate of 6.1% and isolated organisms in 67.4%.⁵

CT provides localization and delineation of the lesion including both the osseous and the extraosseous components. CT helps us to determine the safest approach to the lesion and helps in accurate needle placement into the lesion, and it has become the procedure of choice.⁶ Compared with open biopsy, there is less risk of iatrogenic infection and wound problems. In addition, it is fast, economical, and applicable to outpatients or day hospital patients as general anesthesia is rarely required.⁷ CT-guided spinal biopsy also allows us to determine the susceptibility of bacterial organisms to antibiotics, and this aspect of the procedure becomes extremely important with the emergence of drug-resistant strains as they are a major cause of therapeutic failure.

The value of this procedure in pyogenic spinal infection has been investigated in several studies, indicating a sensitivity range of 30 to 50%,⁸ and review of literature in recent times have shown a wide variation and discrepancy in the statistics of the diagnostic yield of CT-guided biopsy of the spine. A study done by Chew et al in 2001 reported a yield of 91% (39/43) using strict microbiological criteria and when combined with cytopathology reported a yield of 95% (41/43) in patients suspected to have active infectious discitis⁹ and a recent retrospective study by Joo et al⁸ revealed a diagnostic yield of 61% (20/33) for tuberculous spondylitis and 33% (22/67) for

pyogenic spondylitis. The purpose of this study is to assess the utility of CT-guided spinal biopsy in our institution.

Methods

This multidisciplinary research was approved by the institutional review board (IRB number: 14467) and the requirement for informed consent was waived due to the retrospective nature of this study. A retrospective analysis of patients who underwent CT-guided biopsy for suspected infectious spondylodiscitis over the period from 2017 to 2021 was done. The reports were analyzed from the institution's electronic database.

All the procedures were performed by interventional radiologists after referral from the Department of Spinal Surgery. The imaging, including plain radiography and MRI, was reviewed. The basic bleeding parameters, hemoglobin (Hb), prothrombin time (PT), activated partial thromboplastin clotting time (APTT), were assessed. The procedures were performed on day care admission of the patients. Informed written consent was obtained from the patients by the radiologists for the procedures. The procedures were performed in the CT room with sterile precautions. A percutaneous CT-guided extrapedicular approach was done primarily as the changes were mostly near the endplates. Trephine biopsy was done for bone lesions and tru-cut biopsy was done for soft-tissue lesions, which included paravertebral tissue and intervertebral disk, and aspiration of paraspinal abscess was also done when feasible. The biopsies were performed using Ackerman's needle (Cook Medicals). The biopsy needles were directed to the region of the vertebral endplate where the change was maximum and approachable. The coaxial technique was used. The outer cannula of the Ackerman needle allows multiple passes. The direction of the cannula was slightly changed, or the depth of the needle was increased to obtain optimal samples. The procedure details were recorded. The biospecimens obtained were immediately sent for microbiological and histopathological assessments. The microbiological assessment included Mycobacteria Growth Indicator Tube (MGIT), Xpert TB, bacterial culture, and fungal culture for determining the presence of organisms and antibiotic resistance.

Microbiological Assessment

MGIT: Based on the growth of *Mycobacterium tuberculosis*, the culture was reported as positive or negative for TB.

Bacterial culture: Based on the growth of bacterial organisms, the culture was reported as positive or negative.

XPERT TB: This is a polymerase chain reaction (PCR) based test and if mycobacterial DNA was present in the specimen, it was amplified and detected and reported as positive for TB.

Fungal culture: If fungal element growth was seen, then it was reported as a positive fungal culture.

Histopathological Assessment

Definitive TB was considered when granuloma or caseous necrosis with chronic inflammation with positive acid-fast bacillus (AFB) bacteria. When only granuloma or caseous necrosis with chronic inflammation was noted, it was considered as probable TB.

Definite pyogenic infection was considered when acute neutrophilic infiltration was seen with widespread necrosis and bacteria. Probable pyogenic infection was mentioned when acute neutrophilic infiltration was seen with widespread necrosis.

Statistical Analysis

The results of CT-guided biopsy, drug resistance, and other categorical variables were reported using frequency and percentages. Association of CT-guided biopsy results with sociodemographic variables and other categorical variables was reported using Pearson's chi-squared test or Fisher's exact test. A p value of <0.05 was considered statistically significant. All the analyses were performed using the statistical software STATA version 16.0.

Results

There were 259 patients enlisted in this study. The mean age was 46 ± 15.5 years (12–85 years). The infection was localized to the cervical spine in 1 (0.3%), thoracic spine in 120 (46.3%), lumbar spine in 106 (40.9%), lumbosacral region in 13 (5.02%), sacroiliac joint in 13 (5.0%), and sacral spine in 6 (2.2%) patients. ►**Fig. 1** depicts the distribution of lesions based on the spinal level. CT-guided biopsy of the spine provided a confirmatory result in 149/259 (57.1%) samples. Histopathology provided positive results in 95 (36.6%) of the 241 biospecimens sent, MGIT was positive in 51 (19.9%) of the 250 biospecimens sent, and drug resistance was seen in 6 (11.7%) of the 51 TB positive patients with resistance to HRZE (H: isoniazid; R: rifampicin; Z: pyrazinamide; E: ethambutol) in 1 (16.6%) patient, HRZ in 1 (16.6%) patient, HR in 1 (16.6%) patient, H in 1 (16.6%) patient, and S (S: streptomycin) in 2

(33.3%) patients. Xpert TB provided positive results in 72 (27.8%) of the 254 biospecimens sent and rifampicin resistance was seen in 16 (22.2%) of the 72 TB positive samples. Bacterial culture was positive in 29 (11.2%) of the 250 biospecimens sent, with the most common organism being *Staphylococcus aureus*, which made up 18 (62%) of the 29 isolated organisms and 1 biospecimen grew both methicillin-sensitive *S. aureus* and *Escherichia coli*. Drug-specific resistance was seen in 12 (41.3%) of 29 isolated bacterial cultures with resistance to erythromycin in 5 (41.6%) patients, methicillin in 2 (16.6%) patients, erythromycin + tetracycline resistance in 1 (8.3%) patient, methicillin + erythromycin in 1 (8.3%) patient, methicillin + cotrimoxazole + erythromycin in 1 (8.3%) patient, chloramphenicol + ciprofloxacin in 1 (8.33%) patient, and chloramphenicol + gentamicin in 1 (8.3%) patient.

Many patients had an overlap of diagnostic tests as the same patient's samples showed positivity in more than one diagnostic test. Thirty-two patients had overlap between histopathology and MGIT culture. Thirty-eight patients showed an overlap between histopathology and Xpert TB. Twelve patients showed overlap between histopathology and pyogenic bacterial culture and among these, 3 patients had a growth of pyogenic organisms and was Xpert positive for TB, suggesting dual infection. Thirty two patients were reported as positive on the Xpert TB test. Of these, 30 were negative and 2 did not undergo the MGIT test.

►**Table 1** depicts the results of CT-guided spinal biopsy.

As per ►**Table 2**, the number of persons who had prior ATT is 16 (10.7%) and 23 (20.9%), respectively, in positive and negative CT-guided biopsies. Similarly, 133 (89.2%) and 87 (79.1%) patients in positive and negative CT-guided biopsies, respectively, did not have prior ATT. The association between prior ATT and CT-guided biopsy is statistically significant with a p value of 0.019.

Patients who had an inconclusive histopathology biopsy result had the presentation as listed in ►**Table 3**. Clinical outcomes of patients presenting with a negative CT biopsy result are listed in ►**Table 4**. The complication recorded in this study was 0.3% (1/259). The patient reported bleeding at the needle insertion site, and he was given 500 mL normal saline postoperatively and was kept under observation for 3 to 5 hours. However, the vitals were stable throughout the procedure. Postprocedure CT showed no significant hematoma. There was no mortality.

Tru-cut biopsy for soft-tissue samples was done in 40.5% patients (105/259), trephine biopsy for bone lesions was done in 45.5% patients (118/259), and 13.8% patients (36/259) had samples taken via both tru-cut and trephine biopsy method. On comparing the yield of CT-guided biopsy based on the methods used to obtain the samples, tru-cut biopsy was positive in 62.8% (66/105) and trephine biopsy was positive in 45.7% (54/118) and the sample obtained from both biopsy techniques was positive in 80.5% (29/36) patients. The association between tru-cut, trephine, tru-cut and trephine with CT biopsy was evaluated using Pearson's chi-squared test. The p value was <0.001 , which shows that there is a statistically significant association between the variables. ►**Table 5** depicts the

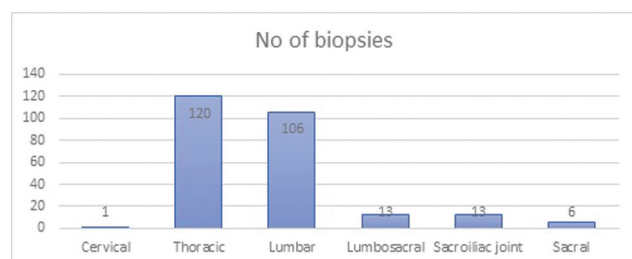


Fig. 1 Distribution of lesions based on spinal level.

Table 1 Results of CT-guided spinal biopsy

Tests	Frequency, n (%) (N = 259)
Histopathology	
Definite TB	9 (3.4)
Probable TB	72 (27.7)
Positive for pyogenic	14 (5.4)
Inconclusive	146 (56.3)
Not done (due to inadequate sample)	18 (6.9)
MGIT	
TB positive	51 (19.6)
TB negative	199 (76.8)
Not done (due to inadequate sample)	9 (3.4)
Bacterial culture	
Positive culture	29 (11.2)
Negative culture	221 (85.3)
Not done (due to inadequate sample)	9 (3.4)
Total	259
XPERT TB	
TB positive	72 (27.8)
TB negative	182 (70.2)
Not done (due to inadequate sample)	5 (1.9)
Overall CT-guided biopsy	
Positive (positive in any of the component histopathology, MGIT, bacterial culture, XPERT TB)	149 (57.5)
Negative (negative result in all the component histopathology, MGIT, bacterial culture, and XPERT TB)	110 (42.4)

Abbreviations: CT, computed tomography; MGIT, mycobacteria growth indicator tube.

Table 2 Association of CT-guided biopsy and prior ATT

Variables	CT biopsy = positive (n = 149)	CT biopsy = negative (n = 110)	p-Value
Prior ATT			0.019
Yes	16 (10.7%)	23 (20.9%)	
No	133 (89.3%)	87 (79.1%)	

Abbreviations: ATT, antitubercular therapy; CT, computed tomography.

comparison of tru-cut, trephine, and tru-cut and trephine with CT biopsy.

Discussion

The current study is among the largest cohorts analyzing the diagnostic value of the CT-guided spinal biopsy. As men-

Table 3 Presentation of inconclusive histopathology

Pathology inconclusive	Count
Chronic osteomyelitis	41
Nonspecific chronic inflammation	50
Necrosis and fibrosis and fibroadipose tissue	29
Hematopoiesis	2
Sample inadequate	2
Hodgkin's lymphoma by paraaortic node biopsy	1
Multiple myeloma by bone marrow biopsy	1
Eosinophilic dense infiltrate	1
Repeat open biopsy positive	10
Repeat open biopsy negative	4
Repeat CT spinal biopsy positive	2
Repeat CT spinal biopsy negative	3
Total	146

Abbreviations: CT, computed tomography.

Table 4 Clinical outcome of CT-guided biopsy negative patients

Clinical outcome of CT negative patients	Count
Antibiotics and improved	11
ATT and improved	32
Antibiotics and lost to follow-up	7
ATT and lost to follow-up	22
Open surgical biopsy positive	10
Open surgical biopsy negative	4
CT spinal biopsy repeat positive	2
CT spinal biopsy repeat negative	3
Lost to follow-up	17
Myeloma with bone marrow aspiration	1
Hodgkin's lymphoma with para-aortic lymph node biopsy	1
Total	110

Abbreviations: ATT, antitubercular therapy; CT, computed tomography.

tioned earlier, the diagnostic yield of this minimally invasive day care procedure is 57%. Among the patients who could not get a conclusive report, repeat CT-guided biopsy was performed in 6/259 (1.9%) patients and surgical open biopsy in 14/259 (5.4%) patients.

Review of literature showed an overall CT-guided biopsy diagnostic yield of 61% (20/33) for tuberculous spondylitis and 33% (22/67) for pyogenic spondylitis as per Joo et al.⁸ Garg et al reported positivity for microbiology in 19% (16/84) of specimens and 41% (25/61) specimens showed positivity for pathology in infections.¹⁰ Waqas et al reported a yield of 75.8% (69/91) for Pott's spine, of which histopathology was positive in 63.7% (58/91), and microbiological culture was

Table 5 Comparison of tru-cut, trephine, and tru-cut and trephine with CT biopsy

	Tru-cut (n = 105)	Trephine (n = 118)	Tru-cut and trephine (n = 36)	p-Value
CT biopsy positive	66 (62.86%)	54 (45.76%)	29 (80.56%)	<0.001
CT biopsy negative	39 (37.14%)	64 (54.24%)	7 (19.44%)	

Abbreviation: CT, computed tomography.

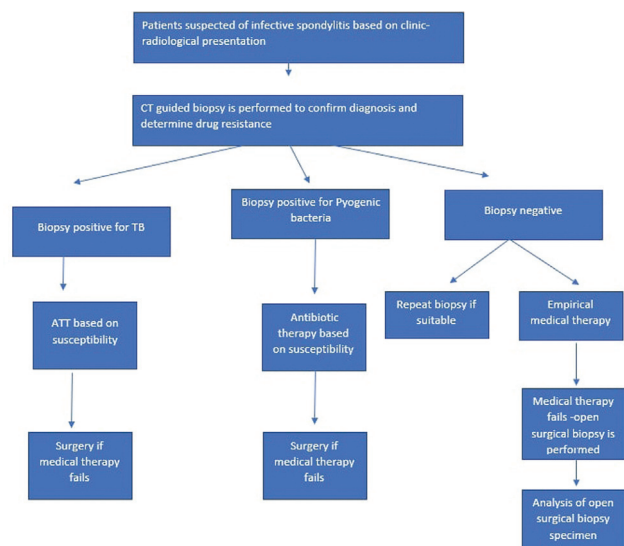


Fig. 2 Protocol of diagnosis and management of an infective spondylitis patient.

positive in 13.1% (12/91).¹¹ Rehm et al reported 25% (21/84) microbiologic isolation of organisms, and *S. aureus* was isolated in 42.3% (9/21) of the positive culture.¹² Culture was positive in 36% (9/25) of samples for suspected infective spondylitis and isolated *S. aureus* in 16% (4/25) and *M. tuberculosis* in 12% (3/25) of the positive cultures as per Enoch et al.¹³ Nam et al reported a 33.3% yield for pyogenic spondylodiscitis.¹⁴ A study done by Chew et al in 2001 reported a yield of 91% (39/43) using strict microbiological criteria and, when combined with cytopathology, reported a yield of 95% (41/43) in patients suspected to have active infectious discitis.⁹ Babu et al in 1994 found a high overall diagnostic yield of 90.6% for infections and neoplasms and *M. tuberculosis* was diagnosed in 93.1% (27/29) of confirmed inflammatory pathology and only 6.89% (2/29) were pyogenic.¹⁵ This study was performed at the beginning of the “CT-guided procedures era” nearly three decades ago. A small sample size, retrospective nature, and possibility of different case selection could be some factors responsible for an unusually high yield.

Our study revealed prior ATT influenced the outcome of the biopsy result. Many studies in the literature like the study done by Rankine et al in 2004 revealed that isolation of an organism decreased from 40 to 25% if patients had received prior antibiotics.¹⁶ Seventy percent of those receiving antibiotics were culture negative in the studies by Hassoun et al.¹⁷ In a study done by Enoch et al, 56% (14/25) were

under empirical antibiotic therapy. Among them, 85.7% (12/14) were negative on culture. This may imply that antibiotic therapy is the one of the reasons for the negative microbiological culture.¹³ Empirical ATT is a common practice in endemic regions; however, such a practice should be discouraged as it reduces yield. In the era of multidrug-resistant (MDR) TB, it can complicate treatment.

In our study, CT guided spinal biopsy has very less inherent complications at 0.39% (1/259). The reported incidence rates in the literature range from 0 to 10%, with serious complication rates being less than 1%.¹⁸ The patient in our study had significant bleeding at needle insertion site. However the vital parameters were stable. Post procedure CT showed no significant hematoma and he was managed conservatively. The current protocol of diagnosis and management of an infective spondylitis patient in our institution is as shown in ►Fig. 2.

Being a retrospective study, there is an inherent bias in patient selection. The patients included in the study had diverse clinical presentations, and the procedures were performed by different interventional radiologists. We would have also missed out on some minor complications. The detailed follow-up and treatment of the patient are beyond the scope of this study. In the literature, there is a lack of randomized case-control studies comparing CT-guided and surgical biopsies among patients suspected of having infectious spondylitis. In a study by Martin Alonso J et al, 67.4% (56/83) yielded positive results on gold standard open surgical biopsy.⁵ All clinicoradiologically suspected patients of infection need not truly have infection and many patients would have already received antimicrobial therapy.

In conclusion, CT-guided percutaneous biopsy for suspected vertebral osteomyelitis is safe and effective. The majority of the CT negative patients were treated with empirical ATT as TB is endemic in the region. This information is potentially useful in counseling the patients. In this study, we have also suggested a treatment algorithm.

Funding
None.

Conflict of Interest
None declared.

References

- Cottle L, Riordan T. Infectious spondylodiscitis. *J Infect* 2008;56(06):401–412
- Lam KS, Webb JK. Discitis. *Hosp Med* 2004;65(05):280–286

- 3 Ross PM, Fleming JL. Vertebral body osteomyelitis: spectrum and natural history. A retrospective analysis of 37 cases. *Clin Orthop Relat Res* 1976;((118):190–198
- 4 Waheed G, Soliman MAR, Ali AM, Aly MH. Spontaneous spondylodiscitis: review, incidence, management, and clinical outcome in 44 patients. *Neurosurg Focus* 2019;46(01):E10
- 5 Martín-Alonso J, Delgado-López PD, Castilla-Díez JM, et al. Role of surgery in spontaneous spondylodiscitis: experience in 83 consecutive patients. *Neurocirugia (Astur : Engl Ed)* 2018;29:64–78
- 6 Kang M, Gupta S, Khandelwal N, Shankar S, Gulati M, Suri S. CT-guided fine-needle aspiration biopsy of spinal lesions. *Acta Radiol* 1999;40(05):474–478
- 7 Feroz I, Makhdoomi RH, Khursheed N, Shaheen F, Shah P. Utility of computed tomography-guided biopsy in evaluation of metastatic spinal lesions. *Asian J Neurosurg* 2018;13(03):577–584
- 8 Joo E-J, Yeom J-S, Ha YE, et al. Diagnostic yield of computed tomography-guided bone biopsy and clinical outcomes of tuberculous and pyogenic spondylitis. *Korean J Intern Med (Korean Assoc Intern Med)* 2016;31(04):762–771
- 9 Chew FS, Kline MJ. Diagnostic yield of CT-guided percutaneous aspiration procedures in suspected spontaneous infectious discitis. *Radiology* 2001;218(01):211–214
- 10 Garg V, Kosmas C, Young PC, Togaru UK, Robbin MR. Computed tomography-guided percutaneous biopsy for vertebral osteomyelitis: a department's experience. *Neurosurg Focus* 2014;37(02):E10
- 11 Waqas M, Qadeer M, Faiz F, Alvi MA, Bari ME. Computed tomography-guided biopsy for potts disease: an institutional experience from an endemic developing country. *Asian Spine J* 2015;9(03):394–398
- 12 Rehm J, Veith S, Akbar M, Kauczor HU, Weber MA. CT-guided percutaneous spine biopsy in suspected infection or malignancy: a study of 214 patients. *Röfo Fortschr Geb Röntgenstr Neuen Bildgeb Verfahr* 2016;188(12):1156–1162
- 13 Enoch DA, Cargill JS, Laing R, Herbert S, Corrah TW, Brown NM. Value of CT-guided biopsy in the diagnosis of septic discitis. *J Clin Pathol* 2008;61(06):750–753
- 14 Nam KH, Song GS, Han IH, Choi BK, Cha SH. Diagnostic value of biopsy techniques in lumbar spondylodiscitis: percutaneous needle biopsy and open biopsy. *Korean J Spine* 2011;8(04):267–271
- 15 Babu NV, Titus VT, Chittaranjan S, Abraham G, Prem H, Korula RJ. Computed tomographically guided biopsy of the spine. *Spine* 1994;19(21):2436–2442
- 16 Rankine JJ, Barron DA, Robinson P, Millner PA, Dickson RA. Therapeutic impact of percutaneous spinal biopsy in spinal infection. *Postgrad Med J* 2004;80(948):607–609
- 17 Hassoun A, Taur Y, Singer C. Evaluation of thin needle aspiration biopsy in the diagnosis and management of vertebral osteomyelitis (VO). *Int J Infect Dis* 2006;10(06):486–487
- 18 Peh W. CT-guided percutaneous biopsy of spinal lesions. *Biomed Imaging Interv J* 2006;2(03):e25