

## A Rare Case Report of Flexion Teardrop Cervical Fracture with Blunt Vertebral Artery Injury Leading to Stroke

### Abstract

Non penetrating trauma to vertebral artery is a known complication in craniovertebral trauma. They are mainly reported with facet dislocations or injuries involving the foramen transversarium. Such a type of injury is rarely seen with flexion injuries. We report such a case leading to cerebellar stroke in a young male presenting to us with hemiparesis. A 43-year-old male presented to us 1 month post trauma after a motor vehicular accident with complaint of weakness of right half of the body since the trauma. He suffered blunt trauma to head and neck and complained of a flail right upper limb since trauma and weakness of the right lower limb which had partly improved. He was conservatively managed elsewhere. Radiographic investigations revealed complete occlusion of the right vertebral artery above the level of 6<sup>th</sup> cervical vertebra and flexion teardrop fracture of 5<sup>th</sup> cervical vertebra. He was managed conservatively for the vertebral artery injury (VAI) and corpectomy of C5 vertebra with anterior cervical plating and fusion. Such a rare type of injury can present with unexplained neurodeficit which needs appropriate radiological investigations for diagnosis before ascribing the cause to cord trauma. Hence, all high velocity motor vehicular accidents with associated fractures and neurodeficit should be screened for blunt VAIs.

**Keywords:** *Blunt vertebral artery injury, cerebellar stroke, flexion teardrop fracture, vertebral artery thrombosis*

### Introduction

Blunt vertebral artery injuries are reported in literature with a variable incidence. The risk of sustaining such injury increases with fracture dislocations of the cervical spine. The key to management of these injuries lies in an early diagnosis of vertebral artery trauma. Thrombosis of vertebral artery may predispose to further embolization and a resultant infarct. This case report emphasises the importance of blunt vertebral artery injury in cervical spine trauma and its management.

### Case Report

A 43-years-old male suffered a high velocity motor vehicular accident after fall from a bike. He suffered blunt trauma to the head and neck. The patient complained of difficulty in movement of right upper and lower limb with a flail right upper limb. He was treated conservatively by a local physician. Due to nonresolving weakness, the patient was referred to us. The patient at

the time of presentation complained of pain in the neck and hemiparesis. He also had a resolving scalp hematoma and uniting right undisplaced clavicle fracture. He had a flail right upper limb and nonfunctional power in the right lower limb. The patient also had loss of coordination in the right lower limb. He had a partial sensory loss of crude touch, pain, and temperature on the same side up to C4 dermatome level. On deep palpation, there was midline tenderness over C5 vertebra. Neck movements were painful. Other clinical findings were unremarkable. There was no evidence of ataxia, facial pain, nystagmus, or dysarthria.

Plain radiography revealed a flexion teardrop fracture of the C5 vertebra with posterior translation of proximal spinal column [Figures 1 and 2]. Computed topographic (CT) scan revealed the similar fracture with fracture of the bilateral facets of C5 vertebra without any subluxation [Figure 3]. There was no canal compromise. Magnetic resonance imaging (MRI) revealed no anterior source of cord compression even

**Sudhir Srivastava,  
Aditya Raj,  
Sunil Bhosale,  
Nandan Marathe,  
Manojkumar  
Gaddikeri**

*Department of Orthopedics, Seth GS Medical College and King Edward Memorial Hospital, Mumbai, Maharashtra, India*

### Address for correspondence:

*Dr. Aditya Raj,  
Department of Orthopedics, 6<sup>th</sup> Floor, Multistorey Building, Seth GS Medical College and King Edward Memorial Hospital, Parel, Mumbai - 400 012, Maharashtra, India.  
E-mail: adityagmck@gmail.com*

### Access this article online

**Website:** [www.asianjns.org](http://www.asianjns.org)

**DOI:** 10.4103/ajns.AJNS\_31\_20

### Quick Response Code:



This is an open access journal, and articles are distributed under the terms of the Creative Commons Attribution-NonCommercial-ShareAlike 4.0 License, which allows others to remix, tweak, and build upon the work non-commercially, as long as appropriate credit is given and the new creations are licensed under the identical terms.

For reprints contact: WKHLRPMedknow\_reprints@wolterskluwer.com

**How to cite this article:** Srivastava S, Raj A, Bhosale S, Marathe N, Gaddikeri M. A rare case report of flexion teardrop cervical fracture with blunt vertebral artery injury leading to stroke. *Asian J Neurosurg* 2021;16:187-90.

**Submitted:** 22-Jan-2020 **Revised:** 14-Jun-2020

**Accepted:** 15-Oct-2020 **Published:** 23-Feb-2021

with mild posterior displacement of the proximal column [Figure 4]. It however demonstrated the absence of flow void of the right vertebral artery on T1-weighted axial images [Figure 5]. MRI of brain and CT angiography were added for further investigations which revealed complete occlusion of the right vertebral artery at the level of C5 vertebra. At the time of presentation, there was right posterior inferior cerebellar artery (PICA) territory infarct secondary to right vertebral artery injury (VAI) [Figure 6]. There was presence of T2/fluid attenuated inversion recovery hyperintense area in the right cerebellum, dorsolateral medulla, and upper lateral cervical cord with restriction on diffusion-weighted imaging suggestive of acute infarct. There was the absence of any anterior or posterior source of cord compression at C5 vertebra. Due to acute nature of trauma and anticipating surgical intervention, any antithrombotic could not be started. The patient was counseled regarding the outcomes and advised regarding surgical intervention at the 5<sup>th</sup> cervical vertebra in terms of corpectomy and anterior cervical fusion with plating in view of the unstable nature of the spinal injury. The decision for operative intervention was preferred due to unstable proximal spinal column. The patient underwent the procedure from anterior Smith-Robinson approach in supine position. Corpectomy of C5 vertebra was achieved. Autologous tricortical strut graft for anterior fusion was harvested from the iliac crest and fashioned anteriorly in the trough created by the corpectomy. The graft was supplemented by anterior cervical plating and mobilized postoperatively with a Philadelphia type brace [Figures 7 and 8]. Postoperatively, the motor power of lower limb improved by a single grade, but in upper limb recovery of only finger movements occurred. As per our institutional protocol, we started this patient on oral anti platelets postsurgery in view of the vertebral artery thrombosis.

## Discussion

The incidence of VAI with cervical spine trauma ranges from 3% to 39%. This association is important as the results of both together are far more severe than isolated cervical spine trauma. Although routine radiological investigations frequently identify the type of cervical injury but VAI is diagnosed only with high degree of suspicion and with special investigations. It is important to screen all such patients of cervical spine trauma with unexplained neurological deterioration for a blunt vertebral artery trauma. It is most frequently associated with facetral subluxations, dislocations, or ligamentous injuries causing instability most frequently at the transverse foramen of 6<sup>th</sup> cervical vertebra followed by atlanto-axial junction. Cervical spine trauma used to be infrequently related to blunt VAI which later then rose in number after these patients were subjected to screening for such injuries. The rationale behind treatment of these injuries by systemic anticoagulation was based on the fact that they could improve outcomes in asymptomatic patients.<sup>[1]</sup> These unusual innocuous looking injuries can be potentially devastating and

need to be diagnosed early for an effective management<sup>[2,3]</sup> Such injuries are frequently caused by a flexion-distraction mechanism of injury including facetral subluxations and dislocations, as reported by Louw *et al.*<sup>[4]</sup> The exact incidence of such injuries remains variable largely due to the patient inclusion criteria in the studies but roughly ranges from 3% to 39%. The vertebral injuries can broadly be categorized into three types: (a) Fractures involving the foramen transversarium, (b) Facetral subluxations or dislocations, (c) fractures involving the upper cervical spine. Other types of fractures of the cervical spine are at an insignificant risk of blunt VAI. The development of this observation is primarily derived from the studies based on blunt carotid artery injuries after cervical spine trauma mainly hyperextension injuries.<sup>[3,5]</sup> However, no specific type of vertebral injury pattern can be uniformly attributed to blunt VAI. Most of these injuries are associated with motor vehicular accidents but they are also reported with contact sports, chiropractic manipulations, and minor neck trauma.<sup>[6]</sup> This makes identification and diagnosis of such injuries a difficult job in those patients where high energy trauma is not involved. There does not exist any predisposition for a particular side of involvement but in the study by Walter *et al.*,<sup>[7]</sup> they reported 88% of patients with stroke had a left VAI. This in addition to the study by Yi-Kai *et al.*<sup>[8]</sup> reported that right vertebral arteries inherently had less blood supply, thus unable to compensate for the loss to the left side. The gold standard investigation for the diagnosis of VAI is cerebral arteriography but infrequently used due to its invasive nature and difficulty in carrying out such investigations in the acute trauma settings. It is also added with complications associated with contrast and catheter. Cerebrovascular injuries are classified according to a described grading scale but is angiography based and infrequently performed.<sup>[3]</sup> Other modalities suggested for diagnosis of blunt trauma to vertebral artery are CT angiography and MR angiography. Duplex scanning which is frequently used for diagnosing blunt carotid artery trauma is of lesser value because of low sensitivity, operator dependence, and lack of any pathognomonic findings. CT angiography on the other hand is a better tool owing to good visualization but it is likely to miss certain injuries due to the anatomic course of the vertebral artery through bony structures.<sup>[9]</sup> Its efficacy is improved due to multidetector CT. MR angiography offers a good spectrum for the diagnoses as it is also used for evaluation of cervical spine fractures and assessment of ligamentous anatomy.<sup>[10]</sup> However, its use in acute trauma setting is of limited use owing to more time consumed and general status of the patient. Thus, CT angiography has turned to be an effective alternative to catheter angiography and is routinely employed in several centers for screening VAIs. The association of posterior circulation stroke is also reported as high as 24%. The predominantly involved artery is PICA leading to brainstem stroke. The patient may typically have symptoms similar to lateral medullary syndrome or may have vertebrobasilar ischemia. The treatment protocol depends on the associated injuries both systemically and locally to the

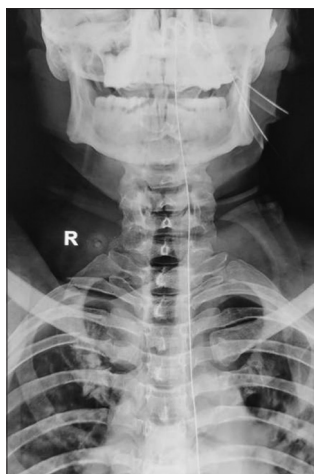

Figure 1: Plain radiograph anteroposterior view demonstrating C5 vertebral body fracture

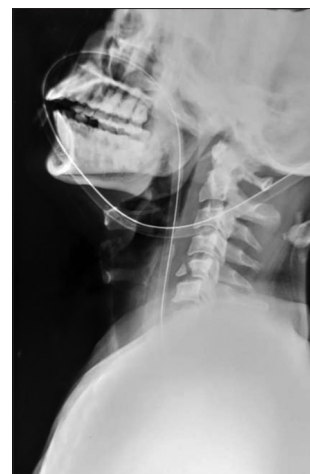

Figure 2: Plain radiograph lateral view demonstrating C5 vertebral body fracture flexion tear-drop type

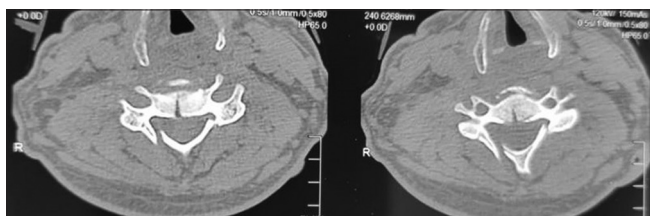


Figure 3: Computed tomographic scan axial view of cervical spine demonstrating facet fracture in addition to C5 body fracture

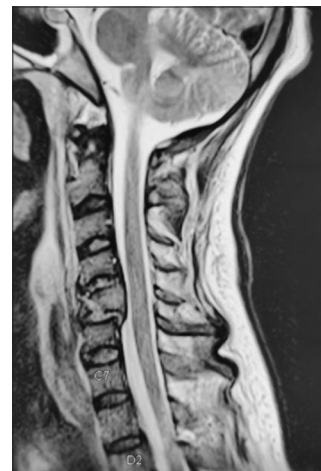


Figure 4: Magnetic resonance imaging T2 sagittal view demonstrating the fracture with posterior shift of proximal spinal column

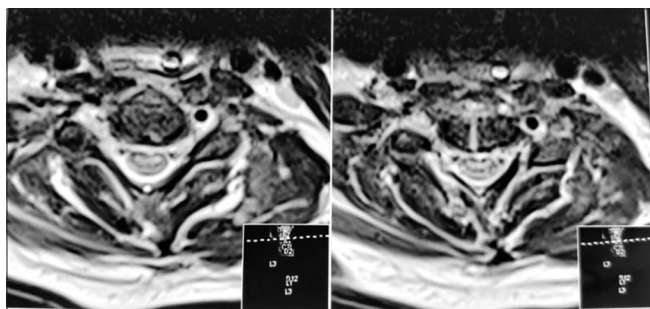


Figure 5: Magnetic resonance imaging T2 weighted axial view demonstrating the fracture with deficient vertebral artery flow void on right side

cervical spine along with the neurological deficit. Treatment specific to cervical spine depends on the column stability and need for anterior or posterior instrumentation. Early surgical fixation in unstable fractures is indicated to prevent any worsening. There are no clear guidelines regarding the treatment for the VAI. The general recommendation is toward systemic anticoagulation although recently it has met significant opposition. Anticoagulation helps in those cases where there is intimal tear but no clear occlusion exists to prevent late onset thrombosis and stroke. The long-term results in these patients are encouraging. However, in other patients with diagnosed stroke or other system trauma involvement, systemic anticoagulation may not to be put to use due to obvious contraindications in patients with acute trauma. Antiplatelet therapy could also be used in some cases which is prone for less complications and easy patient

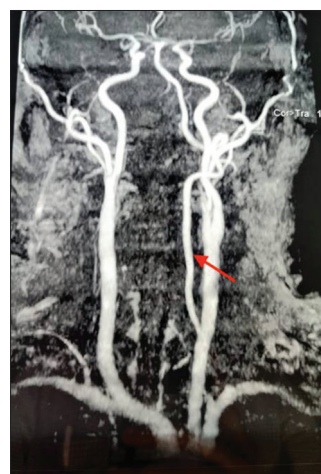

Figure 6: MR angiography demonstrating right vertebral artery deficient filling as compared to the left normal vertebral artery (red arrow)

compliance. The overall outcome in patients with onset of stroke at the time of initial diagnosis remains poor and unaltered by systemic anticoagulation or antiplatelets.<sup>[11]</sup> A

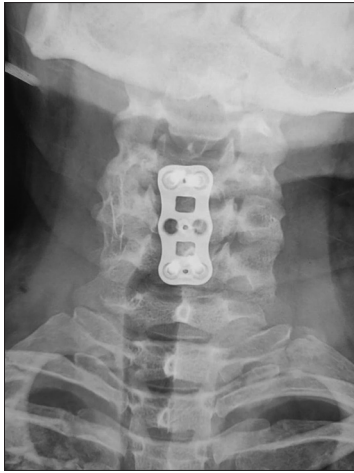

Figure 7: Postoperative plain anteroposterior radiograph demonstrating C5 corpectomy, bone grafting, and anterior cervical plating

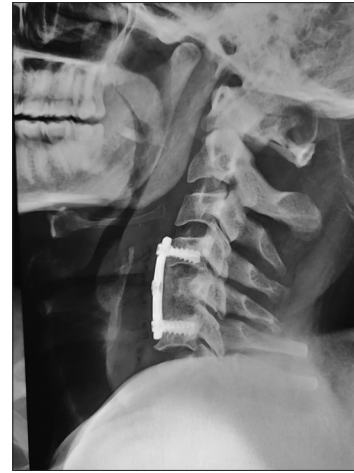

Figure 8: Postoperative plain lateral radiograph demonstrating C5 corpectomy, bone grafting, and anterior cervical plating

significant number among these patients may also eventually be lost to a fatal outcome and it should be kept in mind while managing this group of patients. Initially, asymptomatic patients may also deteriorate later in about one-fourth of the cases and this warrants an early diagnosis and intervention. Due to the absence of precise diagnostic and treatment guidelines, the management largely relies on institutional guidelines and hence the outcomes may not be comparable in all cases. A clear list of possibilities is certainly warranted where screening methods could be applied. Multiple such patient types are reported such as – cervical spine fracture, unexplained neurological examination, patients with facial fractures and Horner’s syndrome.

## Conclusion

Any unexplained neurological finding in patients with cervical fracture dislocations need appropriate investigations to rule out any blunt VAIs. Once diagnosed, effective anticoagulation can prevent further embolization and development of stroke. Watchful attitude is warranted for all such injuries for a fruitful outcome.

## Consent

Informed patient consent has been obtained for participation and publication.

## Declaration of patient consent

The authors certify that they have obtained all appropriate patient consent forms. In the form, the patient has given his consent for his images and other clinical information to be reported in the journal. The patient understands that name and initials will not be published and due efforts will be made to conceal identity, but anonymity cannot be guaranteed.

## Financial support and sponsorship

Nil.

## Conflicts of interest

There are no conflicts of interest.

## References

1. Fabian TC, Patton JH Jr, Croce MA, Minard G, Kudsk KA, Pritchard FE. Blunt carotid injury. Importance of early diagnosis and anticoagulant therapy. *Ann Surg* 1996;223:513-22.
2. Miller PR, Fabian TC, Croce MA, Cagiannos C, Williams JS, Vang M, *et al.* Prospective screening for blunt cerebrovascular injuries: Analysis of diagnostic modalities and outcomes. *Ann Surg* 2002;236:386-93.
3. Biffl WL, Moore EE, Ryu RK, Offner PJ, Novak Z, Coldwell DM, *et al.* The unrecognized epidemic of blunt carotid arterial injuries: Early diagnosis improves neurologic outcome. *Ann Surg* 1998;228:462-70.
4. Louw JA, Mafoyané NA, Small B, Naser CP. Occlusion of the vertebral artery in cervical spine dislocations. *J Bone Joint Surg Br* 1990;72:679-81.
5. Mueller CA, Peters I, Podlogar M, Kovacs A, Urbach H, Schaller K, *et al.* Vertebral artery injuries following cervical spine trauma: A prospective observational study. *Eur Spine J* 2011;20:2202-9.
6. Lee KP, Carlini WG, McCormick GF, Albers GW. Neurologic complications following chiropractic manipulation: A survey of California neurologists. *Neurology* 1995;45:1213-5.
7. Biffl WL, Moore EE, Elliott JP, Ray C, Offner PJ, Franciose RJ, *et al.* The devastating potential of blunt vertebral arterial injuries. *Ann Surg.* 2000 May;231(5):672-81. doi: 10.1097/0000658-200005000-00007.
8. Yi-Kai L, Yun-Kun Z, Cai-Mo L, Shi-Zhen Z. Changes and implications of blood flow velocity of the vertebral artery during rotation and extension of the head. *J Manipulative Physiol Ther* 1999; 22:91–95.
9. Rogers FB, Baker EF, Osler TM, Shackford SR, Wald SL, Vieco P. Computed tomographic angiography as a screening modality for blunt cervical arterial injuries: Preliminary results. *J Trauma* 1999;46:380-5.
10. Zuber M, Meary E, Meder JF, Mas JL. Magnetic resonance imaging and dynamic CT scan in cervical artery dissections. *Stroke* 1994;25:576-81.
11. Parikh AA, Luchette FA, Valente JF, Johnson RC, Anderson GL, Blebea J, *et al.* Blunt carotid artery injuries. *J Am Coll Surg* 1997;185:80-6.