



Open Access

ORIGINAL ARTICLE

Male Infertility

Chronic epididymitis and Grade III varicocele and their associations with semen characteristics in men consulting for couple infertility

Alejandro Oliva¹, Luc Multigner²

Chronic epididymitis and varicocele are frequently observed genital disorders in men consulting for couple infertility, but their impact on semen characteristics at the time of infertility consultation is still a matter of debate. We investigated 652 male partners of couples who had their first infertility consultation between 1999 and 2015 in Argentina. Men with chronic epididymitis ($n = 253$), Grade III varicocele ($n = 106$), and both conditions ($n = 125$) were compared with a control group ($n = 168$) composed of men without these disorders or any other recognized causes of male infertility. We showed that men who presented isolated chronic epididymitis were more likely to have high percentages of low sperm motility and abnormal sperm morphology as well as a high number of white blood cells. Men with isolated Grade III varicocele had low sperm production and motility and an increased percentage of abnormal sperm morphology. Finally, men who simultaneously presented chronic epididymitis with Grade III varicocele had a low sperm motility and increased percentage of abnormal sperm morphology as well as a high number of white blood cells. Physical examination of the genital organs may identify common disorders, potentially involved as causal factors of patient's infertility. These disorders are associated with specific seminal profiles that should help in identifying the best treatment from the available therapeutic options, effectiveness, safety, and allowing as much as possible natural conception.

Asian Journal of Andrology (2018) 20, 360–365; doi: 10.4103/aja.aja_78_17; published online: 6 March 2018

Keywords: couple subfertility; epididymitis; male factor infertility; semen quality; varicocele

INTRODUCTION

Male factors are involved in at least half of the couples who consult for infertility.^{1,2} Knowledge of the causes of infertility and their pathophysiological basis is essential for proposing specific and effective treatments in an adequate cost-benefit ratio.³

Semen analysis is the cornerstone of investigation for male infertility, although it has inherent limitations.^{4,5} It is routinely used to classify sperm parameters according to comprehensive descriptive categories (normozoospermia, azoospermia, oligozoospermia, asthenozoospermia, and teratozoospermia). While seminal analysis is highly informative in characterizing the fertility status of men, it is of limited relevance in identifying causal factors of patient's infertility.⁶

Topographic localization of the cause is the first principle of identification and classification of disorders of male infertility.⁷ In this regard, physical examination, particularly visual inspection and palpation of the external male genital organs, is invaluable for identifying etiological factors and their nature.⁸ Thereafter, linking such disorders to seminal characteristics may help in the understanding of the underlying pathophysiology and to guide the appropriate conduct for the patient.

Abnormal palpations of the extratesticular excurrent ducts, epididymis, and vas deferens, as well as of the veins within the scrotum, are frequent genital signs not only in urological consultations, but

also in men consulting for infertility.^{9–14} At the time of infertility consultations, these genital signs are usually asymptomatic and suggest the presence of chronic epididymitis and varicocele. Even if there is some clinical and pathological evidence linking these disorders to infertility, changes in the affected seminal variables remain poorly studied and controversial.

Chronic epididymitis is an inflammatory condition that is frequently related to past events, such as bacterial or viral invasion or testicular trauma.^{15,16} Few studies, most of them based on a limited number of patients, have suggested that these disorders may affect sperm cell characteristics, such as number, motility, or morphology,^{15,17} but a clear picture is still lacking. In addition, a high number of white blood cells (WBCs) in the semen have been reported and interpreted as a local immunological response.¹⁸

Varicocele is characterized by an abnormal enlargement of the pampiniform venous plexus in the scrotum. Considering the predominance of the left-side varicocele, most etiological hypotheses have their origin in the unique anatomy of the left testicular vein.^{19,20} Studies on the effects of varicocele on seminal characteristics have resulted in conflicting conclusions, despite evidence that varicocele affects testicular function, and several mechanistic hypotheses have been proposed.^{13,21} This may be partially due to the clinical heterogeneity of varicocele, resulting in different effects on seminal characteristics.²¹

¹Center for Interdisciplinary Studies, National University of Rosario, Rosario 2000, Argentina; ²University of Rennes, Inserm, EHESP, Irset (Institut de recherche en santé, environnement et travail), UMR_S 1085, Rennes F-35000, France.

Correspondence: Dr. L. Multigner (luc.multigner@inserm.fr)

Received: 17 July 2017; Accepted: 07 December 2017

It is now recognized that only Grade III varicoceles may significantly affect semen quality,^{22,23} which are those that are visible and palpable at physical examination and that significantly affect the diameter and reflux of blood in the largest vein in the pampiniform plexus.

Here, we aimed to evaluate the relationships between frequent genital disorders, mostly asymptomatic, initially revealed by physical examination, namely chronic epididymitis and Grade III varicocele, and semen characteristics in male partners from couples having their first infertility consultation in Argentina. We also reported for the first time the semen profile of men who simultaneously presented with epididymitis and a Grade III varicocele at the time of consultation.

PATIENTS AND METHODS

Study area and population study

This cross-sectional study took place in the Santa Fe and Entre Rios provinces in Argentina among couples attending the Andrology Unit of one of the four medical institutions in Argentina (Orono Group, Rosario; Garibaldi Italian Hospital, Rosario; Urology Center, Santa Fe; and Adventist Clinic of the Plata, Libertador General San Martin) between June 1999 and June 2015. The initial study population comprised 966 male partners from consecutive couples seeking advice after failure to establish a pregnancy during one year or more of unprotected intercourse. We only considered couples for which the male partner did not have an episode of fever or had taken medications (antibiotics and psychotherapeutic drugs) during the previous 3 months.

Information was collected at several stages. A structured interview was conducted during the first visit to obtain information on the basic demographic, medical, surgical, and reproductive history, past and recent illnesses and treatment, and lifestyle. A semen evaluation that included two semen analyses at an interval of 2–4 weeks was then ordered. The first semen analysis included a semen culture that routinely comprised the search for Gram-positive and Gram-negative bacteria, *Chlamydia trachomatis*, *Mycoplasma hominis*, and *Ureaplasma urealyticum*. Semen analyses were conducted in the corresponding laboratories of each medical institution. During the second visit, which took place a few weeks after the second semen analysis, a complete physical and andrological examination was carried out.

Physical examination

All men were examined in both supine and standing positions by one physician (AO). The examination in the supine position included visual examination of the penis, urethral meatus position, pubic hair distribution, and scrotum, and palpation and comparison of the testis, epididymis, and vas deferens. The spermatic venous plexus was carefully examined by palpation, with and without the Valsalva maneuver, with the patients in both the supine and standing positions. Testicular volume was assessed using a Prader orchidometer (Pro-Health Product Ltd., Guangzhou, China) which provides measurements closely related to those obtained by ultrasounds.²⁴

We defined chronic epididymitis in those patients who presented any indurations, irregularities, or thickening, and that reported a past event of scrotal pain episode related to genital infection or trauma. Ambiguous cases of abnormal palpation of the epididymis or vas deferens or when patients did not report past events were confirmed by direct ultrasound (Toshiba Aplio 300, Toshiba Medical Systems Corporation, Otawara, Japan).^{24,25} Direct ultrasound allows the detection of any modifications in diameter, texture, vascularization, cysts, and calcifications, and their localization in the head, tail, proximal vas deferens, or vas deferens ampulla.²⁴ Grade III varicocele was

defined as those visible through the scrotal skin and palpable without the Valsalva maneuver. Color Doppler ultrasound (Toshiba Aplio 400, Toshiba Medical Systems Corporation) was systematically employed to confirm these clinical varicoceles, as well as ambiguous cases, as recommended by the European Association of Urology.²⁶

Semen analysis

Semen analysis was performed according to the World Health Organization (WHO) guidelines.²⁷ Semen samples were obtained by masturbation after a recommended period of 3 to 5-day sexual abstinence. Semen volume was measured in a graduated pipette, accurate to within 0.1 ml. Sperm concentration was determined by Neubauer hemocytometer (Malassez Hemocytometer, DYNAL®, Thermo Fisher Scientific, Waltham, MA, USA), after an appropriate dilution. Sperm motility was assessed by direct observation in a microscope ($\times 400$, Eclipse E200-LED, Instruments Inc., Melville, NY, USA). Sperm morphology and semen cytology, including WBCs' identification, were assessed by staining slides (May–Grunwald Giemsa staining, MGG-1048, Casa Álvarez, Madrid, Spain) and direct observation under a microscope ($\times 1000$, Nikon Instruments Inc.). WBC identification included the evaluation of lymphocytes and polymorphonuclear cells that can be discriminated from other seminal cells, such as immature sperm cells or epithelial cells. The four laboratories were examined every month using the same internal quality control protocol with frozen semen in straws from fertile individuals. Inter- and intra-assay coefficients of variation were 7.0% and 6.0% for sperm concentration, 17.0% and 9.0% for sperm motility, and 14.0% and 8.0% for sperm morphology, respectively.

Data classification

We first excluded 164 men because they did not complete the entire medical procedure, including physical examination and semen analysis. We further excluded 150 men for whom we identified: (a) well-recognized clinical causes of infertility other than those here under study (mostly mal-descended testes, primary or secondary hypogonadism, spermatic cord torsion, confirmed obstruction of the epididymis or vas deferens, absence of the vasa deferentia, or ejaculatory dysfunction); (b) an active genital infection; (c) past treatment that could have influenced the pituitary–gonadal axis or chemotherapy. The final study population comprised 652 men (**Figure 1**).

Patients with an abnormal (by palpation) epididymis or vas deferens, confirmed by direct echography (Toshiba Medical Systems Corporation) if necessary (68 of 378 cases of epididymitis included in the final analysis), were considered to have chronic epididymitis, with or without extension to the vas deferens. We grouped chronic epididymitis based on their similar etiological factors and pathophysiology, regardless of their laterality.^{28,29} Patients with color Doppler ultrasound (Toshiba Medical Systems Corporation) – confirmed Grade III varicocele – were grouped regardless of their laterality. We found that some patients simultaneously presented chronic epididymitis and varicocele. Thus, we finally defined four groups: isolated chronic epididymitis group, isolated Grade III varicocele group, combined chronic epididymitis and Grade III varicocele group, and a control group in which patients were without chronic epididymitis or Grade III varicocele (**Figure 1**).

For sperm parameters, continuous outcomes (as evaluated by the laboratory) were semen volume (ml), sperm concentration ($\times 10^6 \text{ ml}^{-1}$), total sperm output ($\times 10^6$; the product of seminal volume \times sperm concentration), percentage of total motile spermatozoa, percentage of spermatozoa with normal morphology, and WBC concentration ($\times 10^6 \text{ ml}^{-1}$). Semen characteristics were categorized as dichotomous

variables according to thresholds based on the WHO guidelines for defining reference limits:²⁷ semen volume (<2 vs ≥2 ml), sperm concentration (<20 × 10⁶ vs ≥20 × 10⁶ ml⁻¹), sperm output (<40 × 10⁶ vs ≥40 × 10⁶), sperm motility (<50% vs ≥50%), sperm morphology (<30% vs ≥30%), and WBC concentration (<1 × 10⁶ vs ≥1 × 10⁶ ml⁻¹).

We recorded and classified the following information as continuous variables: age (year), weight (kg), height (m), and testicular volume (ml). Body mass index (BMI) was calculated as weight/height² (kg m⁻²) and categorized as normal weight (<25 kg m⁻²), overweight (≥25 and <30 kg m⁻²), and obese (≥30 kg m⁻²). We also recorded the following data: type of fertility (primary, secondary), season of sperm analysis (autumn, winter, spring, and summer), smoking (ever vs never), and alcohol consumption (ever vs never).

Statistical analysis

Comparisons between groups were made with the Chi-squared test for categorized variables and the Student's *t*-test for continuous variables. In the analyses involving a categorized outcome variable, we used multiple logistic regression analyses to produce odds ratios (ORs) and 95% confidence intervals (95% CI) for the association between semen characteristics and patient categories, adjusted for confounding factors. The control group was always the group of patients without chronic epididymitis and Grade III varicocele. Univariate logistic regression analysis was used to evaluate potential confounding factors (age, BMI, smoking, alcohol consumption, season of sperm analysis, and type of infertility). Factors were considered to be confounding if their inclusion in the model modified the estimate of the OR by >10%.³⁰ Age was always included as a confounding factor in the adjusted model. Missing data for covariates (4 for smoking) were addressed by substituting them by a missing value indicator variable. All analyses were performed with

the Statview software package (SAS Institute Inc., Cary, NC, USA). All *P* values were two sided, and considered to be statistically significant if *P* < 0.05.

Ethical approval

Approval for this study was obtained from the Institutional Review Board of each institution in Argentina (Orono Group, Rosario; Garibaldi Italian Hospital, Rosario; Urology Center, Santa Fe; and Adventist Clinic of the Plata, Libertador General San Martin). Informed consents were obtained from all patients.

RESULTS

General characteristics of the final study population (*n* = 625) and patient groups are presented in **Table 1**. The median age was 34 years and did not differ between patient groups. Most patients (90.0%) consulted for primary infertility, but those presenting with isolated chronic epididymitis or isolated Grade III varicocele were more likely to present a secondary infertility than patients without these genital disorders. Nearly 40% (39.1%) of the men were overweight or obese, and this did not differ between groups except for those presenting with isolated chronic epididymitis, in which the prevalence of being overweight and obese was lower. There was a higher proportion of smokers among patients who had Grade III varicocele, whether isolated or combined with chronic epididymitis. Finally, individuals with chronic epididymitis, whether isolated or combined with Grade III varicocele, tended to have a higher total testicular volume.

Semen characteristics of the study population are presented in **Table 2**. Dichotomized-dependent variables were used to assess the association between patient categories and seminal characteristics presented as the adjusted OR (**Table 3**). The presence of isolated chronic epididymitis was significantly associated with having

Table 1: General characteristics of the study population

Characteristics	All (n=652)	Controls (n=168)	Epididymitis (n=253)	<i>P</i>	Varicocele (Grade III, n=106)	<i>P</i>	Epididymitis and varicocele (Grade III, n=125)	<i>P</i>
Age (year)								
Mean±s.d.	34.2±6.0	34.4±6.6	33.9±6.1	0.391	33.9±5.0	0.434	34.6±5.8	0.862
Median (interquartile)	34.0 (30.0–37.0)	34.0 (30.0–38.0)	34.0 (30.0–37.0)		34.0 (31.0–37.0)		34.0 (31.0–38.0)	
Type of sterility, <i>n</i> (%)								
Primary	587 (90.0)	161 (95.8)	221 (87.4)	0.003	92 (86.8)	0.006	113 (90.4)	0.062
Secondary	65 (10.0)	7 (4.2)	32 (12.6)		14 (13.2)		12 (9.6)	
BMI (kg m ⁻²), <i>n</i> (%)								
<25	397 (60.9)	91 (54.2)	177 (70.0)	0.004	62 (58.5)	0.725	67 (53.6)	0.700
≥25 and <30	96 (14.7)	29 (17.3)	26 (10.3)		15 (14.2)		26 (20.8)	
≥30	159 (24.4)	48 (28.6)	50 (19.8)		29 (27.4)		32 (25.6)	
Smoking*, <i>n</i> (%)								
Never	466 (71.9)	138 (82.1)	184 (73.3)	0.036	65 (61.9)	0.002	79 (63.7)	<0.001
Ever	182 (28.1)	30 (17.9)	67 (26.7)		40 (38.1)		45 (36.3)	
Alcohol consumption, <i>n</i> (%)								
Never	166 (25.5)	51 (30.4)	63 (24.9)	0.217	29 (27.4)	0.595	23 (18.4)	0.020
Ever	486 (74.5)	117 (69.6)	190 (75.1)		77 (72.6)		102 (81.6)	
Season of sperm analysis, <i>n</i> (%)								
Autumn	168 (25.8)	40 (23.8)	65 (25.7)	0.627	33 (31.1)	0.355	30 (24.0)	0.660
Winter	73 (11.2)	22 (13.1)	31 (12.3)		9 (8.5)		11 (8.8)	
Spring	162 (24.8)	43 (25.6)	52 (20.6)		30 (28.3)		37 (29.6)	
Summer	249 (38.2)	63 (37.5)	105 (41.5)		34 (32.1)		47 (37.6)	
Total testicular volume (ml)								
Mean±s.d.	46.8±10.9	44.8±13.1	47.4±9.6	0.057	47.1±10.9	0.238	48.0±9.8	0.075
Median (interquartile)	50.0 (40.0–55.0)	46.0 (38.0–57.0)	50.0 (40.0–55.0)		50.0 (40.0–60.0)		50.0 (40.0–55.0)	

P values were calculated using a two-sided Chi-squared test for the comparison of percentages, the two-sided Student's *t*-test for the comparison of the means (age), or a Mann-Whitney U-test for differences in continuous distribution (total testicular volume). *Four missing data: two in the Epididymitis group, one in the Varicocele group and one in the Varicocele and Epididymitis group. s.d.: standard deviation; BMI: body mass index

Table 2: Semen characteristics of the study population

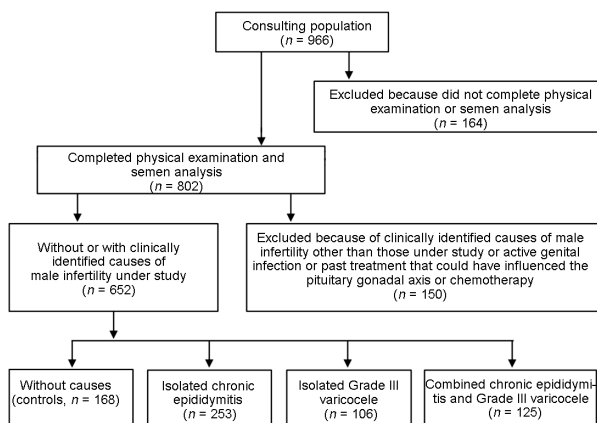
Characteristics	All (n=652)	Controls (n=168)	Epididymitis (n=253)	P	Varicocele (Grade III, n=106)	P	Epididymitis and varicocele (Grade III, n=125)	P
Semen volume (ml), median (interquartile)	2.4 (1.3–3.5)	2.2 (1.0–3.3)	2.4 (1.4–3.4)		2.5 (1.1–3.6)		2.4 (1.7–3.8)	
<2.0, n (%)	264 (40.5)	77 (45.8)	99 (39.1)	0.172	42 (39.6)	0.312	46 (36.8)	0.121
≥2.0, n (%)	388 (59.5)	91 (54.2)	154 (60.9)		64 (60.4)		79 (63.2)	
Sperm concentration (×10 ⁶ ml ⁻¹), median (interquartile)	22.8 (3.1–57.8)	27.1 (1.4–74.8)	25.8 (5.3–67.6)		12.1 (1.6–35.0)		18.0 (4.7–39.1)	
<2.0, n (%)	307 (47.1)	76 (45.2)	104 (41.1)	0.401	62 (58.5)	0.033	65 (52.0)	0.252
≥2.0, n (%)	345 (52.9)	92 (54.8)	149 (58.9)		44 (41.5)		60 (48.0)	
Sperm output (×10 ⁶), median (interquartile)	53.6 (7.9–148)	69.8 (2.2–181)	63.1 (10.5–168)		29.0 (5.3–79.0)		44.6 (14.1–93.6)	
<40, n (%)	366 (56.1)	94 (56.0)	158 (62.5)	0.183	48 (45.3)	0.085	66 (52.8)	0.592
≥40, n (%)	286 (43.9)	74 (44.0)	95 (37.5)		58 (54.7)		59 (47.2)	
Sperm motility (%), median (interquartile)	44.0 (28.0–57.5)	51.0 (16.5–61.3)	44.5 (29.8–58.0)		44.0 (32.0–56.0)		39.5 (27.3–59.6)	
<50, n (%)	280 (42.9)	87 (51.8)	106 (41.9)	0.046	42 (39.6)	0.049	45 (36.0)	0.007
≥50, n (%)	372 (57.1)	81 (48.2)	147 (58.1)		64 (60.4)		80 (64.0)	
Sperm morphology (%), median (interquartile)	22.5 (11.0–37.5)	31.0 (11.5–39.0)	23.0 (12.5–37.5)		17.3 (9.0–32.5)		21.5 (11.0–33.1)	
<30, n (%)	258 (39.6)	87 (51.8)	104 (41.1)	0.031	30 (28.3)	<0.001	37 (29.6)	<0.001
≥30, n (%)	394 (60.4)	81 (48.2)	149 (58.9)		76 (71.7)		88 (70.4)	
WBCs (×10 ⁶ ml ⁻¹)*								
≤1, n (%)	440 (67.6)	140 (83.8)	121 (47.8)	<0.001	94 (88.7)	0.264	85 (68.0)	0.002
>1, n (%)	211 (32.4)	27 (16.2)	132 (52.2)		12 (11.3)		40 (32.0)	

P values were calculated using a two-sided Chi-squared test for the comparison of percentages. *One missing data in the Controls group. WBCs: white blood cells

Table 3: Adjusted odds ratios and 95% confidence intervals for the relationship between genital disorders and semen characteristics

Characteristics	Controls	Epididymitis	Varicocele (Grade III)	Epididymitis and varicocele (Grade III)
Patients with genital disorders, n (%)	168 (25.8)	253 (38.8)	106 (16.3)	125 (19.2)
Semen volume <2.0 ml, OR (95% CI)	1.0 (reference)	0.75 (0.50–1.11) ^a	0.77 (0.47–1.26) ^a	0.69 (0.43–1.11) ^a
Sperm concentration <20 × 10 ⁶ ml ⁻¹ , OR (95% CI)	1.0 (reference)	0.84 (0.57–1.25) ^a	1.82 (1.10–3.028) ^b	1.32 (0.83–2.10) ^a
Sperm output <40 × 10 ⁶ , OR (95% CI)	1.0 (reference)	0.76 (0.51–1.13) ^a	1.62 (1.00–2.67) ^b	1.14 (0.72–1.82) ^a
Sperm motility <50%, OR (95% CI)	1.0 (reference)	1.49 (1.00–2.20) ^a	1.69 (1.02–2.79) ^b	2.08 (1.28–3.38) ^b
Sperm morphology <30%, OR (95% CI)	1.0 (reference)	1.54 (1.04–2.29) ^a	2.74 (1.63–4.62) ^a	2.56 (1.57–4.17) ^a
WBCs >1 × 10 ⁶ ml ⁻¹ , OR (95% CI)	1.0 (reference)	5.65 (3.50–9.13) ^a	0.67 (0.32–1.39) ^a	2.45 (1.40–4.28) ^a

^aAdjusted for age; ^badjusted for age and type of sterility. CI: confidence interval; OR: odds ratio; WBCs: white blood cells

**Figure 1: Flow chart of the study population selection.**

≥1 × 10⁶ ml⁻¹ WBCs, <30% morphologically normal sperm cells, and <50% motile sperm cells. Men with isolated Grade III varicocele had a significantly higher risk of having <50% motile sperm cells

and <30% morphologically normal sperm cells and a sperm cell output of <40 × 10⁶. Finally, patients with both chronic epididymitis and Grade III varicocele had a significantly higher risk of having <50% motile sperm cells, <30% morphologically normal sperm cells, and a WBC count of ≥1 × 10⁶ ml⁻¹.

DISCUSSION

In this study, we investigated the semen profile of men with common genital disorders, such as chronic epididymitis and Grade III varicocele, initially revealed by physical examination of male partners from couples having their first infertility consultation.

Palpation of extratesticular excurrent ducts, as well of the veins within the scrotum, may be difficult to interpret and lead to misclassification. However, all patients included in this study were examined by a single physician, thus eliminating interobserver variability. Direct ultrasound was also used when chronic epididymitis was uncertain, and color Doppler ultrasound was systematically used to confirm Grade III varicocele.

Here, we showed that isolated chronic epididymitis is associated with low sperm motility and a low percentage of morphologically

normal sperm cells, as well as an elevated number of WBCs. The presence of a high number ($>1 \times 10^6 \text{ ml}^{-1}$) of WBCs is not surprising, as it is a hallmark of inflammation of the extratesticular excurrent ducts.³¹ WBCs, particularly lymphoid cells, are activated by many chemical, physical, and biological stimuli. Such factors generate an inflammatory response and cellular reactions that induce the production of antigens, superoxides, complement proteins, neuropeptides, and lipoproteins, resulting in cell degranulation. After activation, inflammatory mediators are released into the semen, including histamine, and many cytokines and chemokines,^{32,33} which are possibly harmful for sperm cell function, inducing the alteration of sperm cell characteristics.^{34,35}

Isolated Grade III varicocele in our study population was associated with low sperm production and motility, as well as reduced percentage of morphologically normal sperm cells, without affecting the number of WBCs. Our observations are consistent with recent reports, showing that patients with Grade III varicocele have low semen quality.^{21,22} Various mechanisms have been hypothesized to be involved, such as high intrascrotal temperature, changes in testicular blood flow and venous pressure, reflux of renal or adrenal metabolic products, hormonal dysfunction, autoimmunity, defects in the acrosome reaction, and oxidative stress.¹³ Molecular and genetic studies have provided insights into the causes of low semen quality and altered sperm function in men with varicocele: elevated apoptosis among developing germ cells, which may give rise to low sperm production; high levels of reactive oxygen species, associated with reduced sperm motility; and high concentrations of toxic agents, such as cadmium, in seminal plasma, which may be involved in abnormal sperm morphology.³⁶

We identified a group of men who simultaneously presented chronic epididymitis and Grade III varicocele. It is not surprising that such diseases sometimes coexist, given the high frequency of both conditions in infertile men. This association has not been specifically reported and investigated until now, although two studies reported that Grade III varicocele affects the biological function of the epididymis by lowering α -glucosidase (specific epididymis-derived protein) in addition to testicular impairment.^{37,38} These patients combined low sperm cell motility and a high frequency of sperm cells with abnormal morphology,^{37,38} as observed in patients with isolated Grade III varicocele, with a high number of WBCs,³⁷ as observed in patients with isolated chronic epididymitis. Although alterations in sperm concentration and production were not always statistically significant, this group of patients tends to present the worst semen analysis profile.

By carrying out a physical examination, including visual inspection and palpation of the external male genital organs, we confirmed that chronic epididymitis and Grade III varicocele are common potential etiological factors in male patients consulting for couple infertility. We have shown that these disorders are associated with specific and different semen characteristics depending on whether they are observed in isolation or together relative to patients who do not present these conditions. New studies taking into account the diversity of localization of epididymal lesions combined with the assay of biological markers of epididymal function will be necessary to improve our knowledge on the negative effects on semen characteristics of varicocele and epididymal changes.

Combining a careful physical examination for these etiological factors with a semen analysis would help orientate the practitioner to the best treatment from the available therapeutic options, their effectiveness and safety, and their compatibility with natural conception. This may be particularly important in those countries where a significant proportion of infertile couples cannot access specialized clinics or advanced reproductive technologies for cost reasons.

A variety of drug treatments (e.g., antioxidants, mast cell stabilizers, and nonsteroidal anti-inflammatory agents) have been proposed for patients with a high WBC count, resulting in fewer WBCs and improvement of sperm characteristics.^{39,40} In addition to surgery,³⁷ antioxidants and drugs that act on testicular vascularization have been proposed for varicocele to improve sperm characteristics.^{41–44} In the future, it may be beneficial to explore these drug treatment options in situations where Grade III varicocele is associated with epididymitis. In all cases, it is up to the practitioner to decide, considering the effectiveness and safety of the treatment, as well the patient's wishes.

AUTHOR CONTRIBUTIONS

AO and LM conceived the study design, interpreted the results, were involved in writing the manuscript, and approved the final submitted version. AO acquired clinical and semen data. LM analyzed the data and wrote the first draft of the manuscript. Both authors read and approved the final manuscript.

COMPETING INTERESTS

Both authors declare no competing interests.

REFERENCES

- Mosher WD, Pratt WF. Fecundity and infertility in the United States: incidence and trends. *Fertil Steril* 1991; 56: 192–3.
- Thonneau P, Marchand S, Tallec A, Ferial ML, Ducot B, *et al.* Incidence and main causes of infertility in a resident population (1,850,000) of three French regions (1988–1989). *Hum Reprod* 1991; 6: 811–6.
- ESHRE Capri Workshop Group. A prognosis-based approach to infertility: understanding the role of time. *Hum Reprod* 2015; 30: 2243–8.
- Björndahl L. What is normal semen quality? On the use and abuse of reference limits for the interpretation of semen analysis results. *Hum Fertil (Camb)* 2011; 14: 179–86.
- Wang C, Swerdloff RS. Limitations of semen analysis as a test of male fertility and anticipated needs from newer tests. *Fertil Steril* 2014; 102: 1502–7.
- Dadhich P, Ramasamy R, Lipshultz LI. The male infertility office visit. *Minerva Urol Nefrol* 2015; 67: 157–68.
- Nieschlag E. Classification of andrological disorders. In: Nieschlag E, Behre HM, editors. *Andrology: Male Reproductive Health and Dysfunction*. 2nd Edition. Berlin Heidelberg: Springer-Verlag; 2001. p83–7.
- Behre HM, Yeung CH, Holstein AF, Weinbauer GF, Gassner P, *et al.* Diagnosis of male infertility and hypogonadism. In: Nieschlag E, Behre HM, editors. *Andrology: Male Reproductive Health and Dysfunction*. Berlin Heidelberg: Springer-Verlag; 2001. p. 89–124.
- Schuppe HC, Pilatz A, Hossain H, Meinhardt A, Bergmann M, *et al.* [Orchitis and male infertility]. *Urologe A* 2010; 49: 629–35. [Article in German].
- Nickel JC. Chronic epididymitis: a practical approach to understanding and managing a difficult urologic enigma. *Rev Urol* 2003; 5: 209–15.
- Awojobi OA, Nkposong EO, Lawani J. Aetiologic factors of male infertility in Ibadan, Nigeria. *Afr J Med Med Sci* 1983; 12: 91–4.
- Kopa Z, Wenzel J, Papp GK, Haidl G. Role of granulocyte elastase and interleukin-6 in the diagnosis on sperm function. *Andrologia* 2005; 30: 73–80.
- Jarow JP. Effects of varicocele on male fertility. *Hum Reprod Update* 2001; 7: 59–64.
- Gorelick JJ, Goldstein M. Loss of fertility in men with varicocele. *Fertil Steril* 1993; 59: 613–6.
- Haidl G, Allam JP, Schuppe HC. Chronic epididymitis: impact on semen parameters and therapeutic options. *Andrologia* 2008; 40: 92–6.
- Chan PT, Schlegel PN. Inflammatory conditions of the male excurrent ductal system. Part I. *J Androl* 2002; 23: 453–60.
- Rusz A, Pilatz A, Wagenlehner F, Linn T, Diemer T, *et al.* Influence of urogenital infections and inflammation on semen quality and male fertility. *World J Urol* 2012; 30: 23–30.
- Wolff H. The biologic significance of white blood cells in semen. *Fertil Steril* 1995; 63: 1143–57.
- Schoor RA, Elhanbly SM, Niederberger C. The pathophysiology of varicocele-associated male infertility. *Curr Urol Rep* 2001; 2: 432–6.
- De Schepper A. Nutcracker' phenomenon of the renal vein and venous pathology of the left kidney. *J Belge Radiol* 1972; 55: 507–11.
- Naughton CK, Nangia AK, Agarwal A. Varicocele and male infertility. Part II. Pathophysiology of varicoceles in male infertility. *Hum Reprod Update* 2001; 7: 473–81.
- Al-Ali BM, Marszalek M, Shamloul R, Pummer K, Trummer H. Clinical parameters and semen analysis in 716 Austrian patients with varicocele. *Urology* 2010; 75: 1069–73.

- 23 Al-Ali BM, Shamloul R, Pichler M, Augustin H, Pummer K. Clinical and laboratory profiles of a large cohort of patients with different grades of varicocele. *Cent European J Urol* 2013; 66: 71–4.
- 24 Lotti F, Maggi M. Ultrasound of the male genital tract in relation to male reproductive health. *Hum Reprod Update* 2015; 21: 56–83.
- 25 Behre HM, Kliesch S, Schädel F, Nieschlag E. Clinical relevance of scrotal and transrectal ultrasonography in andrological patients. *Int J Androl* 1995; 18 Suppl 2: 27–31.
- 26 Jungwirth A, Giwercman A, Tournaye H, Diemer T, Kopa Z, *et al.* European Association of Urology guidelines on Male Infertility: the 2012 update. *Eur Urol* 2012; 62: 324–32.
- 27 World Health Organization. WHO Laboratory Manual for the Examination of Human Semen and Semen-Cervical Mucus Interaction. Cambridge: Cambridge University Press; 1992.
- 28 Chan PT, Schlegel PN. Inflammatory conditions of the male excurrent ductal system. Part II. *J Androl* 2002; 23: 461–9.
- 29 Wilson SR, Katz DS. Computed tomography demonstration of epididymitis with extension to vas deferens. *Urology* 2006; 68: 1339–40.
- 30 Greenland S, Rothman KJ, editors. Introduction to stratified analysis. Modern Epidemiology. Philadelphia: Lippincott-Raven; 1998. p. 253–79.
- 31 Anderson DJ. Cell-mediated immunity and inflammatory processes in male infertility. *Arch Immunol Ther Exp (Warsz)* 1990; 38: 79–86.
- 32 Maegawa M, Kamada M, Irahara M, Yamamoto S, Yoshikawa S, *et al.* A repertoire of cytokines in human seminal plasma. *J Reprod Immunol* 2002; 54: 33–42.
- 33 Sanocka D, Jedrzejczak P, Szumata-Kaekol A, Fraczek M, Kurpisz M. Male genital tract inflammation: the role of selected interleukins in regulation of pro-oxidant and antioxidant enzymatic substances in seminal plasma. *J Androl* 2003; 24: 448–55.
- 34 Sharma RK, Pasqualotto AE, Nelson DR, Thomas AJ Jr., Agarwal A. Relationship between seminal white blood cell counts and oxidative stress in men treated at an infertility clinic. *J Androl* 2001; 22: 575–83.
- 35 Whittington K, Ford WC. Relative contribution of leukocytes and of spermatozoa to reactive oxygen species production in human sperm suspensions. *Int J Androl* 1999; 22: 229–35.
- 36 Marmar JL. The pathophysiology of varicoceles in the light of current molecular and genetic information. *Hum Reprod Update* 2001; 5: 461–72.
- 37 Lehtihet M, Arver S, Kalin B, Kvist U, Pousette A. Left-sided grade 3 varicocele may affect the biological function of the epididymis. *Scand J Urol* 2014; 48: 284–9.
- 38 Vivas-Acevedo G, Lozano-Hernández R, Camejo MI. Varicocele decreases epididymal neutral α -glucosidase and is associated with alteration of nuclear DNA and plasma membrane in spermatozoa. *BJU Int* 2014; 113: 642–9.
- 39 Saharkhiz N, Nikbakht R, Hemadi M. Ketotifen, a mast cell blocker improves sperm motility in asthenospermic infertile men. *J Hum Reprod Sci* 2013; 1: 19–22.
- 40 Oliva A, Multigner L. Ketotifen improves sperm motility and sperm morphology in male patients with leukocytospermia and unexplained infertility. *Fertil Steril* 2006; 85: 240–3.
- 41 Cavallini G, Biagiotti G, Ferraretti AP, Gianaroli L, Vitali G. Medical therapy of oligoasthenospermia associated with left varicocele. *BJU Int* 2003; 91: 513–8.
- 42 Cavallini G, Ferraretti AP, Gianaroli L, Biagiotti G, Vitali G. Cinnocicam and L-carnitine/acetyl-L-carnitine treatment for idiopathic and varicocele-associated oligoasthenospermia. *J Androl* 2004; 25: 761–70.
- 43 Azadi L, Abbasi H, Deemeh MR, Tavalae M, Arbabian M, *et al.* Zaditen (Ketotifen), as mast cell blocker, improves sperm quality, chromatin integrity and pregnancy rate after varicocelectomy. *Int J Androl* 2011; 34: 446–52.
- 44 Oliva A, Dotta A, Multigner L. Pentoxifylline and antioxidants improve sperm quality in male patients with varicocele. *Fertil Steril* 2009; 91: 1536–9.

This is an open access journal, and articles are distributed under the terms of the Creative Commons Attribution-NonCommercial-ShareAlike 4.0 License, which allows others to remix, tweak, and build upon the work non-commercially, as long as appropriate credit is given and the new creations are licensed under the identical terms.

©The Author(s)(2018)