

[CASE REPORT]

Thiamine Deficiency in a Nondrinker and Secondary Pulmonary Edema after Thiamine Replenishment

Hiroyuki Nakamura, Ayano Utsunomiya, Yuriko Ishida and Tetsuya Horita

Abstract:

A 48-year-old man was brought to our emergency room with acute abdominal pain and systemic edema, indicating acute circulatory failure with lactic acidosis. Furosemide treatment paradoxically worsened the systemic edema and induced confusion. He had no drinking history but hardly ate legumes or meats containing thiamine. Administration of fursultiamine dramatically improved the symptoms and subsequently caused pulmonary edema. Thiamine deficiency may occur in nondrinkers with an unbalanced diet. In this condition, diuretic therapy can worsen the symptoms before thiamine supplementation by promoting the flushing of water-soluble vitamins but is needed for the management of secondary pulmonary edema after thiamine replenishment.

Key words: thiamine, heart failure, lactic acidosis, edema, abdominal pain, beriberi

(Intern Med 59: 373-376, 2020)

(DOI: 10.2169/internalmedicine.3585-19)

Introduction

Thiamine (vitamin B1) is an essential cofactor of the key enzymes in aerobic glucose metabolism. Its deficiency damages neurons, which depend on aerobic metabolism, and causes loss of tendon reflexes and mental confusion (1). Autonomic dysfunction leads to high-output heart failure by impairing vasoconstriction, and anaerobic metabolism causes the accumulation of lactate in tissues (2). Since thiamine deficiency can be life-threatening due to central nervous disorders, heart failure and/or lactic acidosis, its early diagnosis and treatment with thiamine injection are mandatory (3). Thiamine deficiency has been considered to occur in heavy drinkers (4), although it can develop in nondrinkers with an unbalanced diet. Medical awareness of the clinical presentations and treatment strategies of this life-threatening condition are needed for it to be considered in the differential diagnosis and for the early treatment of affected patients.

Case Report

A 48-year-old man was brought to our emergency room by ambulance complaining of acute abdominal pain and sys-

temic edema. He had been aware of systemic edema and weight gain for several months. He had neither a remarkable medical history nor any drinking history. He also denied tobacco and illicit drug use.

On arrival, his vital signs were remarkable for a low blood pressure of 76/27 mmHg, sinus tachycardia of 110 beats per minute, a respiratory rate of 24 per minute and a 94% oxygen saturation on room air. His body temperature was 35.9 °C with cold sweat. A physical examination revealed diffuse abdominal distension with tenderness generalized throughout the abdomen. Pitting edema was found in his limbs. Cardiac auscultation did not reveal accessory heart sounds or murmurs, and the lung fields were clear. The results of a complete blood cell count were normal, and the C-reactive protein level was within the normal range. The following myogenic enzymes were elevated: aspartate aminotransferase, 336 IU/L (normal: <40 IU/L); alanine aminotransferase, 153 IU/L (normal: <40 IU/L); lactate dehydrogenase, 744 IU/L (normal: <250 IU/L); creatinine kinase, 1,930 IU/L (normal: <270 IU/L). Both serum creatinine and urea nitrogen levels were also elevated to 2.18 mg/dL (normal: <1.10 mg/dL) and 68.3 mg/dL (normal: <21.0 mg/dL), respectively, whereas the results of a urinalysis were normal. The plasma brain natriuretic peptide level was

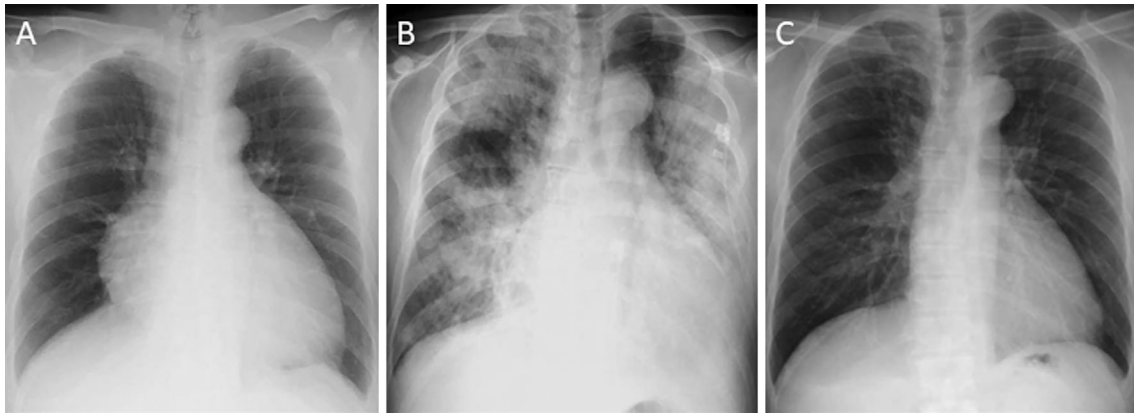


Figure 1. Chest X-ray findings on (A) days 1, (B) 12 and (C) 21.

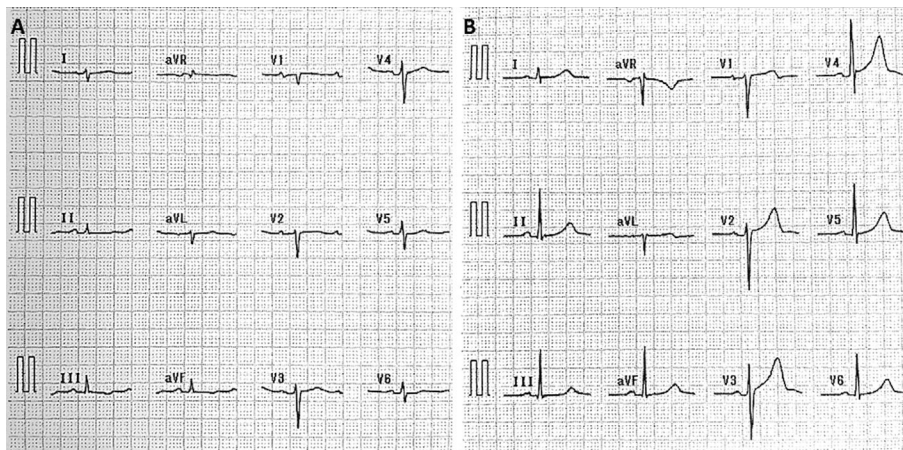


Figure 2. Electrocardiograms on (A) days 1 and (B) 21.

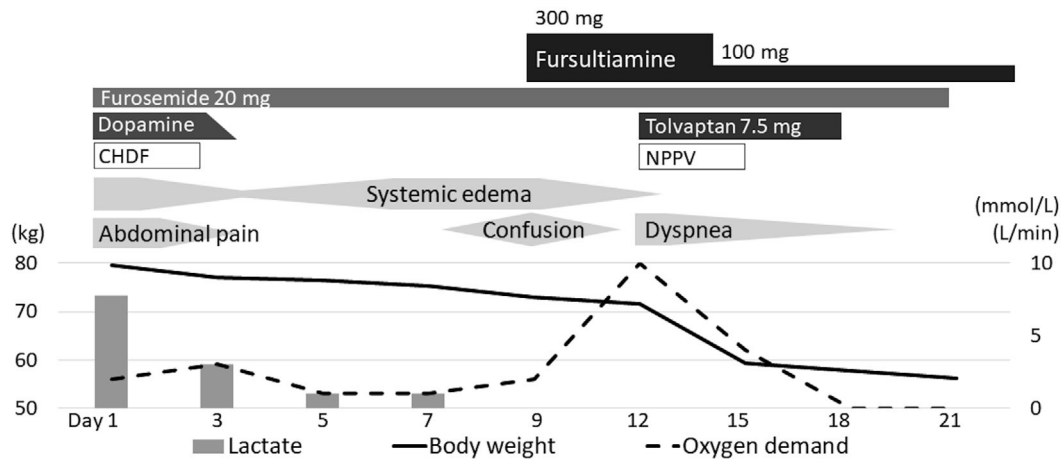
remarkably increased to 3,100 pg/mL (normal: <18 pg/mL). An arterial blood gas analysis revealed lactic acidosis [pH: 7.26, partial pressure of carbon dioxide in arterial blood (PaCO₂): 8.3 mmHg, HCO₃⁻: 3.7 mmol/L and lactate: 7.8 mmol/L]. These findings indicated acute circulatory failure. The cardiac wall motion, ejection fraction (EF: 60%) and ratio of the early to late ventricular filling velocities (E/A: 1.0) were normal, although the echocardiographic cardiac output (CO: 8.3 L/min) and tricuspid regurgitation peak gradient (TRPG: 40 mmHg) were slightly elevated. Chest X-ray showed an enlarged cardiac silhouette, especially the right atrium (Fig. 1A). An electrocardiogram showed right axis deviation and flat t-waves (Fig. 2A). Contrast-enhanced computed tomography displayed no apparent causes for the acute abdominal pain.

Dopamine and rehydration were started to normalize his blood pressure, and continuous hemodiafiltration (CHDF) was performed to correct his lactic acidosis. The abdominal pain disappeared along with the correction of lactic acidosis, and systemic edema decreased through CHDF. However, systemic edema worsened again despite intravenous furosemide 20 mg/day after stopping CHDF. He presented signs of confusion on day 9 of hospitalization. Neurological examinations revealed loss of the patellar and achilles tendon reflexes.

Thiamine deficiency was suspected based on the combination of the following clinical symptoms: neurological disorder, high-output heart failure and lactic acidosis. Intravenous injection of fursultiamine 300 mg immediately improved his confusion and dramatically decreased the systemic edema. However, the patient developed dyspnea on day 12, requiring treatment with noninvasive positive-pressure ventilation. Chest X-ray showed pulmonary edema (Fig. 1B). Echocardiographic CO was normalized (4.7 L/min), whereas the EF decreased to 40%. E/A and TRPG were elevated to 1.7 and 72 mmHg, respectively. Diuretics (furosemide 20 mg/day and tolvaptan 7.5 mg/day) concomitantly with thiamine administration ameliorated his dyspnea and improved his chest X-ray (Fig. 1C), electrocardiogram (Fig. 2B) and echocardiography findings (Fig. 3). The patient was discharged from the hospital on day 28 and has been maintained with oral thiamine supplement.

Discussion

Thiamine deficiency, despite being a relatively rare condition, is easily misdiagnosed in critically ill patients. This medical situation can present with high-output heart failure, an unusual condition that remains poorly recognized (2), and is characterized by an increase in CO to compensate for



	Day 1	Day 12	Day 21	
Ejection fraction	60	40	60	(%)
Cardiac output	8.3	4.7	4.0	(L/min)
E/A	1.0	1.7	0.7	
TRPG	40	72	28	(mmHg)

Figure 3. Clinical course and echocardiography findings. CHDF: continuous hemodiafiltration, E/A: ratio of the early (E) to late (A) ventricular filling velocities, NPPV: noninvasive positive-pressure ventilation, TRPG: tricuspid regurgitation peak gradient

the decreased systemic vascular resistance, as well as mild to moderate pulmonary hypertension, reflecting hyperhemodynamics (5-7). A lack of thiamine increases lactic acid production by altering the aerobic metabolism. Lactic acidosis often presents with gastrointestinal symptoms, such as abdominal pain, nausea and vomiting (8). Clinicians should therefore suspect thiamine deficiency in critically ill patients with unexplained systemic edema and gastrointestinal symptoms.

Thiamine is a vitamin included in whole grains, legumes and some meats and is prone to deficiencies in Asian people who regularly eat refined rice. Since relatively little thiamine is stored in the body, and given its short half-life, thiamine must be ingested daily. Drinking alcohol interferes with thiamine absorption, and diuretics promote the flushing of this water-soluble vitamin (4). However, thiamine deficiency can occur even in nondrinkers with inadequate nutrition or habitual users of diuretics (9). While the present patient was a nondrinker, he subsisted on refined rice and hardly ate legumes or meat for many years due to a poor living condition subsequent to his lack of regular employment. The administration of furosemide before supplementation of thiamine in this patient paradoxically aggravated the systemic edema and resulted in the development of confusion.

Thiamine deficiency is diagnosed according to the unique clinical symptoms and the dramatic improvement of the symptoms after the administration of thiamine (10). The blood thiamine level could not be measured in the present patient. However, thiamine deficiency cannot be denied based simply on blood thiamine levels, as thiamine is widely distributed in tissues (11). Furthermore, blood thia-

mine levels cannot be determined instantly in the emergency room. Thiamine should thus be empirically administered to all patients suspected of thiamine deficiency. High-dose thiamine administered at a dose of 100-300 mg/day is needed to cure patients with critical thiamine deficiency due to their impaired thiamine utilization (12). The effect of thiamine administration is quick, generally manifesting within 24 hours of dosing (13).

In the present patient, pulmonary edema occurred after the replenishment of thiamine followed by a dramatic improvement in the systemic edema. This occurred because the normalization of vasoconstriction rapidly increased the systemic vascular resistance (cardiac afterload) and venous return (cardiac preload), ultimately leading to congestive heart failure (14). We should be alert for the potential development of secondary pulmonary edema during the treatment of patients with thiamine deficiency (15). In our case, the pulmonary edema was successfully treated by diuretics concomitantly with thiamine. In patients with thiamine deficiency, diuretics can worsen the symptoms before the supplementation of thiamine; however, they should still be used concomitantly with thiamine in order to prevent secondary pulmonary edema after thiamine replenishment.

The authors state that they have no Conflict of Interest (COI).

Acknowledgement

We would like to express our deepest appreciation to Dr. Olga Amengual for helping with the English proofreading.

References

1. Sechi G, Serra A. Wernicke's encephalopathy: new clinical settings and recent advances in diagnosis and management. *Lancet Neurol* **6**: 442-455, 2007.
2. Anand IS, Florea VG. High output cardiac failure. *Curr Treat Options Cardiovasc Med* **3**: 151-159, 2001.
3. Imamura T, Kinugawa K. Shoshin beriberi with low cardiac output and hemodynamic deterioration treated dramatically by thiamine administration. *Int Heart J* **56**: 568-570, 2015.
4. Lei Y, Zheng MH, Huang W, et al. Wet beriberi with multiple organ failure remarkably reversed by thiamine administration: a case report and literature review. *Medicine (Baltimore)* **97**: e0010, 2018.
5. Attas M, Hanley HG, Stultz D, et al. Fulminant beriberi heart disease with lactic acidosis: presentation of a case with evaluation of left ventricular function and review of pathophysiologic mechanisms. *Circulation* **58**: 566-572, 1978.
6. Yamamura M, Murai H, Kaneko S, et al. Case report: pericardial effusion with constrictive physiology in a patient with wet beriberi. *Nutr J* **15**: 37, 2016.
7. Park JH, Lee JH, Jeong JO, et al. Thiamine deficiency as a rare cause of reversible severe pulmonary hypertension. *Int J Cardiol* **121**: e1-e3, 2007.
8. Donnino M. Gastrointestinal beriberi: a previously unrecognized syndrome. *Ann Intern Med* **141**: 898-899, 2004.
9. Misumida N, Umeda H, Iwase M. Shoshin beriberi induced by long-term administration of diuretics: a case report. *Case Rep Cardiol* **2014**: 878915, 2014.
10. Wakabayashi A, Yui Y, Kawai C. A clinical study on thiamine deficiency. *Jpn Circ J* **43**: 995-999, 1979 (in Japanese).
11. Pearson WN. Blood and urinary vitamin levels as potential indices of body stores. *Am J Clin Nutr* **20**: 514-527, 1967.
12. Yoshinaga M, Hayashi M, Yokoi H, et al. The case that developed marked anasarca with a disturbance of consciousness induced by beriberi heart due to the vitamin B1 use disorder. *Shinzou* **47**: 1213-1218, 2015 (in Japanese).
13. Galvin R, Brathen G, Ivashynka A, et al. EFNS guidelines for diagnosis, therapy and prevention of Wernicke encephalopathy. *Eur J Neurol* **17**: 1408-1418, 2010.
14. Betrosian AP, Thireos E, Toutouzas K, et al. Occidental beriberi and sudden death. *Am J Med Sci* **327**: 250-252, 2004.
15. Givertz MM, Colucci WS, Braunwald E. Clinical aspects of heart failure: high-output heart failure: pulmonary edema. In: *Heart Disease*. 6th ed. Braunwald E, Ed. Saunders, Philadelphia, 2001: 534-561.

The Internal Medicine is an Open Access journal distributed under the Creative Commons Attribution-NonCommercial-NoDerivatives 4.0 International License. To view the details of this license, please visit (<https://creativecommons.org/licenses/by-nc-nd/4.0/>).