

João Francisco Martins¹, Luis Rito Cruz²,
Daniela Jardim Pereira², Jose Eduardo Sousa¹,
Paulo Martins¹

Posterior reversible encephalopathy syndrome in a patient submitted to extracorporeal membrane oxygenation for COVID-19

Síndrome da encefalopatia posterior reversível em paciente com COVID-19 submetida à oxigenação por membrana extracorpórea

1. Intensive Medicine Service, Centro Hospitalar e
Universitário de Coimbra - Coimbra, Portugal.

2. Medical Imaging Service, Centro Hospitalar e
Universitário de Coimbra - Coimbra, Portugal.

ABSTRACT

A 63-year-old woman presented to the emergency department with an acute history of fever, prostration and dyspnea. She was diagnosed with severe COVID-19 acute respiratory distress syndrome and, despite optimized critical care support, met the indications for veno-venous extracorporeal membrane oxygenation. On day 34, after 7 days of wean sedation with a positive evolution of neurologic status, she presented a limited generalized tonic-clonic seizure

not related to hydroelectrolytic or metabolic imbalance, which led to a diagnostic investigation; her brain imaging tests showed a posterior reversible encephalopathy syndrome. This case emphasizes the issue of neurological complications in patients with severe COVID-19 infection and the importance of early diagnosis and support.

Keywords: Neurologic manifestations; Brain diseases; Coronavirus infections; COVID-19; Acute distress syndrome; Extracorporeal membrane oxygenation

INTRODUCTION

Coronavirus disease 2019 (COVID-19) is a rapidly evolving pandemic that emerged in Wuhan, China, and so far, no specific treatment has been considered effective except supportive care.⁽¹⁾ The Extracorporeal Life Support Organization (ELSO) guidelines for extracorporeal membrane oxygenation (ECMO) in COVID-19 patients recommend administering veno-venous extracorporeal membrane oxygenation (VV-ECMO) for the treatment of COVID-19-related acute respiratory distress syndrome (ARDS) in expert centers.⁽²⁾

Neurologic complications are becoming increasingly recognized in patients with severe COVID-19 infections.⁽³⁾ The most common neurologic symptoms include headache, anosmia, and ageusia. Other findings include stroke, impairment of consciousness, coma, seizure and encephalopathy.⁽⁴⁾ Damage within the central nervous system might be caused directly by the virus or by the body's innate and adaptive immune responses to infection. We describe one patient with severe COVID-19 ARDS who underwent VV-ECMO in whom brain imaging showed posterior reversible encephalopathy syndrome (PRES).

CASE REPORT

A 63-year-old woman with a past medical history of obesity and arterial hypertension presented to the emergency department of a secondary hospital with a 7-day history of fever, dry cough, hyposmia and myalgia.

Conflicts of interest: None.

Submitted on March 19, 2021

Accepted on May 30, 2021

Corresponding author:

João Francisco Martins
Serviço de Medicina Intensiva
Centro Hospitalar Universitário de Coimbra
Praceta Prof. Mota Pinto, 3000-075
Coimbra, Portugal
E-mail: joaofranciscomid@gmail.com

Responsible editor: Viviane Cordeiro Veiga

DOI: 10.5935/0103-507X.20210067



At admission, she was alert with a respiratory rate of 22 cycles per minute, pulse rate of 90 beats per minute, and oxygen saturation of 90%. Laboratory tests revealed lymphopenia (1.55×10^9) and elevated C-reactive protein (10.62mg/dL). COVID-19 testing was performed by nasopharyngeal and throat swabs and was positive for severe acute respiratory syndrome coronavirus 2 (SARS-CoV-2) by polymerase chain reaction.

The situation rapidly evolved, with fever, prostration and worsening dyspnea. Arterial blood gas analysis showed severe respiratory failure, and chest X-ray evidenced diffuse bilateral pulmonary infiltrates. She was intubated and mechanically ventilated, but her respiratory status continued to deteriorate despite optimized critical care, including prone positioning ventilation and neuromuscular blockade. Her chest computed tomography scan after intubation revealed extensive multifocal ground-glass opacities bilaterally, without any pulmonary embolism. The initial ventilator settings were volume-controlled ventilation with a tidal volume of 360mL (6mL/kg of ideal body weight), respiratory rate of 14 breaths per minute, positive end-expiratory pressure (PEEP) of 14 cmH₂O and static compliance 44cmH₂O.

On the second day of admission, arterial blood gas revealed a pH of 7.34, partial pressure of carbon dioxide (PaCO₂) of 53mmHg, partial pressure of oxygen (PaO₂) of 102mmHg and bicarbonate (HCO₃) of 29.7mmol/L, with a partial pressure of oxygen/fraction of inspired oxygen (PaO₂/FiO₂) ratio of 98. She met the indications for VV-ECMO and was transferred to our intensive care unit (ICU), which has an established VV-ECMO program. The procedure was performed safely, and no complications occurred. Arterial blood gas analysis 3 hours after beginning VV-ECMO showed a pH of 7.386, PaCO₂ of 43mmHg, PaO₂ of 94.3mmHg, and HCO₃ of 25.4mmol/L, with no abrupt variation in PaCO₂. Early nutrition and rehabilitation were begun after VV-ECMO introduction.

On day 14 of admission, the patient developed ventilator-associated pneumonia due to *Pseudomonas aeruginosa* and had completed 7 days of antibiotic therapy with ceftazidime and vancomycin with a favorable response. On day 20 of admission, her chest radiography and lung compliance improved, and she was successfully decannulated after 455 hours of VV-ECMO support and was tracheostomized 7 days later. The patient maintained good renal function throughout her hospitalization.

On day 34 of admission, after 7 days of sedation weaning with a positive evolution of her neurologic status, a limited generalized tonic-clonic seizure led to a diagnostic investigation.

Investigation

Blood tests revealed decreasing C-reactive protein (6.11mg/dL), procalcitonin (0.07ng/mL), fibrinogen (307ng/mL) and ferritin levels (2,802ng/mL) but increasing levels of D-dimer (18,021ng/mL) and interleukin 6 (10.4pg/mL) on the day before the development of symptoms. None of the drugs administered to the patient were associated with PRES, namely, immunosuppressive, immunomodulating and chemotherapeutic drugs.

A brain magnetic resonance imaging (MRI) scan was performed, and fluid-attenuated inversion recovery (FLAIR) images demonstrated symmetric and confluent hyperintensity affecting the juxtacortical and subcortical white matter, affecting primarily her occipital and parietal regions but also her frontal, temporal and left cerebellar hemispheres. The deep gray nuclei were spared, and no area of restricted diffusion or contrast enhancement was present. Susceptibility-weighted imaging showed multiple punctate microhemorrhages affecting superficial and deep white matter but relatively sparing the area of FLAIR hyperintensity. Punctate microhemorrhages predominantly involved the juxtacortical white matter and the corpus callosum (especially the genu and splenium). Additionally, there were three infracentimetric subacute hemorrhages in the external capsules, with T1 hyperintensity (Figure 1).

The cerebrospinal fluid specimen was negative for SARS-CoV-2 and showed protein (31mg/dL), glucose (74mg/dL) and lactate (1.89mmol/L) within normal limits.

Outcome

She had nearly recovered from the neurologic deficits despite critical-illness myopathy and was discharged after 44 days in the hospital to a secondary hospital's subacute rehabilitation facility, having nearly returned to her baseline mentation.

DISCUSSION

According to the interim guidance formulated by ELSO, ECMO should be considered a rescue therapy for COVID-19 with refractory hypoxemia and worsening hypercapnia despite optimized traditional therapies, in particular lung-protective ventilation, prone positioning and high PEEP.⁽²⁾

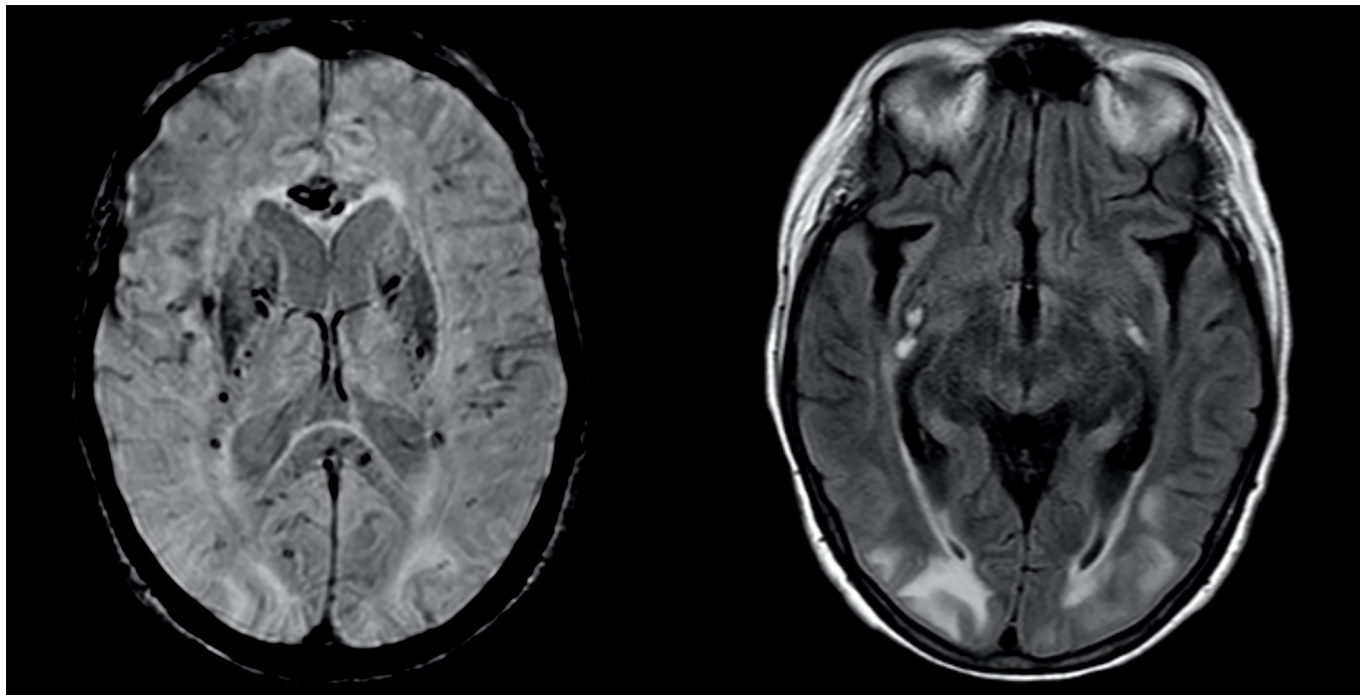


Figure 1 - Axial susceptibility-weighted images demonstrate numerous punctate microhemorrhagic foci within the deep and subcortical white matter, particularly in the internal capsule and within the corpus callosum.

Fluid-attenuated inversion recovery images show symmetric and confluent hyperintensity affecting the juxtacortical and subcortical white matter, primarily affecting occipital and parietal regions. There were three infracentimetric subacute hemorrhages in the external capsules, with fluid-attenuated inversion recovery and T1 hyperintensity.

Extracorporeal membrane oxygenation is being used as rescue therapy in patients with severe lung injury secondary to COVID-19, but it is associated with several complications, such as neurologic injuries, that can be a significant cause of morbidity and mortality. Although the most frequent neurological complications related to ECMO are intracerebral hemorrhage and ischemic stroke,⁽⁵⁾ to the best of our knowledge, this is the first report of patients with COVID-19 supported with ECMO who presented PRES.

In fact, the described MRI findings are highly suggestive of PRES and indicate dysfunction of the brain's vascular autoregulation and endothelial dysfunction. Although the patient also had a prolonged intubation period with fluctuating blood pressures, namely, mean arterial pressures between 95 and 130mmHg, endothelial dysfunction secondary to COVID-19 could also have contributed to the PRES. Cerebral blood flow and autoregulation can also

be affected during VV-ECMO, including abrupt PaO₂ and PaCO₂ changes on ECMO initiation.⁽⁶⁾ The presence of SARS-CoV-2 in slow-flowing cerebral microcirculation may facilitate the interaction of the virus spike protein with endothelial ACE2 receptors, initiating a cycle of viral budding, impairing autoregulation and increasing the risk of capillary rupture.⁽⁷⁾ Accordingly, white matter microhemorrhages might reinforce this process or, alternatively, might also be related to hypoxia, which is common in ECMO-treated patients, and translate into posthypoxic leukoencephalopathy.

CONCLUSION

Our patient recovered with medical management and nursing rehabilitation, in line with the favorable clinical results described in most cases of non-COVID-19 posterior reversible encephalopathy syndrome.

RESUMO

Uma mulher com 63 anos de idade compareceu ao pronto-socorro com história aguda de febre, prostração e dispnéia. Recebeu diagnóstico de quadro grave da

COVID-19 e síndrome do desconforto respiratório agudo. Apesar de suporte clínico intensivo, cumpriu os critérios para ser submetida à oxigenação venovenosa por membrana extracorpórea. No dia 34, após 7 dias de desmame da sedação com evolução positiva de seu

quadro neurológico, apresentou uma crise tônico-clônica generalizada limitada, não relacionada com desequilíbrio hidroeletrólítico ou metabólico, que levou à necessidade de investigação diagnóstica. Seus exames de imagem cerebral revelaram síndrome da encefalopatia posterior reversível.

Este caso enfatiza a questão das complicações neurológicas em pacientes com COVID-19 grave e a importância do diagnóstico e suporte precoces.

Descritores: Manifestações neurológicas; Encefalopatias; Infecções por coronavírus; COVID-19; Síndrome do desconforto respiratório agudo; Oxigenação por membrana extracorpórea

REFERENCES

1. National Institutes of Health. COVID-19 Treatment Guidelines. Coronavirus Disease 2019 (COVID-19) Treatment Guidelines. [cited 2020 Sep 23]. Available from: <https://www.covid19treatmentguidelines.nih.gov/>
2. Shekar K, Badulak J, Peek G, Boeken U, Dalton HJ, Arora L, Zakhary B, Ramanathan K, Starr J, Akkanti B, Antonini MV, Ogino MT, Raman L, Barret N, Brodie D, Combes A, Lorusso R, MacLaren G, Müller T, Paden M, Pellegrino V; ELSO Guideline Working Group. Extracorporeal Life Support Organization Coronavirus Disease 2019 Interim Guidelines: A Consensus Document from an International Group of Interdisciplinary Extracorporeal Membrane Oxygenation Providers. *ASAIO J.* 2020;66(7):707-21.
3. Ellul MA, Benjamin L, Singh B, Lant S, Michael BD, Easton A, et al. Neurological associations of COVID-19. *Lancet Neurol.* 2020;19(9):767-83.
4. Zubair AS, McAlpine LS, Gardin T, Farhadian S, Kuruvilla DE, Spudich S. Neuropathogenesis and neurologic manifestations of the coronaviruses in the age of coronavirus disease 2019: a review. *JAMA Neurol.* 2020;77(8):1018-27.
5. Nasr DM, Rabinstein AA. Neurologic complications of extracorporeal membrane oxygenation. *J Clin Neurol.* 2015;11(4):383-9.
6. Kazmi SO, Sivakumar S, Karakitsos D, Alharthy A, Lazaridis C. Cerebral pathophysiology in extracorporeal membrane oxygenation: pitfalls in daily clinical management. *Crit Care Res Pract.* 2018;2018:3237810.
7. Wu Y, Xu X, Chen Z, Duan J, Hashimoto K, Yang L, et al. Nervous system involvement after infection with COVID-19 and other coronaviruses. *Brain Behav Immun.* 2020;87:18-22.