



## Case report

## Solitary skull metastasis in presumed early stage cervical cancer

Brianne M. Morgan<sup>a,\*</sup>, Matthew Bierowski<sup>a</sup>, Amalia Brawley<sup>b</sup>, Ayodele G. Ayoola<sup>c</sup>,  
Joshua Kesterson<sup>b</sup>

<sup>a</sup> Penn State College of Medicine, 500 University Drive, Hershey, PA 17033, United States

<sup>b</sup> Department of Obstetrics and Gynecology, Penn State Health Milton S. Hershey Medical Center, 500 University Drive, Hershey, PA 17033, United States

<sup>c</sup> Department of Medicine, Penn State Health Milton S. Hershey Medical Center, 500 University Drive, Hershey, PA 17033, United States

## ARTICLE INFO

## Keywords

Cervical carcinoma

Skull metastasis

Denosumab

## 1. Background

Cervical cancer is the most common reproductive malignancy in women worldwide, causing 311,000 deaths in 2018 (Arbyn et al., 2020). Its pattern of spread is typically direct and/or contiguous invasion, thus the majority of women present with regional disease (Thanappapras et al., 2010). Isolated skull metastases are exceedingly rare in squamous cell carcinoma of the cervix, especially early stage (Zilberlicht et al., 2015; Diaz et al., 2019). Herein, we present a case of a woman with FIGO stage IB2 squamous cell carcinoma of the cervix who, after surgical resection and staging, presented with an isolated skull metastasis.

## 2. Case summary

This is a 56-year-old postmenopausal woman with no previous history of abnormal PAP smears who presented with vaginal bleeding and cervical cytology showing malignant cells of either squamous or glandular origin. This prompted further imaging, including MRI, which demonstrated a 4 × 4.5 cm cervical mass. The patient underwent a radical hysterectomy, bilateral salpingo-oophorectomy, and pelvic lymphadenectomy. Final pathology demonstrated a poorly differentiated squamous cell carcinoma with deep stromal invasion and lymphovascular space invasion. The surgical margins were negative and all pelvic lymph nodes were negative for malignancy, meeting classification as stage IB2. Based on this pathology, the patient met Sedlis criteria for external pelvic radiation following the hysterectomy with concurrent chemotherapy with a platinum-based agent. Her post-operative course was complicated by a pulmonary embolus which delayed port

placement for chemotherapy. Prior to initiation of chemotherapy and seven weeks following surgery, the patient was noted to have a palpable lesion on her forehead, which was painless, but visually distressing. Ultrasound confirmed a 3 cm mass of the frontal calvarium. Follow up CT demonstrated an enhancing soft tissue density with heterogeneous lucency measuring 12 × 7 mm and destruction of the underlying calvarium, consistent with an aggressive process (Fig. 1). Fine needle aspiration confirmed metastatic poorly differentiated carcinoma, consistent with metastases. Bone scan demonstrated no evidence of other bony metastatic disease.

Treatment began with six cycles of 175 mg/m<sup>2</sup> paclitaxel, 50 mg/m<sup>2</sup> cisplatin, and 50 mg/kg bevacizumab IV. After completion of chemotherapy regimen, chemoradiation and 12 cycles of monthly SubQ 120 mg denosumab were initiated. The patient underwent external beam radiation therapy (EBRT) consisting of 220 cGy/25Fx (5500 cGy total) to the pelvis and 300 cGy/10Fx (2700 cGy total) to the skull with concurrent weekly 40 mg/m<sup>2</sup> cisplatin. Only three out of seven cycles of cisplatin was given due to severe nausea, dehydration, and acute renal failure, requiring a hospital admission. Interstitial brachytherapy Ir-192 15 Gy/3Fx was completed following chemoradiation which was tolerated well. Skull metastasis persisted and a treatment plan of six cycles of 175 mg/m<sup>2</sup> paclitaxel, 50 mg/m<sup>2</sup> cisplatin, and 15 mg/kg bevacizumab IV was initiated. Due to persistent peripheral neuropathy, paclitaxel was reduced 50% by the second cycle and the entire regimen was discontinued before the third cycle. Maintenance 15 mg/kg bevacizumab was begun. Post-treatment PET CT showed no evidence of locally recurrent disease or metabolically active metastatic disease. Following therapy, the patient was doing well with no clinical evidence of disease

\* Corresponding author.

E-mail address: [bmorgan4@pennstatehealth.psu.edu](mailto:bmorgan4@pennstatehealth.psu.edu) (B.M. Morgan).

<https://doi.org/10.1016/j.gore.2021.100889>

Received 12 September 2021; Received in revised form 2 November 2021; Accepted 8 November 2021

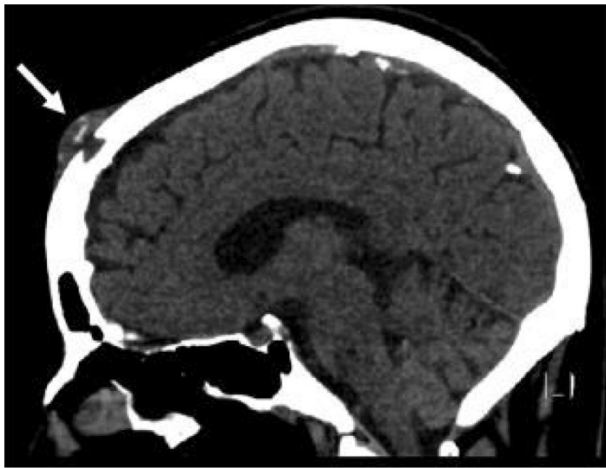
Available online 13 November 2021

2352-5789/© 2021 The Author(s).

Published by Elsevier Inc.

This is an open access article under the CC BY-NC-ND license

(<http://creativecommons.org/licenses/by-nc-nd/4.0/>).



**Fig. 1.** CT Brain/Head with contrast demonstrating an enhancing soft tissue density mass with destruction of underlying calvarium, measuring 12 × 7 mm (arrow).

and an excellent performance status. The patient is 8 months into remission, receiving PET CT every 3 months for restaging, and has completed 10/12 cycles of denosumab and 2/12 cycles of bevacizumab.

### 3. Discussion

Hematogenous spread of cervical cancer is usually an indicator of late stage disease with the liver, lung, and bones being the most frequent location of distant metastases (Thanappapras et al., 2010; Gardner et al., 2020; Agarwal et al., 2002). While there are case reports of isolated metastases to distant sites of the body from cervical cancer, isolated skull metastases are exceedingly rare with few published cases. Zilberlicht et al. (2015) reported a single skull metastasis in a 58-year-old woman with stage IIb cervical carcinoma. Diaz et al. (2019) reported a single skull metastasis in a 41-year old female 18 months after treatment for stage IIIB cervical cancer.

There are estimated to be around a dozen cases of skull metastasis from cervical cancer in the literature with the majority of these reports occurring in later stage disease, following the hypothesis of lymphatic spread prior to hematologic spread (Zilberlicht et al., 2015; Diaz et al., 2019). However, both Zilberlicht et al. (2015) and Diaz et al. (2019) demonstrate there are very rare cases in which hematological spread may occur concurrently. One current explanation is that local venous spread allows bloodstream seeding that transports the tumor to the external carotid artery (Agarwal et al., 2002). This case report further supports the possibility of early hematologic spread.

The most common presenting symptoms of a skull metastasis include a noticeable scalp mass, headache, and local bony tenderness (Zilberlicht et al., 2015). In this case, the patient presented with a skull mass only seven weeks following diagnosis of cervical carcinoma, which allowed for efficient diagnosis of the skull metastasis. However, given there are reports of isolated skull metastasis several years after remission, it is imperative that the physician maintains a high index of suspicion for metastatic disease for any patient with a past history of cervical carcinoma presenting with new onset head-related symptoms (Diaz et al., 2019; Baid et al., 1992).

This patient's systemic cytotoxic and radiation therapy was supplemented with denosumab due to its documented success in prolonging survival and preventing the progression of bone metastasis from primary squamous cell carcinomas (Gül et al., 2016; Scagliotti et al., 2012). Denosumab is a subcutaneous injected monoclonal antibody that binds to RANKL, blocking osteoclast maturation and function, therefore inhibiting bone resorption (Hanley et al., 2012). Denosumab reduces skeletal-related events in patients with solid tumors and bone

metastasis, Gül et al. (2016) and Scagliotti et al. (2012) found that it was associated with improved median survival in patients with squamous cell carcinoma of the lung with bone metastasis. Although there are no reports in the literature looking at the outcomes of using denosumab in patients with bone metastasis specifically from cervical cancer, van Dam et al. (2019) hypothesize that inhibition of RANK-RANKL interaction may not only be beneficial with bone metastasis, but also with disrupting cell-cell signaling of the primary cervical carcinoma. Citing prior experiments, they discuss how RANKL is directly secreted by cervical cells and may be used as a method by tumors to create an immune-suppressive environment, with its inhibition potentially reversing this effect (Demoulin et al., 2015). The role of RANKL signaling in cervical carcinoma progression is further supported by experiments demonstrating a positive correlation between RANKL mRNA levels and increasing tumor burden, lymph nodes metastasis, and clinical stage (Ma et al., 2017). The long-term success of this treatment regimen warrants further investigation.

In conclusion, patients with new onset headaches or bony skull protuberances with a history of cervical carcinoma should be evaluated for evidence of metastasis. Early hematologic spread is possible, as evidenced in this case with distal metastasis with no lymphatic involvement. In the case of bony metastasis from primary cervical carcinoma, providers should advise the addition of denosumab to treatment regimen as it may serve a bone-stabilizing and potential therapeutic effect.

### 4. Consent

Written informed consent was obtained from the patient for publication of this case report and accompanying images. A copy of the written consent is available for review by the Editor-in Chief of this journal upon request.

### Declaration of Competing Interest

The authors declare that they have no known competing financial interests or personal relationships that could have appeared to influence the work reported in this paper.

### References

- Agarwal, U., Dahiya, P., Chauhan, A., et al., 2002. Scalp metastasis in carcinoma of the uterine cervix – a rare entity. *Gynecol. Oncol.* 87 (3), 310–312. <https://doi.org/10.1006/gyno.2002.6829>.
- Arbyn, M., Weiderpass, E., Bruni, L., de Sanjosé, S., Saraiya, M., Ferlay, J., Bray, F., 2020. Estimates of incidence and mortality of cervical cancer in 2018: a worldwide analysis. *Lancet Glob. Health* 8 (2), e191–e203.
- Baid, B.L., Kumar, L., Chander, S., et al., 1992. Bone metastases in the patients of carcinoma cervix. *Indian J. Cancer* 29 (2), 71–75.
- Demoulin, S.A., et al., 2015. Cervical (pre)neoplastic microenvironment promotes the emergence of tolerogenic dendritic cells via RANKL secretion. *Oncoimmunology* 4 (6), e1008334. <https://doi.org/10.1080/2162402X.2015.1008334>.
- Diaz, J.F.R., Zelaya, A.H., Rosas, A.M.A., 2019. Scalp and skull bone metastasis in cervical carcinoma – a rare entity. *Eancer* 13, 969. <https://doi.org/10.3332/ecancer.2019.969>.
- Gardner, A.B., Charo, L.M., Mann, A.K., et al., 2020. Ovarian, uterine, and cervical cancer patients with distant metastases at diagnosis: most common locations and outcomes. *Clin. Exp. Metastasis* 37 (1), 107–113. <https://doi.org/10.1007/s10585-019-10007-0>.
- Gül, G., Sendur, M.A.N., Aksoy, S., et al., 2016. A comprehensive review of denosumab for bone metastasis in patients with solid tumors. *Curr. Med. Res. Opin.* 32 (1), 133–145.
- Hanley, D.A., Adachi, J.D., Bell, A., Brown, V., 2012. Denosumab: mechanism of action and clinical outcomes. *Int. J. Clin. Pract.* 66 (12), 1139–1146. <https://doi.org/10.1111/ijcp.12022>.
- Ma, D., et al., 2017. KLF5 promotes cervical cancer proliferation, migration and invasion in a manner partly dependent on TNFRSF11a expression. *Sci. Rep.* 7 (1) <https://doi.org/10.1038/s41598-017-15979-1>.
- Scagliotti, G.V., Hirsh, V., Siena, S., et al., 2012. Overall survival improvement in patients with lung cancer and bone metastases treated with denosumab versus zoledronic acid: subgroup analysis from a randomized phase 3 study. *J. Thorac. Oncol.* 7 (12), 1823–1829.

- Thanaprapasr, D., Nartthanarung, A., Likittanasombut, P., et al., 2010. Bone metastasis in cervical cancer patients over a 10-year period. *Int. J. Gynecol. Cancer* 20 (3), 373–378.
- van Dam, P.A., Verhoeven, Y., Jacobs, J., et al., 2019. RANK-RANKL signaling in cancer of the uterine cervix: A review. *Int. J. Mol. Sci.* 20 (9), 2183. <https://doi.org/10.3390/ijms20092183>.
- Zilberlicht, A., Voldavsky, E., Lavie, O., et al., 2015. Prolonged survival in a patient with isolated skull recurrence of cervical carcinoma – Case report and review of the literature. *Gynecol. Oncol. Rep.* 11, 20–22.