

CASE REPORT

Distal trisomy 10q syndrome, report of a patient with duplicated q24.31 – qter, autism spectrum disorder and unusual features

Yasser Al-Sarraj¹, Hakam Abu Al-Khair², Rowaida Ziad Taha¹, Namat Khattab¹, Zakaria H. El Sayed², Bushra Elhusein² & Hatem El-Shanti^{1,3}

¹Shafallah Medical Genetics Center, Doha, Qatar

²Shafallah Center for Children with Special Needs, Doha, Qatar

³ Carver College of Medicine, University of Iowa, Iowa City, Iowa

Correspondence

Hatem El-Shanti, Shafallah Medical Genetics Center, 69 Lusail Street, West Bay Area, P.O. Box: 33123, Doha, Qatar. Tel: +974-4495-6244; Fax: +974-4495-6223; E-mail: elshantih@smgc.org.qa

Funding Information

This study is funded by intramural funds from the Shafallah Center.

Received: 10 January 2014; Revised: 20 May 2014; Accepted: 24 May 2014

Clinical Case Reports 2014; 2(5): 201–205

doi: 10.1002/ccr3.94

Key Clinical Message

We report on a patient with distal trisomy 10q syndrome presenting with a few previously undescribed physical features, as well as, autism spectrum disorder (ASD). We recommend that patients with distal trisomy 10q syndrome should have a behavioral evaluation for ASD for the early institution of therapy.

Keywords

Autism spectrum disorder, genome-wide SNP genotyping, quantitative PCR, trisomy 10q syndrome.

Introduction

The distal trisomy 10q syndrome is a clinically and cytogenetically recognizable entity with multiple reported cases in the literature as early as 40 years ago [1–15], but was later delineated as a distinct entity [16, 17]. As the majority of the reported cases are secondary to parental balanced translocations or de novo unbalanced translocations, there is an associated monosomy of the reciprocal chromosomal segment in the form of a derivative chromosome. In a few cases, the only detectable abnormality is the 10q duplication (trisomy) [18–21], in addition, 10q triplication (tetrasomy) is reported in one case [22].

Here, we report a 26-year-old man with multiple congenital anomalies, dysmorphic features, severe intellectual impairment, and an autism spectrum disorder (ASD). Cytogenetic and molecular analyses showed an unbalanced chromosomal abnormality with duplication of about 30 MB of the distal long arm of chromosome 10 (10q24.31 – 10qter).

Case Report

The subject of this report is a 26-year-old Qatari man of Arabic ethnicity, who was identified since early childhood to have multiple congenital anomalies and severe intellectual impairment. He was born at full-term with notable cleft palate repaired at the age of 2 years, and had neonatal jaundice due to ABO blood group incompatibility treated successfully with phototherapy. Hypotonia was notable from early on. He started walking, with a walker, at the age of 30 months and walked independently at the age of 42 months, albeit with an awkward and unstable gait. He uttered the first words at the age of 7 years and never acquired phrase speech despite receiving speech therapy on several occasions. Hearing was reported to be normal on several assessments and he had hypermetropia that required correction by glasses. He never had any reported seizures, gastrointestinal problems, cardiac problems, frequent infections, or asthma. There were no significant findings on the magnetic resonance imaging (MRI) of the brain. He is the oldest in a sibship of six

(three brothers and two sisters) with third cousin parents and the family history is negative for similar conditions or recurrent abortions.

On examination, he has a flat face with facial asymmetry, flat nasal bridge and a flat nose, hypertelorism, microphthalmia with strabismus but without blepharophimosis, epicanthal folds with slight ptosis of the eyelids, tented upper lip with profoundly prominent upper and lower lips, prominent long mandible with obtuse mandibular angle, small prominent posteriorly rotated ears with poorly folded helices and without a lobule and webbing of the neck (pterygium coli), Figure 1A and B. Despite the short stature, he has arachnodactyly and dolichostenomelia with his hands reaching to his knees on standing, Figure 1C, D, and E. He has camptodactyly (contractures of the proximal interphalangeal joints of the 2nd to the 5th finger) more pronounced on the left hand, Figure 1D and E. He has normal chest without pectus deformity, but has prominent scapulae. He has kyphosis and positional scoliosis. There is valgus deformity of the feet (intoeing) and long hallux and prominent heels. His height is 155 cm (below the third percentile) and his weight is 40 kg (below the third percentile) and his head circumference is 52.5 cm (2 SD below the mean).

The behavior and psychological assessment of this patient included C.A.R.S. (Childhood Autism Rating Scale) screening, in which he scored 30/60, which puts him at a low level of mild ASD. Despite the poor verbal and nonverbal communication skills, he understands a great deal of

instructions. The autism diagnostic interview-revised (ADI-R) evaluation (obtained from his caretaker – aunt) shows poor verbal and non-verbal communication, poor social skills and inconsistent eye contact, preoccupation with electronic gadgets, batteries and wires and he repetitively ensures the softness of his undergarments by feeling them. While he scored within the cutoff range of ASD in areas of qualitative abnormalities in reciprocal social interaction and communication, he did not meet the cutoff score for restricted, repetitive and stereotyped patterns of behavior. The autism diagnostic observation schedule (ADOS) evaluation showed the diagnosis of ASD. The abnormal development started before 3 years of age, and he was given the diagnosis of Pervasive Developmental Disorder Not Otherwise Specified (PDD-NOS). He is diagnosed with severe intellectual impairment based on Stanford Binet IV test scores and Adaptive Behavior Scale (ABS) and Vinland Adaptive Behavior Scale (VABS) evaluations.

Methods

Cytogenetic analysis of banded chromosomes showed an abnormal chromosome 14 with a substantial chromosomal material, probably chromosome 10q, on its short arm. Both chromosomes 10 had normal banding pattern. Parents are reported to have normal chromosomes (Karyotypes are not shown).

Molecular studies: DNA was extracted from peripheral blood, drawn after obtaining an informed consent from the

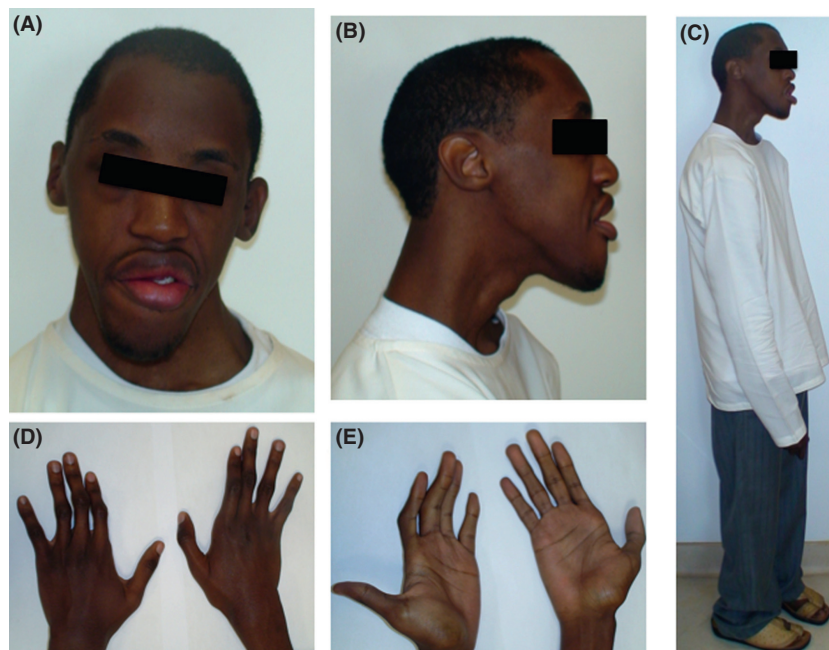

Figure 1. Dysmorphic features. (A and B) Facial and neck features from the front and the side. (C) Dolichostenomelia with the hand reaching close to the knee. (D and E) Camptodactyly and arachnodactyly.

patient's legal guardian, using Puregene kit from Gentra (Qiagen Sciences, Germantown, MD). The consent forms and the research project were approved by the Shafallah Medical Genetics Center Institutional Review Board, which operates according to the accords of the declaration of Helsinki. An MLPA (multiplex ligase-dependent probe amplification) assay for sub-telomeres was performed using P036C, P069 and P070 probe mixes (MRC-Holland, Amsterdam, Holland) and compared against 9 male and female controls.

For copy number variation (CNV) analysis, we employed genome-wide single nucleotide polymorphism (SNP) genotyping using Illumina Infinium Bead Chip HumanCNV370-Duo and then Human1M-Duo (Illumina, San Diego, CA). The analysis was carried out using GenomeStudio 2011.1 from Illumina.

For confirmation of the breakpoint, quantitative real-time PCR was performed using qPCR Fast Start DNA Master SYBR Green I (Roche, Basel, Switzerland) on a light cycler system (Roche v2.0). Primers were designed with Primer3 web based software (<http://bioinfo.ut.ee/primer3/>). The patient sample was compared against 2 control samples with various concentrations.

Results

The MLPA assay provided evidence that there are three copies of chromosome 10q sub-telomeric sequences

(results not shown). Subsequently, quantitative real-time PCR for sequences from coding exons of two genes, *TUB-GCP2* and *VENTX*, located at 10q26.3, centromeric to the subtelomeric sequences, demonstrated the presence of three copies of the amplified exonic region (results not shown).

The CNV analysis of the region on 10q showed three copies of all SNPs starting from marker *cnvi0004765* till the telomere, while the marker *rs7916091* was the first telomeric marker to show two copies (Fig. 2). Both markers are 165 base pairs apart (at about 104.97 MB) and both are contained within the intronic stretch of *BC040734* gene and both are telomeric to *NT5C2* (GRCh 37/hg 19). No other significant CNVs were found and as there was no access to parents' DNA, we could not assess for de novo CNVs. Quantitative real-time PCR for sequences from coding exons of *NT5C2* (at about 104.8 MB) demonstrated the presence of two copies, while quantitative real-time PCR for sequences from coding exons of *LOC729020* (at about 105 MB) showed three copies.

Discussion

In this illustrative patient, the distal 10q duplication is sharply demarcated by a combination of genome-wide SNP genotyping array and quantitative real-time PCR to identify the extent of the 10q duplication and to confirm the absence of any associated monosomy or other signifi-

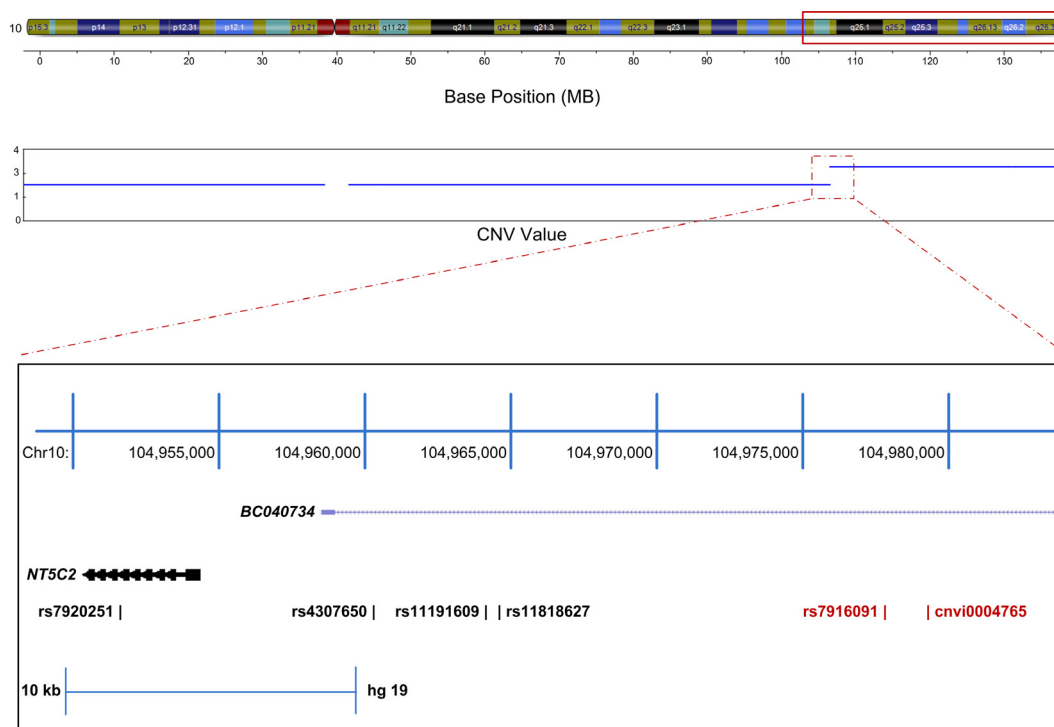


Figure 2. Idiogram of chromosome 10 showing the duplicated region and a detailed molecular map of the breakpoint.

cant CNV. The duplicated region spans about 30.5 MB from 10q24.1 to qter and contains 168 protein coding genes and 115 noncoding RNAs. In the current report and similar to a few other reported cases, the duplication is “pure” constituting the only genomic imbalance in this patient [18–21].

In this report, the patient has features that are relevant to the distal trisomy 10q syndrome, such as delayed growth and development, hypotonia, dysmorphic features, and congenital anomalies [16]. The relevant dysmorphic features include flat face, flat nasal bridge, hypertelorism, tented upper lip (bow-shaped mouth), ear anomalies, webbing of the neck, and prominent scapulae [12, 14, 16, 21, 23]. The congenital anomalies shared with other reported cases include microcephaly, cleft palate, foot deformity, and camptodactyly [1, 12, 14, 16, 21, 22, 23]. However, the subject of this report has unique features that to our knowledge are not previously described including prominent lips, facial asymmetry, marfanoid habitus with dolichostenomelia and arachnodactyly. In addition, he does not have clear blepharophimosis, which is consistently reported [14] and no pectus deformity.

The patient in this report had extensive behavioral evaluation that showed poor reciprocal social interactions, failure to engage in age appropriate social activities, non-verbal communication problems, excessive adherence to routines and restricted interests. He was diagnosed with PDD-NOS according to the DSM-IV, which is on the ASD spectrum. The diagnosis of ASD still holds under the DSM-5. The majority of the existing reports denote mental retardation without the performance of any behavioral evaluation. In one case report, socialization and communication defects were identified using Vineland ABS [21]. We recommend that cases of trisomy 10q should undergo behavioral evaluation to identify treatable or modifiable pathology.

In conclusion, we report a patient with “pure” distal trisomy 10q, in whom we identified the breakpoint using several high-resolution molecular techniques. Although the subject present clinical findings similar to previously reported cases, some features are lacking and new features are described. Behavioral evaluation adds the diagnosis of ASD to the spectrum of features in the distal trisomy 10q syndrome.

Acknowledgment

This study is funded by intramural funds from the Shafallah Center.

Conflict of Interest

None declared.

References

1. Francke, U. 1972. Quinacrine mustard fluorescence of human chromosomes: characterization of unusual translocations. *Am. J. Hum. Genet.* 24:189–213.
2. Laurent, C., M. Bovier-Lapierre, and B. Dutrillaux. 1973. Partial trisomy 10 due to hereditary translocation t(1;10)(q44;q22). *Humangenetik* 18:321–327.
3. Talvik, T., A. V. Mikelsaar, R. Mikelsaar, M. Käosaar, and S. Tüür. 1973. Inherited translocations in two families (t(14q+;10q-) and t(13q-;21q+)). *Humangenetik* 19:215–226.
4. Mulcahy, M. T., J. Jenkyn, and P. L. Masters. 1974. A familial 10/13 translocation: partial trisomy C in an infant associated with familial 10/13 translocation. *Clin. Genet.* 6:335–340.
5. Roux, C., J. L. Taillemite, and G. Baheux-Morlier. 1974. Partial trisomy 10q dueto familial translocation t(10q-;22p-plus). *Ann. Genet.* 17:59–62.
6. Forabosco, A., S. Bernasconi, G. Giovannelli, and B. Dutrillaux. 1975. Trisomy of the distal third of the long arm of chromosome 10. Report of a new case due to a familial translocation t(10;18)(q24;p11). *Helv. Paediatr. Acta* 30:289–295.
7. Berger, R., J. Derre, M. Murawsky, and C. Amiel-Tison. 1976. Partial “de novo” trisomy 10q. *J. Genet. Hum.* 24:261–269.
8. Fraisse, J., B. Lauras, A. La Selve, and F. Freycon. 1977. Two new cases of trisomy 10q21 to 10qter in two sisters due to paternal translocation t(9;10)(q34;q24). *Ann. Genet.* 20:128–131.
9. Taysi, K., V. Yang, N. Monaghan, and N. Beraha. 1983. Partial trisomy 10q in three unrelated patients. *Ann. Genet.* 26:79–85.
10. Johnson, V. P., and W. C. Sutliff. 1994. Duplication 10q confirmed by DNA in situ hybridization. *Am. J. Med. Genet.* 52:184–187.
11. Garcia-Heras, J., J. A. Martin, S. F. Witchel, and P. Scacheri. 1997. De novo der(X)t(X;10)(q26;q21) with features of distal trisomy 10q: case report of paternal origin identified by late replication with BrdU and the human androgen receptor assay (HAR). *J. Med. Genet.* 34:242–245.
12. Davies, J., A. Jaffé, and A. Bush. 1998. Distal 10q trisomy syndrome with unusual cardiac and pulmonary abnormalities. *J. Med. Genet.* 35:72–74.
13. Wiktor, A., G. L. Feldman, E. V. Bawle, P. Czarnecki, J. V. Conard, and D. L. Van Dyke. 2001. Deletion of 2q37 and duplication of 10q24: two cases in the same family and review of the literature. *Ann. Genet.* 44:129–134.
14. Bartholdi, D., S. P. Toelle, B. Steiner, E. Boltshausen, A. Schinzel, and M. Riegel. 2008. Blepharophimosis and mental retardation (BMR) phenotypes caused by chromosomal rearrangements: description in a boy with

- partial trisomy 10q and monosomy 4q and review of the literature. *Eur. J. Med. Genet.* 51:113–123.
15. Aglan, M. S., A. K. Kamel, and N. A. Helmy. 2008. Partial trisomy of the distal part of 10q: a report of two Egyptian cases. *Genet. Couns.* 19:199–209.
 16. Yunis, J. J., and O. Sanchez. 1974. A new syndrome resulting from partial trisomy for the distal third of the long arm of chromosome 10. *J. Pediatr.* 84:567–570.
 17. Klep-de Pater, J. M., J. B. Bijlsma, H. F. de France, N. J. Leschot, M. Duijndam-van den Berge, and J. O. van Hemel. 1979. Partial trisomy 10q: a recognizable syndrome. *Hum. Genet.* 46:29–40.
 18. Petek, E., G. Köstl, L. Rauter, I. Mutz, K. Wagner, and P. M. Kroisel. 2001. Molecular cytogenetics and phenotype characterization of a de novo pure partial trisomy 10 (q24.33-qter). *Clin. Dymorphol.* 10:151–153.
 19. Migliori, M. V., A. M. Ciaschini, G. Discepoli, V. Abbasciano, M. Barbato, and E. Pannone. 2002. Distal trisomy of 10q. Report of a new case of duplication 10q25.2-25.3→qter defined by FISH. *Ann. Genet.* 45:9–12.
 20. Hou, J. W. 2003. Chromosomal 10q26 trisomy resulting from paternal T(9;10)(PTER;Q26.1). *J. Formos. Med. Assoc.* 102:887–892.
 21. Carter, M. T., S. Dyack, and J. Richer. 2010. Distal trisomy 10q syndrome: phenotypic features in a child with inverted duplicated 10q25.1-q26.3. *Clin. Dymorphol.* 19:140–145.
 22. Devriendt, K., G. Matthijs, M. Holvoet, E. Schoenmakers, and J. P. Fryns. 1999. Triplication of distal chromosome 10q. *J. Med. Genet.* 36:242–245.
 23. Kibe, T., Y. Mori, T. Okanishi, K. Shimojima, K. Yokochi, and T. Yamamoto. 2011. Two concurrent chromosomal aberrations involving interstitial deletion in 1q24.2q25.2 and inverted duplication and deletion in 10q26 in a patient with stroke associated with antithrombin deficiency and a patent foramen ovale. *Am. J. Med. Genet. A* 155A:215–220.