

Successful Arthroplasty Using Cadaveric Meniscus for Osteochondral Defects in the Wrist and Hand Joints

Don Hoang, MD*
 Vivi W. Chen, BS*
 Daniel J. Gould, MD, PhD*
 Myles J. Cohen, MD*†
 David A. Kulber, MD, FACS*†

Background: Osteochondral defects of the radiocarpal, metacarpophalangeal (MCP), and proximal interphalangeal (PIP) joints often necessitate joint arthrodesis or mechanical arthroplasty, which has a limited lifespan. In severely arthritic wrist and finger joints, we propose a novel adjunct for joint salvage using cadaveric meniscus for joint resurfacing as an off-the-shelf alternative to address osteochondral defects and restore normal intraarticular contact stress.

Methods: A total of 14 patients with osteochondral defects in 5 radiocapitate, 5 MCP, 3 PIP, and 1 carpometacarpal joints received cadaveric meniscus to facilitate arthroplasty. Patient demographic, perioperative pain, range of motion, and complications were examined.

Results: Patients aged 17 to 73 years old (average, 54.6 years old) underwent joint reconstruction for scaphoid nonunion ($n = 1$), scaphoid-lunate advanced collapse ($n = 4$), or osteoarthritis of MCP/carpometacarpal ($n = 6$) or PIP ($n = 3$) joints. Successful arthroplasty with joint space preservation occurred in all joints. Patients had a significant reduction in average pain scale score ($P < 0.01$) and improved average range of active motion degrees of flexion ($P < 0.01$) and degrees of extension ($P < 0.05$). No complications resulted; only a revision tenolysis and capsulotomy were required for PIP and MCP arthroplasties. Postoperative films reveal preservation of arthroplasty joint space after an average 19.7-month follow-up (range, 8–54).

Conclusions: We believe that meniscus is a viable joint salvage option or adjunct to preserve pain-free motion and avoid total joint arthrodesis. In this series of 14 patients, we demonstrate the successful use of cadaver meniscus in hand joint arthroplasty, such that it advantageously maintains a low metabolic demand, is biointegratable, and is surgically malleable. (*Plast Reconstr Surg Glob Open* 2017;5:e1257; doi: 10.1097/GOX.0000000000001257; Published online 8 March 2017.)

INTRODUCTION

Historically believed to be “functionless remnants of intra-articular leg muscles,”¹ the human menisci were later found to actually serve an important role in load

sharing, shock absorption, joint stability and lubrication, joint nutrition, and overall protection of articular cartilage.² Menisci are composed of 70% water, and collagen type I makes up 60–70% of its dry weight.³ Together, the high composition of water is crucial for optimal force transmission, and the layers of collagen matrix are organized so as to effectively convert loading force into hoop stress.³ With the move from meniscus removal to preservation in the 1970s,⁴ increased surgical advancements eventually led to the use of free meniscal allograft transplantation (MAT) to restore knee biomechanics, alleviate postmeniscectomy symptoms, and delay osteoarthritis.⁵ Various documentations exist for the first MAT, with some indicating 1972 as the first one performed by Zukor et al.⁶ and others citing

*Department of Plastic and Reconstructive Surgery, Keck School of Medicine, University of Southern California, Los Angeles, Calif.; and †Plastic Surgery Center, Cedars-Sinai Medical Center, Los Angeles, Calif.

Received for publication September 7, 2016; accepted January 11, 2017.

Presented at the American Society for Surgery of the Hand (ASSH) 2016 in Austin, Texas.

Copyright © 2017 The Authors. Published by Wolters Kluwer Health, Inc. on behalf of The American Society of Plastic Surgeons. This is an open-access article distributed under the terms of the Creative Commons Attribution-Non Commercial-No Derivatives License 4.0 (CCBY-NC-ND), where it is permissible to download and share the work provided it is properly cited. The work cannot be changed in any way or used commercially without permission from the journal.

DOI: 10.1097/GOX.0000000000001257

Disclosure: None of the authors has a financial interest in any of the products, devices, or drugs mentioned in this manuscript. The Article Processing Charge was paid for by the authors.

1984 as the first MAT.⁵ However, a protective effect was not produced and documented until 1997.⁷ Since then, cadaveric menisci have been utilized to treat various forms of meniscus damage or degradation.

In cases of osteoarthritis in the finger and wrist joints, treatments most commonly used have been joint arthrodesis and joint arthroplasty. Arthrodesis involves fusion of the second and third digits in extension and fusion of the fourth and fifth digits in 10–20 degrees of flexion. Utilized for debilitating pain and deformity, arthrodesis aims to recreate normal cascade of the fingers and results in surgical immobilization of a joint by fusion of the adjacent bones. After arthrodesis, motion in the joints is no longer possible. This is in contrast to arthroplasty, in which surgical reconstruction or replacement of a joint allows continued mobility of the joint. However, these methods predispose the patient to a long list of complications,^{8–11} including but not limited to implant failure, infection, and hardware complications.⁹ Complications often lead to additional surgical management. On the other hand, complication rates in MAT are low to acceptable^{4,12,13} with reportedly low reoperation and revision rates even in an athletic population.¹⁴

MAT is typically indicated when therapy fails to provide symptomatic relief or when joint space narrowing occurs, with the most common indication for MAT being patients with symptoms of a meniscus-deficient tibiofemoral compartment.³ Upon completion of the procedure, the MAT has been shown to yield fair to excellent results in almost 85% of patients, with long-term improvements in pain and functional outcomes.^{15,16} However, the MAT has traditionally been successfully documented for use in the knee joint. After an extensive literature search, we have found no documented cases of using meniscus harvested from a donor in hand and wrist procedures, except more

recently by Shapiro et al.¹⁷ on the trapeziometacarpal arthritis of the thumb. As such, the purpose of this study is to investigate the results of MAT in osteochondral defects of severely arthritic finger and wrist joints and subsequently demonstrate the novel use of the cadaveric meniscus for successful joint resurfacing and arthroplasty.

PATIENTS AND METHODS

Between February 2012 and December 2015, we operated on 14 patients who qualified for finger or wrist arthroplasty using cadaveric meniscus. All patients suffered from osteoarthritis, with osteochondral defects in 5 radiocapitate, 5 metacarpophalangeal (MCP), 3 proximal interphalangeal (PIP), and 1 carpometacarpal (CMC) joints. Reasons for surgery included scaphoid nonunion ($n = 1$), scaphoid-lunate advanced collapse ($n = 4$), or osteoarthritis of MCP and CMC ($n = 6$) or PIP ($n = 3$) joints. The average age of these patients was 54.6 years (range, 17–73 years; 5 males and 9 females), and the average follow-up period was 19.7 months.

Data Collection

Both preoperative and postoperative x-rays were taken of the affected joint area, with postoperative magnetic resonance imaging (MRI) obtained for patient 10 to evaluate the viability of the cadaveric meniscus graft. Preoperatively, range of motion (ROM) of the affected joint and pain score were recorded. ROM preoperatively ranged from 0 to 5 degrees, with an average of 1.1 degrees. Pain was evaluated using a numeric pain rating scale ranging from 0 to 10, with 0 representing no pain and 10 representing the highest degree of pain.¹⁸ Preoperative pain scores ranged from 7 to 10, with an average score of 9.7. Postoperatively,

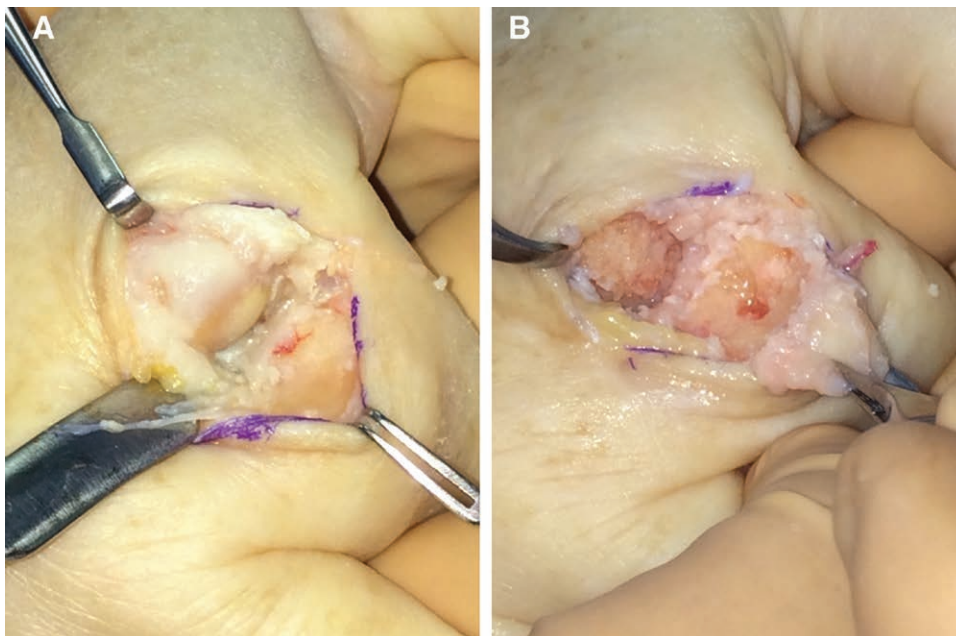


Fig. 1. A, Intraoperative view of a 60-year-old female patient (patient 10) with second metacarpal head and proximal phalanx arthritis. B, Intraoperative debridement of metacarpal head and proximal phalanx joint surfaces debrided, with preparation for grafting.

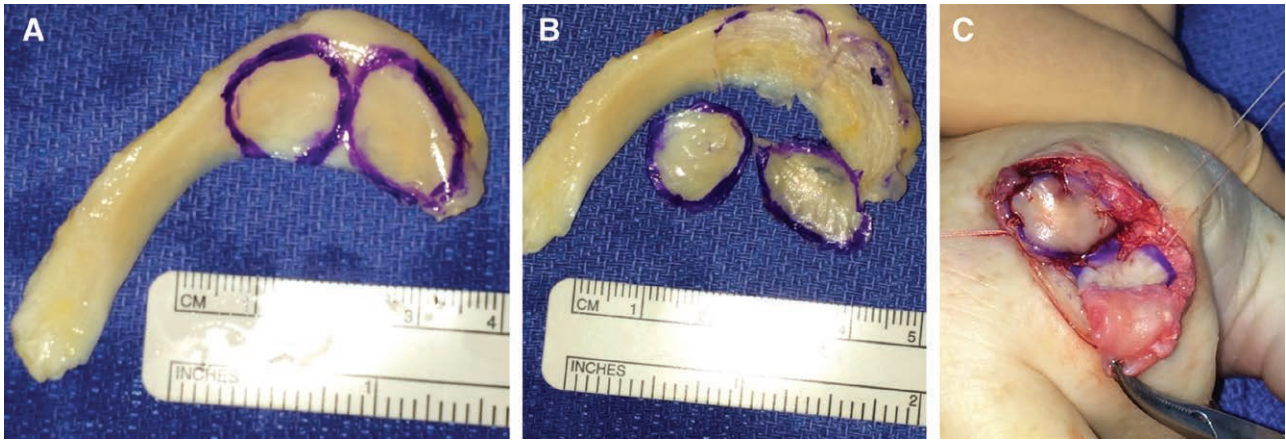


Fig. 2. (A, B) Preparation of cadaver meniscal graft and (C) inseting of graft with vicryl suture and fibrin glue.

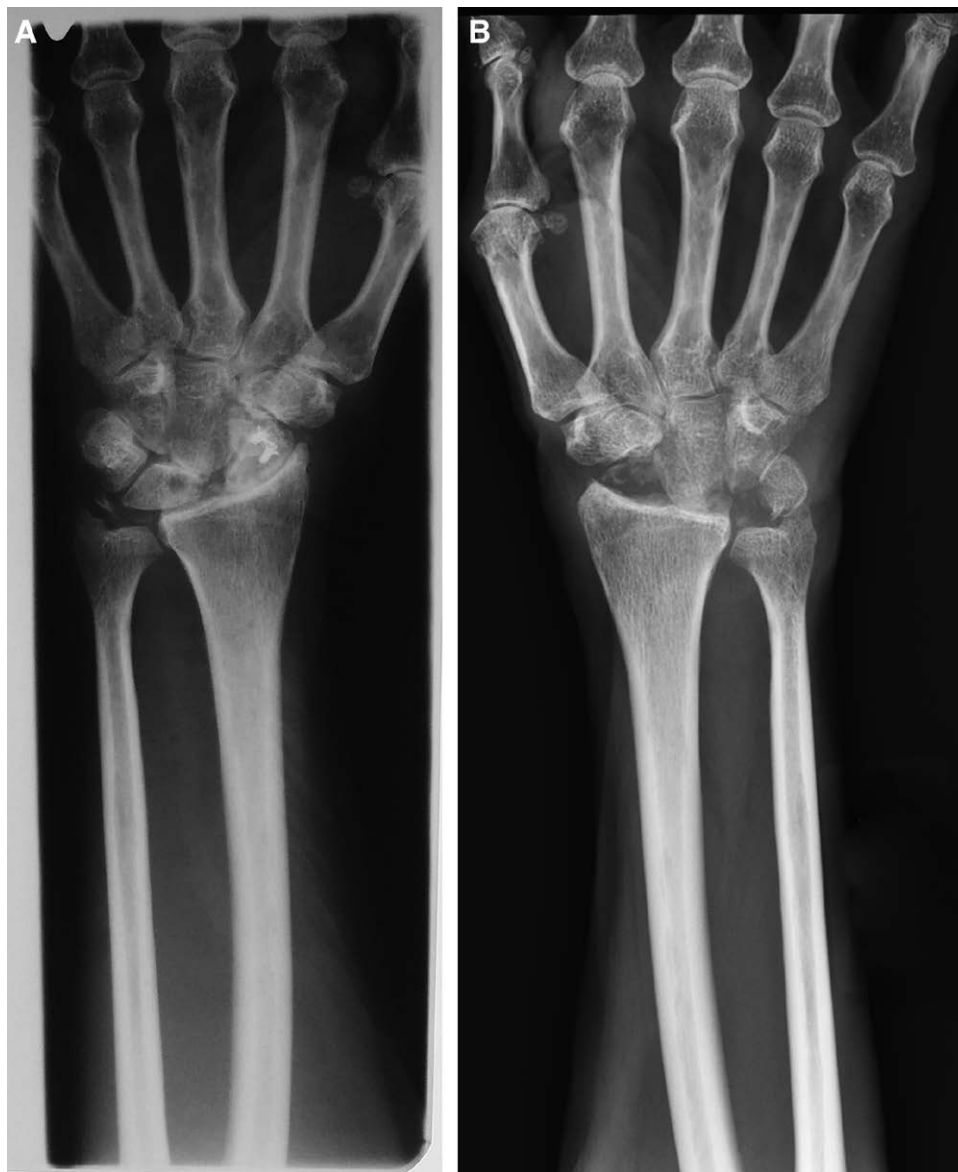

Fig. 3. A, Preoperative x-rays of the right wrist displaying scaphoid nonunion advanced collapsed osteoarthritis in patient 9, a 55-year-old male. B, Postoperative x-rays after proximal row carpectomy and cadaveric meniscus resurfacing of radiolunate fossa and capitate.

flexion and extension of the affected joint and pain score were again recorded.

Surgical Procedure

Patients underwent standard surgical exposures and salvage procedures such as proximal row carpectomies specific to their arthritic joint. For interphalangeal (IP) joints, a slightly curved dorsal incision is made to expose the extensor apparatus of the IP joint. A midline incision is made through the extensor mechanism while protecting the insertion. Collateral ligaments are preserved while exposing osteochondral defects. Upon closure, the extensor mechanism is repaired with either interrupted mattress sutures or a running suture with a monofilament absorbable suture. Similarly, for the MCP joint, a longitudinal incision is made over the MCP joint and the extensor tendon is split longitudinally. The dorsal capsule is divided to expose the joint. For radiocarpal joints, a longitudinal incision is made dorsal in the line of the third metacarpal. The extensor retinaculum is incised over the third compartment, and the fourth and second compartments are exposed over the carpus. If not already performed, the posterior interosseous nerve is excised. The capsule is in-

cised transversely at the level of the capitulunate joint. The extensor carpi radialis longus muscle tendon is retracted radially, and the extensor carpi radialis brevis muscle tendon is retracted ulnarly to allow exposure and evaluation of the surfaces of the capitate, distal lunate, hamate, and distal triquetrum.

Once osteochondral defects were identified at the joint surfaces (Fig. 1A), they were debrided back to healthy cancellous bone (Fig. 1B). Measurements were then taken of the debrided osteochondral defect as a template for the cadaver meniscus graft needed to be fashioned (Fig. 2A, B). Once the cadaver meniscus was trimmed to exact size, they were inset and sutured over the osteochondral defect with 4-0 Mersiline sutures (Fig. 2C) and coated with fibrin sealant glue. Intraoperatively, joint spaces were evaluated and reduced to ensure they were preserved without bone contact. The surgical exposures were then closed in layers.

Patients who presented with radiocarpal joint arthritis (Fig. 3A) underwent proximal row carpectomies in the standard fashion. However, the above technique was utilized to address the capitate and radiolunate fossa osteochondral defects, before reduction of the capitate into the radiolunate fossa (Fig. 3B).

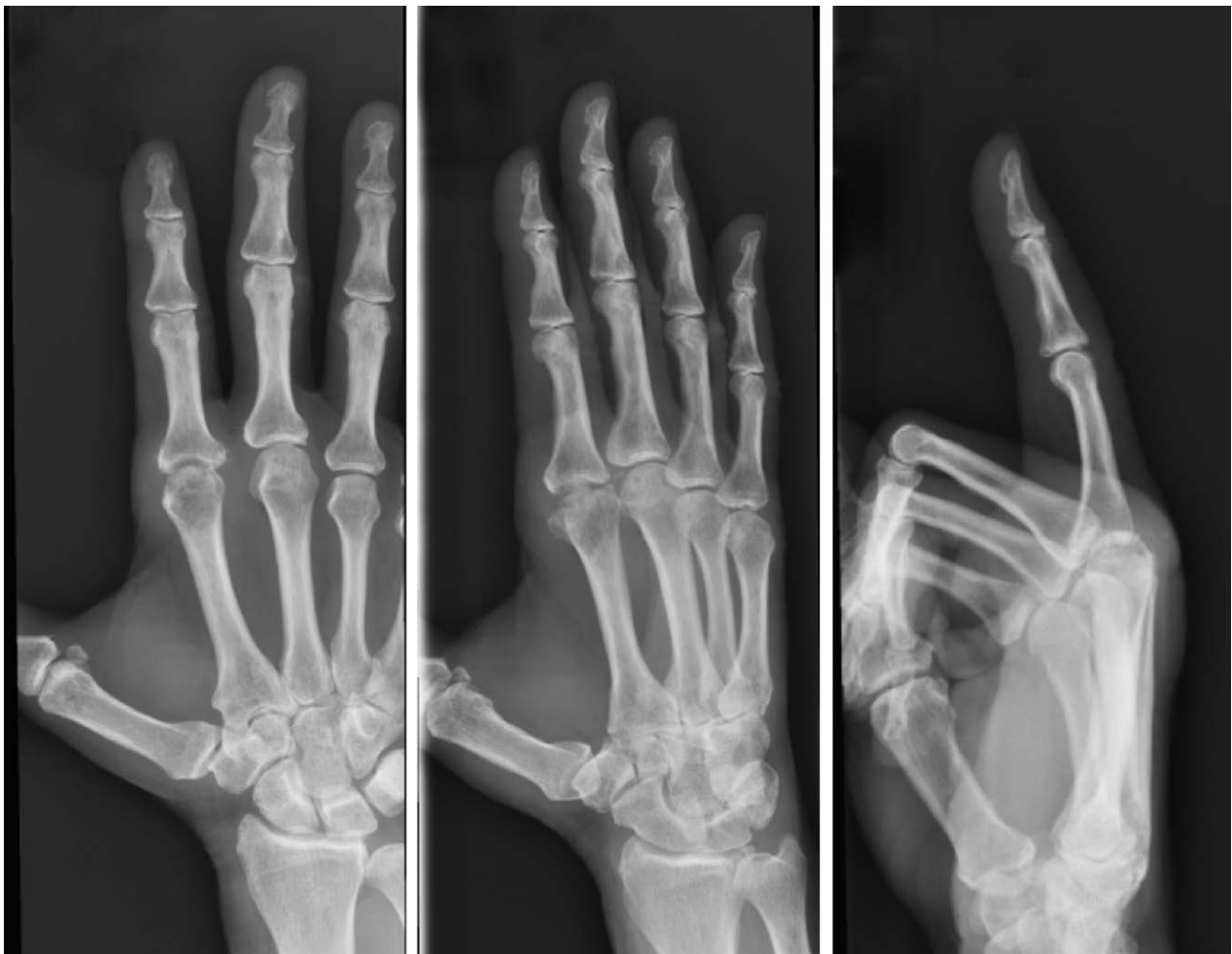

Fig. 4. Patient 10, preoperative x-rays of nontraumatic osteoarthritis of the right index finger.

At 3 weeks postoperatively, all patients underwent hand therapy.

Clinical Case

Patient 10 is a 60-year-old right-hand dominant female office worker with a history of severe pain in her right index finger for over 1 year. Her pain was worse with any activity and prevented her from participating in regular hobbies such as crocheting and knitting, which required fine manual dexterity. This deficit caused her much emotional distress. Her previous treatments included multiple steroid injections but with no benefit. Her most recent injection was at 3 weeks before presentation. The patient's medical

and surgical history included a trigger finger release of her right index finger at 9 months before presentation and bilateral carpal tunnel releases. She had unremarkable medication history and was a former smoker with no history of alcohol use.

On preoperative physical exam, the incision from her trigger finger release was healing well. The patient displayed mild erythema at her second MCP joint. Preoperative ROM was 0 degrees at the second MCP joint due to pain and swelling, with tenderness to palpation. She displayed full ROM in all other digits. Her neuromuscular exam was within normal limits. Preoperative level of pain was a 10 on the pain scale.

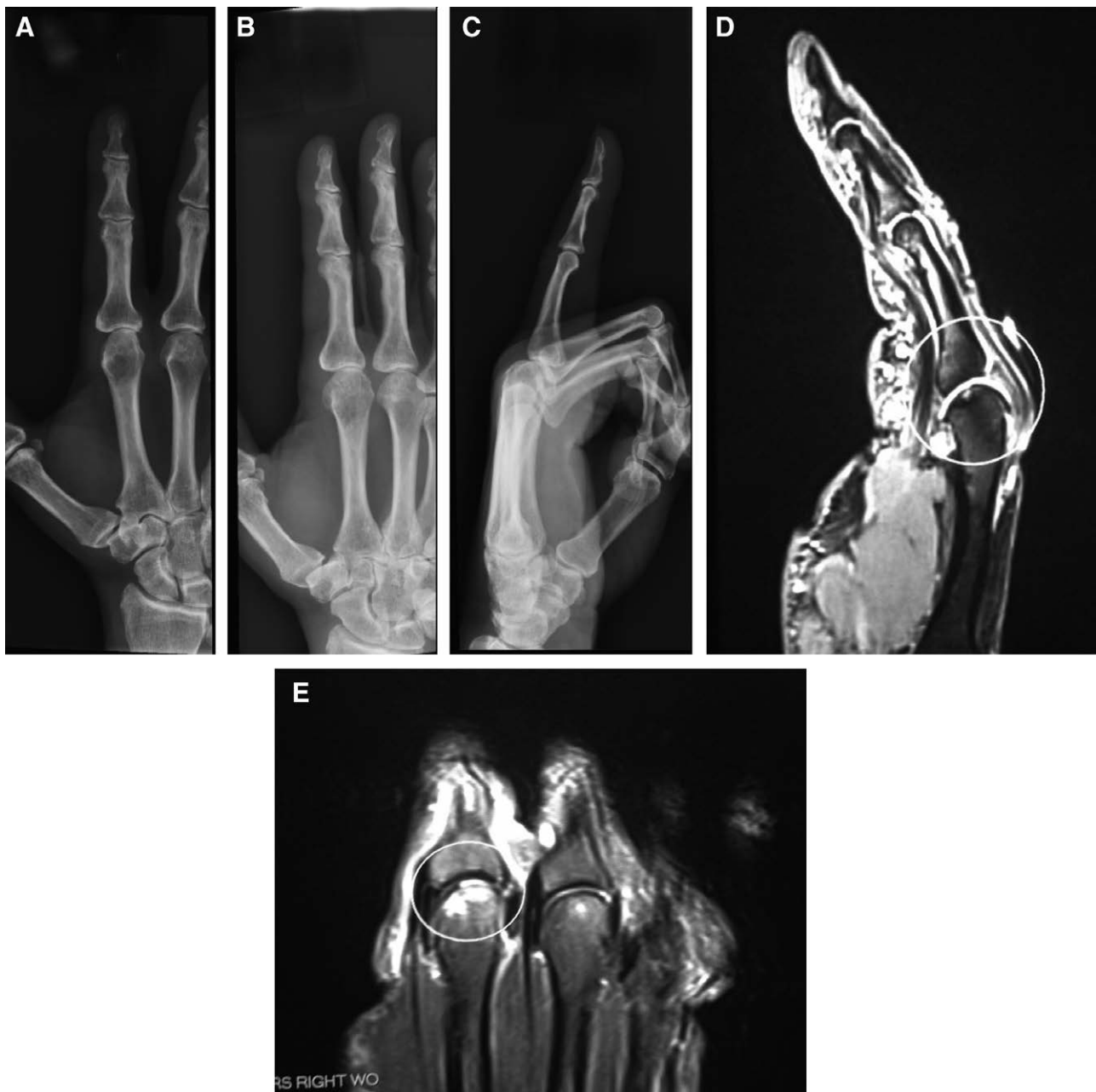

Fig. 5. A–C, Postoperative x-rays of patient 10 revealing preserved joint space at 1 month. D, E, Postoperative MRI films showing meniscal transplant intact and in place at volar aspect of second MCP joint 3 months after surgery.

Table 1. Patient Data

Patient	Joint Pathology	Joint Involved	Affected Side	Age	Sex	Cadaver Meniscus	Complications	Preoperative ROM (Degrees)	Hand Therapy (3 Weeks Postoperatively)				Operative Revisions	Duration of Follow-up (Months)
									Preoperative Pain (Score)	Postoperative Pain (Score)	Flexion of Affected Joint (Degrees)	Extension of Affected Joint (Degrees)		
1	Traumatic osteoarthritis (SLAC wrist)	Radiocarpal wrist	Right	51	M	Yes	None	0	Yes	10	1	None	18	
2	Traumatic osteoarthritis (finger laceration through joint)	Third MCP	Left	17	F	Yes	None	0	Yes	10	6	Tenolysis, capsulotomy	19	
3	Osteoarthritis (ischemia induced by sepsis)	Second MCP	Left	40	F	Yes	None	0	Yes	10	1	Tenolysis, capsulotomy	25	
4	Traumatic osteoarthritis (finger fracture)	Fifth MCP	Left	54	M	Yes	None	0	Yes	10	3	None	54	
5	Traumatic osteoarthritis (finger fracture)	Fifth PIP	Left	54	F	Yes	None	5	Yes	10	2	Tenolysis, capsulotomy	26	
6	Osteoarthritis (nontraumatic)	Third MCP	Right	59	M	Yes	None	5	Yes	10	1	None	34	
7	Traumatic osteoarthritis (SLAC wrist)	Radiocarpal wrist	Right	73	F	Yes	None	0	Yes	10	3	None	16	
8	Traumatic osteoarthritis (SLAC wrist)	Radiocarpal wrist	Left	50	F	Yes	None	0	Yes	10	0	None	17	
9	Traumatic osteoarthritis (SNAC wrist)	Radiocarpal wrist	Left	55	M	Yes	None	0	Yes	10	0	None	15	
10	Osteoarthritis (nontraumatic)	Second MCP	Right	60	F	Yes	None	0	Yes	10	0	None	14	
11	Traumatic osteoarthritis (SLAC wrist)	Radiocarpal wrist	Left	57	M	Yes	None	0	Yes	10	0	None	12	
12	Osteoarthritis (nontraumatic)	Second PIP	Right	67	F	Yes	None	0	Yes	—	0	None	10	
13	Osteoarthritis (nontraumatic)	Thumb CMC	Left	59	F	Yes	Postoperative swelling/pain treated with steroids	5	Yes	7	4	None	8	
14	Osteoarthritis (nontraumatic)	Second PIP	Left	69	F	Yes	None	0	Yes	60	3	None	8	
Average				54.6				1.1	Average wrist	9.7	1.7		19.7	
									Average MCP					
									Average PIP					

SLAC, scapholunate advanced collapse of the wrist; SNAC, scaphoid nonunion advanced collapse of the wrist.

The patient had a diagnosis of painful MCP joint arthritis in her right index finger, as can be seen in preoperative x-rays (Fig. 4). All nonsurgical management failed. As a result, she was presented with multiple surgical options, including arthrodesis, silicone arthroplasty, and nonconstrained implants. In addition to strongly desiring pain relief, the patient also wished to continue working. This rendered the option of arthrodesis unsatisfactory because the patient needed her index finger to type for her job. With arthroplasty, there was also a high risk of implant fracture or failure due to the specific demands of her occupation. As a result, the patient was presented with the option of MCP joint reconstruction using MAT.

The patient underwent the above surgical technique and was postoperatively placed in a radial gutter splint with MCP joint in extension and PIP free for 3 weeks. Her sutures were removed at 2 weeks, and she started hand therapy at 3 weeks with a removable hand splint. Her precautions included no heavy lifting or strenuous activity without other weight-bearing restrictions. X-rays and MRI revealed preservation of joint space and an intact cadaver meniscus (Fig. 5).

The patient's pain significantly improved from a preoperative 10 to a 0 on the pain scale. She has been utilizing her hand for most daily tasks, including some lifting. Her active ROM for the right index MCP joint was 13–70 degrees. Her hand grip strength, as measured by a dynamometer, was 45 pounds, as opposed to 62 pounds in her contralateral hand. Three-point pinch was 14 (16 contralateral) and lateral pinch was 14.5 (16 contralateral).

Statistical Analyses

Wilcoxon signed rank test was used to determine statistical differences between the paired pre- and postoperative measurements. *P* values were two-tailed, and values equal to or less than 0.05 were defined as statistically significant.

RESULTS

Results for all 14 patients are listed in Table 1. The mean follow-up period showing postoperative preservation of arthroplasty joint space on radiographs was 19.7 months, ranging from 8 to 54 months. All patients received hand therapy at 3 weeks postoperatively. Of the 14 patients who underwent this technique, all achieved successful joint arthroplasty with joint space preservation. Postoperative flexion of the affected joint was available in 12 of 14 patients. In those 12 patients, average postoperative flexion improved to 15 degrees for wrist joints, 46 degrees for MCP joints, and 50 degrees for PIP joints ($P < 0.01$). Postoperative extension of the affected joint was available in 6 of 14 patients, average of which was 30 degrees—also a significant improvement from preoperative ROM ($P < 0.05$). There was a significant reduction in average pain scale score from 9.7 to 1.7 ($P < 0.01$). Aside from postoperative swelling in 1 patient, no complications occurred. Of 14 patients, only 2 (14%) required tenolysis and capsulotomy for postoperative revisions of PIP and MCP arthroplasties (Fig. 6). Postoperative radiographic imaging revealed not only preserved joint spaces on x-ray

hand films (Fig. 5A–C) but also that meniscal transplant remained intact and in place on MRI at 3 months postoperatively (Fig. 5D, E).

DISCUSSION

The loss of meniscal tissue is associated with early-onset knee osteoarthritis^{19–21} and often also causes immense pain, loss of function, and articular cartilage degeneration.¹³ For MAT on the knee, current studies consistently reveal favorable clinical and functional results in young and active meniscectomized patients.²² These improvements in symptoms, function, and quality of life were also shown at longer follow-up periods of 7–14 years.²² Furthermore, according to Samitier et al.,²² although MAT does not necessarily prevent degeneration in previously healthy cartilage, it may prevent the progression of cartilage damaged at long-term follow-up. Because of the successful use of MAT on the knee, this study aimed to demonstrate MAT as a valuable alternative to treating osteochondral defects of the radiocarpal, MCP, and PIP joints. The cadaveric meniscus not only provides resurfacing of the affected bone but also serves to maintain the articular space. No additional interventions are taken to maintain the articular space. Biointegration of the cadaver meniscus occurs via contact from debrided bone at either or both bone surfaces of a joint. Joint collapse in this case may actually be beneficial as a bolster to maintain the graft in place.

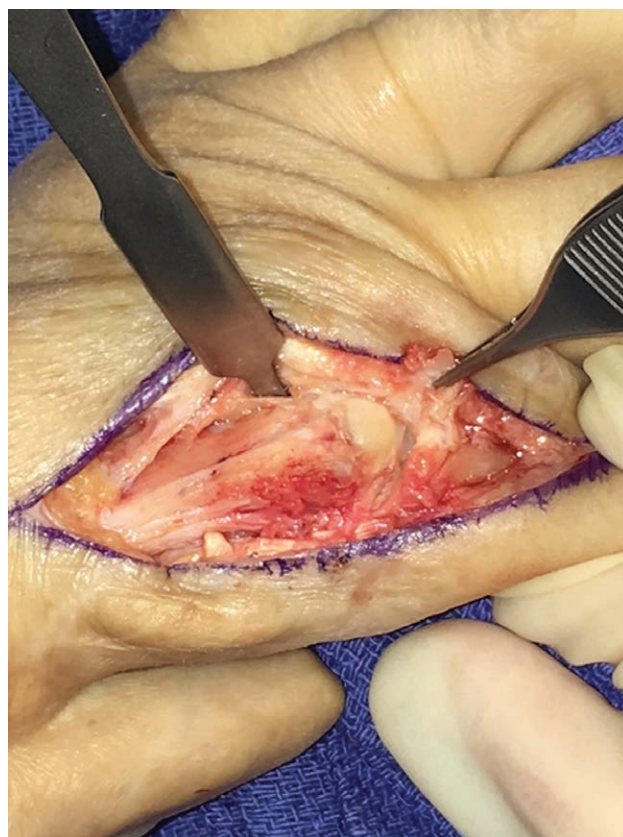


Fig. 6. Intraoperative view of tenolysis and capsulotomy 19 months after second MCP joint resurfacing, revealing intact joint surfaces.

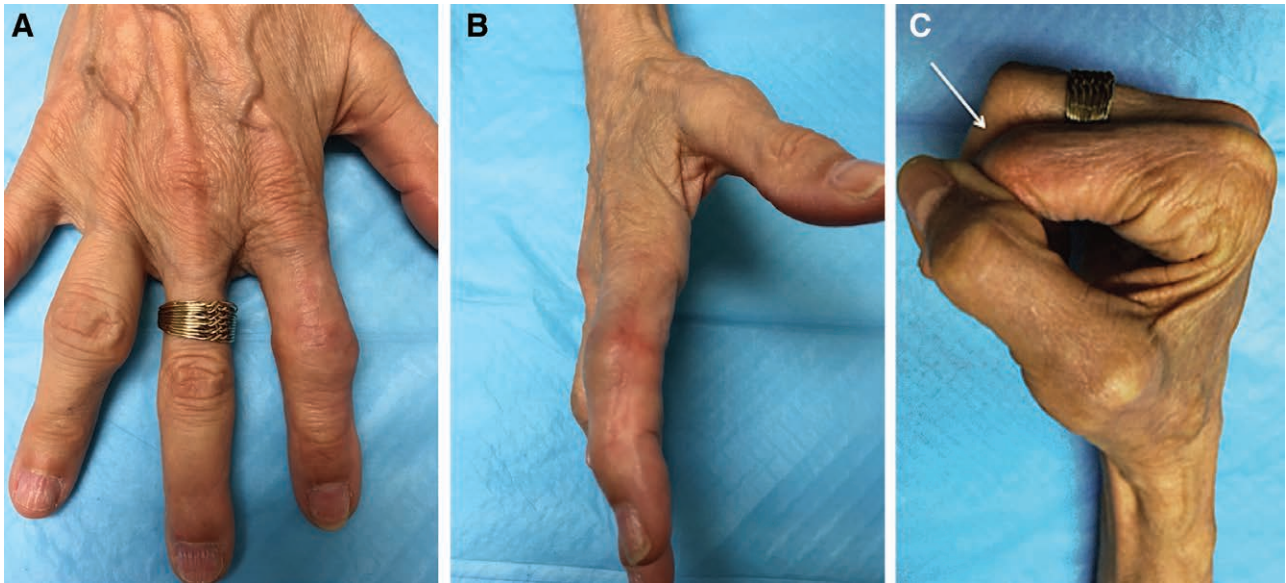


Fig. 7. Patient 12, a 67-year-old female with nontraumatic osteoarthritis at (A) 6 months postoperatively from second PIP joint reconstruction with cadaver meniscus (anteroposterior view). B, Lateral view of reconstructed joint. C, Improved ROM, with 60-degree flexion at PIP joint from 0 degrees preoperatively.

Our results showed significant improvements from preoperative to postoperative outcomes in both ROM and pain scale score (Table 1, Fig. 7). Postoperative films reveal preserved joint space (Figs. 5A–C and 3B), with the meniscal transplant intact and preserved in place at 3 months postoperatively (Fig. 5D–E). Therefore, we believe that the novel use of this procedure can preserve pain-free motion and avoid total joint arthrodesis. It also obviates the need for revision and reduces problems of foreign body and mechanical failure of joint implants.

The alternative choices are fraught with complications avoidable through the use of MAT. Arthrodesis is more frequently used at the distal IP and thumb MCP joints and carries the complications of nonunion, malunion, dorsal skin necrosis, and prominent hardware. Because it is hinged, silicone arthroplasty is the standard for deformed joints. However, removing the requirement of soft-tissue restraints is plagued with a fracture rate of 42% at 10 years and 66% at 17 years, with a revision rate of 17% and 37%, respectively. Nonconstrained implants require adequate bone stock and sufficient soft tissues for stability and has an overall revision rate of 12% and 16-year survivorship of 70%.^{23–25}

Because this is a case series, it is statistically underpowered and limited by a small cohort size. However, our results provide evidence that a robust, large-scale prospective study is worthwhile and that a comparison between the cadaveric meniscus procedure and other procedures such as joint arthrodesis and mechanical arthroplasty can be undertaken to further elucidate these treatment options. Although our average follow-up time of 19.7 months allows us to observe substantial outcomes, longer follow-up time is required to verify lasting outcomes. Additional animal studies are being conducted that may elucidate the mechanism of cell recruitment and biointegration of cadaveric meniscus.

David A. Kulber, MD

Cedars-Sinai Medical Center
8635 West Third Street Suite 990W
Los Angeles, CA 90048
E-mail: kulberd@cshs.org

REFERENCES

1. Bland Sutton J. The ligaments of the knee joint. In: Bland Sutton J, ed. *Ligaments, Their Nature and Morphology*. 2nd ed. London: HK Lewis; 1897:32–38.
2. MacConaill MA. The movements of bones and joints; the mechanical structure of articulating cartilage. *J Bone Joint Surg Br*. 1951;33B:251–257.
3. Lee AS, Kang RW, Kroin E, et al. Allograft meniscus transplantation. *Sports Med Arthrosc*. 2012;20:106–114.
4. Elattar M, Dhollander A, Verdonk R, et al. Twenty-six years of meniscal allograft transplantation: is it still experimental? A meta-analysis of 44 trials. *Knee Surg Sports Traumatol Arthrosc*. 2011;19:147–157.
5. Milachowski KA, Weismeier K, Wirth CJ. Homologous meniscus transplantation. Experimental and clinical results. *Int Orthop*. 1989;13:1–11.
6. Zukor DJ, Cameron JC, Brooks PJ, et al. The fate of human meniscal allografts. In: Ewing JW, ed. *Articular Cartilage and Knee Joint Function: Basic Science and Arthroscopy*. New York: Raven Press; 1990:147.
7. Cummins JF, Mansour JN, Howe Z, et al. Meniscal transplantation and degenerative articular change: an experimental study in the rabbit. *Arthroscopy*. 1997;13:485–491.
8. Athwal GS, Chenkin J, King CJ, et al. Early failures with a spheric interposition arthroplasty of the thumb basal joint. *J Hand Surg Am*. 2004;29:1080–1084.
9. Gaspar MP, Kane PM, Shin EK. Management of complications of wrist arthroplasty and wrist fusion. *Hand Clin*. 2015;31:277–292.
10. Gray KV, Meals RA. Hematoma and distraction arthroplasty for thumb basal joint osteoarthritis: minimum 6.5-year follow-up evaluation. *J Hand Surg Am*. 2007;32:23–29.
11. Peimer CA. Long-term complications of trapeziometacarpal silicone arthroplasty. *Clin Orthop Relat Res*. 1987;220:86–98.

12. Rosso F, Bisicchia S, Bonasia DE, et al. Meniscal allograft transplantation: a systematic review. *Am J Sports Med.* 2015;43:998–1007.
13. Kang RW, Lattermann C, Cole BJ. Allograft meniscus transplantation: background, indications, techniques, and outcomes. *J Knee Surg.* 2006;19:220–230.
14. Waterman BR, Rensing N, Cameron KL, et al. Survivorship of meniscal allograft transplantation in an athletic patient population. *Am J Sports Med.* 2016;44:1237–1242.
15. Vundelinckx B, Vanlauwe J, Bellemans J. Long-term subjective, clinical, and radiographic outcome evaluation of meniscal allograft transplantation in the knee. *Am J Sports Med.* 2014;42:1592–1599.
16. Verdonk PC, Verstraete KL, Almqvist KF, et al. Meniscal allograft transplantation: long-term clinical results with radiological and magnetic resonance imaging correlations. *Knee Surg Sports Traumatol Arthrosc.* 2006;14:694–706.
17. Shapiro PS, Diao E, Givens LM. Meniscal allograft arthroplasty for the treatment of trapeziometacarpal arthritis of the thumb. *Hand (N Y).* 2015;10:407–416.
18. McCaffery M, Pasero C. *Pain: Clinical Manual.* 2nd ed. St Louis: Mosby; 1999.
19. Burke DL, Ahmed AH, Miller J. A biomechanical study of partial and total medial meniscectomy of the knee. *Trans Orthop Res Soc.* 1978;3:91.
20. Fairbank TJ. Knee joint changes after meniscectomy. *J Bone Joint Surg Br.* 1948;30B:664–670.
21. Seedhom BB, Hargreaves DJ. Transmission of load in the knee joint with special reference to the role of the menisci: part II: experimental results, discussions, and conclusions. *Eng Med Biol.* 1979;8:220–228.
22. Samitier G, Alentorn-Geli E, Taylor DC, et al. Meniscal allograft transplantation. Part 2: systematic review of transplant timing, outcomes, return to competition, associated procedures, and prevention of osteoarthritis. *Knee Surg Sports Traumatol Arthrosc.* 2015;23:323–333.
23. Satteson ES, Langford MA, Li Z. The management of complications of small joint arthrodesis and arthroplasty. *Hand Clin.* 2015;31:243–266.
24. Cook SD, Beckenbaugh RD, Redondo J, et al. Long-term follow-up of pyrolytic carbon metacarpophalangeal implants. *J Bone Joint Surg Am.* 1999;81:635–648.
25. Parker WL, Rizzo M, Moran SL, et al. Preliminary results of non-constrained pyrolytic carbon arthroplasty for metacarpophalangeal joint arthritis. *J Hand Surg Am.* 2007;32:1496–1505.