

A Call for Caution in the Immunocompromised: Coronavirus Disease 2019 Associated With Mortality in a Vaccinated Lung Transplant Recipient

John I. Hogan,¹ and Camille N. Kotton²

¹Division of Infectious Diseases and International Health, Hospital of the University of Virginia, University of Virginia School of Medicine, Charlottesville, Virginia, USA, and ²Division of Infectious Diseases, Massachusetts General Hospital, Harvard Medical School, Boston, Massachusetts, USA

We describe a vaccinated lung transplant recipient who experienced a fatal outcome associated with coronavirus disease 2019 (COVID-19). Tocilizumab was administered. The patient exhibited clinical and radiographic evidence of colitis during the course of multiple secondary infections. This report emphasizes the need for more conservative precautions to prevent COVID-19 infection in transplant recipients.

Keywords. colitis; COVID-19; invasive fungal infection; solid organ transplantation; tocilizumab; vaccination.

In a scientific triumph, the unprecedented efficacy of novel vaccination strategies has afforded millions of Americans a robust level of protection against coronavirus disease 2019 (COVID-19) and its multifarious complications. Unfortunately, whereas adverse outcomes attributed to COVID-19 in vaccinated members of the immunocompetent majority are uncommon, the risk of hospitalization and death remains tangible for patients with immunocompromising conditions.

CASE REPORT

In March 2021, a patient in their 60s who underwent lung transplantation >5 years prior received the Ad26.CoV2.S vaccine. The patient had excellent allograft function, no history of

recent rejection, and was maintained on stable doses of prednisone, tacrolimus, and delayed-release mycophenolate at the time of vaccination. Sixty-two days later, the patient developed fever, cough, and dyspnea. Social history was significant for work at a correctional facility associated with >250 cases of COVID-19. Admission occurred on day 5 of illness. Severe acute respiratory syndrome coronavirus 2 (SARS-CoV-2) polymerase chain reaction (PCR) was positive. Sequencing identified the B.1.1.7 (Alpha) variant. Chest radiograph demonstrated diffuse pulmonary infiltrates. Providers discontinued mycophenolate and prednisone on admission. Despite prompt treatment with dexamethasone and remdesivir, the patient required intubation 3 days after admission and received tocilizumab at that time. After experiencing a series of complications including severe hypoxemia and renal dysfunction requiring dialysis, the patient developed progressively worsening shock on day 16 of illness. Empiric vancomycin and aztreonam were initiated in the setting of a listed penicillin allergy. The patient progressed to require nearly maximal vasopressor support and supplemental oxygen delivery, and the infectious disease team was consulted. Documentation suggested prior carbapenem tolerance, and the patient was transitioned to meropenem, vancomycin, micafungin, and voriconazole. The patient's vasopressor requirement improved dramatically over the course of several hours. Computed tomography (CT) of the chest on day 17 of illness demonstrated diffuse pulmonary infiltrates with a ground-glass predominance and coalescent consolidations (Figure 1A). Simultaneous CT of the abdomen demonstrated significant thickening of the sigmoid colon (Figure 1B). Despite initial clinical improvement with empiric antimicrobials, the patient sustained a fatal cardiac arrest on day 17 of illness. Purulent secretions from a tracheal aspirate subsequently grew mucoid *Pseudomonas aeruginosa* and *Candida albicans*. Blood cultures grew *Clostridium innocuum* and *C albicans*. Serum cytomegalovirus (CMV) PCR resulted at 267 IU/mL. Stool PCR for *Clostridioides difficile* was negative. Qualitative SARS-CoV-2 anti-spike immunoglobulin G (IgG) obtained on day 16 of illness was positive. Semi-quantitative SARS-CoV-2 anti-spike IgG obtained on day 17 of illness was positive, detected at a concentration of 70.4 U/mL. The patient died before nucleocapsid IgG testing was performed.

DISCUSSION

Similar to the diminished responses observed with other vaccines after transplant, a growing body of literature strongly suggests that immunosuppression may significantly impact the immunogenicity of COVID-19 vaccines [1–3]. A minority of lung transplant recipients mounted a detectable humoral response to vaccination in multiple studies [2]. In a particularly

Received 29 July 2021; editorial decision 26 October 2021; accepted 8 November 2021; published online 10 November 2021.

Social Media Post

Report of COVID-19 associated with mortality in a vaccinated lung transplant recipient serves as a warning to other immunocompromised patients.

#TxID #COVID-19 #Vaccination #Transplant

Correspondence: John. I. Hogan, MD, Hospital of the University of Virginia, 1215 Lee St, Charlottesville, VA 22903, USA (jih8u@hscmail.mcc.virginia.edu).

Open Forum Infectious Diseases®2021

© The Author(s) 2021. Published by Oxford University Press on behalf of Infectious Diseases Society of America. This is an Open Access article distributed under the terms of the Creative Commons Attribution-NonCommercial-NoDerivs licence (<https://creativecommons.org/licenses/by-nc-nd/4.0/>), which permits non-commercial reproduction and distribution of the work, in any medium, provided the original work is not altered or transformed in any way, and that the work is properly cited. For commercial re-use, please contact journals.permissions@oup.com <https://doi.org/10.1093/ofid/ofab557>

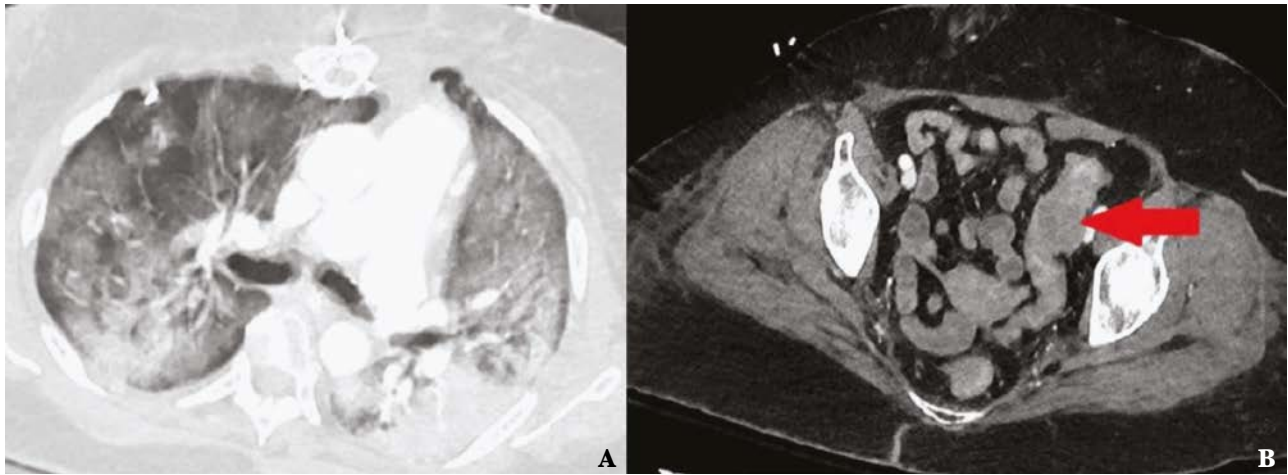


Figure 1. A, Computed tomographic (CT) scan of the thorax demonstrating diffuse pulmonary infiltrates with ground-glass predominance and associated consolidations. B, CT scan of the abdomen with arrow indicating region of significant thickening along the sigmoid colon.

concerning recent publication, zero of 21 lung transplant recipients assessed 4–6 weeks after receiving a second dose of the BNT162b2 vaccine exhibited detectable anti-spike IgG [4]. Compared with messenger RNA (mRNA)–based strategies, the single dose of the Ad26.COVS.2 vaccine may be associated with a lower seroconversion rate in solid organ transplant (SOT) recipients [3]. Other risk factors including recent transplantation, corticosteroid use, mycophenolate use, triple immunosuppression, lymphopenia, and advanced age have also been associated with a suboptimal humoral response to COVID-19 vaccination in transplant recipients [2]. In contrast to the suboptimal seroconversion rates observed in lung transplant recipients after vaccination, convalescence after natural infection has been associated with an anti-spike IgG seroconversion rate of 85% in this population [4]. The reasons for this observed discordance, whether related to differences in the timing of antibody assessment after vaccination or infection, recovered patients representing a population enriched with more immunologically fit hosts, or true differences in the ability of virus and vaccine in eliciting a humoral response, have not been elucidated.

Suboptimal vaccine immunogenicity may predispose to increased rates of adverse outcomes in SOT recipients. In a recent series describing outcomes in transplant recipients who contracted COVID-19 after vaccination, 1 of 7 patients exhibited detectable anti-spike antibodies. Five of 7 patients required admission, a rate of hospitalization substantially higher than would be expected in immunocompetent hosts [5]. In another recent series describing 55 vaccinated SOT recipients, 27% required hospitalization, >10% required admission to the intensive care unit, and >5% died. A single patient in this series exhibited detectable anti-spike IgG prior to COVID-19 infection [6].

While studies like these demonstrate a substantial risk of adverse outcomes in SOT recipients despite vaccination, less clear is an optimal, standardized strategy to assess the

immunogenicity of vaccination and correlate immunogenicity with vaccine efficacy in this population. In the general population, mean neutralizing antibody titers after vaccination appear to correlate with protection from symptomatic infection [7]. However, the humoral response is not the only factor involved in patient outcomes. Patients with genetic defects resulting in the complete absence of B-cell function have recovered from infection [8]. Recent high-quality data suggest that convalescent plasma administered to patients at risk for adverse outcomes does not appear to prevent the progression of disease [9]. Monoclonal antibody therapy administered to ambulatory patients within 7 days of symptom onset appears to confer clinical benefit, but small numbers of immunocompromised hosts in some studies limit direct extrapolation to the transplant population [10]. Vaccination in lung transplant recipients has been shown to elicit detectable responses in CD4 and CD8 T-cells despite the absence of a detectable humoral response, but the clinical utility of T-cell assays in predicting vaccine efficacy has not been defined [2].

In this case, a transplant recipient experienced a fatal outcome despite the qualitative detection of anti-spike IgG related to vaccination and/or the response to COVID-19 infection. Whereas qualitative antibody detection may not correlate with outcomes, high absolute antibody levels generated during the course of infection correlate more strongly with decay in viral load and decreased mortality [11]. Furthermore, a rapid humoral response may also correlate with a lower risk of mortality [12]. Suboptimal vaccine response, rapid decline in immunity after vaccination, and a delayed, less robust response to infection are all factors that may have contributed to this patient's severe disease. The clinical significance of absolute anti-spike IgG levels identified in the transplant population may be more challenging to ascertain without the availability of a standardized assay allowing providers to correlate immunogenicity with vaccine efficacy.

In an effort to address the suboptimal response to vaccination observed in immunocompromised hosts, the Centers for Disease Control and Prevention recently recommended that SOT recipients who previously received 2 doses of either the BNT162b2 or mRNA-1273 vaccine should receive a third dose [13]. Compared to a 2-dose schedule, the administration of 3 doses of the BNT162b2 vaccine in high-risk patients has been associated with decreased rates of infection including severe illness [14]. In SOT recipients, the administration of 3 doses of the mRNA-1273 vaccine appears to result in enhanced humoral and T-cell responses [15]. Based on recent data demonstrating improved immunogenicity and high efficacy after repeat dosing, forthcoming guidelines may recommend that immunocompromised hosts receive a second dose of the Ad26.COVS vaccine [16].

Finally, this case underscores the risk of secondary infections in immunocompromised patients afflicted with COVID-19. This patient's duration of intubation predisposed to pneumonia related to *Pseudomonas aeruginosa*. This pathogen is more frequently isolated from lung transplant recipients [17]. In cases of definitively proven secondary bacterial pneumonia occurring during the course of severe COVID-19 infection, *P aeruginosa* is commonly identified [18]. The simultaneous isolation of both *Candida* and *Clostridium* species from blood suggested a polymicrobial source of infection in this case. These pathogens often associated with abdominal infection correlated with the marked bowel pathology observed on imaging. Intestinal complications including perforation have been associated with COVID-19 infection [19]. Though profound shock may have contributed to the bowel pathology noted in this case, the most prominently affected portion of the bowel appeared proximal to Sudeck's point, a site classically associated with watershed ischemia [20]. Serum CMV viral loads may not always correlate well with invasive gastrointestinal disease, but it is more likely that the low level identified in this case represented nonspecific, mild reactivation in the setting of critical illness. This finding highlights the importance of carefully monitoring for CMV reactivation at weekly intervals in SOT recipients receiving augmented immunosuppression [21]. Interleukin 6 (IL-6) antagonism has been associated with intestinal pathology including perforation both in patients with rheumatologic conditions and those with COVID-19 [22, 23]. Clinical symptoms in this scenario may be muted and atypical. Although tocilizumab administration may have a role in the treatment of severe COVID-19, multiple prominent studies assessing the efficacy of this intervention have excluded transplant recipients from enrollment [24, 25]. In the absence of more substantive studies assessing the role of biologic therapy in immunocompromised hosts, providers should exercise caution when considering agents such as tocilizumab in transplant recipients. Clinicians should have a lower threshold to evaluate for intra-abdominal pathology in patients with COVID-19 experiencing clinical decompensation, especially in hosts with immunocompromising conditions and those receiving IL-6 antagonists.

In light of recent trends in the spread of the B.1.617.2 (Delta) variant as well as novel variants that may represent the end result of recombination events, this work emphasizes the ongoing importance of more conservative precautions to avoid COVID-19 infection in transplant recipients [26].

Notes

Patient consent. Per the guidelines of the University of Virginia Institutional Review Board, patient consent was not required for the creation of this publication. Patient information was de-identified in accordance with University of Virginia Institutional Review Board practice.

Data availability. All data used in the creation of this work are available in the public domain.

Financial support. The Division of Infectious Diseases and International Health at the University of Virginia supported the publication of this work.

Potential conflicts of interest. All authors: No reported conflicts of interest.

All authors have submitted the ICMJE Form for Disclosure of Potential Conflicts of Interest. Conflicts that the editors consider relevant to the content of the manuscript have been disclosed.

References

1. Chong P, Handler L, Weber DJ. A systematic review of safety and immunogenicity of influenza vaccination strategies in solid organ transplant recipients. *Clin Infect Dis* **2018**; 66:1802–11.
2. Aslam A, Danziger-Isakov L, Mehra MR. Vaccination immune paresis in heart and lung transplantation. *J Heart Lung Transplant* **2021**; 40:763–6.
3. Boyarsky BJ, Chiang TP, Ou MT, et al. Antibody response to the Janssen COVID-19 vaccine in solid organ transplant recipients. *Transplantation* **2021**; 105:e82–3.
4. Havlin J, Svorcova M, Dvorackova E, et al. Immunogenicity of BNT162b2 mRNA COVID-19 vaccine and SARS-CoV-2 infection in lung transplant recipients. *J Heart Lung Transplant* **2021**; 40:754–8.
5. Wade HM, Gonwa TA, Leoni JC, et al. COVID-19 infection in solid organ transplant recipients after SARS-CoV-2 vaccination. *Am J Transplant* **2021**; 21:3496–9.
6. Caillard S, Chavarot N, Bertrand D, et al; French Society of Transplantation. Occurrence of severe COVID-19 in vaccinated transplant patients. *Kidney Int* **2021**; 100:477–9.
7. Khoury DS, Cromer D, Reynaldi A, et al. Neutralizing antibody levels are highly predictive of immune protection from symptomatic SARS-CoV-2 infection. *Nat Med* **2021**; 27:1205–11.
8. Soresina A, Moratto D, Chiarini M, et al. Two X-linked agammaglobulinemia patients develop pneumonia as COVID-19 manifestation but recover. *Pediatr Allergy Immunol* **2020**; 31:565–9.
9. Korley F, Durkalski-Mauldin V, Yeatts SD. Early convalescent plasma for high-risk outpatients with COVID-19 [manuscript published online ahead of print 18 August 2021]. *N Engl J Med* **2021**. doi:10.1056/NEJMoa2103784.
10. Weinrich D, Sivapalasingam S, Norton T. REGEN-COV antibody combination and outcomes in outpatients with Covid-19 [manuscript published online ahead of print 29 September 2021]. *N Engl J Med* **2021**. doi:10.1056/NEJMoa2108163.
11. Ren L, Fan G, Wu W, et al. Antibody responses and clinical outcomes in adults hospitalized with severe coronavirus disease 2019 (COVID-19): a post hoc analysis of LOTUS China trial. *Clin Infect Dis* **2021**; 72:e545–51.
12. Lucas C, Klein J, Sundaram ME, et al; Yale IMPACT Research Team. Delayed production of neutralizing antibodies correlates with fatal COVID-19. *Nat Med* **2021**; 27:1178–86.
13. Centers for Disease Control and Prevention. COVID-19 vaccines for moderately to severely immunocompromised people. **2021**. <https://www.cdc.gov/coronavirus/2019-ncov/vaccines/recommendations/immuno.html>. Accessed 5 October 2021.
14. Bar-On Y, Goldberg Y, Mandel M. Protection of BNT162b2 vaccine booster against COVID-19 in Israel. *N Engl J Med* **2021**; 385:1393–400.
15. Hall VG, Ferreira VH, Ku T, et al. Randomized trial of a third dose of mRNA-1273 vaccine in transplant recipients. *N Engl J Med* **2021**; 385:1244–6.
16. Johnson & Johnson. Johnson & Johnson announces real-world evidence and phase 3 data confirming strong and long-lasting protection of single-shot COVID-19 vaccine in the U.S. **2021**. <https://www.jnj.com/johnson-johnson-announces-real-world-evidence-and-phase-3-data-confirming-strong-and-long-lasting-protection-of-single-shot-covid-19-vaccine-in-the-u-s>. Accessed 5 October 2021.

17. Hogan J, Hill BK, Sifri CD. *Pseudomonas aeruginosa* infections in transplant: epidemiology and emerging treatment options. In: Morris MI, Kotton CN, Wolfe C, eds. *Emerging Transplant Infections*. Cham, Switzerland: Springer; **2021**.
18. Clancy CJ, Schwartz IS, Kula B, Nguyen MH. Bacterial superinfections among persons with coronavirus disease 2019: a comprehensive review of data from postmortem studies. *Open Forum Infect Dis* **2021**; 8:ofab065.
19. Al Argan RJ, Alqatari SG, Al Said AH, et al. Gastrointestinal perforation secondary to COVID-19: case reports and literature review. *Medicine (Baltimore)* **2021**; 100:e25771.
20. Brandt LJ, Feuerstadt P, Blaszka MC. Anatomic patterns, patient characteristics, and clinical outcomes in ischemic colitis: a study of 313 cases supported by histology. *Am J Gastroenterol* **2010**; 105:2245–52; quiz 2253.
21. Kotton CN, Kumar D, Caliendo AM, et al; Transplantation Society International CMV Consensus Group. The third international consensus guidelines on the management of cytomegalovirus in solid-organ transplantation. *Transplantation* **2018**; 102:900–31.
22. Strangfeld A, Richter A, Siegmund B, et al. Risk for lower intestinal perforations in patients with rheumatoid arthritis treated with tocilizumab in comparison to treatment with other biologic or conventional synthetic DMARDs. *Ann Rheum Dis* **2017**; 76:504–10.
23. Bruce-Hickman D, Sajeed SM, Pang YH. Bowel ulceration following tocilizumab administration in a COVID-19 patient. *BMJ Open Gastroenterol* **2020**; 7:e000484.
24. REMAP-CAP Investigators. Interleukin-6 receptor antagonists in critically ill patients with COVID-19. *N Engl J Med* **2021**; 384:1491–502.
25. Rosas IO, Bräu N, Waters M, et al. Tocilizumab in hospitalized patients with severe Covid-19 pneumonia. *N Engl J Med* **2021**; 384:1503–16.
26. Hacısuleyman E, Hale C, Saito Y, et al. Vaccine breakthrough infections with SARS-CoV-2 variants. *N Engl J Med* **2021**; 384:2212–8.