




Contents lists available at ScienceDirect

JPRAS Open

journal homepage: <http://www.journals.elsevier.com/jpras-open>

## Original Article

# Dual plane breast implant reconstruction in large sized breasts: How to maximise the result following first stage total submuscular expansion

Giuseppe Giudice, Michele Maruccia, Eleonora Nacchiero, Rossella Elia, Paolo Annoscia, Michelangelo Vestita \*

Section of Plastic and Reconstructive Surgery, Department of Emergency and Organ Transplantation, University of Bari, 11, Piazza Giulio Cesare, Bari, 70124, Italy

## ARTICLE INFO

*Article history:*

Received 23 May 2017

Accepted 20 November 2017

Available online 31 January 2018

*Keywords:*

Breast

Reconstruction

Dual plane

Two stages

Expander

Volume mismatch

## ABSTRACT

*Introduction:* Women who were good candidates for a skin reducing mastectomy, but were instead treated with a skin-sparing mastectomy and reconstruction with expanders, show discrepancy of volume and form between the healthy breast (voluminous and ptotic) and the expanded mastectomy envelope and muscle, which has a smaller size as well as excessive amount of skin at the lower pole.

*Methods:* From January 2014 to March 2015, we recruited 18 women with breasts of medium to large volume and with moderate to severe ptosis, already treated at a different centre with a one-side mastectomy and reconstruction by means of an expander. These women were treated at our unit for the second reconstructive step with a dual plane technique and a contralateral reduction/mastopexy.

*Results:* The minimum duration of follow-up was 2 years (range 24–30 months). The average volume of the implants was 613 g. The reconstructive outcome at the final follow-up (at least 24 months) was judged by the specialist as excellent in 5 cases, very good in 10 cases and good in 3 cases. Breast Q average score was 87.08.

*Discussion:* The disinsertion of the expanded muscle dome and the use of a dual plane technique for the placement of the definitive implant provide a solution to the skin-volume mismatch problem. The subcutaneous placement of the implant at the level of the lower pole extends the excessive amount of skin and gives the

\* Corresponding author. Section of Plastic and Reconstructive Surgery, Department of Emergency and Organ Transplantation, University of Bari, 11, Piazza Giulio Cesare, Bari, 70124, Italy.  
E-mail address: [michelangelovestita@gmail.com](mailto:michelangelovestita@gmail.com) (M. Vestita).

<https://doi.org/10.1016/j.jpra.2017.11.003>

2352-5878/© 2017 The Author(s). Published by Elsevier Ltd on behalf of British Association of Plastic, Reconstructive and Aesthetic Surgeons. This is an open access article under the CC BY-NC-ND license (<http://creativecommons.org/licenses/by-nc-nd/4.0/>).

reconstructed breast fullness and natural ptosis. Further validation of our results is needed.

© 2017 The Author(s). Published by Elsevier Ltd on behalf of British Association of Plastic, Reconstructive and Aesthetic Surgeons. This is an open access article under the CC BY-NC-ND license (<http://creativecommons.org/licenses/by-nc-nd/4.0/>).

## Introduction

Breast reconstruction is today an integral part of the therapeutic management of breast cancer.<sup>1</sup> The reconstructive process can be initiated at the time of mastectomy and implies, in about 70% of cases, the insertion of a skin expander.<sup>2</sup> Once a sufficient expansion is reached, the process is continued, in a second stage, with the replacement of the breast expander with the final implant. The ideal candidates for this type of reconstruction are patients with breasts of small to medium volume. In contrast patients with breasts of medium to large size and with ptosis, can undergo a skin reducing mastectomy and immediate reconstruction with prosthetic implants.<sup>3–11</sup>

Given the above, women have come to our attention, who, although they were candidates for a skin reducing mastectomy, were instead treated with a skin-sparing mastectomy and reconstruction with expanders. The result was a considerable discrepancy of volume and shape between the healthy breast (voluminous and ptotic) and the expanded mastectomy envelope and underlying muscle, which presented a smaller size as well as excessive amount of skin at the lower pole. In these cases, in order to be able to replace the skin expander with an implant of greater volume, while making use of the excess tissue at the lower pole, we carried out a definitive reconstruction by means of a dual plane technique.

## Materials and methods

From January 2014 to March 2015, we recruited 18 women with breasts of medium to large volume and with moderate to severe ptosis, already treated at a different centre with a one-side mastectomy and reconstruction by means of an expander. These women were treated at our unit for the second reconstructive step: replacement of the breast expander and insertion of the final implant. The characteristics of the study population are summarized in [Table 1](#). All patients had completed the skin expansion (average volume: 500 cc) and had an excess of skin at the lower pole of the expanded breast (pinch test >2 cm) with a healthy breast of large volume and medium to severe ptosis. The average age of our patients was 53 years (range 50–58 years); 14 patients were overweight (BMI 25–29.9 kg/m<sup>2</sup>), 4 were class 1 obese (BMI 30–34.9 kg/m<sup>2</sup>). Patients with a smoking habit or those with severe comorbidities (diabetes, renal insufficiency, congestive heart condition, chronic liver disease, metabolic diseases) were excluded. None of the patients had been treated with adjuvant radiotherapy.

In all cases breast expanders were replaced with silicone anatomical implants and all patients further underwent at the same time contralateral adjustment by means of breast reduction or mastopexy. Patients were regularly followed up and the reconstructive and aesthetic outcomes were defined by clinical and photographic assessment. The Breast Q questionnaire was used to assess the surgical outcome by the patients' perspective. Early and late complications were also assessed and recorded.

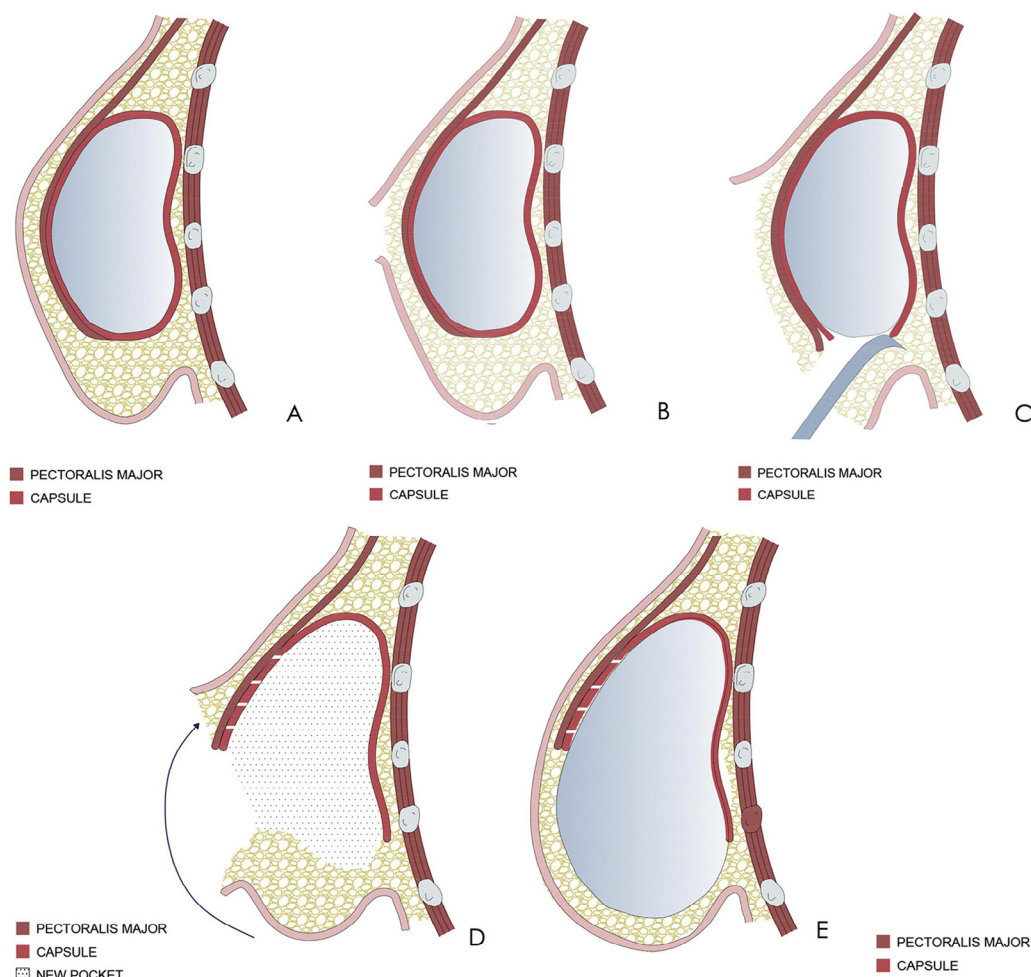
### *Surgical technique (Figure 1)*

The replacement of the breast expander with the final implant was performed in all patients with a dual plane technique. This technique provides access to the expanded submuscular pocket through the previous surgical scar. The skin flap inferior to the mastectomy scar is separated off the muscle down to the inframammary fold. The expanded muscle dome, thus exposed, is disconnected at the level of its lower margin from the costal plane. Equatorial capsulotomy and fenestration of the capsule

**Table 1**  
Characteristics and outcomes of the population in study.

Patient	Age (y)	BMI	Stage	Treatment	Comorbidities	Complications	Breast Q (2 years)	Physician assessment (2years)	Revision surgery	Follow-up (months)
1	50	25	pT2N1Mx	TER left+ MP right	None	–	91,5	Excellent	No	24
2	52	26,7	pT2N0Mx	TER left+ T right	None	–	89,6	Very good	Fat graft	24
3	50	26,5	pT2N1Mx	TER left+ MP right	None	–	87,5	Very good	No	24
4	58	32,4	pT1bN0Mx	TER right+ MP left	Hypertension Hypercholesterolemia	–	87,3	Very good	No	24
5	54	28,2	pT1bN1Mx	TER right+ MP left	Hypothyroidism	–	86,7	Very good	No	24
6	57	33,1	pT2N1Mx	TER right+ T left	Hypertension	Hypertrophic scars	79,2	Good	No	26
7	56	29,3	cT3N1Mx	TER right+ T left	None	–	83,8	Very good	No	26
8	56	28,7	pT2N1Mx	TER left+ T right	Hypertension	–	85,5	Very good	Fat graft	27
9	52	25,8	pT2N1Mx	TER left+ MP right	None	–	90,2	Excellent	No	30
10	55	25,7	pT1bN0Mx	TER right+ MP left	Hypercholesterolemia	–	89,8	Excellent	No	24
11	48	28,3	pT1bN0Mx	TER right+ T left	None	Hypertrophic scars	84,1	Very good	NO	26,3
12	54	27	pT2N1Mx	TER left+ MP right	None	–	85,6	Very good	No	28,5
13	49	27,9	pT2N1Mx	TER left+ MP right	Hypothyroidism	–	88,9	Very good	Fat graft	24
14	50	26,5	pT1bN1Mx	TER right+ T left	None	–	89	Excellent	No	24
15	53	25,5	pT2N1Mx	TER right+ T left	None	–	86	Excellent	No	24
16	57	33,1	pT2N0Mx	TER right+ T left	Hypertension Hypercholesterolemia	–	92,2	Good	Fat graft	26
17	56	32,6	pT2N0Mx	TER right+ T left	None	–	81,5	Good	No	29
18	47	26,9	pT1bN0Mx	TER left+ MP right	Hypothyroidism	–	89,2	Very good	No	28,5

TER: tissue expander replacement; MP: mastopexy; T: T-inverted breast reduction.

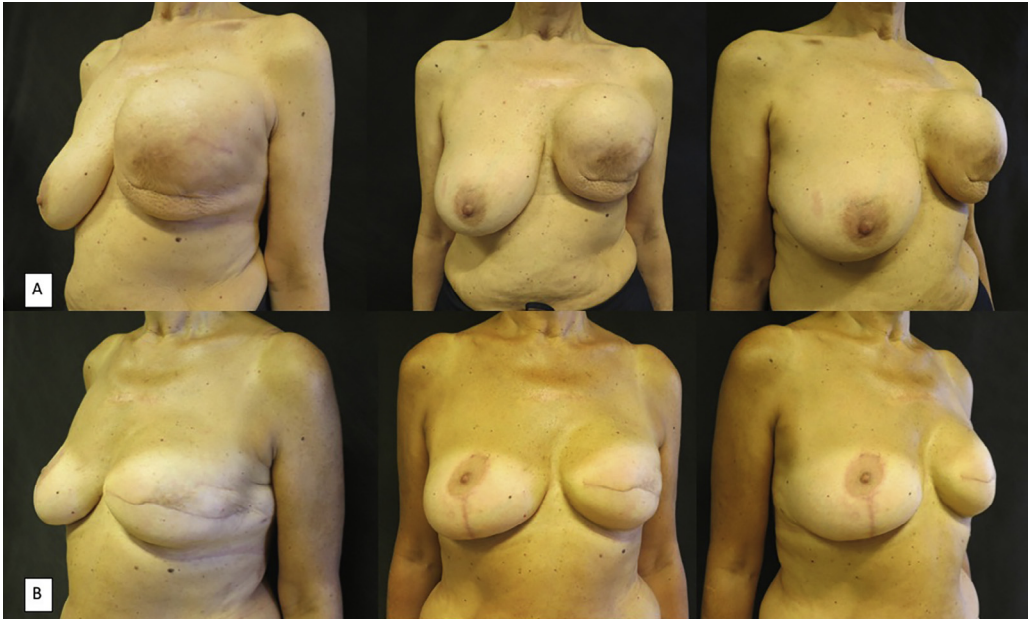


**Figure 1.** A) The figure shows the result of the first reconstructive step with the tissue expander. Note the thickness of the lower pole of the breast. B) Incision along the previous surgical scar. C) Exposure of the expanded muscle pocket and disinsertion of the expanded muscle dome at the level of the lower margin from the costal plane. D) Removal of the breast expander. At this time capsulotomy is performed. The dual plane pocket is created by releasing the muscle and the implant is covered inferiorly with the advancement of the lower pole skin flap. E) Placing of the final implant. Skin closure.

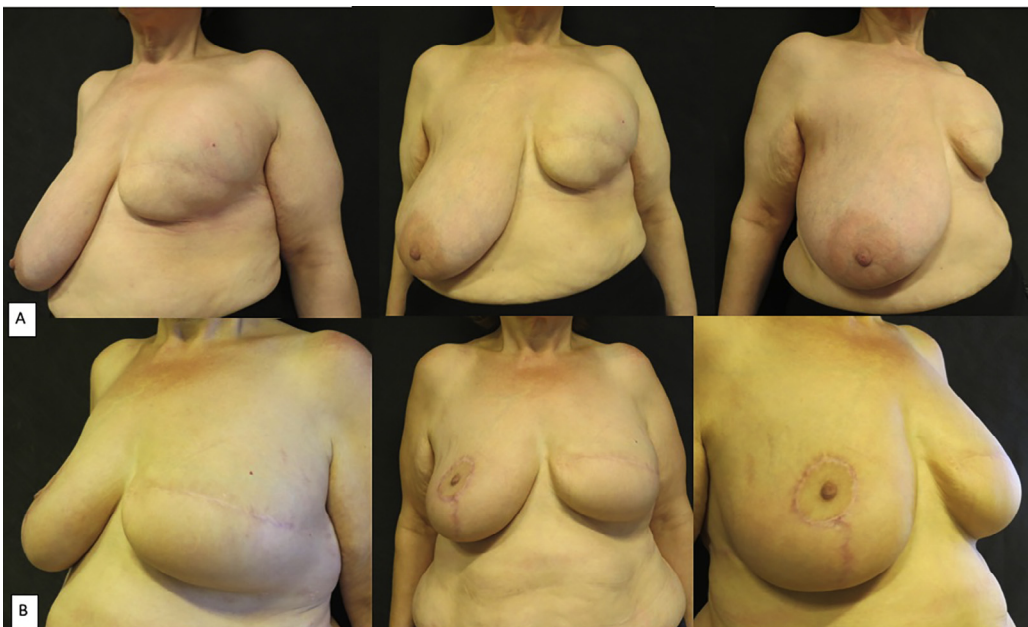along the lower margin of the pectoralis major muscle are carried out. A dual plane pocket is thus defined, in which the implant remains submuscular in the upper pole which is enlarged by the capsulotomy and then becomes subcutaneous inferiorly by advancing the skin flap of the lower pole, allowing for the placement of a definitive implant of a greater volume compared to the volume reached during expansion. Please note that subcutaneous thickness  $>2$  cm is a key element for the successful and safe application of this technique. The choice of the size of the implant is made by objective pre-surgical examination and with the help of sizers. A suction drainage is positioned in all cases.

### Results (Figures 2–4)

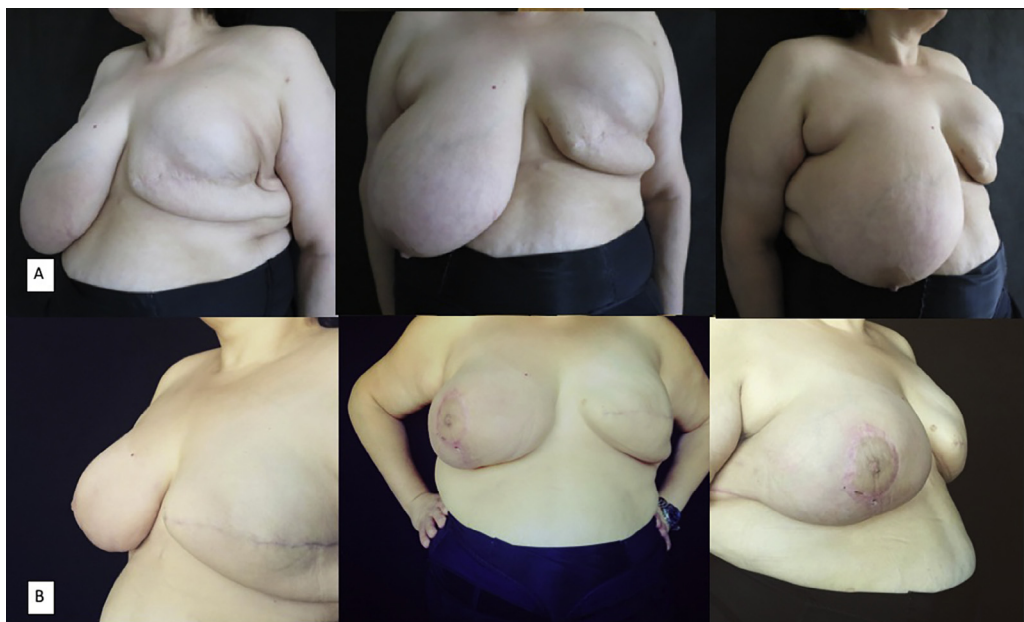The minimum duration of follow-up was 2 years (range 24–30 months). The average volume of the implants was 613 g. In no case we encountered early complications (haematoma, seroma,



**Figure 2.** A) A 65-year-old patient presented with unilateral breast reconstruction by means of an expander (550 cc) and contralateral moderate breast ptosis. B) Postoperative views show the result 24 months postoperatively.



**Figure 3.** A) A 58-year-old patient presented with unilateral breast reconstruction by means of an expander (450 cc) and contralateral severe breast ptosis. B) Postoperative views show the result 30 months postoperatively.



**Figure 4.** A) A 49-year-old patient presented with unilateral breast reconstruction by means of an expander (450 cc) and contralateral severe breast ptosis. Note the excess of skin at the lower pole of the expanded breast. B) Postoperative views show the result 24 months postoperatively.

perioperative infection, surgical scar dehiscence); there were no cases of capsular contracture or visibility of the prosthetic implant. In 2 cases we observed hypertrophic scars development, treated by application of silicone gel and dye laser. In 4 cases, 6 to 9 months after the definitive reconstruction by prosthetic implant, the patients underwent lipofilling to optimize the volumetric symmetry between the two breasts. All the patients underwent a contralateral breast mastopexy or reduction at the same time of the second step of reconstruction with a septum-based mammoplasty and no complications (the average weight reduction was 383 g). The reconstructive outcome at the final follow-up (24 months minimum) was judged by the specialist as excellent in 5 cases, very good in 10 cases and good in 3 cases. Breast Q average score was 87.08 (Table 1).

## Discussion

Skin reducing mastectomy was introduced for single-stage reconstruction (direct-to-implant) of voluminous and ptotic breasts. It is considered a safe surgical oncological procedure and capable to yield an aesthetic result of excellent quality.<sup>3–11</sup> However, in everyday clinical practice it may happen to be challenged by women with macromastia, who were already treated with a skin-sparing mastectomy and reconstruction with a breast expander.<sup>12,13</sup> Such patients often experience a marked disproportion between a redundant skin cover around the lower pole and the breast volume to be rebuilt. Even more, in overweight or obese women, the pectoralis major muscle has a relatively small size compared to the size of the desired implant,<sup>14</sup> and the positioning of the final implant inside the expanded muscle pocket does not allow to make use of the excessive skin at the lower pole with the goal to increase the final volume and to obtain a better symmetry. In fact, in these cases the disinsertion of the expanded muscle dome and the use of a dual plane technique for the placement of the definitive implant provide a solution to the skin-volume mismatch problem. The new enlarged pocket allows for the positioning of a definitive implant of greater volume compared to the one which could have been fitted into the previously expanded muscle pocket. The subcutaneous placement of the implant

at the level of the lower pole extends the excessive amount of skin and gives the reconstructed breast fullness and natural ptosis.

In conclusion, the good aesthetic and reconstructive results, reported by both physicians and patients, indicate the possible usefulness of this dual plane technique in cases of women with voluminous and ptotic breasts who originally underwent breast reconstruction with skin expanders.

Our results, although encouraging, need further validation on a larger sample of patients and possibly longer follow-up.

### Conflict of interest

None.

### Funding sources

None.

### References

1. Toth BA, Lappert P. Modified skin incisions for mastectomy: the need for plastic surgical input in preoperative planning. *Plast Reconstr Surg*. 1991;87:1048–1053.
2. American Society of Plastic Surgeons. ASPS 2014 Plastic Surgery Statistics Report. 2015. <https://www.plasticsurgery.org/documents/News/Statistics/2014/plastic-surgery-statistics-full-report-2014.pdf>. Accessed April 2017.
3. Hammond DC, Capraro PA, Ozolins EB, Arnold JF. Use of skin-sparing reduction pattern to create a combination skin-muscle flap pocket in immediate breast reconstruction. *Plast Reconstr Surg*. 2002;110:206–211.
4. Hudson DA, Skoll PJ. Complete one-stage, immediate breast reconstruction with prosthetic material in patients with large or ptotic breasts. *Plast Reconstr Surg*. 2002;110:487–493.
5. Nava MB, Cortinovia U, Ottolenghi J, et al. Skin-reducing mastectomy. *Plast Reconstr Surg*. 2006;118:603–610.
6. Losken A, Collins BA, Carlson GW. Dual-plane prosthetic reconstruction using the modified wise pattern mastectomy and fasciocutaneous flap in women with macromastia. *Plast Reconstr Surg*. 2010;126:731–738.
7. Salgarello M, Visconti G, Barone-Adesi L, et al. Inverted-T skin reducing mastectomy with immediate implant reconstruction using the submuscular-subfascial pocket. *Plast Reconstr Surg*. 2012;130:31–41.
8. Irwin GW, Black A, Refsum SE, McIntosh SA. Skin-reducing mastectomy and one-stage implant reconstruction with a myodermal flap: a safe and effective technique in risk-reducing and therapeutic mastectomy. *Plast Reconstr Surg*. 2013;66:1188–1194.
9. De Vita R, Pozzi M, Zoccali G, et al. Skin-reducing mastectomy and immediate breast reconstruction in patients with macromastia. *J Exp Clin Cancer Res*. 2015;34:120.
10. Maruccia M, Mazzocchi M, Dessy LA, Onesti MG. One-stage breast reconstruction techniques in elderly patients to preserve quality of life. *Eur Rev Med Pharmacol Sci*. 2016;20:5058–5066.
11. Maruccia M, Di Taranto G, Onesti MG. One-stage muscle-sparing breast reconstruction in elderly patients: a new tool for retaining excellent quality of life. *Breast J*. 2017;doi:10.1111/tbj.12860.
12. Dessy LA, Maruccia M, Mazzocchi M, Scuderi N. Treatment of post mastectomy pain syndrome after mastopexy with botulinum toxin. *J Plast Reconstr Aesthetic Surg*. 2014;67:873–874.
13. Troccola A, Maruccia M, Dessy LA, Onesti MG. Cortisone-induced gigantomastia during chemotherapy. *G Chir*. 2011;32:266–269.
14. Kobraei EM, Cauley R, Gadd M, et al. Avoiding breast animation deformity with pectoralis-sparing subcutaneous direct-to-implant breast reconstruction. *Plast Reconstr Surg Glob Open*. 2016;4:e708.