



Case Report

Successful management of a giant unruptured mycotic coronary artery aneurysm after coronary angioplasty



Pankaj Aggarwal*, Pravin Saxena, Anil Bhan

Department of Cardiothoracic and Vascular Surgery, Medanta – The Medicity, Gurgaon, Haryana, India

ARTICLE INFO

Article history:

Received 8 January 2016

Accepted 14 August 2016

Available online 24 August 2016

Keyword:

Mycotic coronary artery aneurysm

ABSTRACT

Coronary artery stent infection has been reported with both bare metal stent and drug eluting stent and can present as mycotic coronary artery aneurysm, pseudoaneurysm, myocardial abscess, pericarditis or exudative effusion. Infection at the site of coronary stent implantation is rare and is believed to result typically from either direct stent contamination at the time of delivery or transient bacteraemia from access site. Introduction of drug-eluting stent (DES) has led to a marked reduction in the problem of in-stent restenosis across all patient subsets and lesions complexities. Recently, several case reports of pseudoaneurysm formation after DES implantation have been reported in the literature. We describe the successful surgical management of giant mycotic pseudoaneurysm of left anterior descending artery (LAD) presenting as fever of unknown origin. This report illustrates the importance of early detection and prompt management of these rare coronary pseudoaneurysms, which is a highly lethal condition.

© 2016 Cardiological Society of India. Published by Elsevier B.V. This is an open access article under the CC BY-NC-ND license (<http://creativecommons.org/licenses/by-nc-nd/4.0/>).

1. Case report

A 51-year-old male presented with a history of a primary placement of drug eluting stent to LAD about a year back for a discrete block in mid LAD for acute myocardial infarction at some other hospital. Left ventricular ejection fraction (LVEF) at that time was normal. Patient was otherwise non-diabetic and non-hypertensive. One month after primary stenting to LAD and during routine follow-up, patient was detected to have developed pseudoaneurysm of LAD in 2D echocardiography. Diagnosis was reconfirmed on angiography and was managed by concerned cardiologist by putting a covered stent (nature of stent was not known in both cases). About 6 months after the redo PTCA, patient was admitted to the same hospital with complaints of generalized weakness and fever. Patient was discharged after a course of antibiotics. The LVEF on transthoracic echo had declined to 40%.

Six months later, patient was admitted at our hospital with high-grade fever and chest pain. An urgent echo revealed a large pseudoaneurysm of LAD projecting anterior to left ventricle and extending till pulmonary artery. The aneurysm was partially thrombosed. There was to and fro flow of blood through a narrow

neck. There was also global hypokinesia with LVEF of 20%. Only the inferior and lateral walls of LV were moving. There was mild to moderate mitral regurgitation (MR) also.

Blood cultures were sent and empirical antibiotics were started as per hospital infection protocol.

Coronary computed tomography angiography revealed a large 9 cm × 6 cm aneurysm of LAD (Fig. 1) with peripheral thrombus. The stent in artery was blocked with no distal flow seen in the artery. Left circumflex (LCX) was small. The stent was visible floating in the cavity of the pseudoaneurysm. The whole of left side of the heart had no large vessel on angiography. The right coronary artery was dominant, huge and supplying the inferior and lateral wall (Fig. 2).

Admission laboratory studies were notable for thrombocytopenia and an elevated Troponin I level. The electrocardiography showed poor progression of R wave in leads V1–V6.

The preliminary blood cultures reports were sterile. However, the fever was persisting in spite of 2 days of injectable Meropenam and Teicoplanin which were started empirically. By day 5 of admission, the patient had become afebrile. Final blood culture report after 5 days of incubation was also sterile. It was decided to operate on the patient.

On hospital day 6, patient was taken up for surgery. The intraoperative transesophageal echocardiography (TEE) confirmed the presence of a 7.5 cm pseudoaneurysm on the anterior surface of the heart with mild mitral regurgitation and a low LVEF of 20% (Fig. 3).

* Corresponding author at: Hno 3995, Janglian Street, Fazilka 152123, Punjab, India.

E-mail address: draggarwal.pankaj@gmail.com (P. Aggarwal).

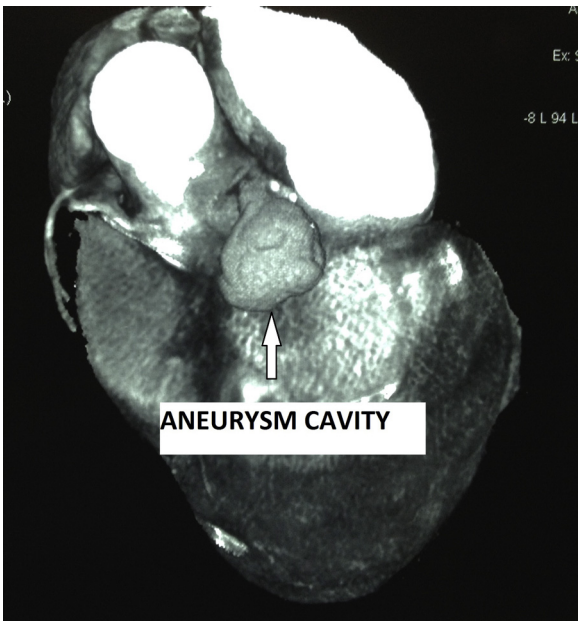


Fig. 1. CT angiography showing large aneurysmal cavity with narrow neck.

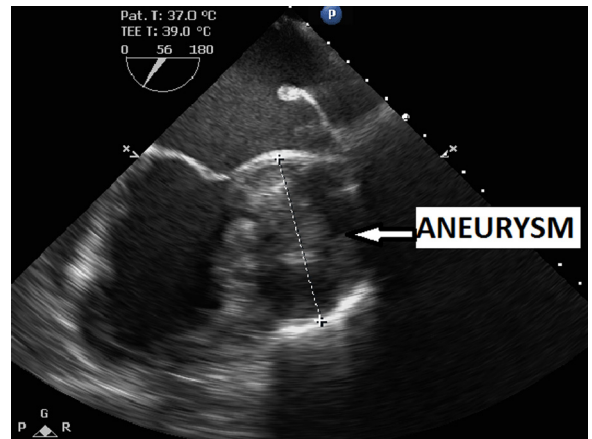


Fig. 3. Intraoperative TEE showing large aneurysm abutting LV wall.

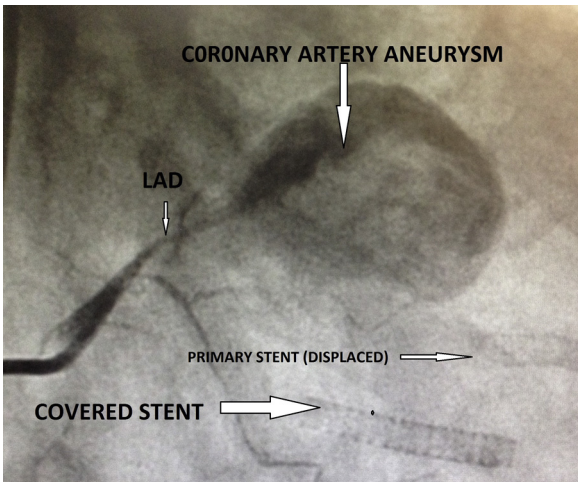


Fig. 2. Conventional catheter angiography showing dye from LAD entering into aneurysm. Two stents are also visible.

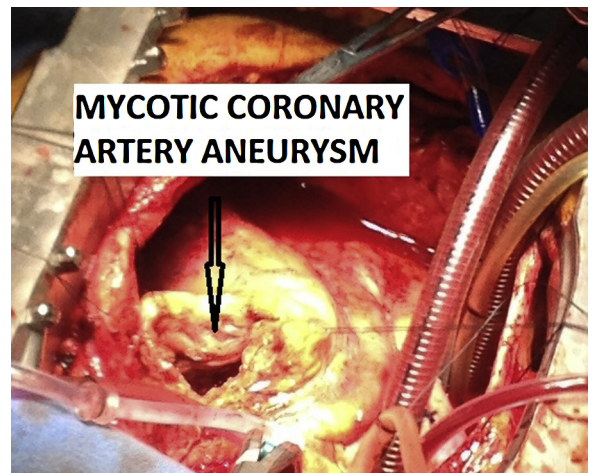


Fig. 4. Intraoperative view of opened coronary aneurysm.

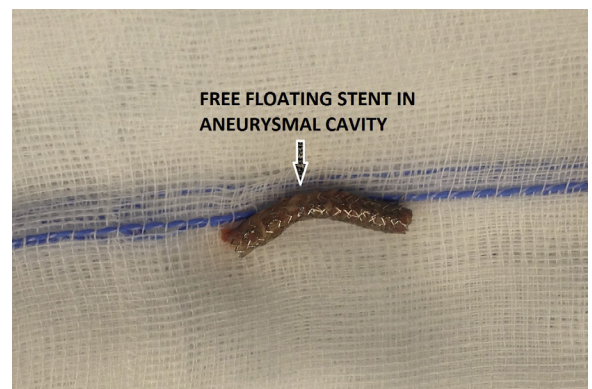

Fig. 5. The covered stent recovered from aneurysm cavity.

The patient underwent two-vessel coronary artery bypass and coronary pseudoaneurysmectomy. Intraoperative findings included extensive 8 cm pseudoaneurysm of the LAD (Fig. 4). The pseudoaneurysm was cleaned of the thrombus in which the stent was also found (Fig. 5). The primary stent could not be located. The thrombus and necrotic material was sent for culture and sensitivity. The narrow neck of the pseudoaneurysm was formed by proximal LAD. LAD opening in pseudoaneurysm was closed by pledgetted sutures. All necrotic tissue was excised, a reverse-saphenous vein graft (rSVG) to the first obtuse marginal branch and rSVG to LAD were grafted. The resected aneurysm wall was sent to pathology for further analysis. An intraaortic balloon pump (IABP) was placed before coming off cardiopulmonary bypass. TEE showed only mild MR not requiring any intervention. The operation was otherwise uneventful.

On postoperative day (POD) 1, the patient was extubated. By POD 3, EF had increased to 30% and the IABP was taken out.

The culture report of the pseudoaneurysm material showed pseudomonas infection which was sensitive to most antibiotics, including the ones he was already on.

Post-IABP removal, he had few episodes of non-sustained ventricular tachycardia.

So, an implantable cardioverter defibrillator was implanted and patient was discharged home on POD 15 on oral antibiotics for 8 weeks.

2. Discussion

The development of a mycotic coronary pseudoaneurysm is a rare entity being first reported by Bougon in 1812.^{1,2} The majority

of coronary pseudoaneurysms occur in the setting of atherosclerosis with congenital aneurysms, vasculitis (e.g., Kawasaki syndrome) and connective tissue disorders.^{1–3} A distinct occurrence is a mycotic coronary pseudoaneurysm (MCA) post-percutaneous coronary intervention (0.3–0.6%) with only 19 cases reported in the international literature.⁴ Mechanical factors, infection and inflammation are three major contributors reported to lead to the development of mycotic coronary pseudoaneurysms in these cases.⁴ The arterial wall injury caused by oversized balloons and stents might be the potential mechanical factors, *Staphylococcus aureus* is the primary infectious agent in the majority of cases. The direct stent contamination at the time of delivery, repeated femoral access and femoral artery sheaths left in place for a long duration may facilitate bacteraemia of *S. aureus*, which is a normal skin commensal.⁴ Late stent infection may be caused by drug-eluting stent related local problems like delayed endothelialization of the stent struts, inhibition of neointimal growth, late incomplete healing of any injury, stent apposition, and coronary aneurysm formation.^{5,6} Coronary pseudoaneurysms have been reported from 3 days to up to 4 years after DES implantation procedures, with varying clinical presentations.^{7,8}

Interestingly, our patient had pseudomonas infection which has also been reported by Chen et al.⁴ in 3 of 19 patients as etiological organism.

Potential complications secondary to mycotic coronary pseudoaneurysms include rupture, cardiac tamponade, fistulisation, myocardial ischemia or infarction secondary to septic embolization and sudden cardiac death.^{5,6}

In this case the huge mycotic pseudoaneurysm had formed slowly over a year after a breach in the LAD arterial wall following the percutaneous transluminal coronary angioplasty (PTCA) and subsequent pseudomonas bacteraemia from the infected stent.

Coronary ligation with resection appears to offer the most uncomplicated approach, assuming viable target vessels exist for grafting. Given the proximity of the LAD ostium and distal portion of the left main artery to the infected aneurysm, the proximal LAD was bypassed with an rSVG and another saphenous vein was grafted to obtuse marginal branch that was compressed by the

pseudoaneurysm. In view of low LVEF, dense adhesions of pericardium to chest wall and active infection in the area, internal mammary artery was not harvested. Without appropriate target vessels, the complexity of such a surgical approach increases significantly.

The unusual nature was because of the huge size, compression of the circumflex artery by aneurysm and infection of the aneurysm by pseudomonas in an otherwise healthy 51-year-old male. Given the limited experience with huge LAD pseudoaneurysm, clinical management is still evolving, as the majority of reported cases have been documented post-mortem.¹

As evidenced by this case, correlating findings between the CT angiogram, coronary angiogram and TEE is of paramount importance in the management of these rare coronary pseudoaneurysms. Early diagnosis, appropriate antibiotic therapy and prompt surgery remain the mainstay of current therapy.

Conflicts of interest

The authors have none to declare.

References

1. Mylonakis E, Calderwood SB. Infective endocarditis in adults. *N Engl J Med*. 2001;345:1318–1330.
2. Osevala MA, Heleotis TL, Dejene BA. Successful treatment of a ruptured mycotic coronary artery aneurysm. *Ann Thorac Surg*. 1999;67:1780–1782.
3. Briguori C, Sarais C, Sivieri G, et al. Polytetrafluoroethylene-covered stent and coronary artery aneurysms. *Catheter Cardiovasc Interv*. 2002;55:326–330.
4. Chen IC, Chao TH, Wu YH, Kan CD, Fang CC. Afebrile mycotic aneurysm with rupture in right coronary artery after bare-metal stent implantation: a case report and review of literature. *Acta Cardiol Sin*. 2012;28:344–348.
5. Matsumoto M, Konishi Y, Miwa S, et al. Mycotic aneurysm of the left coronary artery. *Ann Thorac Surg*. 1998;65:841–842.
6. Nonin S, Hasegawa T, Hirai H, Suehiro S, Yoshiyama M. Giant mycotic coronary aneurysm associated with late stent infection. *Eur Heart J Cardiovasc Imaging*. 2013;630.
7. Aoki J, Kirtane A, Leon MB, Dangas G. Coronary artery aneurysms after drug-eluting stent implantation. *JACC Cardiovasc Interv*. 2008;1(February (1)):14–21.
8. Kapur NK, Conte JV, Wittstein IS. Successful management of an unruptured mycotic coronary aneurysm. *J Invasive Cardiol*. 2007;19:E366–E368.