

Contents lists available at [ScienceDirect](#)

## International Journal of Surgery Case Reports

journal homepage: [www.casereports.com](http://www.casereports.com)Salpingo-ureteric fistula—A rare complication following laparoscopic surgery for colorectal cancer: A case report and literature review<sup>☆</sup>N. Nkwam<sup>a,\*</sup>, V. During<sup>b</sup>, T. Chen<sup>b</sup><sup>a</sup> Department of Urology, Lincoln County Hospital, United Lincolnshire Hospitals NHS Trust, Greetwell Road, Lincolnshire LN2 5QY, United Kingdom<sup>b</sup> Department of Urology, Worcestershire Royal Hospital, Worcestershire Acute Hospitals NHS Trust, Charles Hastings Way, Worcestershire WR5 1DD, United Kingdom

## ARTICLE INFO

## Article history:

Received 24 July 2013

Received in revised form 18 January 2014

Accepted 29 January 2014

Available online 7 February 2014

## Keywords:

Salpingo-ureteric  
Complication  
Fistula  
Fallopian tube  
Colorectal cancer  
Laparoscopic

## ABSTRACT

**INTRODUCTION:** We report the management and outcome of the case of a 57-year old woman with adenocarcinoma of the rectum. Following neo-adjuvant chemo-radiotherapy and laparoscopic-assisted anterior resection of her tumour she developed a right salpingo-ureteric fistula.**PRESENTATION OF CASE:** Three weeks following laparoscopic anterior resection of the tumour she presented with urinary frequency and incontinence. A ureteric stent was inserted and left in-situ for five months but the fistula did not heal. The patient underwent exploration and open repair of the salpingo-ureteric fistula which resolved her symptoms.**DISCUSSION:** There have not been many reported cases in the literature of salpingo-ureteric fistulae but after initial trial of management with ureteric stents all eventually required open exploration and repair. **CONCLUSION:** we advocate open repair of salpingo-ureteric fistulae as the definitive management following intra-operative injury.

© 2014 The Authors. Published by Elsevier Ltd on behalf of Surgical Associates Ltd. All rights reserved.

## 1. Introduction

The majority of ureteric injuries are iatrogenic and it has been reported that up to 73% are gynecological, with 14% and 13% resulting from general surgical and urological procedures, respectively.<sup>1</sup> One of the key factors in determining management and outcome with peri-operative ureteric injury is early recognition but this is not always apparent until patients present post-operatively with associated signs and symptoms. These can range from loin pain and intra-abdominal sepsis to renal failure<sup>2</sup> and also urinary incontinence in the rare cases of fistula formation as described here.

## 2. Presentation of case

A 57-year old woman was referred to the colorectal surgeons with a history of change in bowel habit and weight loss. Colonoscopy revealed an annular constricting carcinoma extending from the recto-sigmoid flexure 12 cm from the anal margin to 20 cm in the distal sigmoid. Both CT and MRI scan confirmed the presence of an extensive circumferential tumor in the upper

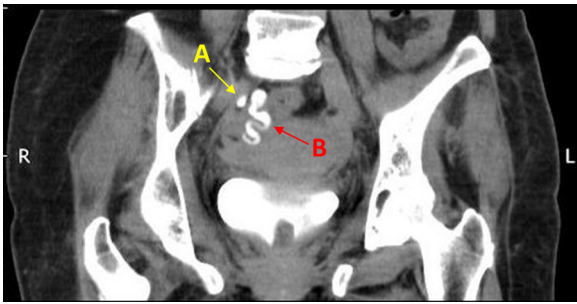
rectum extending to 6 cm from anal margin with enlarged pelvic lymph nodes with no distant metastases, making it a T4 N1 M0 recto-sigmoid adenocarcinoma, radiologically. Due to increasing obstructive bowel symptoms she had a 9 cm metal wall intra-luminal stent deployed via flexible sigmoidoscopy and onward referral to the oncologists for neo-adjuvant chemo-radiotherapy. She completed a 5 and a half week course of 50.4 Gy radiotherapy with oral daily capecitabine. There was slight improvement in her gastrointestinal symptoms and she remained without any lower urinary tract symptoms. Repeat MRI scan demonstrated reduction in size of the tumor with no development of metastases.

Seven weeks after completing her neo-adjuvant chemo-radiotherapy she underwent laparoscopic assisted anterior resection and defunctioning ileostomy. She was discharged on the fifth post-operative day without immediate complication. The final histology was Duke's C1, T3 N1 M0 moderately differentiated adenocarcinoma of the rectum. On out-patient review two weeks post-op her only complaint was that of urinary frequency so a urology referral was made. Now 3 weeks post-op she attended urology clinic troubled by urinary incontinence not associated with stress or urgency. Examination revealed pooling of urine in the vagina raising the possibility of a vesico-vaginal fistula. The patient was catheterised and a CT urogram demonstrated a leak from a stenosed distal right ureter ([Fig. 1\[A\]](#)) with drainage of contrast/urine via the right fallopian tube ([Fig. 1\[A\]](#)) into the uterus, then vagina. The proximal ureter was grossly dilated down to the stenosis ([Fig. 2\[A\]](#)) with contrast seen in the vagina ([Fig. 2\[B\]](#)). The next step was

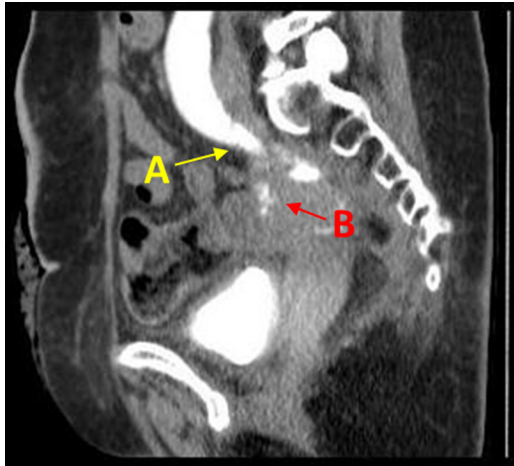
<sup>☆</sup> This is an open-access article distributed under the terms of the Creative Commons Attribution-NonCommercial-No Derivative Works License, which permits non-commercial use, distribution, and reproduction in any medium, provided the original author and source are credited.

\* Corresponding author. Tel.: +44 01522 512 512x3791.

E-mail address: [mnkwan@doctors.org.uk](mailto:mnkwan@doctors.org.uk) (N. Nkwam).

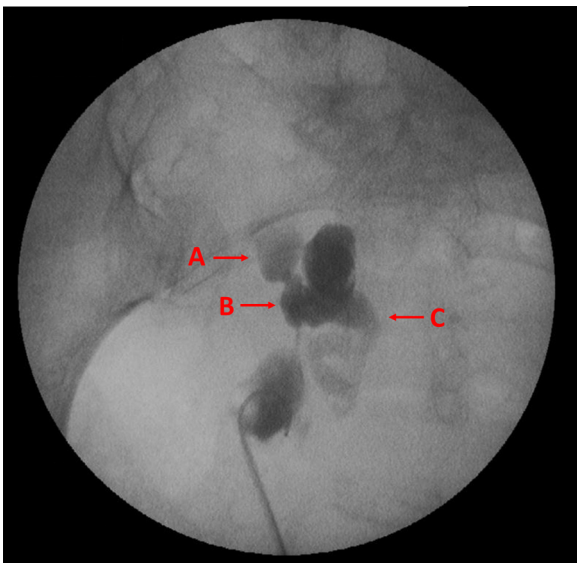


**Fig. 1.** CT urogram (coronal); (A) Contrast in right ureter; (B) contrast in right fallopian tube.

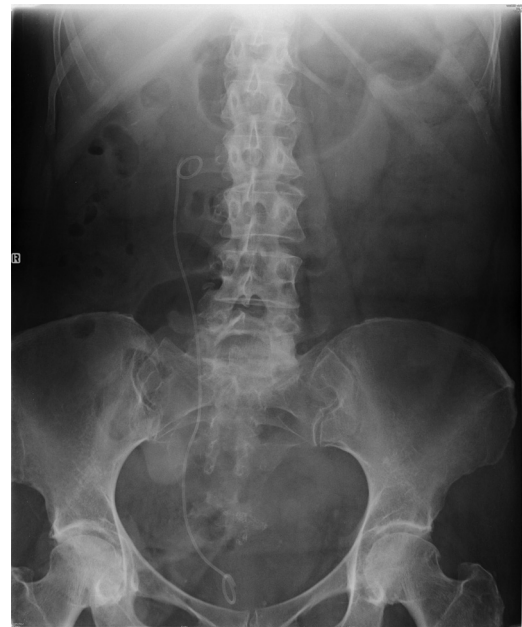

**Fig. 2.** CT urogram (sagittal); (A) gross right hydronephrosis down to stenosis; (B) contrast in vagina.

for right retrograde urography and ureteroscopy which demonstrated the appearance of a suture at the ureteric stricture, and right ureteric stent insertion. Fig. 3 illustrates the dilated right ureter proximally [A]; salpingo-ureteric fistula [B]; and outline of contrast-enhanced tortuous right fallopian tube [C]. A 4.5Fr, 26 cm



**Fig. 3.** Right retrograde urography; (A) proximal dilated right ureter; (B) salpingo-ureteric fistula; (C) outline of contrast-enhanced tortuous right fallopian tube.



**Fig. 4.** Right 6Fr, 24 cm ureteric stent in situ.

ureteric stent was negotiated over a guidewire into the right renal pelvis under X-ray guidance (Fig. 4).

Discussion at the multi-disciplinary team meeting advised that the patient have a trial of healing with the stent in situ during which time she could have adjuvant chemotherapy with oxaliplatin and 5-fluorouracil for her rectal cancer. The stent remained in situ-for five months, however, two days after its removal via flexible cystoscopy she was readmitted with right loin pain exacerbated by voiding and vomiting. A CT scan revealed severe hydronephrosis so she underwent urgent cystoscopy and right retrograde urography and 6Fr, 24 cm ureteric stent insertion. The retrograde urography again demonstrated extravasation of contrast at the lower third of the ureter with evidence of a ureteric stricture.

As a result of this failed trial of stenting the decision was made to perform a laparotomy and open repair which she had 6 weeks later. During this procedure the missing segment of the right ureter was retrieved from the area of the infundibulo-pelvic ligament down into the pelvis and this segment was bridged by the ureteric stent already in place and was surrounded by a cavity walled off by her right ovary and right fallopian tube. A right salpingo-oophorectomy and distal ureterectomy was performed at the site of the fistula which was at the level of the common iliac artery, and a large psoas hitch of the bladder was created prior to ureteroneocystostomy. Her ileostomy was also closed. Her stent was removed 8 weeks post-op and she has had no further urological complaints at 6 months follow-up.

### 3. Discussion

Many cases of fistulas between the fallopian tubes and the bowel have been reported in literature but very few between the fallopian tube and the urinary tract. A *pubmed* literature search using the keywords *salpingo-ureteral*, *salpingo-ureteric*, *fistula* and *fallopian tube* yielded just six cases between 1976 and 1993.

In 1988 Christmas and Badenoch<sup>3</sup> documented the case of a 59-year old woman presenting with right-sided abdominal pain pneumonephrosis on plain abdominal film. Endoscopic catheterisation of the right ureter revealed a blockage and the patient required laparotomy and right nephro-ureterectomy with the histology

confirming an inflammatory mass connecting the ureter to the right fallopian tube.

Huang et al.<sup>4</sup> reported on the CT appearance of a salpingo-ureteral fistula in a woman following laparoscopic laser surgery in endometriosis in 1992. The following year Braslis and Stephens<sup>5</sup> documented uretero-fallopian fistula as an unusual complication of open ureterolithotomy. In this particular case, the patient's main complaint was that of complete urinary incontinence post-op, similar to our reported case. She underwent stent insertion of a 7Fr multi-length ureteral pigtail catheter and her incontinence resolved completely. This was removed after 6 weeks but her symptoms promptly returned so the stent was re-inserted and left in situ for a further 6 months. Upon removal a further retrograde urography demonstrated persistence of the salpingo-ureteric fistula. A laparotomy was required and the fallopian tube was found to be densely adhered to the medial surface of the pelvic ureter. This segment was debrided and edges re-apposed along with a left salpingectomy and the patient made a full recovery post-op with resolution of her symptoms.

Steckel et al.<sup>6</sup> documented on a case of Uretero-fallopian tube fistula 3 weeks after laparoscopic fulguration of pelvic endometriosis. In this report, a 35-year old woman experienced abdominal pain and urinary incontinence. An intravenous urogram (IVU) revealed right hydronephrosis and a nephrostomy followed by nephrostogram demonstrated the fistula. An internal-external nephrostomy stent was left in situ for 6 weeks after which it was changed to a normal nephrostomy and clamped. Repeat antegrade study showed resolution of the fistula but a ureteric stricture was present and trials of clamping caused clinical deterioration and pyrexia. The patient eventually underwent laparotomy with excision of strictured ureteral segment and right ureteroneocystostomy and right salpingo-oophrectomy due to marked scar formation and endometriosis.

More recently, Crochet et al.<sup>7</sup> described the incident of a left uretero-fallopian fistula after surgery for endometriosis. Retrograde insertion of a left double-J ureteral stent was unsuccessful so a nephrostomy was inserted and a nephrostogram demonstrated contrast leak at the level of the iliac. This patient eventually underwent an exploratory laparotomy where a urosalpinx was excised and a left ureteroneocystostomy with psoas hitch was performed 8 weeks post-op.

#### 4. Conclusion

Fistula formation between the ureteric and gynecological tracts is well documented and, therefore, diagnosis of a salpingo-ureteric fistula should be considered in patients presenting with urinary

incontinence following abdominal surgery, be it open or laparoscopic. From our experience, such injuries are best managed with open repair of the fistula.

#### Conflict of interest

None.

#### Funding

None.

#### Ethical approval

Written informed consent was obtained from the patient for publication of this case report and accompanying images. A copy of the written consent is available for review by the Editor-in-Chief of this journal on request.

#### Author contributions

*N. Nkwam*: Reviewed patient in clinic; sourced case notes; wrote case report; performed literature search and literature review on the case.

*V. During*: Reviewed electronic case notes; described follow-up management; helped obtain written consent from patient to publish.

*T.F. Chen*: Identified patient's case; gave guidance to approach to the write-up of the case report; discussed literature review; reviewed patient in clinical setting.

#### References

- Lynch TH, Martínez-Piñero L, Plas E, Serafetinides E, Türkeri L, Santucci RA, et al. EAU guidelines on urological trauma. *Eur Urol* 2005;**47**(January (1)): 1–15.
- Abboudi H, Ahmed K, Royle J, Khan MS, Dasgupta P, N'Dow J. Ureteric injury: a challenging condition to diagnose and manage. *Nat Rev Urol* 2013;**10**(February (2)):108–15.
- Christmas TJ, Badenoch DF. Pneumonephrosis due to a fallopian tube/ureteric fistula. *Br J Urol* 1988;**62**(August (2)):187. Department of Surgery, London Hospital, London.
- Huang A, Fruauff A, Ferragamo M, Goffner L, Losada RA. Salpingoureteral fistula: CT appearance. *Urol Radiol* 1992;**14**(1):191–3.
- Braslis KG, Stephens DA. Uretero-fallopian fistula: an unusual complication of open ureterolithotomy. *J Urol* 1993;**150**(December (6)):1900–2.
- Steckel J, Badillo F, Waldbaum RS. Uretero-fallopian tube fistula secondary to laparoscopic fulguration of pelvic endometriosis. *J Urol* 1993;**149**(May (5)):1128–9.
- Crochet P, Savoie PH, Agostini A, Zaritsky E, Lechevallier E, Coulange C. Uretero-fallopian fistula after gynecological surgery for endometriosis: a case report. *J Minim Invasive Gynecol* 2008;**15**(January–February (1)):108–9.

#### Open Access

This article is published Open Access at [sciedirect.com](http://sciedirect.com). It is distributed under the [IJSCR Supplemental terms and conditions](#), which permits unrestricted non commercial use, distribution, and reproduction in any medium, provided the original authors and source are credited.