

OPEN

Systemic AA Amyloidosis Associated With Intravenous Injection of Oral Prescription Opioids—An Autopsy Case Report

Kenneth M. Zabel, MD,* Grace Y. Lin, MD, PhD,*
Rebecca E. Sell, MD,† and Omonigho Aisagbonhi, MD, PhD*

Abstract: There are reports of AA amyloidosis associated with intravenous and/or subcutaneous injection of street drugs, such as heroin and cocaine. Most reports describe patients with substance use disorder, renal amyloidosis and concurrent viral infections, such as hepatitis and/or human immunodeficiency virus. Herein, we present a case of systemic AA amyloidosis and sepsis in a 34-year-old woman with a history of intravenous injection of oral prescription medications (as evidenced by excipient lung disease) who had no known history of human immunodeficiency virus nor of hepatitis B or C. Our case shows the broader spectrum of pathology that can occur with the misuse of prescription medications.

Key Words: systemic amyloidosis, prescription opioids, autopsy, excipient lung disease, forensic pathology

(*Am J Forensic Med Pathol* 2022;43: 191–194)

A amyloidosis, also referred to as secondary amyloidosis, is a progressive disease caused by deposition of serum amyloid A protein, an acute phase reactant, on various organs and tissues secondary to chronic inflammation.^{1,2} Diseases that have been linked to AA amyloidosis include rheumatoid arthritis,^{3,4} inflammatory bowel disease,^{3,5} common variable immunodeficiency,^{6,7} and familial Mediterranean fever.⁸ AA amyloidosis has also been linked to subcutaneous and intravenous injection of illegal drugs, such as heroin and cocaine.^{9–18}

Herein, we present the autopsy findings of a woman with chronic pain, chronic kidney disease from biopsy-proven renal AA amyloidosis, heart failure with reduced ejection fraction and hypothyroidism, who developed sepsis and died. She was found to have excipient lung disease and systemic amyloidosis on autopsy. Our case highlights the spectrum of pathologies that can be associated with intravenous injection of oral medications.

CASE

A 34-year-old woman with a chronic sternal wound infection presented to the hospital with chest pain. She had open-heart surgery 10 years before repair a ventricular septal defect and noted exposed sternal wires. She was admitted multiple times over the past year for recurrent bacteremia but had developed chronic pain with opioid use disorder and had difficulty with adherence to prescribed therapy often leaving the hospital before completion of treatment,

occasionally leaving the hospital with a peripherally inserted central venous catheter line in place. Prior blood cultures had grown *Bacillus licheniformis*, *Lactobacillus rhamnosus*, *Acidovorax temperans*, *Rothia dentocariosa*, and *Candida tropicalis* on multiple different occasions. Over the course of 6 years, she had presented to the hospital on multiple occasions requesting intravenous pain medications and diphenhydramine. On admission 1 month before the current presentation, she had been prescribed hydromorphone and was observed storing the medication in her cheek and blanket. On the first day of the current admission, she was observed attempting to crush her prescribed oxycodone and diphenhydramine to self-administer through her peripheral intravenous line. Her recurrent polymicrobial infections were thought due to her intravenous self-administration of medications, which should have been taken orally. On this admission, she noted worsening shortness of breath and full body swelling in addition to her chest pain.

On evaluation, she had significant anasarca, a decreased ejection fraction on bedside echocardiogram, nephrotic range proteinuria (total protein: 600 mg/dL, 24 hours total: 15,951 mg), and a creatinine level of 2.86 mg/dL. A kidney biopsy showed amyloidosis diffusely involving the glomeruli and arterioles. Immunofluorescence studies were consistent with AA type, and this was confirmed with liquid chromatography tandem mass spectrometry, which identified a peptide profile consistent with AA-type amyloid deposition. She had additional biopsies of the stomach, duodenum, and colon, which showed amyloid deposition in the lamina propria.

During the hospitalization, she had a fever and blood cultures grew *Escherichia coli* while a urine culture grew methicillin-resistant *Staphylococcus aureus* (MRSA). She also had continued purulent drainage from her sternotomy scar wound, with wound culture positive for *Staphylococcus aureus*. While in the hospital, she developed positive blood cultures for *Candida dubliniensis* and was started on antifungal therapy. Her kidney disease worsened, and she was treated with an IL-6 inhibitor occasionally used in patients with AA amyloidosis because of chronic inflammatory states like rheumatoid arthritis. Her prescribed medications also included oxycodone, diphenhydramine, antibiotics (doxycycline), antifungals (fluconazole), and electrolytes (sodium chloride, potassium chloride), among others. However, she continued to deteriorate with worsening electrolyte abnormalities, because of poor nutritional intake, sepsis, and acute on chronic kidney disease. On the day of her death, an IL-6 level was sent resulting at 10,362 pg/mL (normal, 0.0–6.9 pg/mL), suggesting a highly dysregulated immune system. She had an unexpected episode of pulseless electrical activity before being pronounced dead in the hospital, 2 weeks after being admitted.

Pertinent Autopsy Findings

Lungs With Excipient Lung Disease

The right lung was heavy 640 g (normal, 360–570 g). The left lung weighed 410 g (normal, 325–480 g). Histologic sections

Manuscript received June 4, 2021; accepted July 3, 2021.

From the *Department of Pathology, and †Department of Medicine, University of California, San Diego, CA.

The authors report no conflict of interest.

Reprints: Omonigho Aisagbonhi, MD, PhD, 9444 Medical Center Drive (1-200) La Jolla CA 92037. E-mail: oaisagbonhi@health.ucsd.edu.

Copyright © 2021 The Author(s). Published by Wolters Kluwer Health, Inc.

This is an open-access article distributed under the terms of the Creative Commons Attribution-Non Commercial-No Derivatives License 4.0 (CCBY-NC-ND), where it is permissible to download and share the work provided it is properly cited. The work cannot be changed in any way or used commercially without permission from the journal.

ISSN: 0195-7910/22/4302-0191

DOI: 10.1097/PAF.0000000000000718

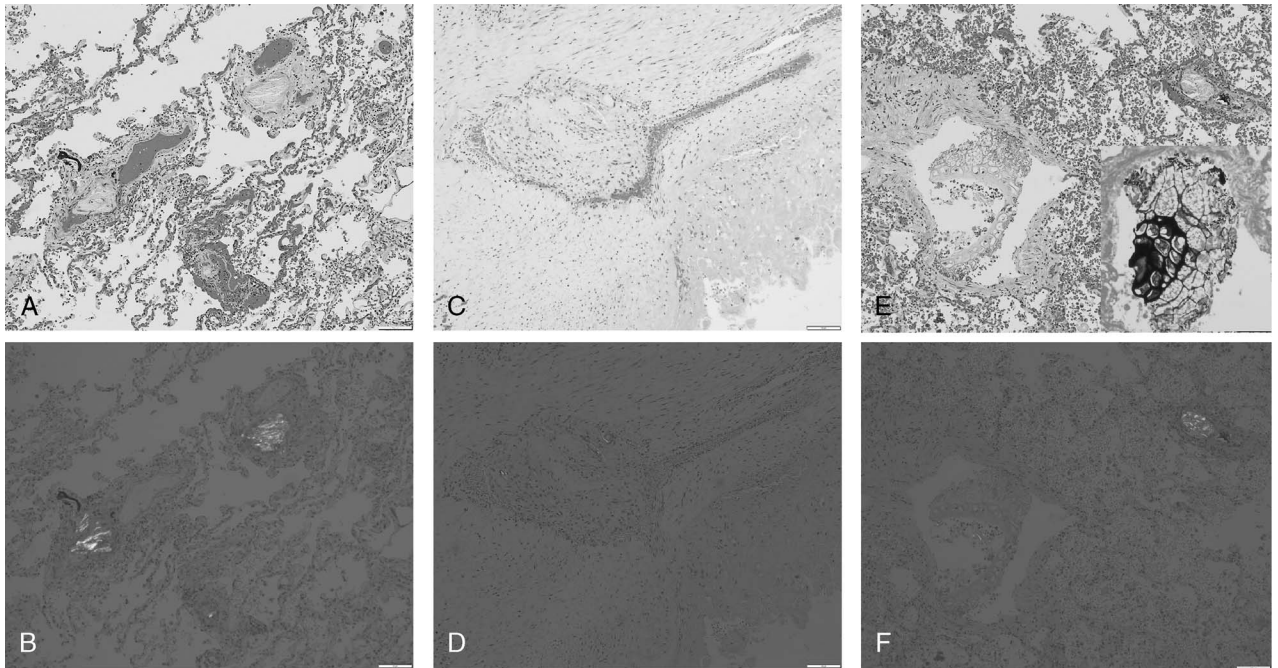


FIGURE 1. Excipient lung disease. Microcrystalline cellulose and crospovidone were present in pulmonary arterioles (A, 10× H&E, polarized in B) and arteries, occasionally associated with thrombi (C, 10× H&E, polarized in D). Vegetable material with fungi and bacteria were also identified in a pulmonary artery branch (E; 10× H&E, GMS stain insert, polarized in F). Figure 1 can be viewed online in color at www.amjforensicmedicine.com.

showed excipient lung disease with crospovidone and microcrystalline cellulose deposits within pulmonary vasculature (Figs. 1A–B), occasionally associated with fibrin thrombi (Figs. 1C–D). Vegetable material, *Candida* species, and Gram-negative bacilli were also identified within a pulmonary artery (Figs. 1E–F).

Necrotizing granulomatous inflammation with identification of *Candida* species

Her stomach was remarkable for necrotizing granulomatous inflammation in the muscularis propria (Fig. 2A). Necrotizing granulomatous inflammation along with fat necrosis was also present in the pancreas. *Candida* species were identified within both foci of necrosis (Fig. 2B).

Systemic Amyloidosis

Amyloid deposition was identified in her kidneys (Fig. 3A), liver (Fig. 3B), gastrointestinal tract (Fig. 3C), thyroid (Fig. 3D), and spleen (Fig. 3E).

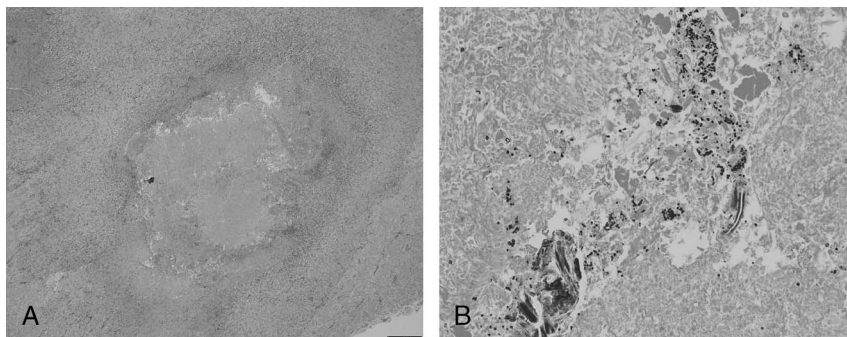


FIGURE 2. Necrotizing granulomatous inflammation. Necrotizing granulomatous inflammation was identified in the stomach muscularis propria (A, 10× H&E). Fungal organisms morphologically consistent with *Candida* species were present within the necrosis (B, 20× GMS stain). Figure 2 can be viewed online in color at www.amjforensicmedicine.com.

Bone Marrow

The bone marrow showed a mildly hypocellular marrow with trilineage hematopoiesis and maturation and no definitive morphologic or immunophenotypic evidence of a plasma cell neoplasm, and no evidence of amyloid deposition by Congo red staining.

Heart With Focal Myocarditis but Without Definite Amyloid Deposition

The heart was enlarged at 370 g (normal, 200–280 g) with healed VSD repair. Histologic sections showed focal subendocardial inflammation comprised predominantly of lymphocytes (Fig. 4A). Small fragments of crospovidone were also identified in rare coronary arteries and capillaries (Fig. 4B), but there was no definite amyloid deposition identified.

Urine Drug Screen

Her urine drug screen was positive for prescribed drugs—oxycodone, noroxycodone, oxycodone, norfentanyl, and fentanyl.

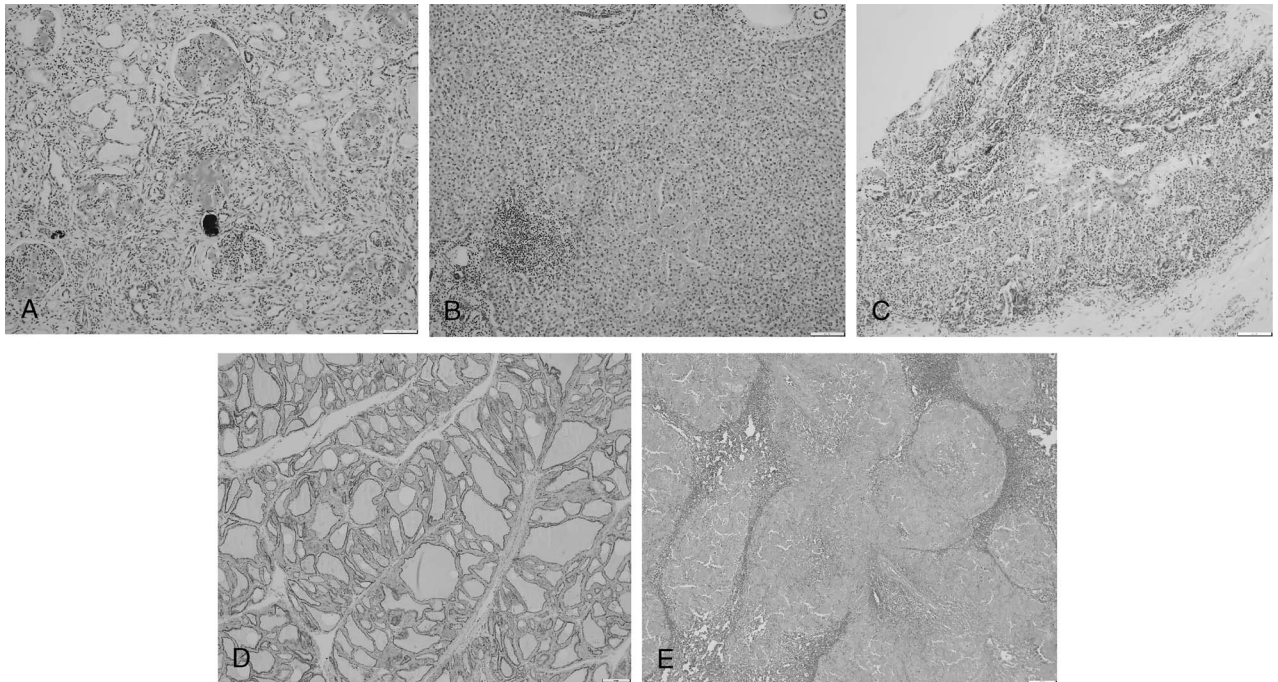


FIGURE 3. Systemic amyloidosis. Amyloid deposition was identified in the glomeruli of the kidneys (A, 10× Congo red stain, notice crosppidone is also present in an arteriole), liver sinusoids (B, 10× Congo red stain), lamina propria of the gastrointestinal tract (C, colon, 10× Congo red stain), basement membrane of the thyroid follicles (D, 10× Congo red stain) and as a mass-forming lesion in the spleen (E, 10× H&E). Figure 3 can be viewed online in color at www.amjforensicmedicine.com.

Screens for amphetamines, barbiturates, cocaine, benzodiazepine, methadone, phencyclidine, and THC were all negative.

DISCUSSION

We herein report the autopsy findings in a woman with prescription opioid use disorder and recurrent infections who, on autopsy, was found to have excipient lung disease, systemic amyloidosis, and necrotizing granulomatous inflammation with *Candida* species identified. She had no known history of human immunodeficiency virus (HIV) or hepatitis, with negative results on tests for hepatitis B and C. To the author's knowledge, our case represents the first autopsy report of systemic amyloidosis associated with intravenous injection of oral prescription medications and recurrent chronic injection drug-related infections.

AA amyloidosis occurs secondary to deposition of acute phase reactant, serum amyloid A, on various organs/tissues in

response to chronic inflammation. Systemic AA amyloidosis is a well-recognized potential sequelae of rheumatoid arthritis, inflammatory bowel disease, tuberculosis and familial Mediterranean fever, among other chronic inflammatory states.¹⁻⁸ Our patient had no known history of rheumatoid arthritis, inflammatory bowel disease, or tuberculosis. She had no reportable variants in the *MEFV* gene (associated with familial Mediterranean fever) on exon sequencing. Her only identifiable risk factor for the development of systemic AA amyloidosis were her history of intravenous drug abuse, as confirmed by the presence of excipient lung disease, a known complication of intravenous injection of crushed oral tablets,^{19,20} and chronic and recurrent infections. Her infections were likely related to the intravenous administration of oral medications she had stored in her mouth as her blood cultures grew organisms that normally reside in the mouth/gastrointestinal tract. Furthermore, a pulmonary vessel contained food material coated in bacteria and fungus (Fig. 1E), as evidence for injection of oral

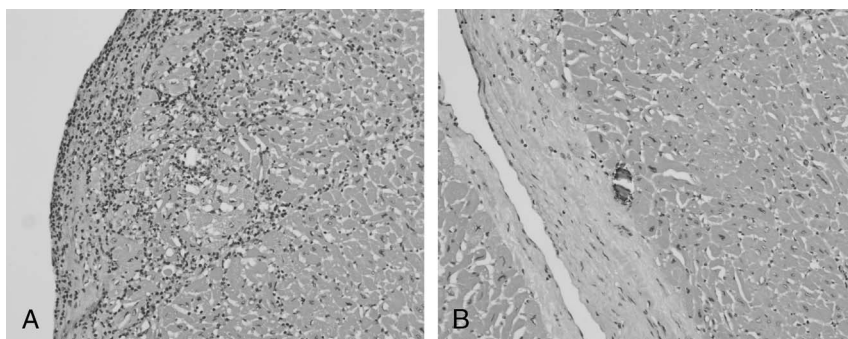


FIGURE 4. Cardiac findings. A subendocardial focus of myocarditis was identified in the heart (A, 20× H&E). Rare capillaries contained crosppidone (B, 20× H&E). Figure 4 can be viewed online in color at www.amjforensicmedicine.com.

contents, with the introduction of oral flora, into her blood stream. In addition, although not present at autopsy, she did have a history of skin infections, including arm pustules, knee infections, and the chronic sternal wound.

Reports of renal AA amyloidosis in injection/intravenous drug users date back to the 1970s—Lowenstein and Gallo⁹ reported renal amyloidosis in a patient with heroin addiction and bacterial endocarditis, Derosena et al¹⁰ similarly reported renal amyloidosis in a 44-year-old man with heroin addiction and skin abscesses, and Jacob et al¹¹ also reported renal amyloidosis in a 50-year-old woman with a history of subcutaneous injection of narcotics and chronic suppurative skin infection. Subsequent reports have similarly linked AA amyloidosis to chronic skin infection associated with injection drug abuse.^{12–14} Although healed by the time of autopsy, our patient had a history of a chronic skin wound over her sternum. She also had prior documented skin infections—including arm pustules and knee infections 2 months and 2 weeks before death, respectively. At autopsy, she had a necrotizing granulomatous abdominal infection that may have likewise contributed to producing the chronic inflammatory environment necessary for the development of AA amyloidosis. As *Candida* was identified within the gastrointestinal granulomatous infection, the formation of the granuloma was attributed to *Candida* and not considered because of inflammatory bowel disease. She had no histologic evidence of inflammatory bowel disease.

Other chronic inflammatory states thought to trigger AA amyloidosis in injection drug users include HIV/acquired immune deficiency syndrome¹⁶ and hepatitis.¹⁷ Our patient had no history of either HIV/acquired immune deficiency syndrome or hepatitis, with tests for hepatitis B and C being negative, suggesting that these infections are not necessary for the development of systemic amyloidosis in intravenous drug users.

Although AA amyloidosis has been described in association with illicit drug use—including heroin and cocaine, with some suggestion that tainted (black tar) heroin may be a more potent trigger,¹⁸ to our knowledge, ours is the first autopsy report of systemic AA amyloidosis associated with intravenous injection of oral prescription opioids. Our patient had no definite history of abuse of other drugs—multiple screens for amphetamines, barbiturates, cocaine, benzodiazepine, methadone, phencyclidine, and THC were negative. The only drugs identified in her urine were prescription opioids and their metabolites. Although she was prescribed opioids for pain, she had been found to exhibit pill hiding behavior and her excipient lung disease is evidence of her intravenous injection of medications that should have been taken orally. Whether excipients can act as amyloid enhancers independent of infection needs to be further explored.

Before death, our patient had a history of chronic renal failure, hypothyroidism, sepsis, chronic nausea and vomiting, and heart failure with reduced ejection fraction. Her systemic amyloidosis involved her kidneys, gastrointestinal tract and thyroid thus accounting for her chronic renal failure, gastrointestinal symptoms and hypothyroidism. However, there was no evidence of significant cardiac involvement by her AA amyloidosis. The lack/low rate of cardiac involvement in AA amyloidosis has been described in other studies.²¹ She, however, had evidence of focal myocarditis, crosopidone in coronary capillaries, and patchy interstitial fibrosis, which may have contributed to her heart failure.

In summary, we present autopsy findings in a patient with a history of intravenous injection of prescription opioids who

developed systemic amyloidosis and sepsis. Our case broadens potential sequelae of prescription opioid abuse.

REFERENCES

- Lachmann HJ, Goodman HJB, Gilbertson JA, et al. Natural history and outcome in systemic AA amyloidosis. *N Engl J Med*. 2007; 356:2361–2371.
- Simons PJ, Al-Shawi R, Ellmerich S, et al. Pathogenetic mechanisms of amyloid A amyloidosis. *Proc Natl Acad Sci U S A*. 2013;110: 16115–16120.
- Papa R, Lachmann HJ. Secondary, AA, amyloidosis. *Rheum Dis Clin N Am*. 2018;44:585–603.
- Obici L, Merlini G. AA amyloidosis: basic knowledge, unmet needs and future treatments. *Swiss Med Wkly*. 2012;142:w13580.
- Lane T, Pinney J, Gilbertson JA, et al. Changing epidemiology of AA amyloidosis: clinical observations over 25 years at a single national referral centre. *Amyloid*. 2017;24:162–166.
- Kadiroglu AK, Yildirim Y, Yilmaz Z, et al. A rare cause of secondary amyloidosis: common variable immunodeficiency disease. *Case Rep Nephrol*. 2012;2012:860208.
- Esenboga S, Ayaz DC, Ayhan AS, et al. COVID associated with systemic amyloidosis. *Case Reports Immunol*. 2015;2015:879179.
- Ben-Chetrit E. Familial Mediterranean fever (FMF) and renal AA amyloidosis—phenotype-genotype correlation, treatment and prognosis. *J Nephrol*. 2003;16:431–434.
- Lowenstein J, Gallo G. Remission of the nephrotic syndrome in renal amyloidosis. *N Engl J Med*. 1970;282:128–132.
- Derosena R, Koss MN, Pirani CL. Demonstration of amyloid fibrils in urinary sediment. *N Engl J Med*. 1975;293:1131–1133.
- Jacob H, Charytan C, Rascoff JH, et al. Amyloidosis secondary to drug abuse and chronic skin suppuration. *Arch Intern Med*. 1978; 138:1150–1151.
- Neugarten J, Gall GR, Buxbaum J, et al. Amyloidosis in subcutaneous heroin abusers (“skin poppers’ amyloidosis”). *Am J Med*. 1986;81:635–640.
- Harris M, Brathwaite R, Scott J, et al. Drawing attention to a neglected injecting-related harm: a systematic review of AA amyloidosis among people who inject drugs. *Addiction*. 2018;113:1790–1801.
- Mani D. Secondary amyloidosis associated with heroin use and recurrent infections—a case report. *Ann Med Surg (Lond)*. 2018;37:38–41.
- Jung O, Haack HS, Buettner M, et al. Renal AA-amyloidosis in intravenous drug users—a role for HIV-infection? *BMC Nephrol*. 2012;13:151.
- Oscik LA, Lee TP, Pedemonte MB, et al. Hepatic amyloidosis in intravenous drug abusers and AIDS patients. *J Hepatol*. 1993;19:79–84.
- Lejmi H, Jen KY, Olson JL, et al. Characteristics of AA amyloidosis in patients in San Francisco. *Nephrology (Carlton)*. 2016;21:308–313.
- Sharma A, Govindan P, Toukalty M, et al. Heroin use is associated with AA-type kidney amyloidosis in the Pacific Northwest. *Clin J Am Soc Nephrol*. 2018;13:1030–1036.
- Ganesan S, Felo J, Saldana M, et al. Embolized Cropsopidone (poly[N-vinyl-2-pyrrolidone]) in the lungs of intravenous drug users. *Mod Pathol*. 2003;16:286–292.
- Nguyen VT, Chan ES, Chou S-HS, et al. Pulmonary effects of i.v. injection of crushed oral tablets: “excipient lung disease”. *AJR Am J Roentgenol*. 2014;203:W506–W515.
- Muchtar E, Dispenzieri A, Magen M, et al. Systemic amyloidosis from A (AA) to T (ATTR): a review. *J Intern Med*. 2021;289:268–292.