

Treatment of multiple refractory ankle ulcerations in thromboangiitis obliterans

A case report

Zheng-Hao Huang, MD^{a,b}, San-Yuan Kuo, MD^b, Yu-Hsiang Chiu, MD^b, Hsiang-Cheng Chen, MD, PhD^b, Chun-Chi Lu, MD^{b,*}

Abstract

Rationale: Thromboangiitis obliterans (TAOs, or Buerger's disease) present as a non-atherosclerotic segmental occlusive vasculitis within medium- and small-sized blood vessels. TAO frequently occurs in young adults and is associated with cigarette smoking. At present, there are no accurately defined treatments for TAO.

Patient concerns: A 34-year-old Asian woman with a 20-year history of heavy cigarette smoking and recurrent, small, and self-limited lower limb ulcerations since adolescence, presented with persisting unhealed ulcerations on both ankles for 6 months. Her wound healing response was poor following the 2-month administration of colchicine, prednisolone, hydroxychloroquine, and mycophenolic acid.

Diagnosis: The patient was diagnosed with TAO with hyperimmunoglobulin E and refractory ulcerations on her ankles.

Interventions: The patient received monthly omalizumab (300mg) and previous medications for 2 months and shifted to omalizumab and colchicine without mycophenolic acid and hydroxychloroquine because of onychomadesis, which was considered to be a possible adverse drug reaction.

Outcomes: The wounds healed almost completely. The administration of omalizumab and colchicine will be continued until they the wounds are fully healed.

Lessons: Mycophenolic acid has a limited function in TAO treatment, especially in cases of refractory skin ulcerations. Omalizumab can be a valuable treatment option for patients with TAO and hyperimmunoglobulin E.

Abbreviations: DMARD = disease modifying antirheumatic drug, IgE = immunoglobulin E, TAO = thromboangiitis obliterans.

Keywords: Buerger's disease, immunoglobulin E, omalizumab, refractory ulcerations, thromboangiitis obliterans

1. Introduction

Thromboangiitis obliterans (TAOs, also known as Buerger's disease) present as a non-atherosclerotic segmental occlusive

vasculitis within medium- and small-sized blood vessels. TAO frequently occurs in young adults and is associated with cigarette smoking. Diagnosis requires the exclusion of other etiologies and uses Shionoya's clinical criteria: smoking, age <50, infra-popliteal arterial occlusions, either upper limb involvement or phlebitis migrans, and absence of atherosclerotic risk factors other than smoking.^[1] There are no accurately defined treatments for TAO at present.^[2]

Anti-immunoglobulin E (anti-IgE) therapies such as omalizumab can reduce serum-free IgE and downregulate IgE expression receptors.^[3] We used omalizumab for refractory skin ulcerations caused by TAO with hyper-IgE in our patient, and the wounds healed well. We consider that omalizumab may play a role in the therapy of TAO with hyper-IgE.

2. Case report

A 34-year-old Asian woman with a 20-year history of heavy cigarette smoking and recurrent, small, and self-limited lower limb ulcerations since adolescence, presented with persisting unhealed ulcerations on both ankles for 6 months (Fig. 1). She had no history of foreign travel and familial problems. She was afebrile without history of trauma, allergies, or systemic disease. After smoking cessation and the 2-month administration of daily colchicine (0.5 mg), prednisolone (10 mg), hydroxychloroquine (400 mg), and mycophenolic acid (360 mg), her wound healing response was still poor (Fig. 2, Table 1).

Editor: N/A.

Ethics committee or institutional review board: TSGHIRB No 1-107-05-033 approved by Tri-Service General Hospital.

Informed consent has been obtained from the patient.

All authors had access to the data and a role in writing this manuscript.

The authors have no funding and conflicts of interest to disclose.

^a Division of Rheumatology, Immunology, and Allergy, Department of Medicine, Kaohsiung Armed Forces General Hospital, Kaohsiung, ^b Division of Rheumatology, Immunology, and Allergy, Department of Internal Medicine, Tri-Service General Hospital; National Defense Medical Center, Taipei, Taiwan.

* Correspondence: Chun-Chi Lu, Division of Rheumatology, Immunology, and Allergy, Department of Internal Medicine, Tri-Service General Hospital, National Defense Medical Center, No 325, Sec 2, Cheng-Gong Rd, Neihu Dist, 114 Taipei, Taiwan (e-mail: jameslutaiwan@gmail.com).

Copyright © 2018 the Author(s). Published by Wolters Kluwer Health, Inc. This is an open access article distributed under the terms of the Creative Commons Attribution-Non Commercial-No Derivatives License 4.0 (CCBY-NC-ND), where it is permissible to download and share the work provided it is properly cited. The work cannot be changed in any way or used commercially without permission from the journal.

Medicine (2018) 97:20(e10798)

Received: 19 January 2018 / Accepted: 25 April 2018

<http://dx.doi.org/10.1097/MD.00000000000010798>

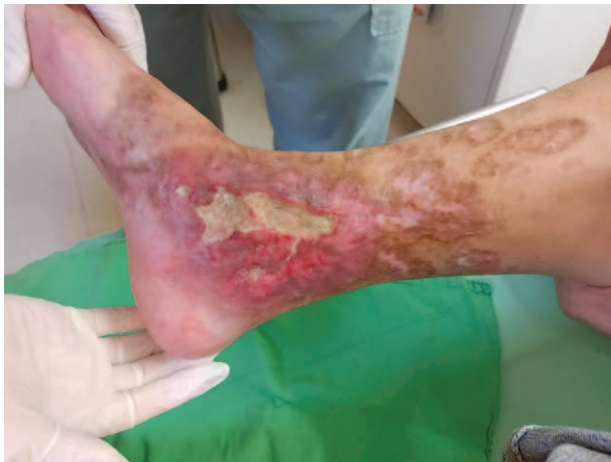

Figure 1. Multiple unhealed ulcerations on the bilateral ankles persisting for 6 months.

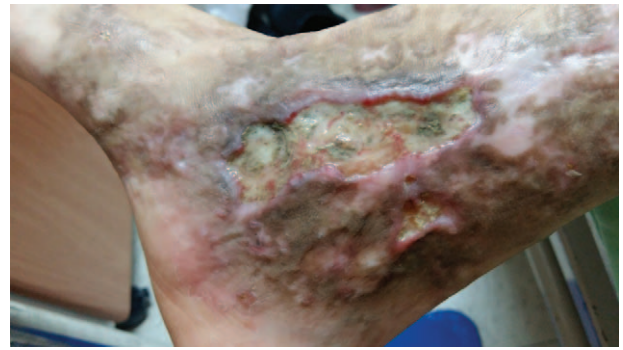


Figure 2. Minimal improvement of the ulcerations after smoking cessation and 2-month administration of colchicine, prednisolone, hydroxychloroquine, and mycophenolic acid.

The pulsation of the bilateral dorsalis pedis arteries was normal in the physical examination. However, the computed tomography angiography showed occlusions of the bilateral posterior tibialis arteries at the level of the ankles (Fig. 3). Laboratory test results revealed a high IgE of 12500 IU/mL (normal range, <165). The patient’s white blood cell and eosinophil counts, renal and liver function, immunoglobulin G, D-dimer, anti-phospholipid antibodies, and anti-neutrophil cytoplasmic antibodies were all normal. The human immunodeficiency virus examination and allergy screen were both negative. Skin biopsies from the ankle revealed inflammation with granular tissue, fibrosis, focal neutrophilic infiltration of vascular walls, and microthrombi; these aspects are consistent with a diagnosis of TAO.

We initiated monthly omalizumab (300mg) administration with her previous medications for the refractory ulcerations with hyper-IgE. Her refractory ulcerations started improving post first dose of omalizumab, and the dose of prednisolone was gradually titrated and then stopped after 1 month. However, we also stopped the administration of mycophenolic acid and hydroxychloroquine before the third dose of omalizumab because of the

onychomadesis and hyperpigmentation, respectively, which were considered to be possible adverse drug reactions. At that point, the patient’s wounds had only partially healed (Fig. 4). The patient received omalizumab and colchicine for the subsequent 5 months, and the wounds exhibited almost total recovery (Fig. 5). The patient’s IgE level was 6970 IU/mL post seventh omalizumab administration. The patient will continue monthly omalizumab and daily colchicine until she achieves total wound recovery without any other disease-modifying anti-rheumatic drugs (DMARDs).

3. Discussion

Diagnosis of TAO requires the exclusion of other etiologies such as autoimmune disorders, hypercoagulation, or diabetes mellitus.^[1] Although Shionoya’s clinical criteria^[4] include infra-popliteal arterial occlusion, the lesions usually present on the foot.^[5] Our patient had a 20-year smoking history. The significant bilateral distal posterior tibial arteries were occluded at the level of the ankle, without evidence of atherosclerosis, and skin biopsy also confirmed the diagnosis of TAO.

Numerous treatments of TAO include prostacyclin, growth factors, sympathectomy, and surgical revascularization. Unfor-

Table 1
Timetable of disease events and antibiotics usage.

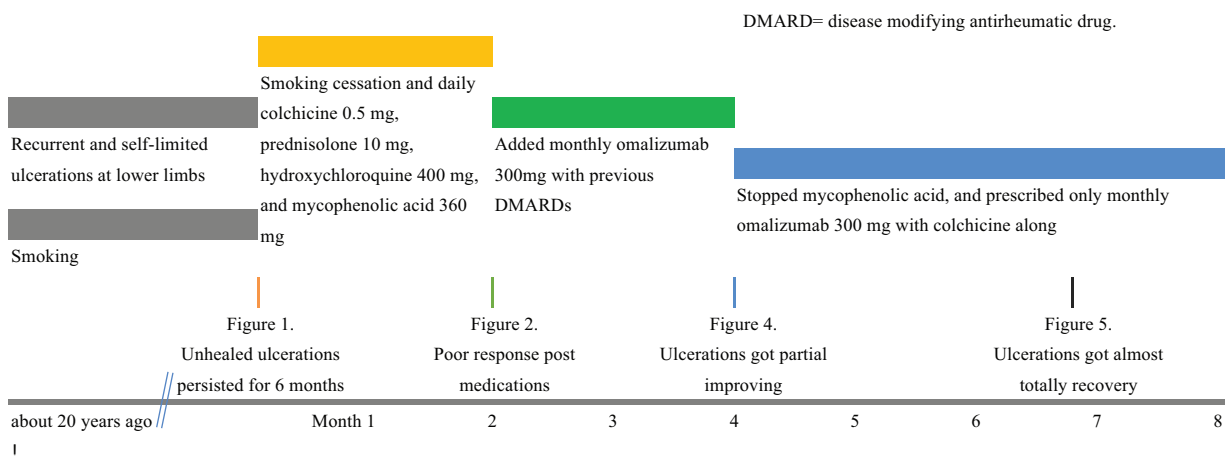

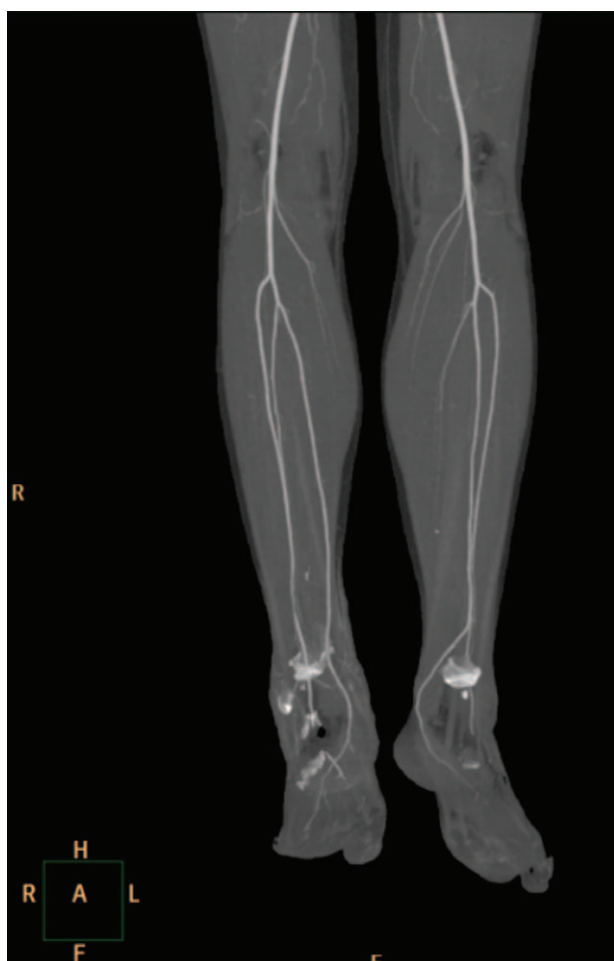


Figure 3. Computed tomography angiography of the lower limbs showed the filling defects of the bilateral distal posterior tibial arteries over the level of the ankles. The toes had collateral circulation from fibular arteries.

tunately, there is no accurately defined treatment.^[2] DMARDs, including mycophenolic acid, were administered for 2 months, but the wound healing response was very poor. Although mycophenolic acid might play a role in the treatment of anti-

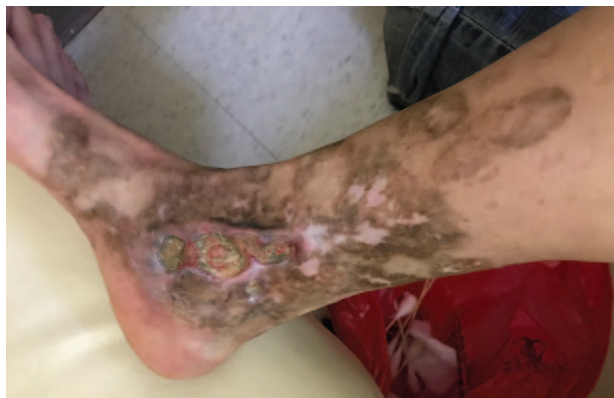

Figure 4. The wounds only partially healed after 2 doses of monthly omalizumab (300 mg) and disease-modifying anti-rheumatic drugs (DMARDs). We stopped mycophenolic acid and hydroxychloroquine because of onychomadesis before the third dose of omalizumab.

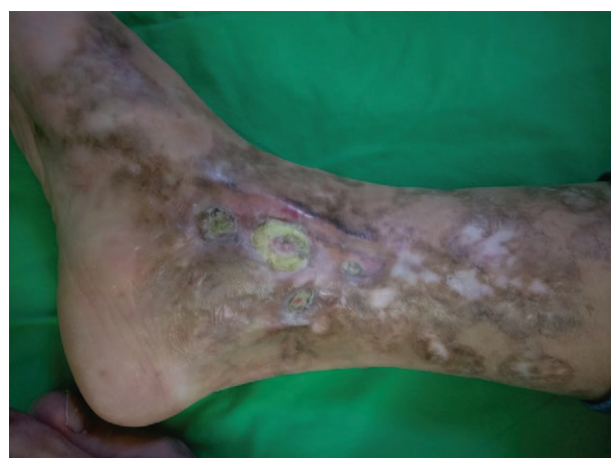

Figure 5. The patient received only omalizumab and colchicine for the subsequent 5 months, and the wounds showed almost complete healing.

neutrophil cytoplasm antibody-associated systemic vasculitis,^[6] we consider the mycophenolic acid therapy in our patient to be unsuccessful. The wounds continued to heal without mycophenolic acid post third dose of omalizumab, which indicated that the patient did not respond to mycophenolic acid.

To the best of our knowledge, there are no reports in the literature regarding the correlation between hyper-IgE and TAO, and we therefore decided to administer a combined therapy of omalizumab and DMARDs. We hypothesized that omalizumab played a therapeutic role for TAO when combined with hyper-IgE and refractory ulcerations.

There are some similar mechanisms among different types of vasculitis. Many complex interactions between inflammation and hemostasis elevate the thrombotic tendency, and chronic inflammation induces endothelial damage.^[7] There are reports of omalizumab used for the treatment of eosinophilic granulomatosis with polyangiitis,^[8] urticarial vasculitis,^[9] and Behçet disease.^[10] Omalizumab is a potential therapy for rare varieties of vasculitis. However, there is limited information on the use of omalizumab for TAO treatment. Anti-IgE therapies such as omalizumab can reduce serum-free IgE, downregulate IgE expression receptors, and inhibit eosinophils.^[3] Skin ulcerations might improve when IgE and eosinophils are under control. This patient ultimately only received omalizumab and colchicine without other DMARDs, but her wounds continued to improve. Although omalizumab has not been a recommended therapy for TAO, we suggest that it could be an option for treating patients with TAO, hyper-IgE, and refractory ulcerations.

The patient continues to receive monthly omalizumab, and we consider that a further biopsy will provide further information about the effect of omalizumab in the pathologic findings.

4. Conclusion

Mycophenolic acid has a limited function in the treatment of TAO with hyper-IgE and refractory skin ulcerations. Omalizumab can be a valuable treatment option for patients with TAO and hyper-IgE.

Author contributions

Conceptualization: Zheng-Hao Huang, San-Yuan Kuo, Hsiang-Cheng Chen, Yu-Hsiang Chiu, Chun-Chi Lu.

Data curation: Zheng-Hao Huang, San-Yuan Kuo, Hsiang-Cheng Chen, Yu-Hsiang Chiu, Chun-Chi Lu.

Formal analysis: Zheng-Hao Huang, Chun-Chi Lu.

Investigation: Zheng-Hao Huang, Chun-Chi Lu.

Validation: Chun-Chi Lu.

Visualization: Chun-Chi Lu.

Writing – original draft: Zheng-Hao Huang.

Writing – review & editing: Zheng-Hao Huang.

References

- [1] Olin JW. Thromboangiitis obliterans (Buerger's disease). *N Engl J Med* 2000;343:864–9.
- [2] Rivera-Chavarría IJ, Brenes-Gutiérrez JD. Thromboangiitis obliterans (Buerger's disease). *Ann Med Surg (Lond)* 2016;7:79–82.
- [3] Holgate S, Casale T, Wenzel S, et al. The anti-inflammatory effects of omalizumab confirm the central role of IgE in allergic inflammation. *J Allergy Clin Immunol* 2005;115:459–65.
- [4] Igari K, Inoue Y, Iwai T. The epidemiologic and clinical findings of patients with Buerger's disease. *Ann Vasc Surg* 2016;30:263–9.
- [5] Joviliano EE, Dellalibera-Joviliano R, Dalio M, et al. Etiopathogenesis, clinical diagnosis and treatment of thromboangiitis obliterans – current practices. *Int J Angiol* 2009;18:119–25.
- [6] Schaefer M, Scholl C, Scharpf D, et al. High interpatient variability in response to mycophenolic acid maintenance therapy in patients with ANCA-associated vasculitis. *Nephrol Dial Transplant* 2015;30:i138–45.
- [7] Aksu K, Donmez A, Keser G. Inflammation-induced thrombosis: mechanisms, disease associations and management. *Curr Pharm Des* 2012;18:1478–93.
- [8] Onat AM, Buyukhatipoglu H, Yilmaz M, et al. Immunoglobulin E: a new diagnostic clue for Behçet's disease? IgE and Behçet's disease. *Clin Rheumatol* 2007;26:81–3.
- [9] Bargagli E, Madioni C, Olivieri C, et al. Churg-Strauss vasculitis in a patient treated with omalizumab. *J Asthma* 2008;45:115–6.
- [10] Ghazanfar MN, Thomsen SF. Omalizumab for urticarial vasculitis: case report and review of the literature. *Case Rep Dermatol Med* 2015;2015:576893.