

# Non Surgical Treatment of Sacral Osteosarcoma

Aledavood S A<sup>1</sup>, Amirabadi A<sup>2</sup>, Memar B<sup>3</sup>

## Abstract

Osteosarcoma may rarely originate from the axial bones such as pelvis or vertebrae. In some pelvic and most vertebral primary tumors, resection often is not possible completely. In general, these tumors cannot be resected with negative margins so they need additional radiotherapy and chemotherapy, but results are unfavourable because of poor local control and high incidence of distant metastases.

This is a case report of sacral osteosarcoma which was treated successfully with chemotherapy and radiation therapy. The patient is a 14-year-old boy with a large osteosarcoma tumor in the first sacral vertebral body, with extra skeletal extension. The patient took radiotherapy (6000 centigray) plus chemotherapy regimen consisting of doxorubicin and cisplatin. In the last follow up 48 months later, the patient was completely asymptomatic with normal performance and there was not any evidence of local progression or distant metastasis.

**Keywords:** Osteosarcoma; Sacrum; Radiotherapy; Chemotherapy

**Please cite this article as:** Aledavood S A, Amirabadi A, Memar B. Non Surgical Treatment of Sacral Osteosarcoma. *Iran J Cancer Prev.* 2012; 5(1): 46-9.

1. Cancer Research Center ,  
Mashhad University of Medical  
Sciences, Mashhad, Iran  
2 .Student Research Committee,  
Mashhad University of Medical  
Sciences, Mashhad, Iran  
3. Omid Hospital, Mashhad  
University of Medical Sciences,  
Mashhad, Iran

Corresponding Author:  
Seyed Amir Aledavood, MD;  
Assistant Professor of Radiation  
Oncology  
Tel: (+98) 51 18 42 86 21  
Email: aledavooda@mums.ac.ir  
Received: 3Nov.2010  
Accepted: 10Jan.2011  
**Iran J Cancer Prev 2012; 1:46-49**

## Introduction

Osteosarcoma may rarely originate from the axial bones such as pelvis or vertebrae [1, 2]. Only 1–3 % of all osteosarcomas involve the spine; the lower lumbar and sacral vertebrae are the most common spinal locations [3].

In some pelvic and most primary vertebral tumors, complete resection often is not possible. More centrally located pelvic tumors, especially those involving the sacrum are unresectable. Contraindications for resection are unusually large extraosseous extensions with sacral plexus or major vascular involvement. On rare occasions, vertebral and sacral resections have been attempted. In general, these tumors cannot be resected with negative margins and are best treated by radiotherapy and chemotherapy [4]. Patients with primary tumors of the axial skeleton have a poor outcome because local control is rare.

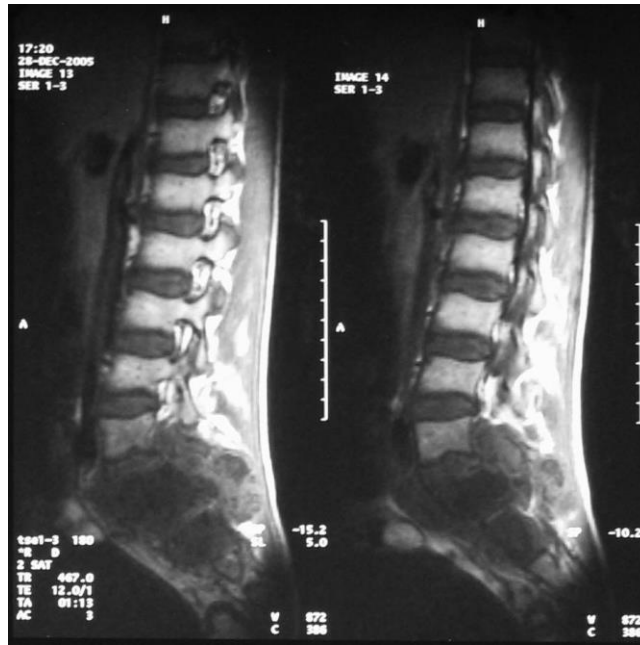The prognosis for these patients may improve with a more aggressive surgical approach and more effective chemotherapy. Patients whose tumors can be completely resected should be approached with curative intent; radiotherapy may provide significant palliation in individuals with unresectable primary tumors and has been reported in a small series to be associated with an improved survival [5].

Within the Cooperative Osteosarcoma Study (COSS), overall survival for patients with primarily spinal tumors was less than 2 years and the local failure rate was near 70% in 22 patients who were studied [6].

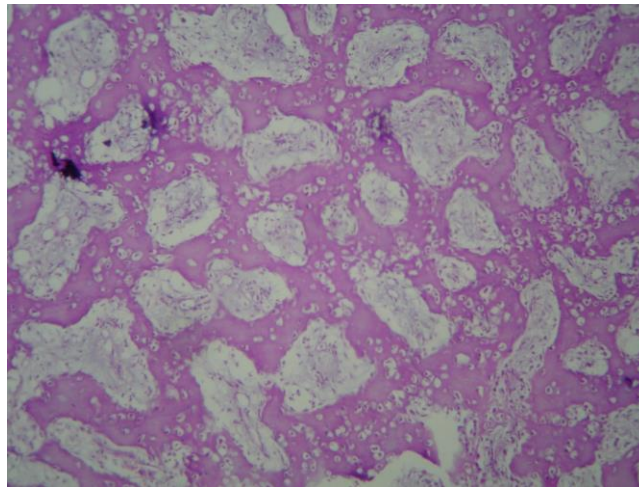
The patient who is presented in this article is a case of sacral osteosarcoma which has been treated with chemotherapy and radiation therapy and his disease has been controlled during 48 months of follow up.

## Case presentation and Management

A 14-years-old boy came with pain in lower lumbar region lasting for 5 months. One month before presentation, pain had referred to right thigh. He also complained of mild anorexia and weigh loss of about 3 kg. There were no gastrointestinal symptoms, fever and sweating in that period. Physical examinations revealed that he suffered only mild to moderate tenderness on sacral region with a very mild bulging with firm consistency. Muscular force in the proximal of lower extremities was normal while there was a moderate weakness in left foot muscles. Plain radiography of the pelvis and lumbosacral region revealed a large sclerotic lesion with ill defined borders in the first sacral vertebral body, with extra skeletal extension. MRI of this region revealed a large destructing bone lesion in sacrum (Figure 1).



**Figure 1.** Sagittal view MRI scan of lower vertebral column



**Figure 2.** Neoplastic bone formation and reticulated woven bone

Complete blood counts and serum biochemistry showed normal profile except increased serum level of Lactic Dehydrogenase (LDH=886) and Alkaline Phosphatase (ALP=1893).

Chest radiography was normal and whole body bone scintigraphy revealed an increased uptake only in sacral region.

Open biopsy of the lesion was done and pathologic study performed. In microscopic evaluation sarcomatous neoplasm was seen with foci of tumoral ossification composed of branching woven

bone trabeculae as well as foci of poorly differentiated hyper cellular regions and extensive areas of chondroblastic differentiation with small areas of mixoid tissues. Grading of tumor was estimated 2 out of 4 and final pathologic diagnosis was chondroblastic osteosarcoma grade 2 (Figure 2).

According to the site of origin and large volume of the tumor it was surgically unresectable; therefore the patient took chemotherapy plus radiotherapy.

Chemotherapy regimen consisted of 2 drugs of cisplatin and doxorubicin; after 4 courses of this

regimen pain subsided dramatically and patient received radiotherapy which was delivered with cobalt-60 teletherapy unit with dose of 6000 centigray in 30 fractions during 7 weeks to the gross tumor with a 3 to 5 cm margin in all directions. After completion of radiotherapy, chemotherapy continued for extra 3 courses of the same regimen.

At the end of treatment and until the last follow up at 48 months later, the patient was completely asymptomatic with normal performance status and there was not any evidence of active loco regional tumor or distant metastasis.

The last pelvic CT scan revealed that sclerotic lesion of the sacral vertebrae with its soft tissue extension remained without any progression.

## Discussion

The present case is an example of successful non-surgical treatment for axial bone osteosarcoma.

Khalfallah et al. presented a case report of 14-years-old girl with third lumbar vertebra which was treated with total vertebrectomy, chemotherapy and radiotherapy.

They concluded that therapeutic approach for the spinal tumor should use the developed techniques of treatment of extremity osteosarcoma because of their encouraging results [7].

Toshifumi Ozaki et al. analyzed 22 patients with spinal osteosarcoma (15 with sacrum tumor and 7 with tumors in other sites) who received chemotherapy. The median survival was 23 months, and 3 patients survived disease free for more than 6 years. In this study there was a significant difference in overall survival between patients who underwent either wide or marginal surgery and patients who underwent either intralesional surgery or no surgery. Among the patients who underwent no surgery or intralesional surgery results tended to be better in those patients who received irradiation compared with patients who did not receive irradiation [8].

Delaney TF et al. [9] evaluated local control of osteosarcoma in patients whom a resection with satisfactory margins was not achieved and evaluated the efficacy of radiotherapy in this setting.

In this study 41 patients with osteosarcomas that either were not resected or were excised with close or positive margins had undergone radiotherapy with external beam photons and/or protons. The anatomical sites treated were head and face, extremity, spine and pelvis. Patients with gross or subtotal resection had a greater rate of local control, survival, and disease-free survival compared with those who underwent biopsy only at 5 years.

Although no definitive dose-response relationship for local control of tumor was seen, the local control rate was better for those patients who received doses equal or higher than 55 Grays vs. lower doses. They concluded that radiotherapy could improve local control of diseases in situations which achieving a safe surgical margin was not possible [9].

## Conclusion

In our patient who was treated with chemotherapy and radiotherapy, a reasonable local control and disease free survival was achieved. Based on current data for osteosarcomas which are unresectable with safe margin, chemotherapy and radiotherapy should be considered. In some patients this type of treatment can produce very good results.

## Acknowledgement

The authors would like to thank Mr. H. Hoseinzadeh (staff of educational technology of Omid Hospital) for preparing digital format of imaging for this article.

## Conflict of Interest

The Authors have no conflict of interest in this article.

## Authors' Contribution

SAA wrote the case presentation and discussion. AA did literature review and wrote the abstract. BM did pathologic review and prepared the pathologic slide photograph.

## References

1. Avcu S, Akdeniz H, Arslan H, Toprak N, Unal O. A Case of Primary Vertebral Osteosarcoma Metastasizing to Pancreas. *JOP. J Pancreas (Online)*. 2009 Jul 6; 10(4):438-40.
2. Vander Griend RA. Osteosarcoma and its variants. *Orthop Clin North Am*. 1996; 27(3): 575-81.
3. Kurugoglu S, Adaletli I, Mihmanli I, Kanberoglu K. Lumbosacral osseous tumors in children. *European Journal of Radiology*. 2008; 65(2): 257-69.
4. Bielack SS, Kempf-Bielack B, Delling G, Exner GU, Flege S, Helmke K, et al. Prognostic factors in high-grade osteosarcoma of the extremities or trunk: an analysis of 1,702 patients treated on neoadjuvant cooperative osteosarcoma study group protocols. *J Clin Oncol*. 2002; 20(3):776.
5. Ozaki T, Flege S, Kevric M, Lindner N, Maas R, Delling G, et al. Osteosarcoma of the pelvis: experience of the Cooperative Osteosarcoma Study Group. *J Clin Oncol*. 2003; 21(2):334.
6. Fagioli F, Aglietta M, Tienghi A, Ferrari S, Brach Del Prever A, Vassallo E, et al. High-dose chemotherapy in the

treatment of relapsed osteosarcoma: an Italian sarcoma group study. *J Clin Oncol* .2002; 20(8):2150.

7. Khalfallah M, Malca S, Roche PH, Duffaud F, Garbe L, Pellet W. Primary spinal osteosarcoma. Apropos of a case. *Neurochirurgie*. 1997; 43(1):39-44.

8. Ozaki T, Flege S, Liljenqvist U, Hillmann A, Delling G, Salzer-Kuntschik M, et al. Osteosarcoma of the

spine:experience of the Cooperative Osteosarcoma Study Group. *Cancer*.2002; 94(4):1069 – 77.

9. DeLaney TF, Park L, Goldberg SI, Hug EB, Liebsch NJ, Munzenrider JE. Radiotherapy for local control of osteosarcoma. *Int J Radiat Oncol Biol Phys*. 2005; 61(2):492-8.