


Transcatheter arterial embolization for bleeding from the pancreaticoduodenal artery in patients with celiac artery stenosis: A technical report

Acta Radiologica Open
11(10) 1–6
© The Author(s) 2022
Article reuse guidelines:
sagepub.com/journals-permissions
DOI: 10.1177/20584601221135180
journals.sagepub.com/home/arr


Yasuyuki Onishi¹ , Hironori Shimizu¹, Hiroyoshi Isoda¹ , Ken Shinozuka² , Shigeru Ohtsuru²  and Yuji Nakamoto¹ 

Abstract

Background: Transcatheter arterial embolization (TAE) is widely accepted as a treatment for bleeding from the pancreaticoduodenal artery (PDA) in patients with celiac artery stenosis. However, the technical aspect of TAE has not received much attention.

Purpose: To report the technical details and success rate of TAE for bleeding from the PDA in patients with CA stenosis.

Material and Methods: Between 2015 and 2021, nine TAE procedures were performed in eight patients (five women, three men; one woman underwent TAE twice). The cause of CA stenosis was compression by the median arcuate ligament in eight cases and CA dissection in one case. The cause of bleeding was flow-related aneurysm rupture in six cases. Pre-TAE CT showed a pseudoaneurysm in all cases. The technical details of TAE were recorded, and the success rate was evaluated.

Results: The technical and clinical success rates were 100%. In six cases, both the CA and superior mesenteric artery (SMA) were cannulated using two parent catheters: a microcatheter advancing to the pseudoaneurysm from the CA (the CA approach) to achieve embolization and another catheter for angiography advancing from the SMA to map the vascular anatomy. In five cases, the CA approach was successfully performed after failed attempts of advancing a microcatheter from the SMA.

Conclusion: TAE is an effective treatment for bleeding from the PDA in patients with CA stenosis. Using two parent catheters, one for CA cannulation and microcatheter advancement and another for SMA cannulation and vascular mapping, may be a useful technique.

Keywords

celiac artery stenosis, embolization, hemorrhage, pancreaticoduodenal artery, pseudoaneurysm

Received 18 August 2022; accepted 09 October 2022

Introduction

In patients with celiac artery (CA) stenosis, bleeding from the pancreaticoduodenal artery (PDA) may occur as a result of flow-related aneurysm rupture.^{1–3} Although PDA aneurysms account for only 2% of all visceral artery aneurysms, clinical relevance is attributable to the high rupture rate associated with these aneurysms.⁴ Transcatheter

¹Department of Diagnostic Imaging and Nuclear Medicine, Graduate School of Medicine, Kyoto University, Kyoto, Japan

²Department of Primary Care and Emergency Medicine, Graduate School of Medicine, Kyoto University, Kyoto, Japan

Corresponding author:

Yasuyuki Onishi, MD, Department of Diagnostic Imaging and Nuclear Medicine, Graduate School of Medicine, Kyoto University, 54 Shogoin-kawahara-cho, Sakyo-ku, Kyoto 606-8507, Japan.
Email: goforawalktoday@yahoo.co.jp



arterial embolization (TAE) is the mainstay treatment for bleeding from the PDA.¹⁻³ The TAE technique to manage bleeding from the PDA is different from arterial bleeding management in other areas, in that the PDA can be approached from the CA or the superior mesenteric artery (SMA).^{1,2} Additionally, in some patients with CA stenosis, the blood flow of the PDA is cephalad: from the inferior pancreaticoduodenal artery to the gastroduodenal artery. Owing to these anatomical characteristics, several TAE techniques are available for bleeding from the PDA in patients with CA stenosis. However, most previous reports did not focus on the technical details of TAE.⁵⁻⁷ The purpose of this study was to report the technical and clinical success of TAE in a small series and discuss TAE techniques for bleeding from the PDA in patients with CA stenosis.

Materials and methods

Patients

The institutional review board approved this study with a waiver of informed consent. Between January 2015 and December 2021, 25 TAE procedures for bleeding from the PDA (the gastroduodenal artery, anterior and posterior superior pancreaticoduodenal artery, anterior and posterior inferior pancreaticoduodenal artery, and inferior pancreaticoduodenal artery) were performed at the authors' institution. The presence or absence of CA stenosis was evaluated in these patients. Stenosis was considered to be present when a patient showed luminal narrowing of the CA exceeding 50% on contrast-enhanced CT² and enhancement of the gastroduodenal artery through the PDA on angiography of the SMA. Among the 25 TAE procedures, stenosis of the CA was observed in nine interventions performed in eight patients. In these nine cases, the clinical information before and after TAE was available, and they constituted the study population. Among the eight patients, five were women and three were men, of which one woman underwent TAE twice. The median age at TAE was 55 years (range: 44–78 years). All patients had no history of pancreatitis or heavy alcohol intake. In eight cases, TAE was performed emergently on the day of presentation, while in one case, TAE was performed 6 days after presentation because the patient was suspected of having acute pancreatitis, and the correct diagnosis was obtained later. Information on each patient is presented in [Table 1](#).

CT findings

Contrast-enhanced CT was performed in all patients before TAE. In eight cases, CT was performed on the same day as TAE. In one case, CT was performed 2 days before TAE. The cause of CA stenosis was compression by the median arcuate ligament (MAL) in eight cases and CA dissection in

one case. The diagnosis of compression by the MAL was made when CT showed focal superior indentation of the CA.^{8,9} The CA was stenotic but patent in all cases. Pseudoaneurysms were found in all cases, while extravasation of the contrast medium was not observed in any of the patients ([Figure 1](#)). In six cases, CT did not show findings of bleeding causes, such as pancreatitis, tumor, and trauma, and rupture of a flow-related aneurysm was diagnosed. The remaining three cases had pancreatic cancer, and the cause of bleeding was cancer invasion in one case and postoperative pancreatic fistula in the other two cases. The median pseudoaneurysm size was 5 mm (range, 3–12 mm). Hematoma around the pseudoaneurysm was observed in seven cases, whereas hematoma in the common bile duct was observed in the remaining two cases.

Embolization procedure

The right common femoral artery was punctured under local anesthesia and moderate sedation, followed by placement of a 4- or 5-F vascular sheath. A 4- or 5-F catheter of various shapes (shepherd hook, cobra, twist, Simmons) was used to cannulate and obtain angiographic images of the CA and SMA. In some cases, a second 4- or 5-F catheter was advanced from a second 4- or 5-F sheath placed in the right or left common femoral artery, and both the CA and SMA were cannulated using two different catheters. A microcatheter with a distal tip of 1.7–2.2-F was advanced to the pseudoaneurysm from one or both parent catheters to embolize the pseudoaneurysm. Distal-to-proximal TAE with microcoils was preferentially performed. N-butyl cyanoacrylate (NBCA) was also used. The technique performed using two sheaths and two parent catheters was named the two-catheter technique. When the two-catheter technique was used and a microcatheter was advanced from the CA, angiography from the SMA route was repeatedly performed to map out the arterial anatomy ([Figure 2](#)). In contrast, the technique performed using one sheath and one parent catheter was called the one-catheter technique. The technique involving advancement of a microcatheter from a parent catheter placed at the CA to the pseudoaneurysm was named the CA approach, whereas that involving advancement of a microcatheter from a parent catheter placed at the SMA was named the SMA approach.

Evaluation

The technical details of each patient were recorded. Technical success of TAE was defined as the absence of pseudoaneurysm visualization on post-TAE angiography. Clinical success was defined by no clinical signs of rebleeding at the site of the pseudoaneurysm for more than 1 month and the absence of pseudoaneurysm visualization on post-TAE contrast-enhanced CT. Complications of the procedure were assessed using the Society of Interventional Radiology criteria.¹⁰

Table 1. Patient characteristics.

Case no.	Pt. no.	Age/sex	Past history	Presentation	Cause of CA stenosis	Cause of bleeding	Location of the PA	Size of the PA (mm)
1	1	44M	None	Abd. pain	MAL compression	Flow-related aneurysm rupture	PIPDA	5
2	2	51F	None	Abd. pain	MAL compression	Flow-related aneurysm rupture	PIPDA	3
3	3	53M	None	Abd. pain	MAL compression	Flow-related aneurysm rupture	AIPDA	8
4	4	54F	SLE	Abd. pain	MAL compression	Flow-related aneurysm rupture	AIPDA	6
5	5	55M	None	Nausea	MAL compression	Flow-related aneurysm rupture	PSPDA	4
6	6	57F	None	Abd. pain	CA dissection	Flow-related aneurysm rupture	PSPDA	4
7	7	72F	Pancreas cancer	Hematemesis and melena	MAL compression	Cancer invasion	PSPDA	3
8	8	78F	Pancreas cancer	Bleeding from the ENBD tube	MAL compression	Postoperative pancreatic fistula	ASPDA	12
9	8	78F	Pancreas cancer	Bleeding from the ENBD tube	MAL compression	Postoperative pancreatic fistula	GDA	5

Abd.: abdominal, AIPDA: anterior inferior pancreaticoduodenal artery, ASPDA: anterior superior pancreaticoduodenal artery, CA: celiac artery, ENBD: endoscopic nasobiliary drainage, GDA: gastroduodenal artery, MAL: median arcuate ligament, PA: pseudoaneurysm, PIPDA: posterior inferior pancreaticoduodenal artery, PSPDA: posterior superior pancreaticoduodenal artery, Pt: patient, SLE: systemic lupus erythematosus.

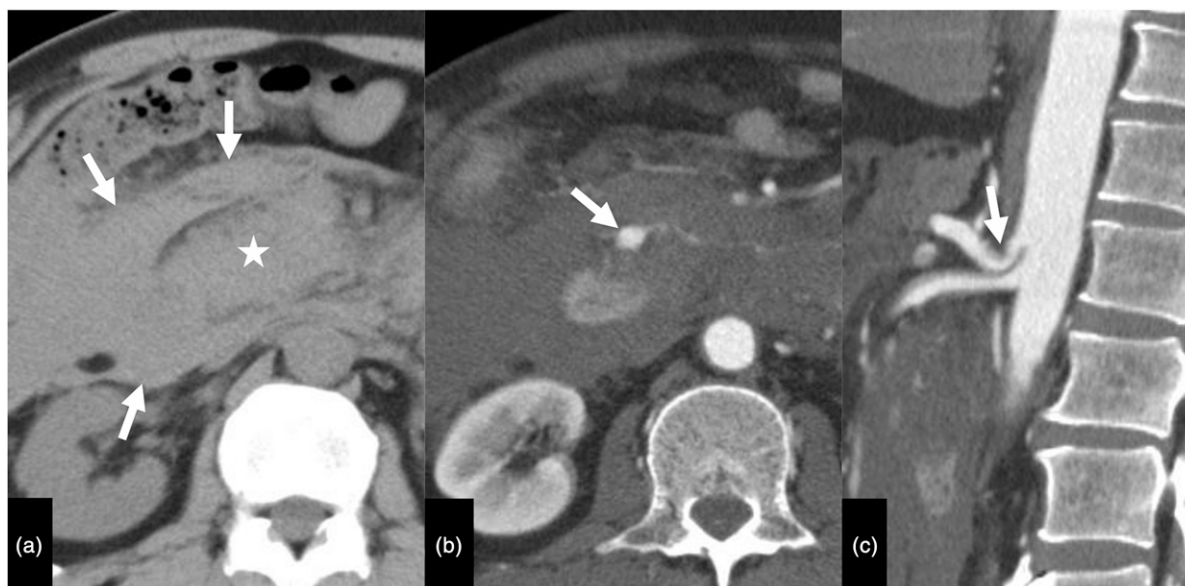

Figure 1. Contrast-enhanced CT in a 53-year-old man presenting with rupture of an anterior inferior pancreaticoduodenal artery (AIPDA) aneurysm due to celiac artery stenosis caused by compression of the median arcuate ligament (case 3). (a) Axial image without contrast medium shows hematoma (arrows) around the pancreatic head (star). (b) Axial arterial-phase contrast-enhanced image shows a pseudoaneurysm (arrow) of the AIPDA. (c) Sagittal arterial-phase contrast-enhanced image shows stenosis and downward compression (arrow) of the celiac artery, which is compatible with compression by the median arcuate ligament.

Results

Detailed information on the TAE technique and outcomes is shown in [Table 2](#). Technical success was achieved in all the

cases. The one- and two-catheter techniques were used in two and seven cases, respectively. The second sheath was placed in the right common femoral artery in five cases, while it was placed in the left in two cases. In six cases, TAE success was

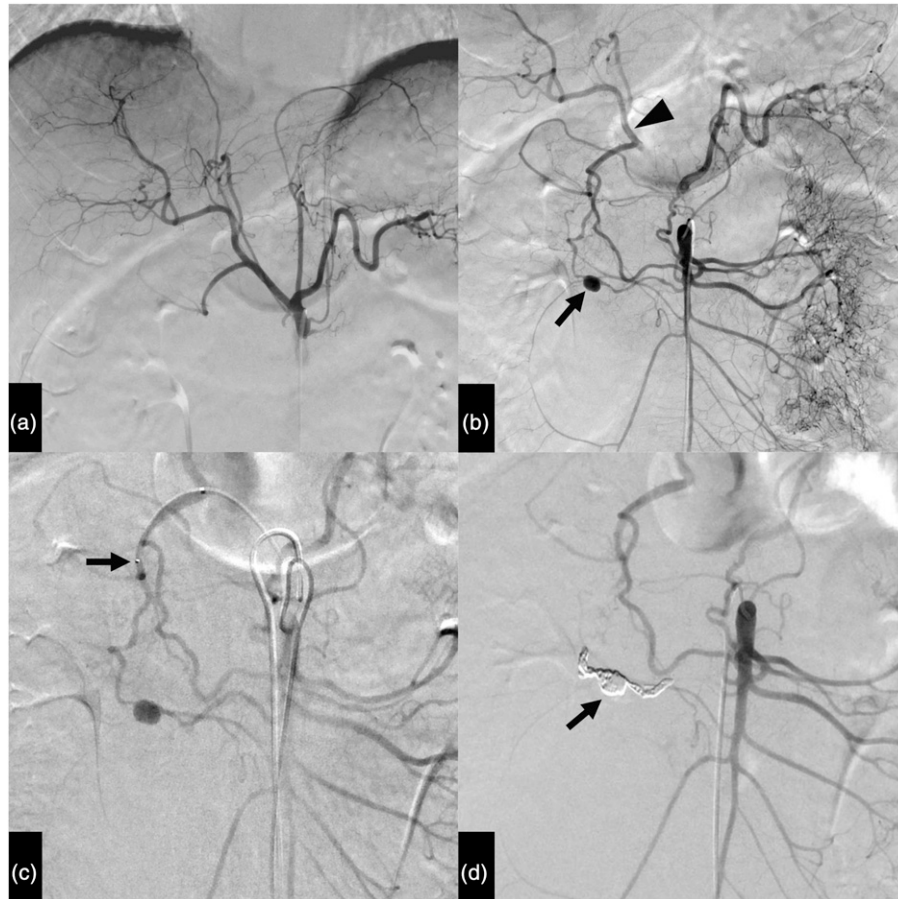


Figure 2. Transcatheter arterial embolization in a 53-year-old man presenting with rupture of an anterior inferior pancreaticoduodenal artery (AIPDA) aneurysm due to celiac artery stenosis caused by compression of the median arcuate ligament (case 3). (a) Angiography of the celiac artery does not show an aneurysm. (b) Angiography of the superior mesenteric artery (SMA) shows a pseudoaneurysm (arrow) of the AIPDA. The hepatic artery (arrowhead) is opacified through the pancreaticoduodenal artery. (c) Angiography of the SMA shows the vascular anatomy of the pancreaticoduodenal artery. This angiography was performed for navigation of a microcatheter. The tip of the microcatheter (arrow) is located at the proximal portion of the anterior superior pancreaticoduodenal artery. (d) Angiography of the SMA after embolization shows occlusion of the pseudoaneurysm with coils (arrow).

achieved using the CA approach and two-catheter technique: a microcatheter was advanced to the pseudoaneurysm from the parent catheter placed at CA, while another catheter was used for angiography approaching from the SMA for vessel mapping. In the remaining three cases, TAE success was achieved using the SMA approach or one-catheter technique. Among the six cases in which the CA approach and two-catheter technique were successful, the SMA approach was attempted before the CA approach in five cases, but the SMA approach failed. Failure of the SMA approach was due to the difficulty of cannulation of the inferior pancreaticoduodenal artery (IPDA) or difficulty in advancing a microcatheter in the IPDA. In eight cases, distal-to-proximal embolization of the pseudoaneurysm was achieved using microcoils. In one case, NBCA mixed with iodized oil at a ratio of 1:4 was injected into the pseudoaneurysm without flow control. Thereafter, proximal embolization with microcoils was performed. The median

number of microcoils that were placed was 9 (range: 4–17). After TAE, all cases showed no clinical signs of rebleeding for more than a month. Post-TAE contrast-enhanced CT obtained after the median of 6 days (range: 3–11) showed no pseudoaneurysm in all cases. Shrinkage of hematoma was observed in all cases. Thus, clinical success was achieved in all the cases. Complications were observed in two cases. One case involved an external iliac artery dissection, and the other involved a posterior IPDA dissection. They were managed conservatively and regarded as minor complications (SIR category: A).

Discussion

In TAE of a PDA pseudoaneurysm in patients with CA stenosis, the pseudoaneurysm can be approached from the CA and SMA. The SMA approach is more straightforward than the CA approach because SMA and IPDA angiography show

Table 2. Technique and outcomes of transcatheter arterial embolization.

Case no.	One- or two-catheter technique	CA approach or SMA approach [※]	Technical/clinical success	Comments on embolization procedure
1	Two	SMA→CA [†]	Yes/Yes	Selection of IPDA from the SMA was difficult.
2	Two	SMA→CA	Yes/Yes	Advancement of a microcatheter in the PIPDA from the SMA was difficult.
3	Two	SMA→CA	Yes/Yes	Selection of the IPDA from the SMA was difficult.
4	Two	SMA	Yes/Yes	
5	Two	SMA→CA	Yes/Yes	Advancement of a microwire from the SMA caused dissection of the PIPDA.
6	Two	CA	Yes/Yes	
7	Two	CA→SMA→CA ^{††}	Yes/Yes	Advancement of a microcatheter to the PSPDA from the CA was not possible due to low stability of a shepherd hook parent catheter. Next, the SMA approach was tried but advancement of a microcatheter in the IPDA was difficult. Then, the CA approach was tried again using a Simmons catheter, which allowed successful embolization because of increased stability of the parent catheter.
8	One	SMA	Yes/Yes	A microcatheter was advanced to the pseudoaneurysm from the SMA. Angiography from the pseudoaneurysm did not show a connection to the GDA. Thus, NBCA embolization of the pseudoaneurysm followed by coil embolization of the proximal artery was performed.
9	One	CA	Yes/Yes	Angiography of the GDA obtained by a microcatheter advanced from the CA showed the pseudoaneurysm. Embolization was performed with one-catheter technique.

CA: celiac artery, EIA: external iliac artery, GDA: gastroduodenal artery, IPDA: inferior pancreaticoduodenal artery, NBCA: N-butyl cyanoacrylate, PIPDA: posterior inferior pancreaticoduodenal artery, SMA: superior mesenteric artery.

[※]The CA and SMA approaches involve advancing a microcatheter to embolize the pseudoaneurysm from the CA and SMA, respectively.

[†]SMA→CA: The CA approach was successful after the failed SMA approach.

^{††}CA→SMA→CA: The CA approach was attempted first but was unsuccessful, after which the SMA approach was attempted but was also unsuccessful. Finally, the CA approach was successful.

a PDA pseudoaneurysm due to CA stenosis. However, this approach may be challenging because of the difficulty in cannulation of the IPDA from the SMA and advancement of a microcatheter in the IPDA.^{11,12} The IPDA may be tortuous, or may steeply bifurcate from the SMA. These anatomical characteristics contribute to the technical difficulty. Additionally, the IPDA originates from the common trunk with the first jejunal artery in 20%–65% of cases.¹³ In this branching pattern, a guide wire may tend to go to the first jejunal artery, and selection of the IPDA may be difficult. Two studies reported successful TAE of PDA pseudoaneurysm in several cases, of which both the SMA approach and the CA approach were used in some cases.^{1,2} Although the reason why the authors used the two approaches and the advantages and disadvantages of each technique were not described in the previous study, the CA approach may have been used because of the difficulty in IPDA cannulation or advancement of a microcatheter in the IPDA. In this study, cannulation of the IPDA or advancement of a microcatheter in the IPDA was difficult in five cases. In these cases, TAE was successfully performed using the CA approach. It was notable that the SMA

approach was unsuccessful in as many as five cases. One probable reason for this was the rapid shift to using the CA approach without adhering to the SMA approach. This is because in our experience, advancing a microcatheter from the CA to the PDA is easier than advancing it from the SMA. A disadvantage of the CA approach is that cannulation of the CA may be difficult in some patients. For example, when CA compression by the MAL is severe, the CA is occluded, and cannulation may be impossible. Even if the CA is not occluded, the catheter placed in the CA may be unstable, making TAE difficult, as observed in one case in this study (case 7).

In previous studies, embolization of a PDA pseudoaneurysm was performed using a one-catheter technique.^{1,2,11,14} In contrast, the two-catheter technique was used in seven out of nine cases in this study, and we believe that this is a useful technique. When the CA approach is used with a one-catheter technique, angiography from a microcatheter does not reveal a pseudoaneurysm because of retrograde flow from the SMA. However, when the two-catheter technique is used, angiography of the SMA can be performed at any time at an appropriate angle during

advancement of a microcatheter from the CA. Presumably, the use of the second catheter could reduce procedure time by allowing for faster tracking into the pseudoaneurysm with fewer transitions from injection to wire replacement. Less catheterization/wire manipulation due to better vessel mapping could also lead to less risk of dissection or spasm. These are advantages of the two-catheter technique. Disadvantages of the two-catheter technique are the increased complexity of the procedure and a higher risk of access site complications. Due to these disadvantages, we do not recommend the two-catheter technique as a primary procedure. However, when TAE with the one-catheter technique is difficult, we recommend the use of the two-catheter technique to successfully perform TAE.

In patients with severe CA stenosis, the PDA provides blood flow from the SMA to the upper abdominal organs, such as the liver, spleen, and upper gastrointestinal tract.¹⁵ In this study, embolization did not cause ischemic complications of the upper abdominal organs. However, embolization of the PDA can cause ischemia of the upper abdominal organs in patients with CA stenosis.^{16,17} Thus, it is imperative that the interventionists understand the risk of ischemic complications.

In conclusion, TAE is an effective treatment for bleeding from the PDA in patients with CA stenosis. The CA approach using the two-catheter technique may be a useful technique in TAE.

Declaration of conflicting interests


The author(s) declared no potential conflicts of interest with respect to the research, authorship, and/or publication of this article.

Funding

The author(s) received no financial support for the research, authorship, and/or publication of this article.

ORCID iDs

Yasuyuki Onishi  <https://orcid.org/0000-0003-0688-2190>

Hiroyoshi Isoda  <https://orcid.org/0000-0002-1789-7390>

Ken Shinozuka  <https://orcid.org/0000-0002-7303-1532>

Shigeru Ohtsuru  <https://orcid.org/0000-0002-6747-9859>

Yuji Nakamoto  <https://orcid.org/0000-0001-5783-8048>

References

- Chivot C, Rebibo L, Robert B, et al. Ruptured pancreaticoduodenal artery aneurysms associated with celiac stenosis caused by the median arcuate ligament: a poorly known etiology of acute abdominal pain. *Eur J Vasc Endovasc Surg* 2016; 51: 295–301.
- Suzuki K, Tachi Y, Ito S, et al. Endovascular management of ruptured pancreaticoduodenal artery aneurysms associated with celiac axis stenosis. *Cardiovasc Intervent Radiol* 2008; 31: 1082–1087.
- Kallamadi R, Demoya MA, Kalva SP. Inferior pancreaticoduodenal artery aneurysms in association with celiac stenosis/occlusion. *Semin Intervent Radiol* 2009; 26: 215–223.
- Ducasse E, Roy F, Chevalier J, et al. Aneurysm of the pancreaticoduodenal arteries with a celiac trunk lesion: current management. *J Vasc Surg* 2004; 39: 906–911.
- Bonardelli S, Spampinato B, Ravanelli M, et al. The role of emergency presentation and revascularization in aneurysms of the peripancreatic arteries secondary to celiac trunk or superior mesenteric artery occlusion. *J Vasc Surg* 2020; 72: 46S–55S.
- Flood K, Nicholson AA. Inferior pancreaticoduodenal artery aneurysms associated with occlusive lesions of the celiac axis: diagnosis, treatment options, outcomes, and review of the literature. *Cardiovasc Intervent Radiol* 2013; 36: 578–587.
- Nasr LA, Faraj WG, Al-Kutoubi A, et al. Median arcuate ligament syndrome: a single-center experience with 23 patients. *Cardiovasc Intervent Radiol* 2017; 40: 664–670.
- Horton KM, Talamini MA, Fishman EK. Median arcuate ligament syndrome: evaluation with CT angiography. *Radiographics* 2005; 25: 1177–1182.
- Gaujoux S, Sauvanet A, Vullierme MP, et al. Ischemic complications after pancreaticoduodenectomy: incidence, prevention, and management. *Ann Surg* 2009; 249: 111–117.
- Sacks D, McClenny TE, Cardella JF, et al. Society of interventional radiology clinical practice guidelines. *J Vasc Interv Radiol* 2003; 14: S199–S202.
- Dave B, Sharma A, Kwolek C, et al. Percutaneous transcatheter arterial embolization of inferior pancreaticoduodenal artery aneurysms associated with celiac artery stenosis or occlusion. *Catheter Cardiovasc Interv* 2010; 75: 663–672.
- Tokuda S, Sakuraba S, Orita H, et al. Aneurysms of pancreaticoduodenal artery due to median arcuate ligament syndrome, treated by open surgery and laparoscopic surgery. *Case Rep Surg* 2019; 2019: 1795653.
- Bertelli E, Di Gregorio F, Bertelli L, et al. The arterial blood supply of the pancreas: a review. III. The inferior pancreaticoduodenal artery. An anatomical review and a radiological study. *Surg Radiol Anat* 1996; 18: 67–74.
- Antoniak R, Grabowska-Derlatka L, Maciag R, et al. Treatment algorithm of peripancreatic arteries aneurysm coexisting with coeliac artery lesion: single institution experience. *Biomed Res Int* 2018; 2018: 5745271.
- Katsura M, Gushimiyagi M, Takara H, et al. True aneurysm of the pancreaticoduodenal arteries: a single institution experience. *J Gastrointest Surg* 2010; 14: 1409–1413.
- Zhang X, Zhang W, Zhou W, et al. Endovascular treatment of ruptured pancreaticoduodenal artery aneurysm with celiac axis stenosis. *Ann Vasc Surg* 2019; 57: 273.
- Shibata E, Takao H, Amemiya S, et al. Perioperative hemodynamic monitoring of common hepatic artery for endovascular embolization of a pancreaticoduodenal arcade aneurysm with celiac stenosis. *Cardiovasc Intervent Radiol* 2017; 40: 465–469.