

Case report

A novel deletion mutation in GUCY2D gene may be responsible for Leber congenital amaurosis-1 disease: A case report

Ahmad Reza Salehi Chaleshtori ^a, Masoud Garshasbi ^{a,*}, Ali Salehi ^b

^a Department of Medical Genetics, Faculty of Medical Sciences, Tarbiat Modares University, Tehran, Iran

^b Ophthalmology Center, Feiz Hospital, Isfahan University of Medical Sciences, Isfahan, Iran

Received 4 February 2019; revised 19 June 2019; accepted 3 July 2019

Available online 27 July 2019

Abstract

Purpose: To investigate genetic mutation(s) underlying retinal degeneration in a male patient.

Methods: A seven-year-old male patient was referred to receive genetic counseling and molecular testing. Clinical examination was performed by slit-lamp examination and electroretinography (ERG). Molecular testing was undertaken through arrayed-primer extension (APEX) and Sanger sequencing.

Results: Slit-lamp examination and flat ERG were in favor of Leber congenital amaurosis (LCA) disease as well as fundus findings. The genetic screening revealed two novel homozygote deletion and duplication variants in intron 15 and exon 16 of the GUCY2D gene. Segregation analysis in the family supports the probable contribution of these two novel mutations in clinical representations of the patient.

Conclusions: This report provides more information about LCA disease and its relevant mutations in Iran. Considering the overlapping phenotypes observed in retinal degenerative disorders, comprehensive molecular testing is needed for precise diagnosis.

Copyright © 2019, Iranian Society of Ophthalmology. Production and hosting by Elsevier B.V. This is an open access article under the CC BY-NC-ND license (<http://creativecommons.org/licenses/by-nc-nd/4.0/>).

Keywords: LCA; GUCY2D mutation; Iran; Deletion; Duplication

Introduction

Leber congenital amaurosis (LCA; OMIM 204000) as a rare eye disorder is the most common cause of retinal dystrophies by the age of 1 year.¹ LCA is represented by severe vision loss at an early age, extinguished electroretinography (ERG), near-absent or sluggish pupillary response, severely decreased visual acuity, sensory nystagmus,² oculo-digital

sign, keratoconus, cataract, photophobia,³ and high hyperopia.⁴ Mutations in at least 26 different genes are associated with the autosomal recessive/dominant transmission of LCA disease (www.sph.uth.tmc.edu/retnet/). The GUCY2D (also known as RetGC-1, ROS-GC) [OMIM 600179] was the first gene to be associated with LCA disease and accounts for 10–20% of LCA cases.⁵ In Iran, there are some reports on a GUCY2D missense variant [NM_000180:c.2447T > C; p.(Ile816Thr)] as a founder mutation associated with LCA.^{1,2} In addition, other GUCY2D missense mutations [NM_000180:c.2348T > C; p.(Leu783Pro)]³ and mutations of AIPL1 [OMIM 604392],⁴ RPGRIP1 [OMIM 605446],⁶ RPE65 [OMIM 180069],⁷ and CRB1 [OMIM 604210]⁸ have been reported in Iranian LCA patients. In the present study, we performed arrayed-primer extension (APEX) molecular testing to find out the underlying mutation in an Iranian LCA patient with severe visual impairment.

Conflict of interest disclosures: There is no conflict of interest.

Ethical statement: The informed consent of parents and the patient for participation in the study and publishing the results was granted.

* Corresponding author. Department of Medical Genetics, Faculty of Medical Sciences, Tarbiat Modares University, P.O. Box 14115-331, Tehran, Iran.
E-mail address: masoud.garshasbi@modares.ac.ir (M. Garshasbi).

Peer review under responsibility of the Iranian Society of Ophthalmology.

<https://doi.org/10.1016/j.joco.2019.07.002>

2452-2325/Copyright © 2019, Iranian Society of Ophthalmology. Production and hosting by Elsevier B.V. This is an open access article under the CC BY-NC-ND license (<http://creativecommons.org/licenses/by-nc-nd/4.0/>).

Case report

A seven-year-old male patient from the western part of Iran with no light perception (NLP) visual acuity was referred to us in order to receive genetic counseling and molecular testing. His parents requested to apply the results of molecular genetic testing for prenatal testing in their next pregnancy. The patient was born to a consanguineous marriage and a normal full-term pregnancy. The patient's main complaint was NLP visual acuity, which was presented at early months of life. Other findings were color blindness, keratoconus, oculo-digital sign, hyperopic refractive errors, and retinal degeneration. Also, funduscopy revealed macular atrophy. ERG of the patient showed a flat response, suggesting rod-cone dystrophy (Fig. 1).

We recruited a microchip platform using the arrayed primer extension (APEX array) (Version 9.0) (Asper biotech, Estonia)

to screen 780 known mutations/single nucleotide polymorphisms (SNPs) in targeted genes (AIPL1, CRB1, CRX, GUCY2D, LRAT, MERTK, CEP290, RDH12, RPGRIP1, RPE65, TULP1, LCA5, SPATA7, IQCB1, and RD3) related to LCA disease. After obtaining the patient's informed consent, the genomic DNA was extracted from peripheral blood leukocytes. The extracted DNA was used in a hybridization reaction followed by annealing to the APEX chip. The Oligonucleotide 3' extension reaction was performed in a template-based manner using four fluorescently labeled ddNTPs and DNA polymerase enzyme, which were incorporated in the reaction. The Genorama software⁹ was used to find the DNA variants. Next, Sanger sequencing was performed to confirm the identified variants.

Our APEX screening revealed an unexpected signal for the probes in the region of the mutation. Then, a deletion and duplication were detected in intron 15 and exon 16 of the

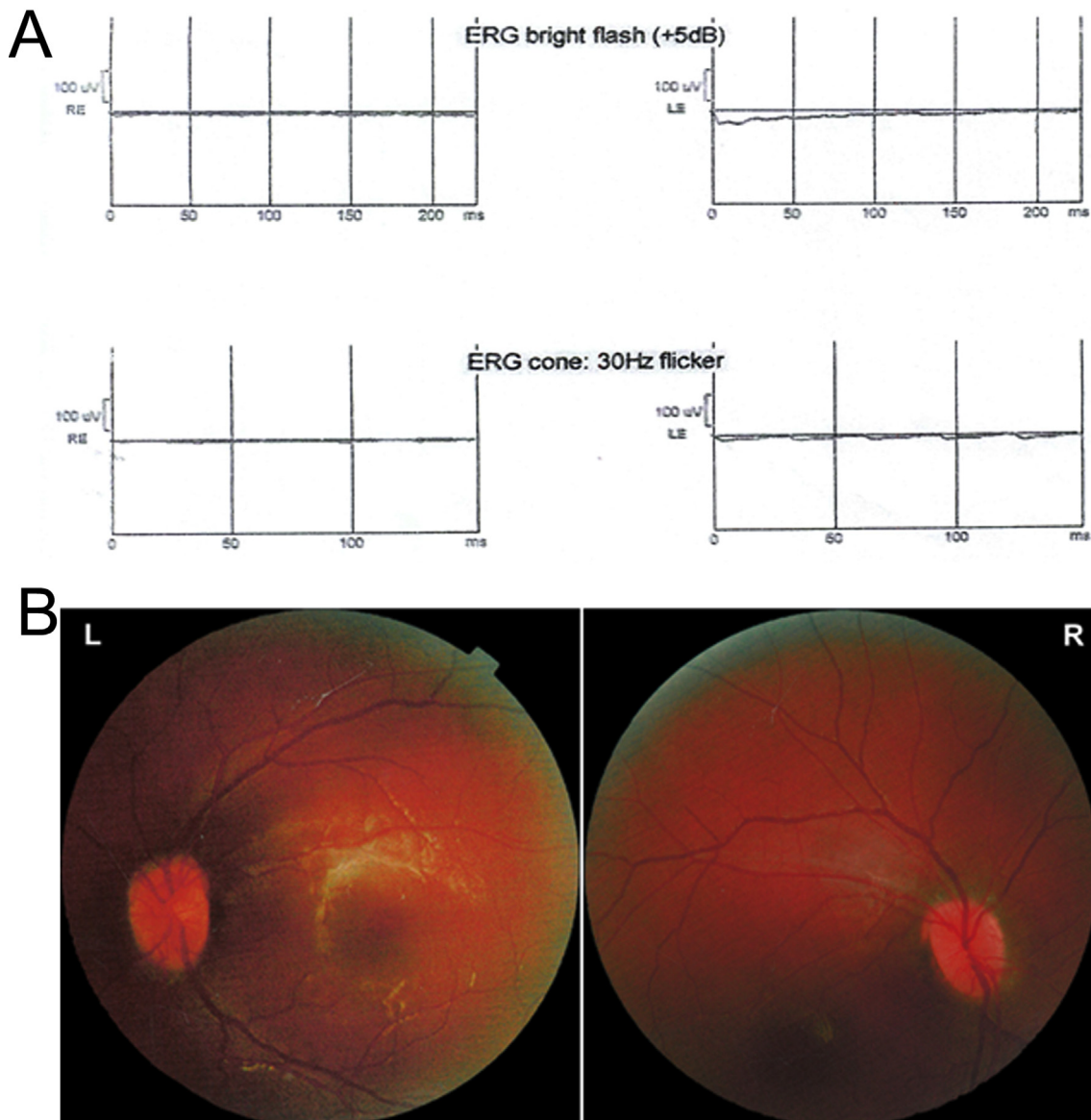


Fig. 1. Electroretinography (ERG) (A) and color fundus photography (B) of the patient.

GUCY2D gene through Sanger sequencing (Table 1 and Fig. 2). The other tested variants did not meet our criteria to be considered further. The exclusion criteria were minor allele frequency (MAF) of greater than 0.01 in public databases of healthy individuals [e.g., Iranome (<http://www.iranome.com/>), Exome Variant Server (EVS) (<https://evs.gs.washington.edu/EVS/>), 1000G (<http://www.internationalgenome.org/1000-genomes-browsers/>), gnomAD (<https://gnomad.broadinstitute.org/>), and GME (<http://igm.ucsd.edu/gme/>)].

The two novel variants were confirmed by Sanger sequencing and segregation study in the family of the patient and found that they were homozygote in the patient and heterozygote in his parents (Fig. 2).

Both variants were evaluated as pathogenic very strong (PVS1) based on the American College of Medical Genetics (ACMG) criterion.¹⁰ In addition, they were assessed as disease-causing variants using the MutationTaster online tool. These variants were not present in Exome Aggregation Consortium (ExAC), ClinVar, EVS, and Iranome databases (Table 1), leaving them as novel variants. In addition, we found that affected amino acids are conserved between different species through Clustal X2 software (Fig. 2B). Splice site predictors (i.e., NNSPLICE and NetGene2) were recruited to predict the impact of the duplication on splicing, as the deletion does not alter the canonical splice site at the intron 15/exon16 boundary. Consequently, we found that the duplication mutation has no effect on the splicing acceptor site by both predictors (Table 1).

Discussion

The GUCY2D mutations are responsible for autosomal recessive LCA-1 retinal degeneration and autosomal dominant/recessive cone-rod dystrophy-6 disease.¹¹ Moreover, GUCY2D mutations have been reported in another retinal degeneration disease known as retinitis pigmentosa.¹² This gene, which is located on chromosome 17p13.1 cytogenetic

band, produces the NM_000180 transcript that translates to a 1103aa protein (120KD transmembrane protein). The GUCY2D gene is expressed in the outer segment of cone/rod photoreceptors. The gene produces a photoreceptor-specific guanylate cyclase (GC-E) protein in the retina.¹³ The GUCY2D protein is composed of a kinase homology domain, dimerization domain, and a catalytic domain located in the cellular cytoplasm.¹⁴ The GUCY2D protein is enrolled in recycling cGMP after phototransduction and recovery of the dark state, consequently.¹⁵ A relative genotype-phenotype correlation is documented for some types of LCA disease.¹⁶ This correlation would be helpful to identify the correct LCA type and probable molecular defects underlying the disease. Recent advances in gene therapies for LCA disease are convincing enough, and it seems that having knowledge about the type of causative mutation in each patient would be helpful and might improve the future medical management.

The deletion mutation in exon 16 of the GUCY2D gene (NM_000180: c.2957_2985del; p.A986Vfs*76) affects the cytoplasmic catalytic domain (Arg488- Ser1103), leading to a frameshift and producing a truncated GUCY2D protein that may undergo nonsense-mediated decay (NMD) (Fig. 2C). The affected residues are conserved, suggesting that they may play an important role in the function of this protein. This mutation might also affect GUCY2D function by affecting RNA splicing. Another known disease-causing mutation at the position of this deletion has been reported in the Human Gene Mutation Database (HGMD) (HGMD ID CM002039) in an Italian patient affected with LCA.¹⁷ This result is in favor of probable damaging effects of this deletion. The duplication mutation (NM_000180: c.2945-1_-11dupCATCTCCACAG) discovered for this case does not alter the canonical splice site at the intron 15/exon16 boundary, suggesting that it may have no effect on the splicing. However, deletion mutation might alter protein features and its function. This interpretation is in line with the previous reports of GUCY2D mutations

Table 1
In silico evaluation of the variants.

Gene (Exon/Intron)	Variants coordinates	Pathogenicity		Minor allele frequency (MAF)	
GUCY2D (Intron 15)	NM_000180: c.2945-1_-11dupCATCTCCACAG; Chr17 (GRCh37): g.7919050_7919060dupCATCTCCACAG	MutationTaster	Disease causing ^a	ClinVar	Absent
		ACMG	PVS1	ExAC	Absent
				1000 G	Absent
				Iranome	Absent
				EVS	Absent
GUCY2D (Exon 16)	NM_000180: c.2957_2985del; Chr17 (GRCh37): g.7919073_7919101del; p.(A986Vfs*76)	NNSPLICE	No effect on the splicing	GME	Absent
		NetGene2	No effect on the splicing	gnomAD Genome	Absent
		MutationTaster	Disease causing ^b	ClinVar	Absent
		ACMG	PVS1	ExAC	Absent
				1000 G	Absent
		Iranome	Absent		
		EVS	Absent		
		NNSPLICE	No effect on the splicing	GME	Absent
		NetGene2	No effect on the splicing	gnomAD Genome	Absent

PVS1: Pathogenic very strong; EVS: Exome Variant Server; HGMD: Human Gene Mutation Database.

^a At intron-exon boundary, protein features might be affected, splice site changes.

^b Nonsense-mediated decay (NMD), amino acid sequence changed, frameshift, known disease mutation at this position (HGMD CM002039), protein features (might be) affected, splice site change.

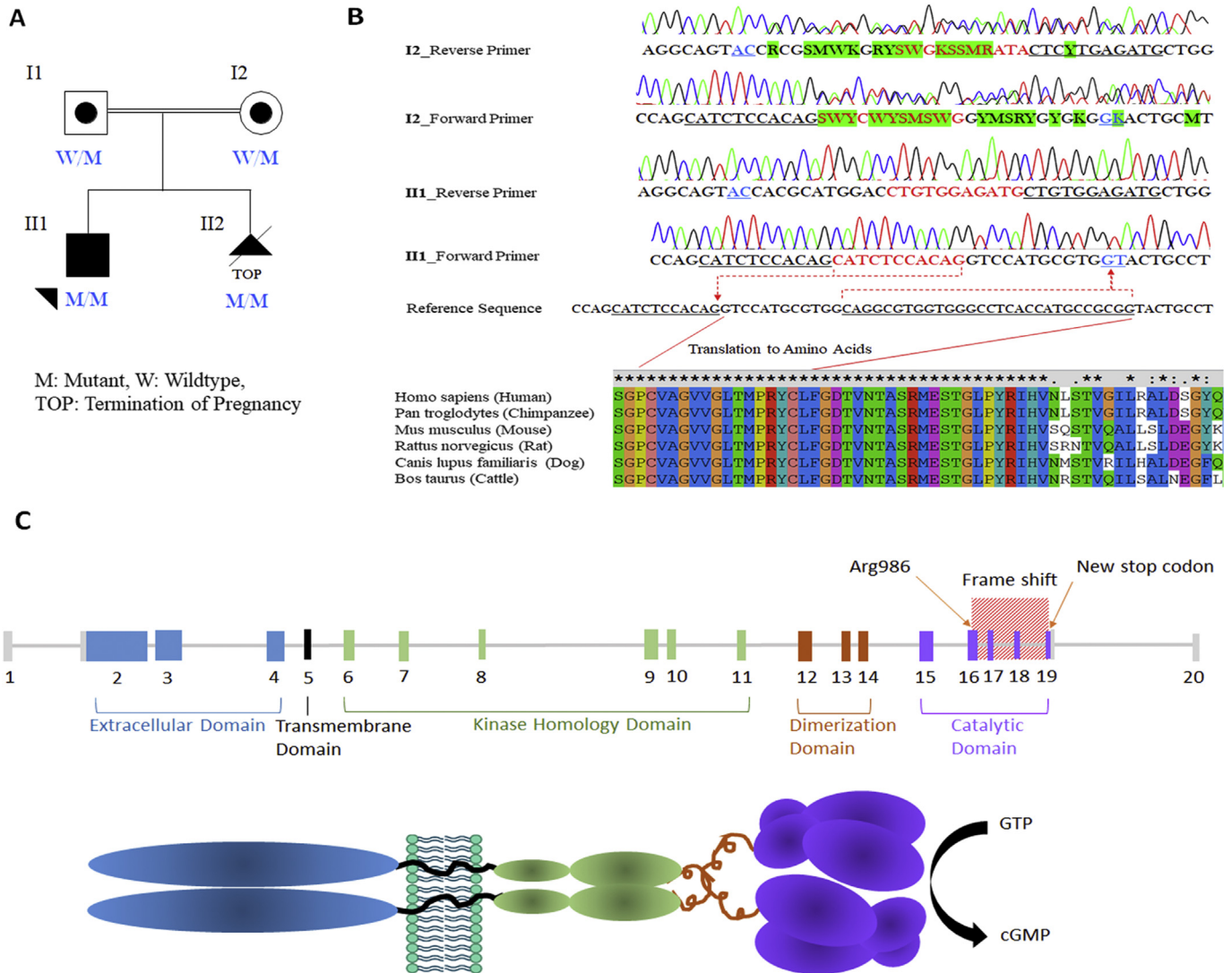


Fig. 2. Mutation confirmation and characterization. A) Segregation status of the mutation in the pedigree; B) Sanger confirmation of del/dup variation in GUCY2D gene and alignment of amino acids in mutation position; red dashed lines and underlined letters denote mutation position and affected sequences, respectively. The green highlights indicate misreading sequences in the patient's mother. Multiple alignments of amino acids in mutation position represent conservation of affected amino acids in some species; C) Schematic presentation of GUCY2D gene and its protein product. The mutation (p.(A986Vfs*76)) position is shown by red texture containing exons 16–19 of the gene. The protein domains and schematic representation of GUCY2D protein are in the same color with relevant exons for a better understanding.

in LCA disease¹¹ and might explain the clinical features of LCA in the patient. However, it is noteworthy that the full length of the GUCY2D gene is not sequenced.

A post-test genetic counseling was performed for family members and explained our findings including the meaning of PVS1 and novel variants that are not evaluated through functional studies, clinical and genetic heterogeneity of LCA disease, present, and possible future therapies, and their options in the next pregnancy. Accordingly, the family decided to do genetic testing for their next pregnancy and terminate the pregnancy following the positive prenatal diagnosis (PND). This decision was made by the parents due to the disease burden and substantial costs involved in continuing the pregnancy.

Overlapping phenotypes in retinal dystrophies often preclude diagnosis on clinical grounds alone. Therefore,

molecular diagnosis is highly recommended to explore the etiology of disease.¹⁸ As a result, molecular diagnosis can improve genetic counseling, which facilitates offering a PND and pre-implantation genetic diagnosis (PGD) to prevent the LCA disease in descendants. In addition, defining the precise molecular defects in LCA patients may improve the standard of care for patients and also can affect the efficiency and effectiveness of possible upcoming gene therapies.

References

1. Rezaie T, Karimi-Nejad MH, Meshkat MR, et al. Genetic screening of leber congenital amaurosis in a large consanguineous Iranian family. *Ophthalmic Genet.* 2007;28(4):224–228.
2. Zernant J, Kulm M, Dharmaraj S, et al. Genotyping microarray (disease chip) for Leber congenital amaurosis: detection of modifier alleles. *Investig Ophthalmol Vis Sci.* 2005;46(9):3052–3059.

3. Özkan EG. *Genetics of Inherited Eye Diseases in the Iranian Population*. St George's, University of London; 2016.
4. Moghadam AK, Vallian J, Vallian S. Molecular characterization of AIPL1 gene region in the Iranian population: application of novel informative haplotypes and detection of mutational founder effect. *Genes Genom*. 2017;39(4):433–443.
5. Rozet JM, Perrault I, Gerber S, et al. Complete abolition of the retinal-specific guanylyl cyclase (retGC-1) catalytic ability consistently leads to leber congenital amaurosis (LCA). *Investig Ophthalmol Vis Sci*. 2001;42(6):1190–1192.
6. Imani S, Cheng J, Mobasher-Jannat A, et al. Identification of a novel RPGRIP1 mutation in an Iranian family with leber congenital amaurosis by exome sequencing. *J Cell Mol Med*. 2018;22(3):1733–1742.
7. Yao S, Dharmaraj S, Millender-Swain T, ElCherbini M, Maumenee I. Mutations in the gene encoding RPE65 in patients with leber congenital amaurosis (LCA). *Investig Ophthalmol Vis Sci*. 2003;44(13), 2303–2303.
8. Ghofrani M, Yahyaei M, Brunner HG, et al. Homozygosity mapping and targeted sanger sequencing identifies three novel CRB1 (crumbs homologue 1) mutations in Iranian retinal degeneration families. *Iran Biomed J*. 2017;21(5):294–302.
9. Jaakson K, Zernant J, Kulm M, et al. Genotyping microarray (gene chip) for the ABCR (ABCA4) gene. *Hum Mutat*. 2003;22(5):395–403.
10. Richards S, Aziz N, Bale S, et al. Standards and guidelines for the interpretation of sequence variants: a joint consensus recommendation of the American College of medical genetics and genomics and the association for molecular pathology. *Genet Med – Offic J Am Coll Med Genet*. 2015;17(5):405–424.
11. Sharon D, Wimberg H, Kinarty Y, Koch KW. Genotype-functional-phenotype correlations in photoreceptor guanylate cyclase (GC-E) encoded by GUCY2D. *Prog Retin Eye Res*. 2018;63:69–91.
12. Perrault I, Hanein S, Gerber S, et al. A novel mutation in the GUCY2D gene responsible for an early onset severe RP different from the usual GUCY2D-LCA phenotype. *Hum Mutat*. 2005;25(2):222.
13. Perrault I, Rozet JM, Calvas P, et al. Retinal-specific guanylate cyclase gene mutations in Leber's congenital amaurosis. *Nat Genet*. 1996;14(4):461–464.
14. Potter LR. Domain analysis of human transmembrane guanylyl cyclase receptors: implications for regulation. *Front Biosci – J Vis Lit*. 2005;10:1205–1220.
15. Azadi S, Molday LL, Molday RS. RD3, the protein associated with Leber congenital amaurosis type 12, is required for guanylate cyclase trafficking in photoreceptor cells. *Proc Natl Acad Sci USA*. 2010;107(49):21158–21163.
16. Alkharashi M, Fulton AB. Available evidence on leber congenital amaurosis and gene therapy. *Semin Ophthalmol*. 2016:1–8.
17. Perrault I, Rozet JM, Gerber S, et al. Spectrum of retGC1 mutations in Leber's congenital amaurosis. *Eur J Hum Genet EJHG*. 2000;8(8):578–582.
18. Wang X, Zein WM, D'Souza L, et al. Applying next generation sequencing with microdroplet PCR to determine the disease-causing mutations in retinal dystrophies. *BMC Ophthalmol*. 2017;17(1):157.