



Trichopus zeylanicus ameliorates ibuprofen inebriated hepatotoxicity and enteropathy: an insight into its modulatory impact on pro/anti-inflammatory cytokines and apoptotic signaling pathways

Nagesh Kishan Panchal¹ · Purushotham Swarnalatha² · Sabina Evan Prince¹

Received: 18 July 2022 / Accepted: 5 August 2022

© The Author(s), under exclusive licence to Springer Nature Switzerland AG 2022

Abstract

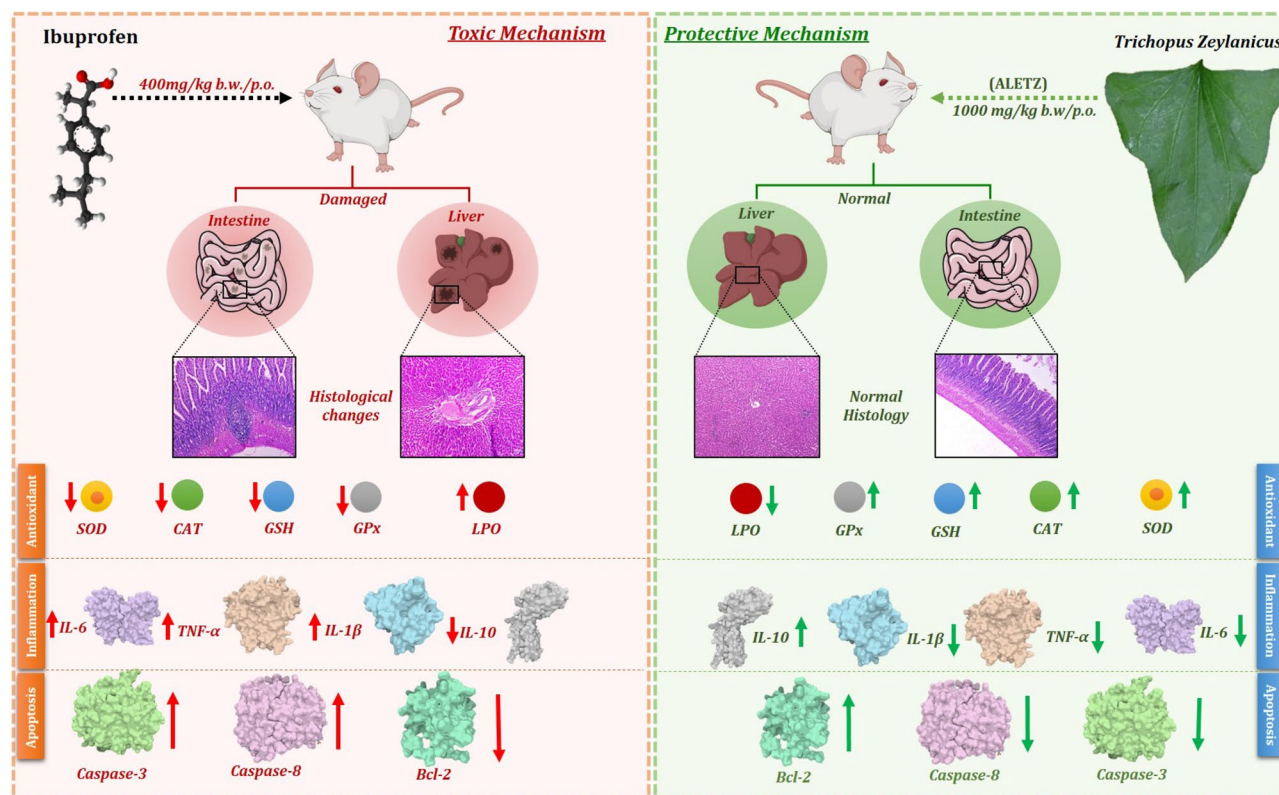
Ibuprofen is a nonsteroidal anti-inflammatory drug that is commonly used for its analgesic, antipyretic and anti-inflammatory effects worldwide. However ibuprofen comes with serious unavoidable adverse effects on various organs when used for long duration or overdosed. *Trichopus zeylanicus* is a medicinal plant endemic to India owning various beneficial properties and is been used in treating various ailments. Therefore, the objective of this study was to evaluate the ameliorative effect of aqueous leaves' extract of *Trichopus zeylanicus* against ibuprofen-induced hepatic toxicity and enteropathy in rats. Overall in this study 30 male albino rats were used, which were divided into five groups (six in each group). Group-I was normal control, Group-II was ibuprofen (400 mg/kg/day) inebriated group, Group-III was silymarin (25 mg/kg/day) pretreated + ibuprofen (400 mg/kg/day), Group-IV was ALETZ (1000 mg/kg/day) pretreated + ibuprofen (400 mg/kg/day), and Group-V was ALETZ alone (1000 mg/kg/day) group. The duration of the administration was for five days, followed by scarifying rats on the sixth day. Later the rats were assessed for liver and intestine enzyme markers, antioxidant parameters along with histopathological changes. In addition the pro-inflammatory markers such as TNF- α , IL-6 and IL-1 β as well as anti-inflammatory cytokine IL-10 levels were measured using ELISA. Lastly the expression pattern of apoptotic signaling markers such as caspase-3, caspase-8 and Bcl-2 was evaluated using western blot. The results obtained from this study showed changes in levels of aforesaid parameter which presented the toxic effect of ibuprofen on liver and small intestine. Pre-treatment of ALETZ in ibuprofen-inebriated group was able to normalize the adverse effect caused due to ibuprofen. The conclusion of the study deduces that pre-treatment with ALETZ alleviates by modulating oxidative stress, inflammation, and apoptosis in ibuprofen inebriated rats, indicating its protective mechanism.

✉ Sabina Evan Prince
eps674@gmail.com

¹ Department of Biomedical Sciences, School of Biosciences and Technology, Vellore Institute of Technology, Vellore 632 014, India

² Department of Information Security, School of Computer Science and Engineering, Vellore Institute of Technology, Vellore, India 632104

Graphical abstract



Keywords Nonsteroidal anti-inflammatory drugs · Ibuprofen · *Trichopus zeylanicus* · BCL-2 · Caspase-8 · Caspase-3

Introduction

Nonsteroidal anti-inflammatory drugs (NSAIDs) are a prominent class of pharmaceuticals that are increasingly utilized across the world (Zappavigna et al. 2020). They have been authorized by the Food and Drug Administration (FDA) for use as anti-inflammatory, analgesic and antipyretic medications (Bertolini et al. 2001; Bozimowski 2015; Kaduševičius 2021). Statistics show that approximately 30 million people use NSAIDs every day since so many are available without a prescription, i.e. over the counter (OTC) (Kim et al. 2021). In spite of extensive therapeutic benefits, NSAIDs if used for long term are involved in several toxicities as reported by myriad of pharmacoepidemiological investigations (Moore et al. 2019).

Ibuprofen, which is derivative of propionic acid, is one of most common NSAIDs that was originally made available in 1969 (Rainsford 2009). Ibuprofen (800–1200 mg/day) is used to treat minor aches and pains, such as headaches, muscle aches, fever, backaches and dysmenorrhea (Bushra and Aslam 2010). However, it is utilized for the long-term treatment of rheumatoid arthritis, osteoarthritis

and numerous other chronic pain conditions at larger doses (1800–2400 mg/day) (Ward 1984; Bushra and Aslam 2010). Ibuprofen has relatively fast absorption in the upper gastrointestinal tract, which is followed by metabolism in liver and clearance via kidneys, leading to short plasma elimination half-life. The main enzymes in metabolism of ibuprofen in the human liver are CYP2C8 and CYP2C9, which are responsible for its stereo selective hydroxylation (Johansson et al. 2014). Additionally, the in vitro studies have reported uridine 5′ diphosphoglucuronosyltransferase (UGTs) which are predominantly expressed in gut and are also involved in metabolism of ibuprofen. Ibuprofen mainly inhibits the cyclooxygenases (COX) enzymes (COX-1 & COX-2) in non-selective manner (Prusakiewicz et al. 2009; Liu et al. 2020). The COX inhibition ultimately leads to reduction in prostaglandin production, which is key player in inflammation. The prolonged use of ibuprofen has been reported to cause metabolomics changes in blood via elevating the levels of alanine transaminase (ALT) and aspartate aminotransferase (AST) signifying the atrocious liver damage (Kim et al. 2021). Additionally, ibuprofen has been deliberated

to cause various serious toxicities such as cardiovascular, hepatic, renal and gastrointestinal at therapeutic dosage if used for longer duration (Hall et al. 1986; Hunter et al. 2011; Sriutha et al. 2018; Kim et al. 2021). Besides there are no therapeutic interventions that can prevent or protect the ibuprofen inebriated toxicities.

The traditional uses of plant-based medicines have led to the discovery of numerous new potent therapies which are been utilized in treating various diseases. Several decades of the studies on medicinal plants and bioactive compounds have revealed their role as anti-inflammatory (Khan et al. 2020; Uddin Chy et al. 2021), anti-microbial (Hossain et al. 2021), anti-fungal (Hemamalini et al. 2020) and antinociceptive (Freitas et al. 2021). Additionally, they have been said to possess anti-cancer (Ahmed et al. 2020; Sinan et al. 2021; Ağagündüz et al. 2022), anti-proliferative (Akkol et al. 2021), anti-diarrheal (Jahan et al. 2022), neuro-protective (Gonçalves et al. 2020; Vieira et al. 2020; Farooq et al. 2021; Goni et al. 2021; Islam et al. 2021), cardio-protective (Fahad et al. 2021) and gastrointestinal (Martínez et al. 2020) protective properties. Recently there was report on polyphenols present in green tea have effective role in management of COVID-19 (Tallei et al. 2021). In addition there are reports on nanoparticles which have been synthesized from plant sources to have shown properties like anticancer, antimicrobial, antileishmanial, etc. (Iqbal et al. 2020). Therefore the growing popularity and efficacy of Ayurveda and natural remedies in the treatment of a variety of illnesses prompted researchers to consider how well they would work against drug-induced organ damage. Numerous research showing the effectiveness of natural remedies in reducing the toxicity of drugs have been conducted to date (Jerin Peter and Evan Prince 2018; Simon et al. 2019).

Trichopus zeylanicus is a medicinal plant endemic to Agastya hills, the extreme end of Western Ghats mountain range of south India. It is well known as “Arogayapacha” means “the greener of health” amongst the indigenous Kani tribes of Agastya hills (Pushpangadan et al. 1988). A speckled spectrum of pharmacological properties such as anti-fatigue, anti-stress, antioxidants, anti-microbial, analgesic, anti-inflammatory, aphrodisiac, anti-diabetic, anti-ulcer, anti-hyperlipidemic and hepatoprotective of *Trichopus zeylanicus* have been reported (Biju et al. 2019). A range of phytochemicals, including flavonoids, tannins, terpenoids, steroids and saponins, have been detected in *Trichopus zeylanicus* (aqueous, ethanol, and methanol) extracts after phytochemical screening. In previous study the protective potentials of the leaf extract of *Trichopus zeylanicus* against paracetamol-induced hepatotoxicity has shown remarkable protective effect (Subramoniam et al. 1997; Rajani et al. 2014; Majee et al. 2019). However, considering all the aforementioned facts, in this study we have evaluated ameliorative potentials of aqueous leaf extract of *Trichopus*

zeylanicus (ALETZ) against ibuprofen-instigated hepatotoxicity and enteropathy in Wistar albino rats.

Material and methods

Extract preparation

The fresh leaves of the *Trichopus Zeylanicus* were collected from Agastya hills of Kerala, India, which was authenticated and certified by the Prof. Jayaraman, Director of Institute of Herbal Botany, Plant Anatomy Research Center, Chennai, Tamil Nadu, India. The certified number of the authenticated plant specimen was PARC/2022/4710. The fresh leaf samples were properly cleaned using water to remove dirt residues and was air dried at room temperature (27 ± 3 °C) for 30 days. Later the samples were pulverized into fine powder using mortar and pestle. The obtained fine powder was then macerated in distilled water (dH₂O) in the ratio of 1:2 (w/v) and was soaked for 24 h. After 24 h of soaking the mixer was filtrated by Whatman Filter paper (number 1). The filtrate was then dried using water bath which yielded 10% (w/w) of the aqueous leaves extract that was used in performing further experiments.

Phytochemical profiling of *Trichopus Zeylanicus* leaves

To analyze the chemical composition of the *Trichopus Zeylanicus* leaves' extract, Gas chromatography-mass spectrometry (GC-MS) was used. The leaf samples were injected into the GC column. And the operation was programmed to start at 60 °C for 2.5 min, additionally, the ramp temp was set from 10 °C/min to 300 °C, the hold was for 6 min and end set at 215 °C for 2.5 min. The temperature of the injector was set to 215 °C while the temp for detector was set to 260 °C. Later, 1 µL of sample was loaded into the GC-MS (GC trace ultra-version 5). The separation procedure of *Trichopus Zeylanicus* leaves was done using MS-thermo DSQ II GC column (30.0 m × 250 µm) via helium gas as carrier and was adjusted to column velocity flow of 1.0 ml/min. The mass spectral scan range from 40 to 600 (m/z) was used and later to identify the compound the peak was compared with The National Institute of Standards and Technology (NIST) research library.

Chemicals and drugs

The ibuprofen tablets were obtained commercially from Abbot India Limited., Verna Salcette, Goa, India. Chemical structure of ibuprofen has been represented in (Fig. 1A). The Silymarin tablet was procured from Micro lab Pvt, Ltd, Solan, Himachal Pradesh, India. Both of these tablets were

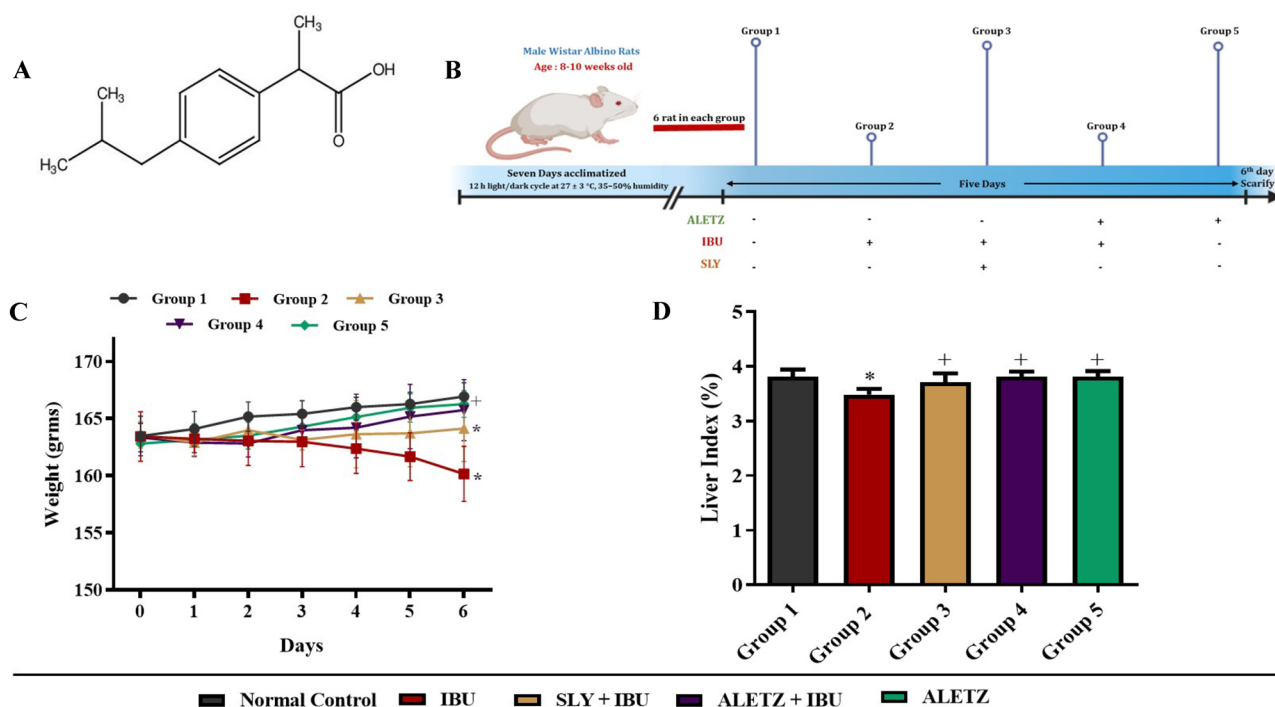


Fig. 1 Effect of ALETZ on experimental rats body weight and liver index. **A** The typical image depicts the molecular structure of ibuprofen. **B** Experimental flowchart representing the in-vivo study timeline, and treatment schedule of IBU, ALETZ and SLY. **C** Represents the change in body weight of experimental rats throughout the study period. **D** Change in liver index of experimental rats. IBU-Ibuprofen,

ALETZ- Aqueous leaves extract of *Trichopus zeylanicus* and SLY-Silymarin. (*) represents Normal Control vs IBU, ALETZ+IBU, SLY+IBU and ALETZ; (+) represents IBU vs ALETZ+IBU, SLY+IBU and ALETZ; (\$) represents SLY+IBU vs ALETZ+IBU and ALETZ; (#) represents ALETZ+IBU vs ALETZ. (*+ \$#) $P < 0.05$ delineates the results statistically significant

dissolved in sterile water and administered. All the other chemicals used were obtained and were of high analytical grade.

Experimental animals

Thirty male wistar albino rats, approximately 8–10 weeks old, and weighing 150–180 g were obtained from the animal house facility, Vellore Institute of Technology, Vellore, Tamil Nadu, India. All rats were maintained under the standard conditions (12 h light/dark cycle at 27 ± 3 °C, 35–50% humidity) and were housed six per cage. Rats were fed regularly with standard pellet diet and water ad libitum. The rats were acclimatized to above mentioned condition for 7 days prior to the commencement of the experiments. The usage of the rats in this study was approved by the Institutional Animal Ethical committee Vellore Institute of Technology, Vellore (VIT/IAEC/21/Dec) as per CPCSEA guidelines.

Scheme of experiment

The animals were divided into mainly five groups and each group contained six animals. The groups were divided as follows and shown in (Fig. 1B):

- Group 1: Normal control group (Normal Saline)
- Group 2: Ibuprofen alone (400 mg/kg. b.w. /day, p.o.) was given for 5 days
- Group 3: Ibuprofen (400 mg/kg. b.w. /day, p.o.) for 5 days + Silymarin (25 mg/kg. b.w./ day, p.o.) before two hrs of ibuprofen treatment for 5 days.
- Group 4: Ibuprofen (400 mg/kg. b.w. /day, p.o.) for 5 days + ALETZ (1000 mg/kg. b.w./day, p.o.) before two hrs of ibuprofen treatment for 5 days.
- Group 5: ALETZ alone (1000 mg/kg b.w./day, p.o.) was given for 5 days.

After the 5 days of treatment period, rats were allowed to fast for 12 h, after the last dosage. Later on 6th day all rats were killed using ether anesthesia. The cardiac puncture was introduced in rats using 5 ml syringe with a 23G1 needle to obtain blood. Later the serum was separated from blood using centrifugation procedure (2000 rpm for

10 min) for antioxidant assays. Later, liver and intestine were collected using surgical procedure for histopathological analysis.

Weight assessment

The weight of the rats was measured twice daily first before the drug administration and second after 6 hrs of drug administration until the day of killing. The change in the body weight in experimental rats (i.e. Increase or Decrease), for all 6 days, was represented in terms of statistical significance ($P < 0.05$). After killing all rats the liver weight was gauged. The liver index was examined using the following formula: (Liver index = (Liver weight/body weight) \times 100%).

Biochemical assessment

The protective activity of *Trichopus Zeylanicus* leaves was deliberated by examining serum markers such as albumin, total bilirubin, direct bilirubin, gamma glutamyl trasapeptidase (GGT), asparatate amino transferase (AST), alanine amino transferase (ALT), Alakaline phosphatase (ALP), high-density cholesterol (HDL), low-density cholesterol (LDL), triglycerides and total cholesterol. All kits were procured commercially from AutoSpan diagnostics, Ltd., Bangalore, India. The analysis for all test was performed as per the standard protocols given by manufacturers.

Antioxidant activity assessment

The small sections of the liver and intestine were obtained from experimental rats and homogenized using heparin-induced platelet activation assay (HIPA). The homogenized liver and intestine samples were then used for analyzing antioxidant parameters such as catalase (CAT), superoxide dismutase (SOD) (Marklund and Marklund 1974), reduced glutathione (GSH) (Sinha 1972), glutathione peroxidase (GPx) (Rotruck et al. 1973) and malondialdehyde (MDA).

Myeloperoxidase assay

The myeloperoxidase (MPO) can be used as indirect marker for small intestine inflammation as it is present in neutrophils. For this assay the intestine tissue was homogenized in 10 mM phosphate buffer with pH 6. The samples were then centrifuged for 10 min at 13,000g, and supernatant obtained was discarded and the tissue homogenate was resuspended in 0.5% hexadecyltrimethyl ammonium bromide. Later the samples was vortexed and recentrifuged for 2 min at 5000g. Last o-dianisidine was added to supernatant and absorbance was recorded at 450 nm.

Cytokine levels assessment

The supernatant obtained from homogenized liver and intestine tissues of experimental rats was used for measuring the level of Tumor necrosis factor- α (TNF- α), Interleukin-6 (IL-6), Interleukin-1 β (IL-1 β) and Interleukin-10 (IL-10) using enzyme-linked immunosorbant assay (ELISA) kits. The ELISA kits were procured from the Sigma-Aldrich, India, and procedures for carrying out this analysis was performed according to the manufacturer's protocol.

Histopathological assessment

For morphological analysis, the liver and intestine sample obtained from experimental rats was fixed in the fixative made [ethanol absolute (85 ml), glacial acetic acid (5 ml) and 40% formaldehyde (10 ml)]. Once the tissue samples were dehydrated they were fixed in paraffin to prepare block for microtomy. Later for analysis the tissue sections of size 4–5 μ m were obtained with microtome, stained with Haematoxylin–Eosin (H&E) and observed under an optical microscope at 10 \times and 40 \times . Histological parameters were examined using photographs obtained with the same magnification and camera settings. The subsequent histological scoring pattern such as 0: no changes, 1: mild changes, 2: moderate changes, 3: severe change was used for assessing tissue architectural damage.

Western blotting

Using the radioimmunoprecipitation assay (RIPA) buffer, proteins extracts from liver and intestinal tissues were prepared. The protein extract was then separated by sodium dodecyl sulfate–polyacrylamide gel electrophoresis gels and then transferred to polyvinylidene difluoride membranes (Millipore, USA). Later the membrane was blocked with 5% BSA for 1 h followed by probing with primary antibody BCL2, Caspase-3 and Caspase-8 (Santa Cruz Biotechnology Inc., Dallas, TX; 1:1,000) incubation overnight at 4 °C. After overnight incubation of primary antibodies the membrane was incubated with secondary HRP conjugated antibodies (1:10,000) for 1 h. Protein bands were imaged using the Bio-Rad Gel imaging system and intensity was examined. All the protein bands were then normalized to that of the vinculin protein and graphs were plotted.

Data display and statistical analysis

The statistical significance between the experimental groups was calculated using one-way analysis of variance (ANOVA) followed by Tukey's post hoc test using GraphPad

Prism v8.0 (San Diego, CA, USA) software. The results of the analysis were expressed as mean (\pm) standard deviation. P -values of less than 0.05 was considered as significant.

Results

Profiling of *Trichopus Zeylanicus* leaves extract

The *Trichopus Zeylanicus* leaf powder was subjected to appropriate solvent and was allowed to dissolve, later the solutions was filtered using nylon membrane mainly used for GC–MS analysis and the chromatogram was obtained as shown in (Fig. S1). The chromatogram was analyzed and list of phytochemical was made as shown in the (Table S1). The phytochemicals with highest concentrations reported were as follows: Farnesol (23.5%), Lupeol acetate (19%), Butylated hydroxytoluene (17.8%), Squalene (7.8%), Lupenone (6.8%), Iridojaponal A (5.9%), β -sitosterol (5.2%), etc.

Effect of ALETZ on liver index & body weight

The body weight of the experimental rats was assessed throughout the course of experiment as shown in Fig. 1C. The results of this evaluation showed that the body weight of the ibuprofen-inebriated group reduced significantly

($P < 0.05$) from that of the normal control group. Whereas in ALETZ pretreated group, a slight reduction in weight was observed for day 1 and day 2. And from day 3 the gain of weight was observed which continued till the last day of the experiment. Additionally, a significant ($P < 0.05$) decrease in the liver index was observed in the ibuprofen-inebriated group, compared to the normal control group. While ALETZ pretreated and ALETZ alone treated groups showed similar liver index that of the normal control group (Fig. 1D).

Effect of ALETZ on liver functional markers

To access the protective effect of ALETZ on ibuprofen-induced hepatotoxicity various functional marker levels was examined. Results obtained represented that there was significant increase ($P < 0.05$) in the levels of ALP, AST, ALT, GGT, total bilirubin and direct bilirubin in serum obtained from ibuprofen-inebriated group when compared to control group. Hence this elevated level of markers signified the hepatic cell damage caused due to ibuprofen in ibuprofen-inebriated group. However, the ALETZ pretreated and ALETZ-alone treated groups retained the levels of these markers near to normal levels (Fig. 2A, B). In addition the levels of albumin and total protein was also evaluated in all the groups, which exhibited substantial decrease of these markers in ibuprofen-inebriated group when compared to

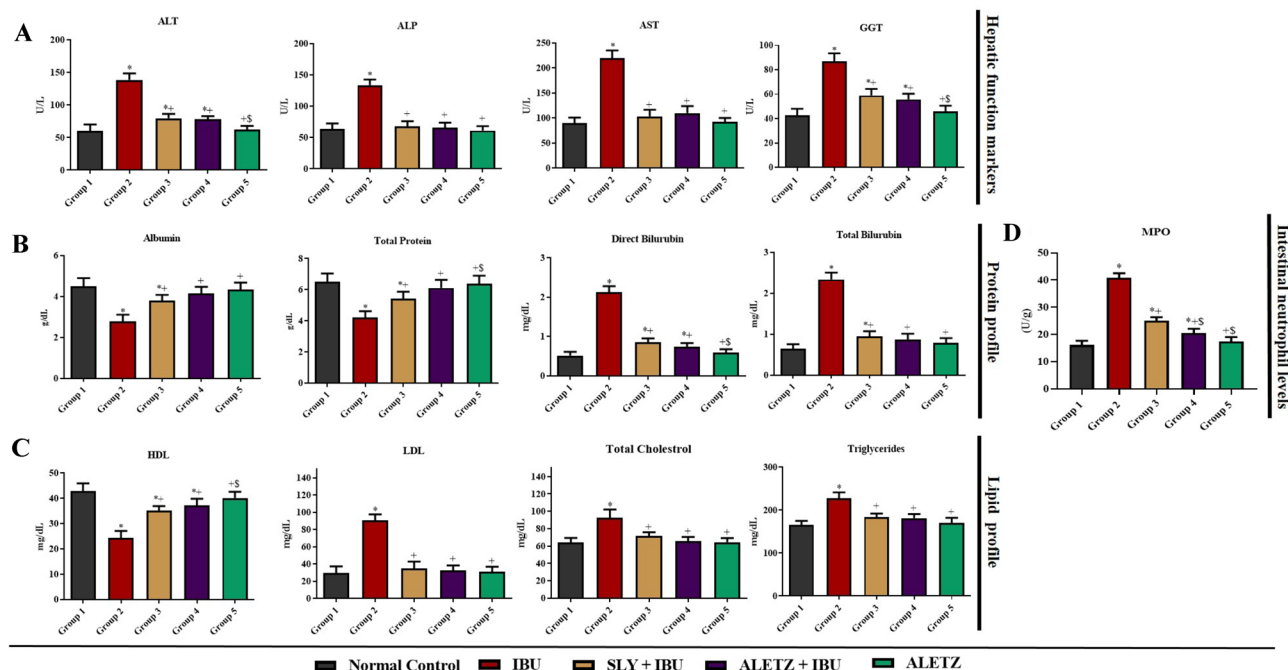


Fig. 2 Effect of ALETZ on biochemical analysis. **A** Hepatic functional marker. **B** Protein profile. **C** Lipid profile. **D** Intestinal functional marker (MPO). IBU-Ibuprofen, ALETZ-Aqueous leaves extract of *Trichopus zeylanicus*, and SLY-Silymarin. (*) represents Normal Control vs IBU, ALETZ+IBU, SLY+IBU and ALETZ;

(+) represents IBU vs ALETZ+IBU, SLY+IBU and ALETZ; (\$) represents SLY+IBU vs ALETZ+IBU and ALETZ; (#) represents ALETZ+IBU vs ALETZ. (*+\$#) $P < 0.05$ delineates the results statistically significant

control. Whereas the ALETZ pretreated group maintained the normal range of albumin and total protein, compared to the silymarin pretreated group, stating its better potency. Furthermore, the levels of HDL, LDL, total cholesterol and triglycerides were examined. This analysis presented a significant ($P < 0.05$) raised levels of LDL, total cholesterol, and triglycerides, besides the lower levels of HDL in the ibuprofen-inebriated group. Whereas in ALETZ pretreated group the levels of these markers were observed close to normal than that of the silymarin pretreated group. Additionally, the ALETZ alone treated group maintained normal levels of these markers as seen in the normal control group (Fig. 2C).

Effect of ALETZ on MPO activity

The MPO activity was evaluated to determine the neutrophil infiltration in the intestine. The results obtained showed a significant raise in neutrophil infiltration in ibuprofen-inebriated group when compared to control group. Moreover, a noteworthy reduction in the levels of MPO was observed in ALETZ-treated groups. This signifies the ALETZ is capable of decreasing the activity of MPO released by the neutrophils (Fig. 2D).

Effect of ALETZ on oxidative stress in liver and intestine

The effect of ibuprofen, ALETZ and silymarin on antioxidant activities in the liver and intestine was assessed using SOD, CAT, GSH and GPx. The results obtained showed that the ibuprofen-inebriated group had notably lower levels of antioxidants as compared to the control group. The reason

behind this might be the antioxidants were utilized in combating the toxins produced due to overdosage of ibuprofen. Moreover, the antioxidant levels in ALETZ and silymarin pretreated groups retained their levels to normal signifying the protective mechanism against ibuprofen toxicity. Later the MDA analysis was performed to assess the fatty acid peroxidation in the cells. The outcome from this analysis showed that there was significant rise in the levels of MDA in liver and intestine tissue homogenate obtained from ibuprofen-inebriated group when compared with normal control. Moreover the levels of MDA were nearly normal in ALETZ and silymarin pretreated groups. The ALETZ alone group has normal level of MDA which was similar to the normal control (Fig. 3A, B). However to examine the morphological changes in liver and intestine the histopathological analysis was carried out.

Effect of ALETZ on histology of liver and intestine

The histological examination was executed for liver and intestine of all the experimental rats used. The histological morphology of the normal control liver showed normal central vein, with sinusoidal spaces, hepatocytes nucleus and Kupffer cell's nucleus. In contrast, the liver architecture disruption in the ibuprofen-inebriated group was seen, along with portal inflammation, inflammatory cell infiltration, hepatocyte degeneration with central vein congestion, and neutrophil infiltration. The ALETZ and silymarin pretreated groups represented mild inflammation along with activation of Kupffer cells. Additionally, they were able to alleviate the inflammation caused by ibuprofen. The ALETZ alone treated group represented the normal liver histological morphology akin to the normal control group (Fig. 4A, B).

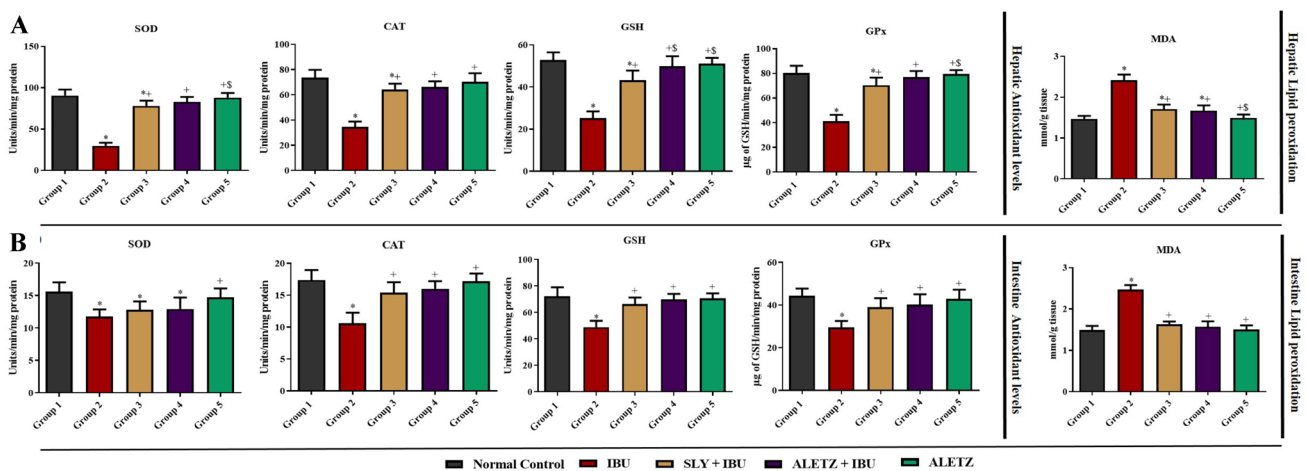


Fig. 3 Effect of ALETZ on antioxidant levels and lipid peroxidation. **A** Liver antioxidant levels. **B** Intestine antioxidant levels. *IBU* IBU-Ibuprofen, *ALETZ*-Aqueous leaves extract of *Trichopus zeylanicus* and *SLY*-Silymarin. (*) represents Normal Control vs IBU,

ALETZ+*IBU*, *SLY*+*IBU* and *ALETZ*; (+) represents *IBU* vs *ALETZ*+*IBU*, *SLY*+*IBU* and *ALETZ*; (\$) represents *SLY*+*IBU* vs *ALETZ*+*IBU* and *ALETZ*; (#) represents *ALETZ*+*IBU* vs *ALETZ*. (* + \$#) $P < 0.05$ delineates the results statistically significant

The histological architecture for the small intestine was examined to assess protective effect of ALETZ on ibuprofen instigated enteropathy. In the normal control group the microvilli, the crypt, goblet cell, enterocyte, and lamina propria of mucosa were intact representing the normal intestinal morphology. Whereas in the ibuprofen-inebriated group inflammatory infiltration, goblet cell depletion, crypt loss, and microvilli disruption were observed, signifying the damage caused by ibuprofen. The silymarin pretreated group represented the mild inflammation and mild reduction in the size of villi. However the ALETZ pretreated group and ALETZ alone treated group exhibited the normal intestinal histological morphology similar to normal control group (Fig. 4C, D). Later the anti/pro inflammatory cytokines levels was examined to confirm the occurrence of inflammation.

Effect of ALETZ on anti/ pro-inflammatory cytokines levels

The raised levels of pro-inflammatory cytokines such as TNF- α , IL-6, and IL-1 β in the liver and intestine tissue homogenates, were observed in the ibuprofen-inebriated

group. However, normal levels of these cytokines were observed in ALETZ pretreated group. The silymarin pretreated group also demonstrated a reduction in the levels of TNF- α , IL-6 and IL-1 β cytokines. Additionally, anti-inflammatory cytokine IL-10 levels were measured in all five groups. The results from this analysis demonstrated that IL-10 levels were significantly low in the ibuprofen-inebriated group. However, the silymarin and ALETZ pretreated group were shown to have higher levels of IL-10 than the ibuprofen-inebriated group. Moreover, the ALETZ alone treated group had shown to have normal levels of TNF- α , IL-6, IL-1 β , and IL-10 (Fig. 5A, B). In addition the effect of ALETZ modulating effect on apoptosis was carried out liver and intestine.

Effect of ALETZ on apoptotic signaling in liver and intestine

The expression of apoptotic signaling markers such as caspase-8, caspase-3 and Bcl-2 was assessed to investigate the protective mechanism of ALETZ against ibuprofen induced liver and intestinal toxicities. Hence the results

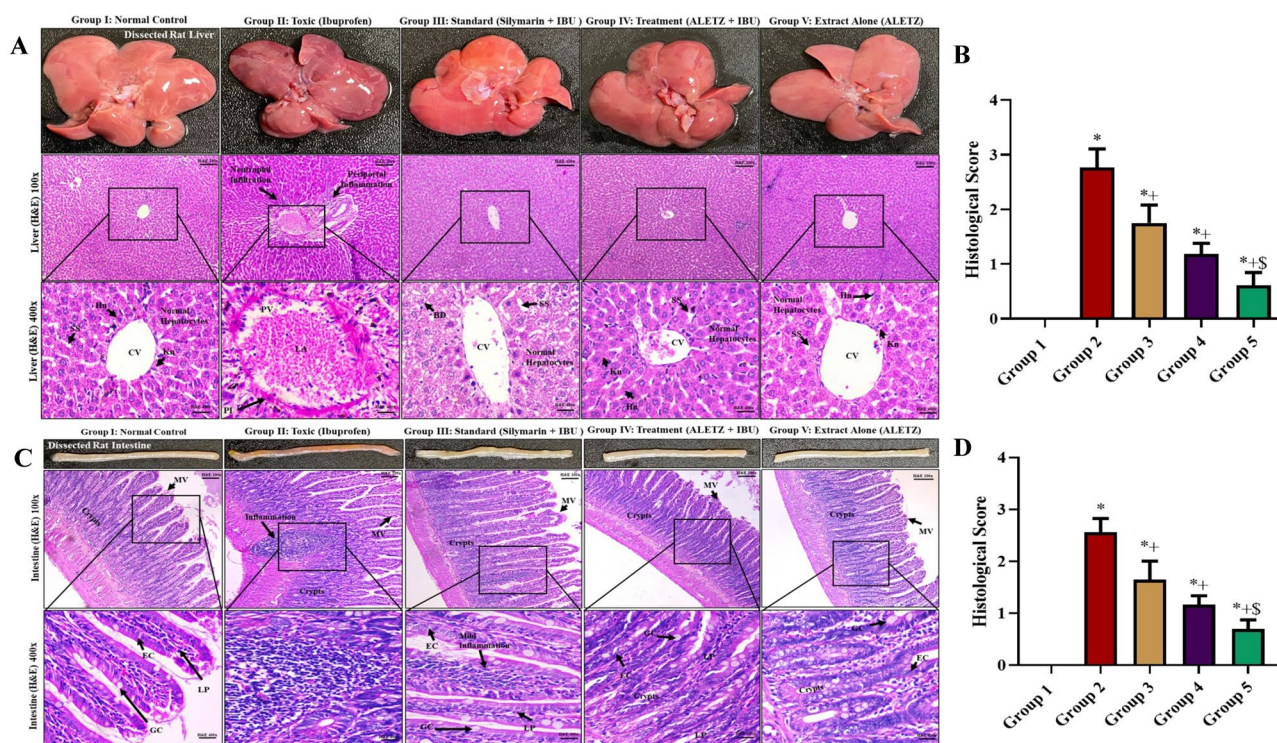


Fig. 4 Histological assessment. **A** Represents the H&E staining of liver tissues. **B** Histological score of liver tissue. **C** Represents the H&E staining of intestine tissues. **D** Histological score of intestine tissue. CV-central vein, Kn-kupffer cell nucleus, Hn-hepatic cell nucleus, SS-Sinusoidal space, PV-portal vein, BD-bile duct, MV-micro villi, EC-enterocyte, GC-goblet cells, LP-lamina pro-

pria, IBU-Ibuprofen, ALETZ-Aqueous leaves extract of *Trichopus zeylanicus*, and SLY-Silymarin. (*) represents Normal Control vs IBU, ALETZ + IBU, SLY + IBU and ALETZ; (+) represents IBU vs ALETZ + IBU, SLY + IBU and ALETZ; (\$) represents SLY + IBU vs ALETZ + IBU and ALETZ; (#) represents ALETZ + IBU vs ALETZ. (* + \$#) $P < 0.05$ delineates the results statistically significant

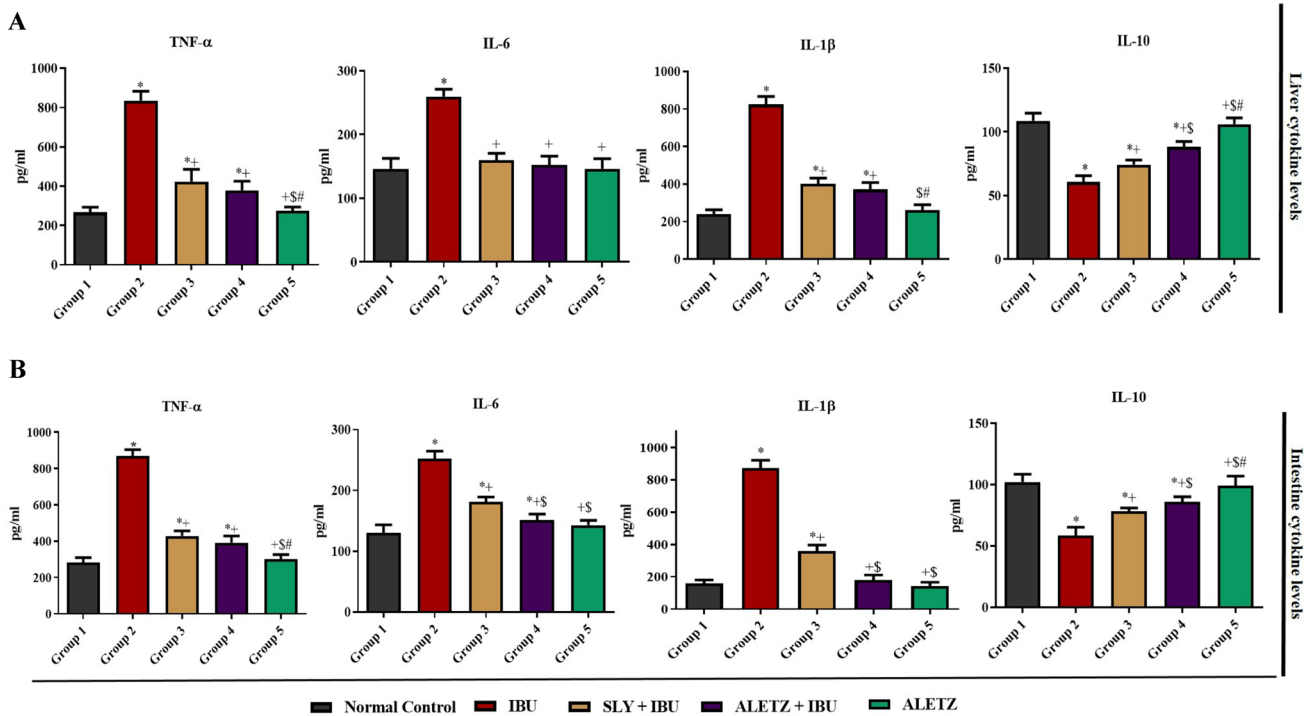


Fig. 5 ALETZ modulates the cytokine levels. **A** Represents the effect of ALETZ on pro-inflammatory makers such TNF- α , IL-6, IL-1 β and anti-inflammatory maker such as IL-10 of liver. **B** Represent the effect of ALETZ on pro-inflammatory makers such TNF- α , IL-6, IL-1 β and anti-inflammatory maker such as IL-10 of Intestine. IBU-Ibuprofen, ALETZ-Aqueous leaf extract of *Trichopus zey-*

lanicus, and SLY-Silymarin. (*) represents Normal Control vs IBU, ALETZ+IBU, SLY+IBU and ALETZ; (+) represents IBU vs ALETZ+IBU, SLY+IBU and ALETZ; (\$) represents SLY+IBU vs ALETZ+IBU and ALETZ; (#) represents ALETZ+IBU vs ALETZ. (*+\$#) $P < 0.05$ delineates the results statistically significant

obtained exhibited the significant decrease in expression of anti-apoptotic marker Bcl-2; however, there was increase in levels of pro-inflammatory cytokines such as caspase-8 and caspase-3 in ibuprofen-inebriated group. In the ALETZ pretreated group the expression of Bcl-2, caspase-3 and caspase-8 was equal to normal which signified the ALETZ role in regulating the ibuprofen induced protein expression via reducing hepatocyte injury due to ibuprofen administration. When compared to silymarin pretreated group the ALETZ pretreated group showed better result. ALTEZ alone treated group showed normal levels of Bcl-2, caspase-3 and caspase-8. The histograms of fold change over control group for all the five groups have been represented in (Fig. 6A, B).

Discussion

NSAIDs are the most widely used medications in the world because of their effectiveness and accessibility. However, this success of NSAIDs is accompanied by very severe, unavoidable side effects that account for more than 30% of hospital admissions for overdose (Simon and Evan Prince 2017). Since NSAIDs are accountable for serious side effects medical professionals have expressed great concern about

using them. After aspirin, one of the most well-known and widely used NSAIDs is ibuprofen, which is sold without a prescription (Rainsford 2009). An overdose of ibuprofen causes mitochondrial stress, idiosyncratic reactions, and the generation of reactive oxygen species.

At high dose ibuprofen is capable of depleting the GSH conjugation, which causes reduction in the levels of antioxidants along with accumulation of toxic metabolites in the cell (Cazanave et al. 2008; Pinnen et al. 2011). This results in peroxidative damage to the cell membrane by disrupting the mitochondrial transmembrane. This transmembrane damage causes a diminution of ATP production which stimulates cell necrosis (Ayala et al. 2014). Therefore, here we appraised the protective mechanism of ALETZ against ibuprofen induced hepatic and intestinal toxicity via modulating the oxidative stress, inflammation and apoptotic signaling. In this study, the bodyweight of all the experimental rats was recorded daily, and the results showed that the body weight of the ibuprofen inebriated group decreased significantly ($P < 0.05$), indicating the ibuprofen's toxic effects. Ibuprofen might have caused gastrointestinal tract ulcers in rats, which made it difficult for them to eat, resulting their body weight to drop. Moreover, the ALETZ alone treated group gained weight for all five days, same as a normal control

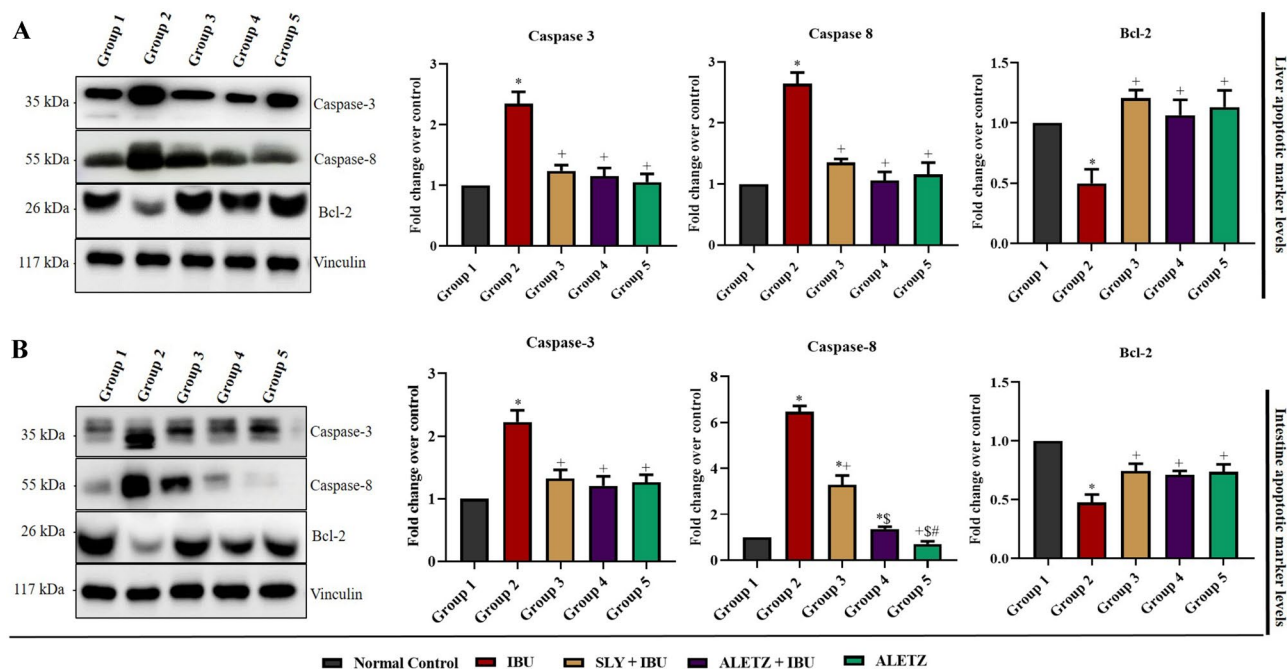


Fig. 6 ALETZ modulates the apoptotic signaling. **A** Represents the protein expression of Caspase-3, Caspase-8 and Bcl-2 in liver using western blotting analysis. **B** Represents the protein expression of Caspase-3, Caspase-8 and Bcl-2 in intestine using western blotting analysis. IBU-Ibuprofen, ALETZ-Aqueous leaf extract of *Trichopus*

zeylanicus, and SLY-Silymarin. (*) represents Normal Control vs IBU, ALETZ+IBU, SLY+IBU and ALETZ; (+) represents IBU vs ALETZ+IBU, SLY+IBU and ALETZ; (\$) represents SLY+IBU vs ALETZ+IBU and ALETZ; (#) represents ALETZ+IBU vs ALETZ. (*+\$#) $P < 0.05$ delineates the results statistically significant

group. Whereas the ALETZ pretreated group showed a slight decrease in weight for the first 2 days and then from 3rd day they started to gain weight which signifies ALETZ's capabilities in restoring the damage caused by ibuprofen. Ibuprofen overdose contributes to hepatocyte damage by increasing cellular permeability, which raises serum levels of ALT, ALP, AST, GGT, total bilirubin and direct bilirubin (Shahnazarian et al. 2018). The elevation in the hepatic enzyme markers might be due to leakage of these markers in circulation which signifies the hepatic injury. However the levels of albumin and total protein levels were significantly reduced in ibuprofen inebriated group when compared to normal control group. Furthermore, the ibuprofen-inebriated group had lower HDL levels and higher levels of LDL, total cholesterol, and triglyceride, which indicated dyslipidemia. In contrast the ALETZ pretreated group was observed to restore the levels of HDL, LDL, total cholesterol and triglycerides near to normal control group. This implied the ALETZ's ability to protect against ibuprofen-induced dyslipidemia. The intestine plays a very vital role in digestion and nutrition assimilation, therefore damage to the intestine may lead to serious ailments (Sensoy 2021). Therefore to examine the intestinal damage caused due to ibuprofen we measured the levels of MPO. The results observed represented the significant rise in the levels of MPO in the ibuprofen-inebriated group which signified the neutrophil infiltration.

Athwart the levels of MPO were restored to the normal in ALETZ pretreated group which inferred that it prevents the intestinal damage caused due to ibuprofen.

Ibuprofen overdose causes the alteration in the SOD, CAT, GSH, and GPx antioxidants levels in various organs (Zoubair 2016; Kim et al. 2021). In this study the antioxidant levels in ibuprofen -inebriated group was found to be decreased in the liver and intestine. The SOD is one of the vital antioxidant enzymes that catalyzes the conversion of O_2^- (superoxide anion) into O (molecular oxygen) or H_2O_2 (hydrogen peroxide) which are important in scavenging the ROS (Fukai and Ushio-Fukai 2011). Therefore, reduction in the levels of SOD in ibuprofen inebriated group causes decline in SOD ability to scavenge ROS. Furthermore the ALETZ pretreated group maintained the SOD levels to normal and nearly similar result was observed in silymarin pretreated and ALETZ alone treated group. The CAT is one of important enzyme that prevents cells from oxidative damage; hence decrease in its level might lead cells to oxidative damage. Thus, a decrease in CAT levels was seen in the ibuprofen-inebriated group, suggesting that ibuprofen may be able to cause oxidative damage to cells via modulating CAT levels. The group that received ALETZ pretreatment had levels of CAT that were normal and showed no signs of oxidative damage. Moreover, the lipid peroxidation was observed by assessing the MDA levels in the

ibuprofen-inebriated group which indicated the increased levels of MDA that signified excess of ROS production and subsequently causing membrane and tissue damage (Ayala et al. 2014; Naji et al. 2021). In ALETZ pretreated the MDA levels were similar to the normal control group which presented no membrane or tissue damage. The reduce levels of GSH was seen in the ibuprofen-inebriated group that indicated reduction in the ability of the cell to prevent cellular damage caused due to ibuprofen. In contrast the normal levels of GSH was maintained by ALETZ pretreated group that connoted the reduction in cellular damage. Collating the outcomes obtained from aforementioned analysis, we could infer ALETZ pretreatment safeguards liver and intestine against free radical mediated oxidative stress by scavenging ROS besides restraining lipid peroxidation and averting antioxidant depletion.

The histopathology analysis of liver and intestine tissues from all five groups interestingly replicated these observations, confirming the ALETZ protective mechanism against ibuprofen toxicity. The pretreatment of ALETZ was able to revert the hepatocyte damage and inflammation triggered due to ibuprofen. However, ibuprofen-inebriated group presented swollen hepatocytes, pyknotic nuclei in hepatocytes with portal inflammation. The ALETZ treated group maintained the normal hepatic architecture and the almost similar result was observed in silymarin pretreated group with some Kupffer cell activated. Additionally the histological analysis of intestine presented degenerative changes like crypt loss, goblet cell reduction and inflammatory infiltration in lamina propria of ibuprofen-inebriated group. In contrast the ALETZ pretreated group showed normal morphology as of normal control group. Besides, the silymarin pretreated group showed some inflammatory cells in micro villi. Whereas normal intestinal architecture was observed in ALETZ alone treated group. As was mentioned previously, the decrease in GSH levels results in oxidative stress, which in turn causes mitochondrial oxidative stress. This causes activation of pro-inflammatory cytokines such TNF- α , IL-6 and IL-1 β (Dauletbaev et al. 2010; Ahmadi et al. 2022). The IL-6 is active mediator of acute phase response which plays a vital role in controlling the levels of IL-10 an anti-inflammatory cytokine (Kothari et al. 2014). The TNF- α and IL-6 are known to be elevated during the course of stress and inflammation. IL-1 β plays important role in mediating the cellular inflammation, differentiation and apoptosis. IL-1 β raised levels have been reported to act as autocrine growth factor in various cancers. In this study we observed the raised levels of TNF- α , IL-6 and IL-1 β cytokines along with decrease in the levels of IL-10 in ibuprofen-inebriated group. This observation signified ibuprofen imbalances the levels of pro and anti-inflammatory cytokines making liver and intestine more susceptible

to the inflammation. Additionally in ALETZ pretreated group the levels of TNF- α , IL-6, IL-1 β and IL-10 were retained to normal control group. Considering the results obtained, the ALETZ indicated to possess the anti-inflammatory effect protecting against ibuprofen-induced hepatic and intestinal toxicity.

Ibuprofen has been reported to cause DNA fragmentation via activation of caspases (Berns et al. 2009). Hence in this study, the modulatory effect of ibuprofen on apoptotic signaling markers such as initiator caspase-8, effector caspase-3 and Bcl-2 was assessed in liver and intestine using western blotting technique. The caspase-3 is known to be activated during the time of cell death or if any injury caused to cell. Therefore, significant elevation of caspase-3 was observed in the ibuprofen-inebriated group which demonstrated ibuprofen caused cellular damage. It also implied ibuprofen modulates the mitochondria mediated apoptosis via elevating the levels of caspase-3 in ibuprofen-inebriated group. The caspase-8 is cysteine protease that plays important role in extrinsic apoptotic signaling via death receptors. In this study the raised level of caspase-8 besides Bcl-2, an anti-apoptotic marker levels, was observed to be reduced in ibuprofen inebriated group. Whereas the levels of caspase-3, caspase-8, and Bcl-2 were presented to the normal in ALETZ pretreated group. This signifies that ALETZ alleviated apoptosis in the liver and intestine via reducing the levels of caspase-3 and caspase-8. Moreover, it also maintains the level of Bcl-2 as that of the normal control group.

Accumulating evidence has suggested that ibuprofen overdose generates free radical which ultimately causes oxidative stress, activates inflammatory machinery and increases apoptosis. Therefore, this was the first study to have observed that ALETZ pretreatment reducing the oxidative stress caused due to overdosing of ibuprofen in liver and intestine. Moreover, ALETZ pretreatment was able to exert downregulation of inflammatory mediators, via increasing the liver and intestine antioxidant defense machinery. Besides, our study also demonstrated that ALETZ pretreatment alleviated the pro-apoptotic marker levels (Fig. 7). Therefore, we conclude that use of ALETZ significantly shows a protective mechanism against ibuprofen induced liver and intestine toxicity via modulation of oxidative stress, pro/anti-inflammatory cytokines and apoptosis signaling.

Conclusion

To conclude, the result obtained from the study demonstrated the ALETZ (1000 mg/kg b.w) pretreatment was capable of attenuating the ibuprofen-inebriated hepatic and small intestine toxicity via modulating the oxidative

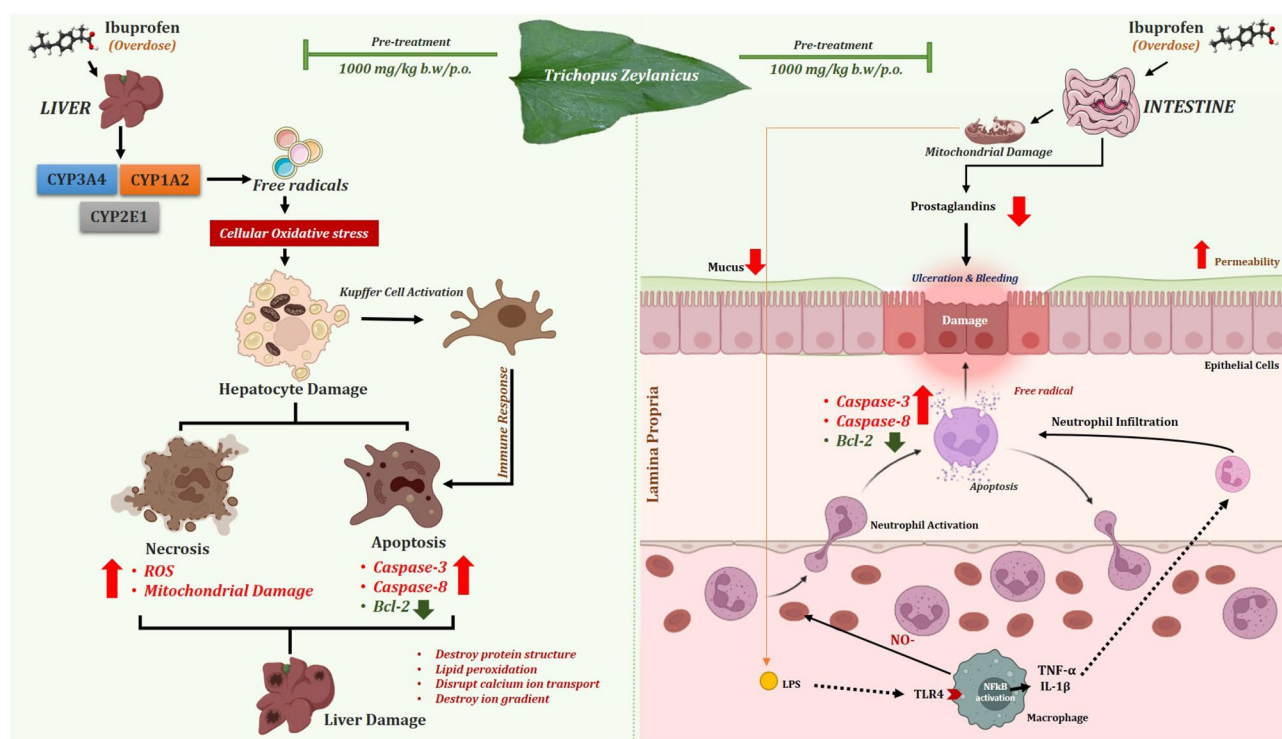


Fig. 7 Overall mechanism of action of ALETZ. The figure represents ALETZ as a potential mediator that inverses the ibuprofen instigated hepatic and intestinal toxicity via modulating the oxidative stress, inflammatory and apoptotic signaling in liver and intestine when pre-treated

stress, inflammation and apoptotic signaling. Additionally, ALETZ was found to restore the levels of liver and intestine enzyme markers, antioxidant and histological architecture. It also retained the levels of TNF- α , IL-6, IL-1 β and IL-10 cytokine. The protein expression of Caspase-3, Caspase-8 and Bcl-2 was observed to be near to normal in ALETZ treated group. Additionally ALETZ alone treated group has not shown any signs of toxicity. Thus study conducted concluded the beneficial effect of ALETZ against ibuprofen induced hepatotoxicity and enteropathy in wistar albino rats. In the future, it will be important to identify and evaluate potential active molecules derived from *Trichopus zeylanicus* against ibuprofen persuaded toxicities. Hence, further studies are obligatory to elucidate the mechanisms of action of these pharmacological activities.

Supplementary Information The online version contains supplementary material available at <https://doi.org/10.1007/s10787-022-01052-5>.

Acknowledgements The authors are thankful to the Vellore Institute of Technology, Vellore, India for providing the necessary facilities to carry out this work.

Author contributions NKP: conceptualization, literature survey, performed experiment, writing—original draft. PS: literature survey,

writing—original draft. SEP: conceptualization, supervision, literature survey, writing—original draft.

Funding No funding was received for this work.

Data availability Enquiries about data availability should be directed to the authors.

Declarations

Conflict of interest All the authors declare no conflict of interest for this work.

Ethical clearance For this study animal ethical clearance was obtained from animal house facility, Vellore Institute of Technology, Vellore, Tamil Nadu India.

References

- Ağagündüz D, Şahin TÖ, Yılmaz B et al (2022) Cruciferous vegetables and their bioactive metabolites: from prevention to novel therapies of colorectal cancer. *Evid-Based Complement Altern Med*. <https://doi.org/10.1155/2022/1534083>
- Ahmadi M, Bekeşchus S, Weltmann K-D et al (2022) Non-steroidal anti-inflammatory drugs: recent advances in the use of synthetic

- COX-2 inhibitors. RSC Med Chem. <https://doi.org/10.1039/d1md00280e>
- Ahmed S, Khan H, Aschner M et al (2020) Anticancer potential of furanocoumarins: Mechanistic and therapeutic aspects. *Int J Mol Sci* 21:1–20. <https://doi.org/10.3390/ijms21165622>
- Akkol EK, Tatli II, Karatoprak GŞ et al (2021) Is emodin with anticancer effects completely innocent? Two sides of the coin. *Cancers* 13:1–52. <https://doi.org/10.3390/cancers13112733>
- Ayala A, Muñoz MF, Argüelles S (2014) Lipid peroxidation: production, metabolism, and signaling mechanisms of malondialdehyde and 4-hydroxy-2-nonenal. *Oxid Med Cell Longev*. <https://doi.org/10.1155/2014/360438>
- Berns M, Toennesen M, Koehne P et al (2009) Ibuprofen augments bilirubin toxicity in rat cortical neuronal culture. *Pediatr Res* 65:392–396. <https://doi.org/10.1203/PDR.0b013e3181991511>
- Bertolini A, Ottani A, Sandrini M (2001) Dual acting anti-inflammatory drugs: a reappraisal. *Pharmacol Res* 44:437–450. <https://doi.org/10.1006/phrs.2001.0872>
- Biju VC, Shidhi PR, Rajan VS, Anoop PKASN (2019) Therapeutic properties of *Trichopus zeylanicus* Subsp. *travancoricus*, a rare, endangered medicinal plant in South India: a review. *Herb Med* 5:1–11. <https://doi.org/10.21767/2472-0151.100040>
- Bozimowski G (2015) A review of nonsteroidal anti-inflammatory drugs. *AANA J* 83:425–433
- Bushra R, Aslam N (2010) An overview of clinical pharmacology of ibuprofen. *Oman Med J* 25:155–161. <https://doi.org/10.5001/omj.2010.49>
- Cazanave S, Vadrot N, Tinel M et al (2008) Ibuprofen administration attenuates serum TNF- α levels, hepatic glutathione depletion, hepatic apoptosis and mouse mortality after Fas stimulation. *Toxicol Appl Pharmacol* 231:336–343. <https://doi.org/10.1016/j.taap.2008.05.010>
- Dauletbaev N, Lam J, Eklove D et al (2010) Ibuprofen modulates NF- κ B activity but not IL-8 production in cystic fibrosis respiratory epithelial cells. *Respiration* 79:234–242. <https://doi.org/10.1159/000255342>
- Fahad FI, Barua N, Shafiqul Islam M et al (2021) Investigation of the pharmacological properties of lepidagathis hyalina nees through experimental approaches. *Life* 11:1–16. <https://doi.org/10.3390/life11030180>
- Farooq U, Khan T, Shah SA et al (2021) Isolation, characterization and neuroprotective activity of folecitin: an in vivo study. *Life*. <https://doi.org/10.3390/life11080825>
- Freitas MA, Vasconcelos A, Gonçalves ECD et al (2021) Involvement of opioid system and trpm8/trpa1 channels in the antinociceptive effect of spirulina platensis. *Biomolecules*. <https://doi.org/10.3390/biom11040592>
- Fukai T, Ushio-Fukai M (2011) Superoxide dismutases: role in redox signaling, vascular function, and diseases. *Antioxid Redox Signal* 15:1583–1606. <https://doi.org/10.1089/ars.2011.3999>
- Gonçalves ECD, Baldasso GM, Bicca MA et al (2020) Terpenoids, cannabimimetic ligands, beyond the cannabis plant. *Molecules* 25:1–47. <https://doi.org/10.3390/molecules25071567>
- Goni O, Khan MF, Rahman MM et al (2021) Pharmacological insights on the antidepressant, anxiolytic and aphrodisiac potentials of *Aglaonema hookerianum* Schott. *J Ethnopharmacol* 268:113664. <https://doi.org/10.1016/j.jep.2020.113664>
- Hall AH, Smolinske SC, Conrad FL et al (1986) Ibuprofen overdose: 126 cases. *Ann Emerg Med* 15:1308–1313. [https://doi.org/10.1016/s0196-0644\(86\)80617-5](https://doi.org/10.1016/s0196-0644(86)80617-5)
- Hemamalini V, Velayutham DPM, Lakshmanan L et al (2020) Inhibitory potential of Hydroxychavicol on Ehrlich ascites carcinoma model and in silico interaction on cancer targets. *Nat Prod Res* 34:1591–1596. <https://doi.org/10.1080/14786419.2018.1519819>
- Hossain S, Urbi Z, Karuniawati H et al (2021) *Andrographis paniculata* (Burm. f.) wall. ex nees: An updated review of phytochemistry, antimicrobial pharmacology, and clinical safety and efficacy. *Life* 11:1–39. <https://doi.org/10.3390/life11040348>
- Hunter LJ, Wood DM, Dargan PI (2011) The patterns of toxicity and management of acute nonsteroidal anti-inflammatory drug (NSAID) overdose. *Open Access Emerg Med* 3:39–48. <https://doi.org/10.2147/OAEM.S22795>
- Iqbal J, Abbasi BA, Ahmad R et al (2020) Phytochemical synthesis of nickel oxide nanoparticles (NiO) using fresh leaves extract of *Rhamnus triquetra* (Wall.) and investigation of its multiple in vitro biological potentials. *Biomedicines*. <https://doi.org/10.3390/BIOMEDICINES8050117>
- Islam N, Khan MF, Khatun MR et al (2021) Neuropharmacological insights of African oil palm leaf through experimental assessment in rodent behavioral model and computer-aided mechanism. *Food Biosci* 40:100881. <https://doi.org/10.1016/j.fbio.2021.100881>
- Jahan I, Khan MF, Sayeed MA et al (2022) Neuropharmacological and Antidiarrheal Potentials of *Duabanga grandiflora* (DC.) Walp. Stem bark and prospective ligand-receptor interactions of its bioactive lead molecules. *Curr Issues Mol Biol* 44:2335–2349. <https://doi.org/10.3390/cimb44050159>
- Johansson M, Strahm E, Rane A, Ekström L (2014) CYP2C8 and CYP2C9 mRNA expression profile in the human fetus. *Front Genet* 5:58. <https://doi.org/10.3389/fgene.2014.00058>
- Kaduševičius E (2021) Novel applications of nsais: Insight and future perspectives in cardiovascular, neurodegenerative, diabetes and cancer disease therapy. *Int J Mol Sci*. <https://doi.org/10.3390/ijms22126637>
- Khan MF, Bin KF, Arman M et al (2020) Pharmacological insights and prediction of lead bioactive isolates of Dita bark through experimental and computer-aided mechanism. *Biomed Pharmacol* 131:110774. <https://doi.org/10.1016/j.biopha.2020.110774>
- Kim M, Lee EJ, Lim KM (2021) Ibuprofen increases the hepatotoxicity of ethanol through potentiating oxidative stress. *Biomol Ther* 29:205–210. <https://doi.org/10.4062/biomolther.2020.108>
- Kothari P, Pestana R, Mesraoua R et al (2014) IL-6-mediated induction of matrix metalloproteinase-9 is modulated by JAK-dependent IL-10 expression in macrophages. *J Immunol (Baltimore, Md: 1950)* 192:349–357. <https://doi.org/10.4049/jimmunol.1301906>
- Liu R, Wu S, Guo C et al (2020) Ibuprofen exerts antiepileptic and neuroprotective effects in the rat model of pentylenetetrazol-induced epilepsy via the COX-2/NLRP3/IL-18 pathway. *Neurochem Res* 45:2516–2526. <https://doi.org/10.1007/s11064-020-03109-9>
- Majee C, Mazumder R, Choudhary AN (2019) Medicinal plants with anti-ulcer and hepatoprotective activity: a review. *Inte J Pharm Sci Res 1 IJPSR* 10:1–11. [https://doi.org/10.13040/IJPSR.0975-8232.10\(1\).1-11](https://doi.org/10.13040/IJPSR.0975-8232.10(1).1-11)
- Marklund S, Marklund G (1974) Involvement of the superoxide anion radical in the autoxidation of pyrogallol and a convenient assay for superoxide dismutase. *Eur J Biochem* 47:469–474. <https://doi.org/10.1111/j.1432-1033.1974.tb03714.x>
- Martínez V, Iriando De-Hond A, Borrelli F et al (2020) Cannabidiol and other non-psychoactive cannabinoids for prevention and treatment of gastrointestinal disorders: useful nutraceuticals? *Int J Mol Sci*. <https://doi.org/10.3390/ijms21093067>
- Moore N, Duong M, Gulmez SE et al (2019) Pharmacoeconomics of non-steroidal anti-inflammatory drugs. *Therapie* 74:271–277. <https://doi.org/10.1016/j.therap.2018.11.002>
- Naji KM, Al-Khatib BY, Al-Haj NS, D'souza MR (2021) Hepatoprotective activity of melittin on isoniazid- and rifampicin-induced liver injuries in male albino rats. *BMC Pharmacol Toxicol* 22:1–11. <https://doi.org/10.1186/s40360-021-00507-9>
- Rajani A, Vishnu M, Vardhan Reddy, et al (2014) Evaluation of Anti-Ulcer Activity of Methanolic extract of leaves of *Trichopus Zeylanicus*. *Int J Phytopharmacology* 5:198–200

- Pinnen F, Sozio P, Cacciatore I et al (2011) Ibuprofen and glutathione conjugate as a potential therapeutic agent for treating Alzheimer's disease. *Arch Pharm* 344:139–148. <https://doi.org/10.1002/ardp.201000209>
- Prusakiewicz JJ, Duggan KC, Rouzer CA, Marnett LJ (2009) Differential sensitivity and mechanism of inhibition of COX-2 oxygenation of arachidonic acid and 2-arachidonoylglycerol by ibuprofen and mefenamic acid. *Biochemistry* 48:7353–7355. <https://doi.org/10.1021/bi900999z>
- Pushpangadan P, Rajasekharan S, Ratheshkumar PK et al (1988) "Arogyappacha" (*Trichopus zeylanicus* gaerin), the "Ginseng" of Kani tribes of Agashyar hills (Kerala) for ever green health and vitality. *Anc Sci Life* 8:13–16
- Rainsford KD (2009) Ibuprofen: pharmacology, efficacy and safety. *Inflammopharmacology* 17:275–342. <https://doi.org/10.1007/s10787-009-0016-x>
- Rotruck JT, Pope AL, Ganther HE et al (1973) Selenium: biochemical role as a component of glutathione peroxidase. *Science (New York, NY)* 179:588–590. <https://doi.org/10.1126/science.179.4073.588>
- Sensoy I (2021) A review on the food digestion in the digestive tract and the used in vitro models. *Curr Res Food Sci* 4:308–319. <https://doi.org/10.1016/j.crfs.2021.04.004>
- Shahnazarian V, Ramai D, Reddy M (2018) A rare case of ibuprofen-induced acute liver injury. *Cureus* 10:e3225
- Simon JP, Evan Prince S (2017) Natural remedies for non-steroidal anti-inflammatory drug-induced toxicity. *J Appl Toxicol* 37:71–83. <https://doi.org/10.1002/jat.3391>
- Simon JP, Evan Prince S (2018) Diclofenac-induced renal toxicity in female Wistar albino rats is protected by the pre-treatment of aqueous leaves extract of *Madhuca longifolia* through suppression of inflammation, oxidative stress and cytokine formation. *Biomed Pharmacother* 98:45–51. <https://doi.org/10.1016/j.biopha.2017.12.028>
- Simon JP, Parthasarathy M, Nithyanandham S et al (2019) Protective effect of the ethanolic and methanolic leaf extracts of *Madhuca longifolia* against diclofenac-induced toxicity in female Wistar albino rats. *Pharmacol Rep* 71:983–993. <https://doi.org/10.1016/j.pharep.2019.05.013>
- Sinan KI, Akpulat U, Aldahish AA et al (2021) LC-MS/HRMS analysis, anti-cancer, anti-enzymatic and anti-oxidant effects of *Boerhavia diffusa* extracts: a potential raw material for functional applications. *Antioxidants*. <https://doi.org/10.3390/antiox10122003>
- Sinha AK (1972) Colorimetric assay of catalase. *Anal Biochem* 47:389–394. [https://doi.org/10.1016/0003-2697\(72\)90132-7](https://doi.org/10.1016/0003-2697(72)90132-7)
- Sriuttha P, Sirichanchuen B, Permsuwan U (2018) Hepatotoxicity of nonsteroidal anti-inflammatory drugs: a systematic review of randomized controlled trials. *Int J Hepatol*. <https://doi.org/10.1155/2018/5253623>
- Subramoniam A, Madhavachandran V, Rajasekharan S, Pushpangadan P (1997) Aphrodisiac property of *Trichopus zeylanicus* extract in male mice. *J Ethnopharmacol* 57:21–27. [https://doi.org/10.1016/S0378-8741\(97\)00040-8](https://doi.org/10.1016/S0378-8741(97)00040-8)
- Tallei TE, Fatimawali NNJ et al (2021) A comprehensive review of the potential use of green tea polyphenols in the management of COVID-19. *Evid-Based Complement Altern Med*. <https://doi.org/10.1155/2021/7170736>
- Uddin Chy MN, Adnan M, Chowdhury MR et al (2021) Central and peripheral pain intervention by *Ophiorrhiza rugosa* leaves: Potential underlying mechanisms and insight into the role of pain modulators. *J Ethnopharmacol* 276:114182. <https://doi.org/10.1016/j.jep.2021.114182>
- Vieira G, Cavalli J, Gonçalves ECD et al (2020) Antidepressant-like effect of terpineol in an inflammatory model of depression: involvement of the cannabinoid system and D2 dopamine receptor. *Biomolecules* 10:1–23. <https://doi.org/10.3390/biom10050792>
- Ward JR (1984) Update on ibuprofen for rheumatoid arthritis. *Am J Med* 77:3–9. [https://doi.org/10.1016/s0002-9343\(84\)80012-1](https://doi.org/10.1016/s0002-9343(84)80012-1)
- Zappavigna S, Cossu AM, Grimaldi A et al (2020) Anti-inflammatory drugs as anticancer agents. *Int J Mol Sci* 21:1–29. <https://doi.org/10.3390/ijms21072605>
- Zoubair B (2016) Evaluation of Diclofenac effect on oxidative stressed mice. *Inte J Pure Appl Biosci* 4:1–8. <https://doi.org/10.18782/2320-7051.2232>

Publisher's Note Springer Nature remains neutral with regard to jurisdictional claims in published maps and institutional affiliations.

Springer Nature or its licensor holds exclusive rights to this article under a publishing agreement with the author(s) or other rightsholder(s); author self-archiving of the accepted manuscript version of this article is solely governed by the terms of such publishing agreement and applicable law.