



OPEN ACCESS

Concurrent growth hormone-producing pituitary adenoma and Rathke's cleft cyst

Alamin Alkundi ,^{1,2} Rabiuh Momoh ,³ Marcus Nash⁴

¹Diabetes and Endocrinology, East Kent Hospitals University NHS Foundation Trust, Canterbury, UK

²Medical Education, Cardiff University, Cardiff, UK

³Intensive Care Medicine, East Kent Hospitals University NHS Foundation Trust, Ashford, UK

⁴General Medicine, William Harvey Hospital, Ashford, UK

Correspondence to

Dr Alamin Alkundi; alamin.alkundi@nhs.net and Dr Rabiuh Momoh; rabiuh.momoh@nhs.net

Accepted 29 July 2022

SUMMARY

A case report describing a finding of concurrent growth hormone-producing pituitary adenoma and a radiologic evidence of Rathke's cleft cyst (RCC) in a middle-aged female is presented. We reviewed the literature and discussed management perspectives for this uncommon finding.

BACKGROUND

Rathke's cleft is the area between the anterior and posterior pituitary glands. The anterior and posterior pituitary glands have different embryological origins (the oral ectoderm and the neural ectoderm, respectively). This cleft (a remnant of the embryonic Rathke's pouch) is usually obliterated in a lot of individuals. There is a rare possibility of the intervening Rathke's cleft developing a cyst(s). Rathke's cleft cyst (RCCs), depending on size, are usually largely asymptomatic.¹ There is increasing documentation of RCC with incidental, concurrent or onward findings of pituitary adenomas in the body of medical literature. Whether this association is an incidental one or whether there is a causative relationship between these two entities remains to be fully explored.²

CASE PRESENTATION

A middle-aged woman presented at the emergency department with a 3-day history of frontal headache and over the left side of her face, of gradual onset, constant and rated 7/10 in severity at presentation. She had reported recurrent similar headaches within the preceding year. She reported normal vision at the time of review but reported having recurrent intermittent blurred vision and dizziness. She reported no recent head trauma and had not noticed any changes to visual fields. She reported no nausea or vomiting. No weakness/numbness in limbs was reported.

She reported swollen feet and hands and her wedding ring does not fit anymore. She had noticed an increase in her shoe size and had increased gaps between teeth. She reported a gradual weight gain and weighed 95 kg (but usually had been around 80 kg). The patient had undergone a tympanoplasty 5 years prior. Her other medical history also includes bilateral otosclerosis, uses hearing aid and tinnitus masker.

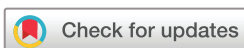On examination, a coarse facial, frontal bossing and proximal myopathy was noted. Blood pressure 144/79 with a pulse rate of 97 beats per minute and height of 173 cm. Her chest was clear to auscultation. Her abdomen was soft, with no palpable

organomegaly or localised swelling. She had a 5/5 power throughout, normal sensations globally. Right pupil size was 5 mm and left pupil was 4 mm in diameter. There was normal pupillary reaction to light bilaterally. Cranial nerves examination, including visual field assessment, were normal bilaterally. She had no cerebrospinal fluid leak through the nose. She had no hearing loss or facial weakness. She had no evidence of abnormal fine limb movements. She had no evidence of abnormal gait. No evidence of base skull fracture or dysphasia was noted. She had no evidence of injury to the neck, no inappropriate or abnormal behaviour and no loss of vision.

INVESTIGATIONS

She was reviewed at an ear, nose and throat clinic a year prior for vertigo and otalgia. MRI head done on recommendation by the ears, nose and throat team showed possible trigeminal nerve irritation and an incidental finding of a RCC. A pituitary and an internal acoustic meatus MRI scan with contrast done 3 months afterward showed a 6.5 × 9 mm non-enhancing cyst in the pituitary sella (see [figure 1](#)), which appeared to be displacing the normal pituitary tissue superiorly and slightly posteriorly. There was no visible pituitary adenoma on the MRI sections. There was no supra or parasellar extension. The optic chiasm was preserved. The pituitary stalk was not deviated and showed normal enhancement post-contrast. No space-occupying lesion, infarction, mass effect, midline shift or hydrocephalous was seen. The cisternal spaces were clear and the grey-white matter interface preserved. No abnormal enhancement following intravenous contrast. Scattered high signal white matter foci were seen and were thought to be most attributable to a low burden of ischaemic small vessel disease. The seventh and eighth cranial nerves had a normal appearance bilaterally with no evidence of an internal acoustic meatus or cerebellopontine angle mass lesion. The internal ear structures appeared intact.

Pituitary hormones profile study done 8 months to this case submission showed only elevated insulin-like growth factor at 43.3 nmol/L (reference range 6.2–24 nmol/L) and a repeated check 2 months afterward at 51.3 nmol/L. Serum prolactin level check alongside was 213 mIU/l (ref: <700 mIU/L), 10:00 hours cortisol—222 nmol/L (ref: 140–690 nmol/L), thyroid-stimulating hormone (TSH) level - 1.3 mU/l (ref: 0.27–4.2 mU/l) and T4 level—12 pmol/L (ref: 12–22 pmol/L). An oral glucose tolerance test was done afterward and revealed a failure to suppress



© BMJ Publishing Group Limited 2022. Re-use permitted under CC BY-NC. No commercial re-use. See rights and permissions. Published by BMJ.

To cite: Alkundi A, Momoh R, Nash M. *BMJ Case Rep* 2022;**15**:e250332. doi:10.1136/bcr-2022-250332

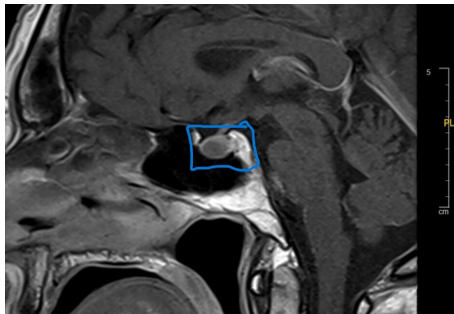


Figure 1 Showing a sagittal section of a contrast MRI pituitary scan in patient demonstrating the Rathke's cleft cyst and displaced pituitary tissue.

serum growth hormone (GH) to $<1\mu\text{g/L}$. Nadir GH level during the test was $2.3\mu\text{g/L}$.

TREATMENT

Her presenting symptoms improved initially with analgesics prescribed and was considered for further outpatient follow-up appointments after an uneventful period of in-hospital observation. Safe-netting instructions were given. She was referred for a formal visual field assessment. Her case was also reviewed at a tertiary centre's endocrinology multidisciplinary meeting. The outcome of the meeting recommended patient to have an octreotide test dose and for further follow-up reviews. Her case was also recommended for further pituitary tumour clinicopathologic deliberations as well as for discussion of feasibility for surgery. The octreotide challenge test showed good response (see table 1 below) but patient opted for surgical intervention due to the intolerable gastrointestinal side effects of octreotide she experienced.

She underwent a transsphenoidal surgery and excision of pituitary tumour was done. On macroscopy, biopsy specimen consists of multiple pieces of soft white tissue fragments measuring in aggregate $8\times 3\times 2\text{mm}$. On microscopy, sections showed multiple pieces of a pituitary neuroendocrine tumour/adenoma. The tumour is arranged in diffuse sheets of cells with oval shaped, mildly atypical nuclei and eccentric abundant eosinophilic cytoplasm. Only rare mitotic figures are identified (1 per 10HPF). There was no necrosis in the tumour. The reticulum pattern was disrupted. Immunohistochemistry showed strong diffuse positivity with GH and pan- α -subunit. Very rare TSH positive cells were also noted. Adrenocorticotrophic hormone (ACTH) was positive on the edge of the biopsy, probably representing infiltrated non-neoplastic cells. Follicle-stimulating hormone (FSH), Leuteinizing hormone (LH), prolactin were negative. Transcription markers Pit-1 and SF1 were positive, while T-pit was positive only in very occasional infiltrated non-neoplastic cells at the edge of the sample. MNF116 reveals only very rare fibrous bodies, in addition to weak cytoplasmic positivity in most tumour cells. Proliferation index was 2% by Ki67.

Table 1 Octreotide challenge test

Interval	Growth hormone level ($\mu\text{g/L}$)
0 min	6.02
120 min	0.23
240 min	0.16
360 min	0.21

ACTH, Adrenocorticotrophic hormone.

Table 2 Hormone profile check 1-week postsurgery

Test	Result	Reference range
TSH	2.61 mU/l	0.27–4.2 mU/l
Free T4	20.4 pmol/L	12–22 pmol/L
Prolactin	209 mIU/l	$<700\text{ mIU/l}$
Growth hormone	0.5 $\mu\text{g/L}$	1–14 $\mu\text{g/L}$
Early morning cortisol	231 nmol/L	140–690 nmol/L

TSH, Thyroid-stimulating hormone.

Histopathology report in summary revealed a strongly GH-positive adenoma, PRL staining negative, PIT1 positive, SF1 positive (and positive on repeat), but FSH and LH negative, Ki67 1–2.

OUTCOME AND FOLLOW-UP

The patient required one dose of DDAVP (1-deamino-8-D-arginine vasopressin) for a transient diabetes insipidus prior to discharge from the tertiary neurosurgical centre following her pituitary surgery. The patient had an admission at her district general hospital (DGH) 1-week postsurgery to assess her recurrent polyuria. Her hormone profile checked at that time is presented in table 2.

She was assessed jointly with her tertiary hospital's endocrine and neurosurgery unit, and she was recommended to be started on oral hydrocortisone 20 mg two times per day, based on her laboratory finding of serum sodium 125 mmol/L, plasma osmolality of 261 mmol/kg (ref: 275 to 295 mmol/kg), random urine osmolality 541 mOsm/kg (ref: 500–850 mOsm/kg), and random urinary sodium of 179 mEq/l (ref: around 20 mEq/l). Her polyuria did improve afterwards but she had required one DDAVP dosage after the above test result samples had been collected. She was discharged home after 1 week of representation to her DGH on oral hydrocortisone replacement and was recommended for periodic follow-ups in clinics at her DGH and tertiary centre. Multidisciplinary discussion about patient at the tertiary centre shortly before her discharge recommended patient for a post-operative IST and GH day curve tests, and to have an interval MRI head study after 3 months.

DISCUSSION

This case report further sheds lights on the increasing association being accorded to the concurrent finding of RCC(s) and pituitary adenoma in recent literatures. In this index case, a diagnosis of a GH-producing pituitary adenoma was diagnosed in a middle-aged patient with a radiologic finding of RCC displacing the pituitary tissue.

The anterior pituitary (a derivative of the embryologic oral ectoderm) contains about 50% growth-hormone producing cells and about 10%–25% of its cells secreting prolactin. The posterior pituitary gland has its origin as a down-growth extension of the diencephalon and secretes oxytocin and anti-diuretic hormone.³ The Rathke's cleft in most growing individuals is an obliterated space between the anterior and posterior pituitary gland. In a few individuals, this obliterated space could remain as a cyst or cysts which largely remain asymptomatic, but in some other situations produce symptoms such as headaches or visual disturbance by compression on the optic chiasma.⁴

There is yet no direct explanation for the cause of concurrent findings of RCC and pituitary adenoma beyond case reports and case series descriptions in the literature. However, the concept of collision tumours (tumours or lesions occurring together but with distinct borders and with different cell populations) has

been described in medical literature and these two entities could fit this description.⁵

Within the literature, there are reported to be up to 14 cases of both RCCs and associated acromegaly.⁶ Some of the earliest research regarding these entities dates to 1978 when a transitional cell tumour located within a RCC wall was first described.⁷ Light and electron microscopy done in their case identified the tumour cells to be like that of the early developmental stage of the anterior pituitary gland. This led to the commonly reported theory that functioning pituitary adenomas (FPAs) and RCCs shared a common embryological origin. However, a case report by Ikeda *et al*, describing acromegaly in a patient whose pituitary adenoma was found located within a RCC negated the afore. They demonstrated via immunohistochemical findings that the cells within the cyst did not resemble those of an early embryological developmental stage.⁸

In 2014, an entirely different causal mechanism of acromegaly was associated with a case of RCC, demonstrating granulomatous anterior hypophysitis. It was suspected that the cyst caused hypophysitis which clinically presented with acromegaly. This case was surgically managed but the authors were suspicious that the case could have been managed without surgical intervention.⁹ A similar causal mechanism was demonstrated in another study of a suspected pituitary adenoma and RCC case. During the surgery, no adenomatous tissue was discovered and it was theorised that the Rathke's cyst caused inflammation that generated hormone release, mimicking a plurihormonal pituitary adenoma.¹⁰

A wider issue of pituitary adenomas and RCC was also explored in a 2018 study that audited 284 cases of known pituitary adenomas. Four were demonstrated to be associated with an RCC, three were hormone-producing, and one of those caused acromegaly. The authors took a slightly different stance from the previous literature and highlighted the importance of suspecting a RCC in all cases of pituitary adenoma, particularly when cysts are non-enhancing on MRI.¹¹

Sumita *et al* in their 2001 publication of a retrospective review of 374 patients with sellar or juxtassellar tumours who had undergone a contrast 1.5 Tesla MRI scan study revealed a 2.1% frequency of finding concurrent RCC and pituitary adenoma. They also revealed that the RCC was adjacent to the pituitary adenoma in seven out of eight of the patients in whom this concurrent association was found and in one of the patients, the cyst enclosed the adenoma.¹² Pojskić *et al* in their 2017 publication claimed to have described the first case of two ectopic pituitary lesions: a RCC and a silent adrenocorticotropic hormone adenoma, found in the sphenoidal sinus.¹³

Azarpira *et al* reported a concurrent finding of RCC and a combined pituitary adenoma with gangliocytoma in a 50-year-old woman in their 2013 publication.¹⁴ Tamura *et al* in their publication in 2014 described a concurrent suprasellar RCC and a GH-producing pituitary adenoma in a 53-year-old man who was earlier assessed on his hospital visit with a lacunar infarction in the left basal ganglia.¹⁵ Bader *et al* in their publication in the year 2004 described the successful role of a modified transsphenoidal skull-based approach towards performing a selective transsphenoidal adenomectomy and decompression of the suprasellar cyst in a patient with concurrent symptomatic RCC (with visual disturbance) and a GH-secreting pituitary adenoma.¹⁶

Surgical consideration (transsphenoidal pituitary adenomectomy) is considered the first-line therapy for the management of most FPAs except prolactinomas (which show a good response to treatment with dopamine agonists (eg, cabergoline). Treatment of FPA is aimed to achieve remission as well as to shrink the size

of the adenoma. Medical treatment and/or radiation therapy can be deployed as an adjuvant treatment following transsphenoidal surgeries for these FPAs. For patients with growth-hormone producing pituitary adenomas with ensuing acromegaly, somatostatin analogues, dopamine agonists, and GH receptor antagonist have been used as a single therapy or in combination, and the high remission rate can be achieved. In patients with acromegaly, preceding treatment with somatostatin analogue helps to improve the rate of success with transsphenoidal surgery.¹⁷ Consideration can be given to the transsphenoidal resection of a symptomatic RCC and a symptomatic pituitary adenoma at the same surgery where they occur together.

Patient's perspective

My diagnosis of acromegaly was both daunting and a venture into the unknown. I had been feeling 'not quite right' for many years, and despite far too many visits to general practice, there was no real conclusion to my symptoms, of which there were many. As time wore on, I began to despair of the constant fatigue that took me to bed every afternoon. I had earache and a twitching eye that was put down to stress, as was the blurred vision that accompanied it. Three years prior to this publication, I began sweating profusely, spent a lot of time urinating without warning, along with swollen feet and fingers. My heart rate was often high. It was the earache that brought me to the door of endocrinology due to a finding of a Rathke's Cleft Cyst during an MRI examination. After some queries regarding this and the importance of it in terms of my symptoms, I was referred to Dr AA at the William Harvey Hospital who diagnosed acromegaly. Since then, I have also been diagnosed with short-lasting unilateral neuralgiform headache with autonomic symptoms (SUNA) syndrome – which explained a lot of the headaches, eye and ear symptoms.

I had transphenoidal surgery to remove this neuroendocrine tumour in June 2022 via the specialist unit at Kings College Hospital as this is not available in my local NHS Trust. Since then, some of the symptoms have subsided. I no longer have feet that resemble 'pigs trotters'. The headaches, unfortunately, remain for now, but that will require further investigation. My hands remain swollen at the present time, and whilst the fatigue is less, it is still there, and I have to identify when I should pace myself. I imagine that, due to the longevity of the condition before diagnosis, this will be a 'work in progress', so I remain patient. I am prescribed 20mg of Hydrocortisone for the time being, and wait for further input regarding the future dose, if any. I am told that my facial features are not as coarse, but I am equally learning to cope with the changes that would not revert.

Learning points

- ▶ Clinicians and surgeons are reminded about increasing literature evidence of the concurrent occurrence of symptomatic Rathke's cleft cyst(s) and pituitary adenoma(ta).
- ▶ Patient education can be further facilitated, and expectations managed in the setting of one or both entities occurring.
- ▶ More explanations beyond case reports or case series evidence will be required to explain the concurrent association between these two clinical entities.

Acknowledgements The authors wish to thank the patient for giving consent to this case report submission.

Contributors AA was involved in the conception, planning, acquisition of data, interpretation of data, analysis and general supervision of this case report submission. RM was involved in the planning, acquisition of data, interpretation of data, reporting, analysis, manuscript development and editing for this case report. He is the submitting author. MN was involved in the planning, obtaining consent, acquisition of data, interpretation of data, reporting, analysis and was involved with manuscript development of this case report.

Funding The authors have not declared a specific grant for this research from any funding agency in the public, commercial or not-for-profit sectors.

Competing interests None declared.

Patient consent for publication Consent obtained directly from patient(s)

Provenance and peer review Not commissioned; externally peer reviewed.

Open access This is an open access article distributed in accordance with the Creative Commons Attribution Non Commercial (CC BY-NC 4.0) license, which permits others to distribute, remix, adapt, build upon this work non-commercially, and license their derivative works on different terms, provided the original work is properly cited and the use is non-commercial. See: <http://creativecommons.org/licenses/by-nc/4.0/>.

Case reports provide a valuable learning resource for the scientific community and can indicate areas of interest for future research. They should not be used in isolation to guide treatment choices or public health policy.

ORCID iDs

Alamin Alkundi <http://orcid.org/0000-0003-0488-220X>

Rabiu Momoh <http://orcid.org/0000-0001-8412-0912>

REFERENCES

- 1 Hashim AJ, Rezapour S, Cyst RC. Available: <https://www.sciencedirect.com/sdfe/pdf/download/eid/3-s2.0-B9780323445498000201/first-page-pdf>
- 2 Babu R, Back AG, Komisarow JM. Symptomatic Rathke's cleft cyst with a co-existing pituitary tumor. *Brief review of the literature*.
- 3 Nussey S, Whitehead S. Endocrinology: an integrated approach
- 4 Isono M, Kamida T, Kobayashi H, et al. Clinical features of symptomatic Rathke's cleft cyst. *Clin Neurol Neurosurg* 2001;103:96–100.
- 5 Koutourousiou M, Kontogeorgos G, Wesseling P, et al. Collision sellar lesions: experience with eight cases and review of the literature. *Pituitary* 2010;13:8–17.
- 6 Tang C, Qiao L, Zhong C, et al. The coexistence of growth hormone-producing pituitary adenoma and Rathke cleft cyst: how can we diagnosis Preoperation?. *J Craniofac Surg* 2018;29:1887–9.
- 7 Kepes JJ. Transitional cell tumor of the pituitary gland developing from a Rathke's cleft cyst. *Cancer* 1978;41:337–43.
- 8 Ikeda H, Yoshimoto T, Katakura R. A case of Rathke's cleft cyst within a pituitary adenoma presenting with acromegaly--do "transitional cell tumors of the pituitary gland" really exist? *Acta Neuropathol* 1992;83:211–5.
- 9 Hojo M, Ishibashi R, Arai H, et al. Granulomatous hypophysitis caused by Rathke's cleft cyst mimicking a growth hormone-secreting pituitary adenoma. *Asian J Neurosurg* 2017;12:283–6.
- 10 Morinaga Y, Nii K, Sakamoto K, et al. Case of acromegaly caused by Rathke cleft cyst mimicking Plurihormonal pituitary adenoma. *World Neurosurg* 2019;126:570–5.
- 11 Jagtap VS, Lila AR, Sarathi V. Coexistent pituitary adenoma with Rathke's cleft cyst: A Case Series. *J Assoc Physicians India* 2018;66:42–6.
- 12 Sumida M, Migita K, Tominaga A, et al. Concomitant pituitary adenoma and Rathke's cleft cyst. *Neuroradiology* 2001;43:755–9.
- 13 Pojskić M, Zbytek B, Beckford NS, et al. First report of coexistence of two ectopic pituitary tumors: Rathke cleft cyst and silent adrenocorticotrophic hormone adenoma. *World Neurosurg* 2017;104:1048.e1–1048.e7.
- 14 Azarpira N, Pakbaz S, Torabineghad S, et al. Acromegaly associated with mixed pituitary adenoma-gangliocytoma and Rathke's cleft cyst. *Turk Neurosurg* 2013;23:527–30.
- 15 Tamura R, Takahashi S, Emoto K, et al. GH-producing pituitary adenoma and concomitant Rathke's cleft cyst: a case report and short review. *Case Rep Neurol Med* 2015;2015:948025.
- 16 Bader LJ, Carter KD, Latchaw RE, et al. Simultaneous symptomatic Rathke's cleft cyst and GH secreting pituitary adenoma: a case report. *Pituitary* 2004;7:39–44.
- 17 Oki Y. Medical management of functioning pituitary adenoma: an update. *Neurol Med Chir* 2014;54:958–65.

Copyright 2022 BMJ Publishing Group. All rights reserved. For permission to reuse any of this content visit <https://www.bmj.com/company/products-services/rights-and-licensing/permissions/>
BMJ Case Report Fellows may re-use this article for personal use and teaching without any further permission.

Become a Fellow of BMJ Case Reports today and you can:

- ▶ Submit as many cases as you like
- ▶ Enjoy fast sympathetic peer review and rapid publication of accepted articles
- ▶ Access all the published articles
- ▶ Re-use any of the published material for personal use and teaching without further permission

Customer Service

If you have any further queries about your subscription, please contact our customer services team on +44 (0) 207111 1105 or via email at support@bmj.com.

Visit casereports.bmj.com for more articles like this and to become a Fellow