

## Case Report

## Recruitment of the left precentral gyrus in reading epilepsy: A multimodal neuroimaging study



Dima Safi <sup>a,b,\*</sup>, Renée Béland <sup>c</sup>, Dang Khoa Nguyen <sup>d</sup>, Philippe Pouliot <sup>e</sup>, Ismail S. Mohamed <sup>f</sup>,  
Phetsamone Vannasing <sup>a</sup>, Julie Tremblay <sup>a</sup>, Maryse Lassonde <sup>a</sup>, Anne Gallagher <sup>a,g</sup>

<sup>a</sup> Centre de Recherche du CHU Sainte-Justine, Montréal, Canada

<sup>b</sup> Département d'orthophonie, Université du Québec A Trois-Rivières, Trois-Rivières, Canada

<sup>c</sup> Ecole d'orthophonie et d'audiologie, Université de Montréal, Montréal, Canada

<sup>d</sup> Service de Neurologie, CHUM Notre-Dame, Montréal, Canada

<sup>e</sup> École Polytechnique, Université de Montréal, Montréal, Canada

<sup>f</sup> JWK Health Center, Dalhousie University, Halifax, Canada

<sup>g</sup> Département de Psychologie, Université de Montréal, Montréal, Canada

## ARTICLE INFO

## Article history:

Received 1 December 2015

Received in revised form 18 December 2015

Accepted 9 January 2016

Available online 21 January 2016

## Keywords:

Reading epilepsy

Multimodal neuroimaging

Ictogenesis

Left precentral gyrus

Phonological reading

Lexical reading

## ABSTRACT

**Purpose:** In a previous study, we investigated a 42-year-old male patient with primary reading epilepsy using continuous video-electroencephalography (EEG). Reading tasks induced left parasagittal spikes with a higher spike frequency when the phonological reading pathway was recruited compared to the lexical one. Here, we seek to localize the epileptogenic focus in the same patient as a function of reading pathway using multimodal neuroimaging.

**Methods and results:** The participant read irregular words and nonwords presented in a block-design paradigm during magnetoencephalography (MEG), functional near-infrared spectroscopy (fNIRS), and functional magnetic resonance imaging (fMRI) recordings, all combined with EEG. Spike analyses from MEG, fNIRS, and fMRI-EEGs data revealed an epileptic focus in the left precentral gyrus, and spike localization did not differ in lexical and phonological reading.

**Conclusion:** This study is the first to investigate ictogenesis in reading epilepsy during both lexical and phonological reading while using three different multimodal neuroimaging techniques. The somatosensory and motor control functions of the left precentral gyrus that are congruently involved in lexical as well as phonological reading can explain the identical spike localization in both reading pathways. The concurrence between our findings in this study and those from our previous one supports the role of the left precentral gyrus in phonological output computation as well as seizure activity in a case of reading epilepsy.

© 2016 The Authors. Published by Elsevier Inc. This is an open access article under the CC BY-NC-ND license (<http://creativecommons.org/licenses/by-nc-nd/4.0/>).

## 1. Introduction

According to the *International League Against Epilepsy* (ILAE), epilepsy is considered as a disease of the brain defined by any of the following conditions: (a) at least two unprovoked (or reflex) seizures occurring >24 h apart; (b) one unprovoked (or reflex) seizure and a probability of further seizures similar to the general recurrence risk (at least 60%) after two unprovoked seizures, occurring over the next 10 years; or (c) diagnosis of an epilepsy syndrome [1]. When seizures are triggered by specific sensory or cognitive stimuli, researchers speak of “reflex” epilepsy. Reflex reading epilepsy is a rare epileptic syndrome in which

silent and/or aloud reading is the main triggering factor. Previous case studies attempted to shed light on the factors responsible for seizure onset in reading epilepsy and several hypotheses have been proposed [2–4]. Epileptic discharges seen on electroencephalography (EEG) recordings have been associated with different localizations [2,3]. In the few recent neuroimaging studies investigating the neural circuits implicated in reading epilepsy, authors postulated that the epileptic activity occurs when a mass of neurons is activated after a triggering stimulus (in this case, reading) within the cortico-subcortical reading network [5–8]. Several cortical and subcortical regions, including the bilateral frontal and temporal lobes, the left premotor and motor cortex, and the left striatum as well as the thalamus, have been reported to be involved in reading epilepsy with variations across participants. Pegna et al. [4] proposed that spike localization in these patients would depend on the reading pathway involved (lexical and phonological reading pathways). However, to our knowledge, no study has yet clearly

\* Corresponding author at: Département d'orthophonie, Local 3836 Pavillon de la Santé, Université du Québec A Trois-Rivières, 3351 Boulevard des Forges, Trois-Rivières, Québec, G9A5H7, Canada. Tel.: +1 819 376 5011x3259.

E-mail address: [dima.safi@uqtr.ca](mailto:dima.safi@uqtr.ca) (D. Safi).

identified the epileptic cerebral regions specific to these pathways as proposed in the cognitive models of reading [9]. Moreover, most of the previous imaging studies used silent reading, which does not allow researchers to assess the patient's reading performance or to adapt the stimuli presentation's rate to the patient's reading speed.

In a previous study aiming to better understand the pathophysiology of reading epilepsy, we investigated a 42-year-old right-handed French-speaking man with primary reading epilepsy, using clinical assessments and continuous video-EEG [10]. Results revealed a significantly higher epileptic activity during reading than during other verbal and nonverbal tasks. The linguistic characteristics significantly affected spike frequency, with a higher frequency in the phonological than in the lexical reading pathway. Scalp-EEG recordings suggested a left fronto-central spike localization. In the present study, we report results from three functional neuroimaging techniques: magnetoencephalography (MEG), functional near-infrared spectroscopy (fNIRS), and functional magnetic resonance imaging (fMRI) – all combined with simultaneous EEG – acquired in the same patient, in order to better delineate the spatial characteristics of the reading-induced epileptic discharges as a function of reading pathway.

## 2. Material and methods

### 2.1. Reading tasks and procedure

The patient gave his written informed consent, and the research was approved by the local institutional ethics committees. The patient read French irregular words (e.g., coefficient) (lexical reading pathway) and nonwords (e.g., nomus) (phonological reading pathway) presented on a computer screen in a block-design paradigm during MEG, fNIRS, and fMRI-EEG recordings. Nonwords were matched to irregular words for length (number of letters) and phonological complexity (syllabic structure, number of phonemes and syllables) (see [11] for details on stimuli's characteristics). Reading blocks (20 s) were separated by a baseline condition (between 5 and 35 s.) during which the patient had to fix a cross presented in the center of the screen. Reading was aloud during fNIRS and silent during fMRI and MEG recordings. The patient underwent fNIRS recordings first in order to determine the patient's reading speed and control his performance. The stimuli's presentation rate was then adjusted to the patient's reading speed for the fMRI and MEG sessions. To prevent a familiarity effect with the stimuli on cerebral activation, the order of the blocks as well as that of the stimuli within a block was counterbalanced across the three techniques.

### 2.2. Data acquisitions and analyses

The EEG data were collected using 19 scalp electrodes placed according to the 10–20 international system for MEG and fNIRS and a 64-channel head cap for fMRI. The EEG epileptic events were marked by an epileptologist, and spike/sharp wave discharges were used as predictors of fNIRS and fMRI responses.

The MEG recordings were acquired using a whole-head Omega 275-channel gradiometer system (VSM MedTech, Canada). A band-pass filter of 5–70 Hz was applied to the raw MEG data. Epileptic events were visually identified by examining MEG recordings and cross-referencing them with simultaneous EEG recordings. Interictal spikes were analyzed by applying a single moving dipole model to the earliest peak of the interictal spike on MEG recordings.

The fNIRS data were obtained using 16 NIRS detectors and 55 sources of 690 nm and 830 nm (Imagent, USA) with nearly full bilateral coverage. Oxyhemoglobin (HbO) and deoxyhemoglobin (HbR) concentration changes were calculated using the Modified Beer Lambert Law. A standard general linear model (GLM) analysis was performed using nirs10 [12].

The fMRI acquisitions were performed with a 3T MRI system (Philips Achieva) using a standard head coil. A second fMRI scan was acquired during the same reading task while the patient was under medication, thus controlling the epileptic activity. In both fMRI sessions, data were processed using SPM8 following standard GLM analysis, estimating the effects of the hemodynamic response function (HRF) for focal spikes as well as for reading irregular words and nonwords.

All data were coregistered with the patient's structural MRI for visualization.

## 3. Results

Reading of irregular words and nonwords evoked many spike/sharp wave discharges localized in the left precentral gyrus, as revealed by MEG, fNIRS, and fMRI results (Fig. 1). There was no difference in localization between reading-induced spikes in irregular words and nonwords.

The MEG equivalent current dipole (ECD) analyses on interictal spikes showed a tight dipole cluster over the left precentral gyrus mostly with a uniform horizontal orientation (Fig. 1A).

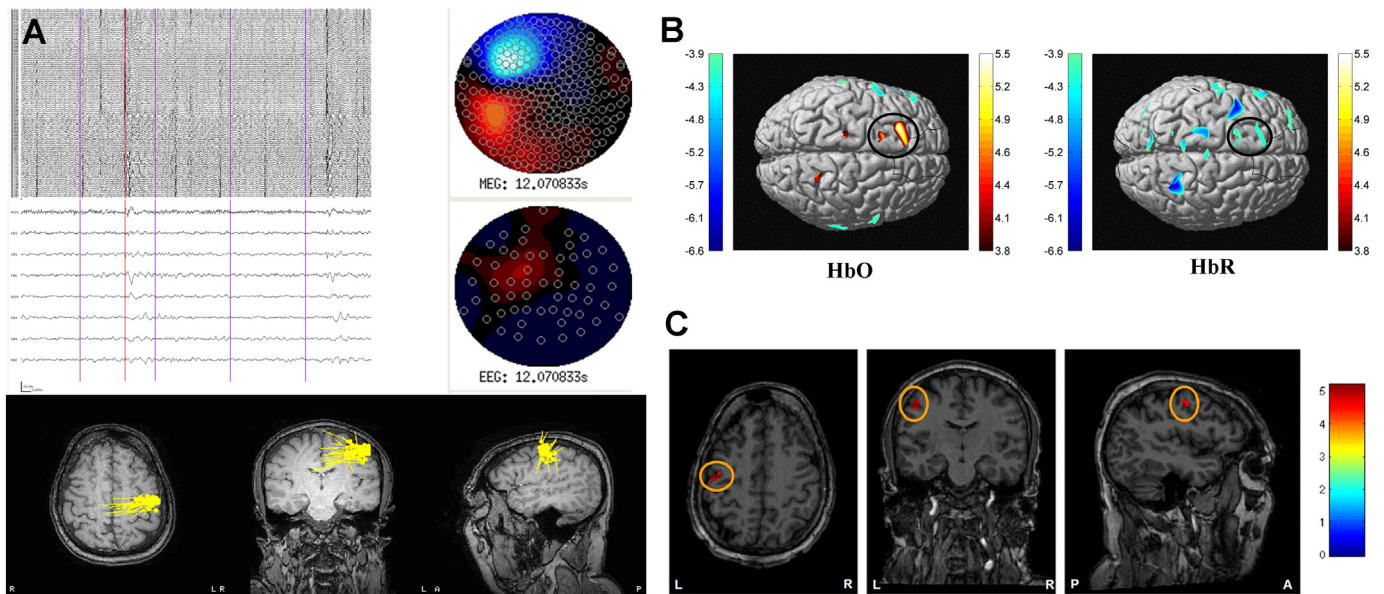
Statistical GLM maps of fNIRS data revealed significant HbO increase and concurrent HbR decrease during spikes compared to baseline over the left precentral gyrus ( $P_{\text{corr}} < 0.05$ ) (Fig. 1B).

In fMRI acquisitions, significant spike-triggered blood oxygen level dependent (BOLD) activation was observed in the left precentral gyrus ( $T = 4.6$ ;  $P_{\text{FWE}} < 0.05$ ) (Fig. 1C). In both irregular word and nonword reading, while the epileptic activity was controlled with medication, results showed significant activations bilaterally in the fronto-temporo-parieto-occipital regions as well as in the cerebellum (see Table 1 in the Supplementary data).

## 4. Discussion

We performed MEG, fNIRS, and fMRI recordings, simultaneously with EEG, in a 42-year-old right-handed French-speaking patient with primary reading epilepsy. To our knowledge, this study is the first to investigate ictogenesis in reading epilepsy during lexical and phonological reading and to use three different multimodal neuroimaging techniques. Furthermore, in conducting fNIRS recordings during an aloud reading task, we were able to control for the patient's reading performance and to measure his reading speed, which was not done in previous researches. The stimulus presentation rate was subsequently adjusted to the patient's reading speed for fMRI and MEG sessions, thus ensuring that the cerebral activations would not be influenced by an inadequate presentation rate.

Results showed that reading-induced epileptic activity was localized in the left precentral gyrus. Our findings confirmed those of previous studies identifying the left motor and premotor cortex as well as the supplementary motor area as the epileptogenic zones in reading epilepsy [5,6,8]. The fMRI acquisitions in our patient while he was under medication, thus in the absence of epileptic activity, showed that cerebral activations associated with reading were localized in several regions including the left precentral gyrus. The activation found in the left precentral gyrus when the patient read irregular words (lexical reading pathway) as well as nonwords (phonological reading pathway) is consistent with findings from studies investigating the neural networks of reading in normal readers [13,14]. According to some authors, the left precentral gyrus activation reflects the sensorimotor control of the mouth, tongue, and pharynx in expressive language activities [15]. As this component is implicated in both irregular word and nonword readings, this would account for the identical localization of spike/wave discharges in our patient with reading epilepsy during both lexical and phonological reading. This hypothesis is applicable not only for aloud but also silent reading, since studies showed that readers would subvocalize and mentally generate articulatory motor patterns even in silent reading [16].



**Fig. 1.** Localization of reading-induced discharges in the left precentral gyrus showed in MEG (Fig. 1A), fNIRS (Fig. 1B), and fMRI data (Fig. 1C). Fig. 1A (left side) represents simultaneous MEG (top) and EEG (bottom) recordings from selected channels over the left hemisphere (MEG, 5–70 Hz) and both central regions (EEG, 1–70 Hz) as well as the topography maps (right side) of one interictal spike indicated by the red vertical line on the MEG–EEG recordings. Purple vertical lines indicate the time of irregular word presentation. Lower row in Fig. 1A shows the dipole cluster in yellow over the left precentral gyrus. Fig. 1B represents the dorsal view of the brain with a significant HbO increase combined to a significant HbR decrease during spikes compared to baseline in the left precentral gyrus. Fig. 1C illustrates the significant BOLD response observed in the left precentral gyrus during spikes/sharp waves when compared to baseline. The colored scales in Fig. 1B and 1C represent the t-value.

A recent meta-analysis of cerebral activations during single word reading in fluent adult readers revealed that the left precentral gyrus was more activated when reading nonwords compared to words and the authors postulated that this region is implicated in phonological output computation [17]. The concurrence between our results in the current study and those from our previous one [10] confirms this hypothesis and sheds light on the ictogenesis of primary reading epilepsy. In our previous study, reading-induced spike frequency was significantly higher when the patient read stimuli involving the phonological reading pathway (which includes grapheme-to-phoneme conversion and phonological output computation) compared to the lexical reading pathway. Moreover, verbal tasks that involved phonological output computation (e.g., nonword repetition and oral spelling) also had a higher spike frequency than those that did not implicate any phonological output computation (e.g., writing-to-dictation), albeit to a lesser degree than the reading tasks.

To conclude, our findings confirm the role of the left precentral gyrus in grapheme-to-phoneme conversion and phonological output computation as well as the ictogenesis of reading epilepsy during both aloud and silent reading. In our patient, the left precentral gyrus hyperexcitability – a region that is a part of the regular neural network of reading and that is involved in phonological output computation through speech production code – accounts for the triggering of epileptic discharges during verbal tasks implicating a phonological output computation as well as during lexical and especially phonological reading.

Supplementary data to this article can be found online at <http://dx.doi.org/10.1016/j.ebcr.2016.01.003>.

### Conflict of interest

The authors declare that there is no conflict of interest.

### Acknowledgments

The authors are grateful to the patient for his unconditional participation. This project was supported by grants from the Canadian Institute of Health Research (CIHR) and the Fonds de la Recherche Québécois en Santé (FRQS) held by Anne Gallagher (FRQS: 26804,

CIHR: MSH-131472) and Dang Khoa Nguyen (FRQS: 31040, CIHR: MOP-133643), the Social Sciences and Humanities Research Council of Canada (SSHRC) held by Renée Béland (N/A), and the Canada Research Chair held by Maryse Lassonde (206863), as well as scholarships from the Fondation de l'Hôpital Ste-Justine et Fondation des Etoiles and the Fondation Desjardins awarded to Dima Safi.

### References

- [1] Fisher RS, Acevedo C, Arzimanoglou A, Bogacz A, Cross JH, Elger CE, et al. A practical clinical definition of epilepsy. *Epilepsia* 2014;55(4):475–82.
- [2] Koepp MJ, Hansen ML, Pressler RM, Brooks DJ, Brandt U, Guldin B, et al. Comparison of EEG, MRI and PET in reading epilepsy: a case report. *Epilepsy Res* 1998;29(3):251–7.
- [3] Koutoumanidis M, Koepp MJ, Richardson MP, Camfield C, Agathonikou A, Ried S, et al. The variants of reading epilepsy: a clinical and video-EEG study of 17 patients with reading-induced seizures. *Brain* 1998;121(8):1409–27.
- [4] Pegna AJ, Picard F, Mortory MD, Vuilleumier P, Seeck M, Jallon P, et al. Semantically-triggered reading epilepsy: an experimental case study. *Cortex* 1999;35(1):101–11.
- [5] Op de beek M, Legros B, Gaspard N, Bourguignon M, Jurysta F, Van Bogaert P, et al. Supplementary motor cortex involvement in reading epilepsy revealed by magnetic source imaging. *Epilepsia* 2011;52(5):31–4.
- [6] Salek-Haddadi A, Mayer T, Hamandi K, Symms M, Josephs O, Fluegel D, et al. Imaging seizure activity: a combined EEG/EMG-fMRI study in reading epilepsy. *Epilepsia* 2009;50(2):256–64.
- [7] Vaudano AE, Carmichael DW, Salek-Haddadi A, Rampp S, Stefan H, Lemieux L, et al. Networks involved in seizure initiation: a reading epilepsy case studied with EEG-fMRI and MEG. *Neurology* 2012;79:249–53.
- [8] Anzellotti F, Franciotti R, Onofri M. Temporal recruitment of cortical network involved in reading epilepsy with paroxysmal alexia: a combined EEG/MEG study. *Seizure* 2013;22:56–8.
- [9] Coltheart M, Rastle K, Perry C, Langdon R, Ziegler J. DRC: a dual route cascaded model of visual word recognition and reading aloud. *Psychol Rev* 2001;108(1):204–56.
- [10] Safi D, Lassonde M, Nguyen DK, Denault C, Macoir J, Rouleau I, et al. Reflex reading epilepsy: effect of linguistic characteristics on spike frequency. *Epilepsy Behav* 2011;20(4):659–67.
- [11] Safi D, Lassonde M, Nguyen DK, Vannasin P, Tremblay J, Florea O, et al. Functional near-infrared spectroscopy for the assessment of overt reading. *Brain Behav* 2012;2(6):825–37.
- [12] Pouliot P, Tremblay J, Robert M, Vannasing P, Lepore F, Lassonde M, et al. Nonlinear hemodynamic responses in human epilepsy: a multimodal analysis with fNIRS-EEG and fMRI-EEG. *J Neurosci Methods* 2012;204(2):326–40.
- [13] Heim S, Alter K, Ischebeck AK, Amunts K, Eickhoff SB, Mohlberg H, et al. The role of the left Brodmann's areas 44 and 45 in reading words and pseudowords. *Cogn Brain Res* 2005;25(3):982–93.

- [14] Joubert S, Beauregard M, Walter N, Bourgouin P, Beaudoin G, Leroux JM, et al. Neural correlates of lexical and sublexical processes in reading. *Brain Lang* 2004;89(1): 9–20.
- [15] Moriai-Izawa A, Dan H, Dan I, Sano T, Oguro K, Yokota H, et al. Multichannel fNIRS assessment of overt and covert confrontation naming. *Brain Lang* 2012;121(3): 185–93.
- [16] Dietz NAE, Jones KM, Gareau L, Zeffiro TA, Eden GF. Phonological decoding involves left posterior fusiform gyrus. *Hum Brain Mapp* 2005;26(2):81–93.
- [17] Taylor JSH, Rastle K, Davis MH. Can cognitive models explain brain activation during word and pseudoword reading? A meta-analysis of 36 neuroimaging studies. *Psychol Bull* 2013;139(4):766–91.