

Received: 2012.08.26
Accepted: 2012.10.23

Isolated septic facet joint arthritis as a rare cause of acute and chronic low back pain – a case report and literature review

Dominika Klekot¹, Anna Zimny², Bogdan Czapiga³, Marek Szaśiadek²

¹ HELIMED Silesian Diagnostic Imaging, Opole, Poland

² Department of General and Interventional Radiology and Neuroradiology, Wrocław Medical University, Wrocław, Poland

³ Department of Neurosurgery, Wrocław Medical University, Wrocław, Poland

Author's address: Dominika Klekot, HELIMED Diagnostic Imaging, Wodociągowa 4 St., 45-221 Opole, Poland,
e-mail: dominika.klekot@helimed.pl

Summary

Background:

The most common cause of low back pain is degenerative disease of the intervertebral disc and other structures of the lumbar spine. However, in some cases other less frequent causes of such pain can be seen, for example septic facet joint arthritis. Until now, only 40 cases of such inflammatory changes within the spine have been reported in the literature. The disease is probably underestimated due to improper diagnostic pathway.

Case Report:

The authors describe a case of a 53-year-old woman who was repeatedly hospitalized during a five-month period because of an acute, severe low back pain, with sphincter dysfunction, partially resembling sciatic symptoms. Physical examinations revealed also focal tenderness in the area of the lumbar spine. Inflammatory markers (ESR – erythrocyte sedimentation rate, CRP – C-reactive protein) were elevated. Conservative analgetic treatment brought only partial and temporary relief of the pain and symptoms. The final accurate diagnosis of isolated septic facet joint arthritis at the level of L5/S1 was established after several months from the onset of the first symptoms, after performing various imaging examinations, including bone scintigraphy as well as CT and MRI of the lumbosacral spine. The patient fully recovered after antibiotic therapy and surgery, which was proven in several follow-up examinations showing no relevant pathology of the lumbar spine. The authors broadly describe the etiology and clinical symptoms of the septic facet joint arthritis as well as the significant role of imaging methods, especially MRI, in diagnostic process. The authors also discuss currently available treatment options, both conservative and surgical.

Conclusions:

The diagnostic procedure of septic facet joint arthritis requires several steps to be taken. Establishing a correct diagnosis may be difficult, that is why it is important to remember about rare causes of low back pain and to perform detailed physical examination, laboratory tests and choose appropriate imaging techniques.

Key words:

low back pain • diagnostics • facet joint arthritis

PDF file:

<http://www.polradiol.com/fulltxt.php?ICID=883634>

Background

Epidemiological data indicate that approx. 70% of individuals older than 30 years of age experience spine pain at least once in a lifetime. In 65% of cases this pain is located in the lumbosacral spine, in 33% it involves the cervical spine, and in approx. 2% of cases the pain occurs in the thoracic spine [1,2]. The most common causes of low back pain are

pathological changes in the intervertebral disc (degenerative disease, hernia); however, other spine elements and paraspinal structures may also undergo pathological changes and cause pain. In patients suffering from pain other than typical radiculalgia, low back pain may be caused by pathological changes in facet joints (degenerative osteoarticular pathology, joint effusion, synovitis, synovial cyst), spondylolysis,

degenerative and inflammatory processes of the spinal ligaments and pathologies of the paraspinal muscles [3].

Magnetic resonance is a diagnostic imaging method enabling the most precise visualization of all spine elements and paraspinal soft tissues. As a rule, T1- and T2-weighted images are used for evaluation of the spine. In addition, images with fat suppression: T2-weighted and T1-weighted after contrast administration, are also very useful and considerably improve diagnostic sensitivity of MR imaging, especially with regard to degenerative-inflammatory changes in the posterior elements of the spine and lumbosacral paraspinal tissues [3-5].

We present a case of a female patient with chronic low back pain, who was repeatedly hospitalized and diagnosed; the correct diagnosis was established and appropriate treatment implemented after several months from the onset of the first clinical symptoms.

Case Report

A 53-year old female patient was admitted to the Department of Neurology on an emergency basis due to a very strong, right-sided low back pain. In anamnesis the patient reported chronic (lasting for several years) and slight low back pain with periodical exacerbations manifested as sciatica, partially resolving after pharmacotherapy and physiotherapy. Besides, no significant diseases were reported in the past medical history.

Physical examination revealed limitation of motion and increased tone of paraspinal muscles in the lumbosacral spine on the right side, positive Lasègue and Mackiewicz signs on the right side, weaker right-sided ankle jerk reflex and hypoesthesia of the right buttock. The patient reported difficulties in urination. The presumptive diagnosis was right-sided sciatica. MR imaging of the lumbosacral spine (low-field MR unit 0.23 T, standard T1- and T2-weighted images, without contrast administration) demonstrated the presence of a small, midline herniation of the intervertebral disc at L5/S1 level, multi-level bulging and vertebral degenerative-deforming changes in the L-S spine. Laboratory tests revealed increased ESR (58 mm/h) and elevated CRP protein levels (30.9 mg/l). In order to find inflammatory lesions, urine analysis, abdominal ultrasonography and chest x-ray were performed; results of these examinations were normal. After administration of analgesics, non-steroidal anti-inflammatory drugs, muscle relaxants and physiotherapy, considerable improvement and pain relief were achieved in the patient. Diagnosis of right-sided radicular pain syndrome due to intervertebral disc herniation at L5/S1 level was established. Further monitoring of laboratory inflammatory markers and well-balanced lifestyle were recommended.

One month later, after a transient improvement the patient was re-admitted to the Department of Neurology due to a very strong, acute pain in the right lumbar area, radiating to the right buttock. Physical examination revealed pain of the paraspinal soft tissues in the right L4-S2 area and along muscle attachments at the right wing of ilium during palpation, slightly positive right-sided Lasègue and Mackiewicz signs, impaired superficial sensibility within

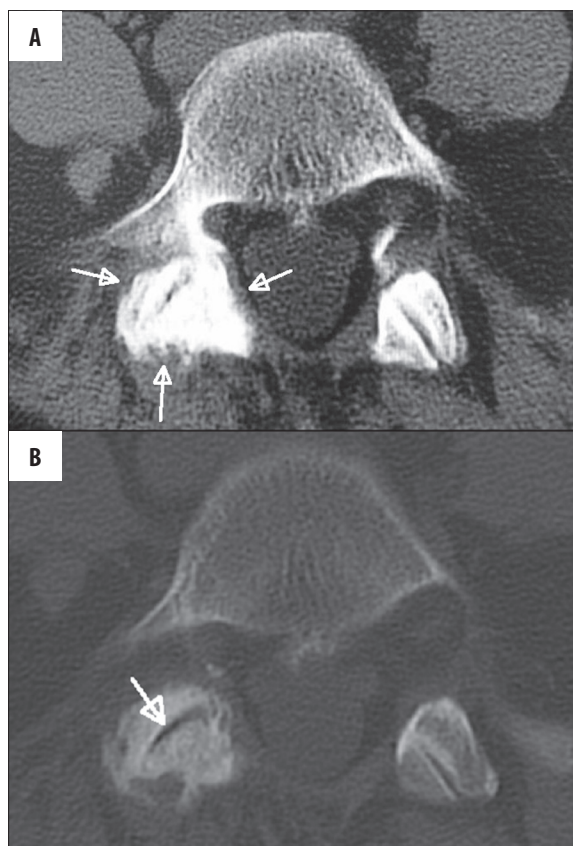


Figure 1. Computed tomography of the spine. (A) soft-tissue window, blurred outline and increased density of paraspinal soft tissues in the right L5/S1 facet joint area (arrows). (B) bone window, degenerative-productive changes of the both L5/S1 facet joints, more pronounced on the right side. Vacuum phenomenon in the right facet joint (arrow).

anterior surfaces of the proximal thighs, and weaker right-sided ankle jerk reflex. The patient complained of a severe pain during even the slightest attempt to change position that resolved only in a supine position and after intramuscular administration of narcotic analgesic drugs. Bone scintigraphy (Tc99m) revealed a single focus of increased bone metabolism at the level of L5/S1 vertebrae, to the right from the vertebral body. With regard to unclear etiology of this lesion, further diagnostics was recommended in order to exclude a possible neoplastic process or active inflammation. Next, CT imaging of L4-S2 spine was performed, which demonstrated increased degenerative-productive changes in both L5/S1 facet joints, vacuum phenomenon in the right facet joint at this level, without any features of osteolysis in the site of their increased marker uptake in scintigraphy. Additionally, a blurred outline of the soft tissue around the right L5/S1 facet joint was observed (Figure 1).

Then, high-field MR examination was performed using 1.5 T scanner. T1- and T2-weighted images, with and without fat saturation followed by intravenous contrast administration were obtained. The images revealed an area of heterogeneous contrast enhancement in the site of the right L5/S1 facet joint, involving: the facet joint, pedicle of vertebral arch and right L5 transverse process. The area of enhancement spread into the paraspinal soft tissues from L4/L5 level to S1/S2

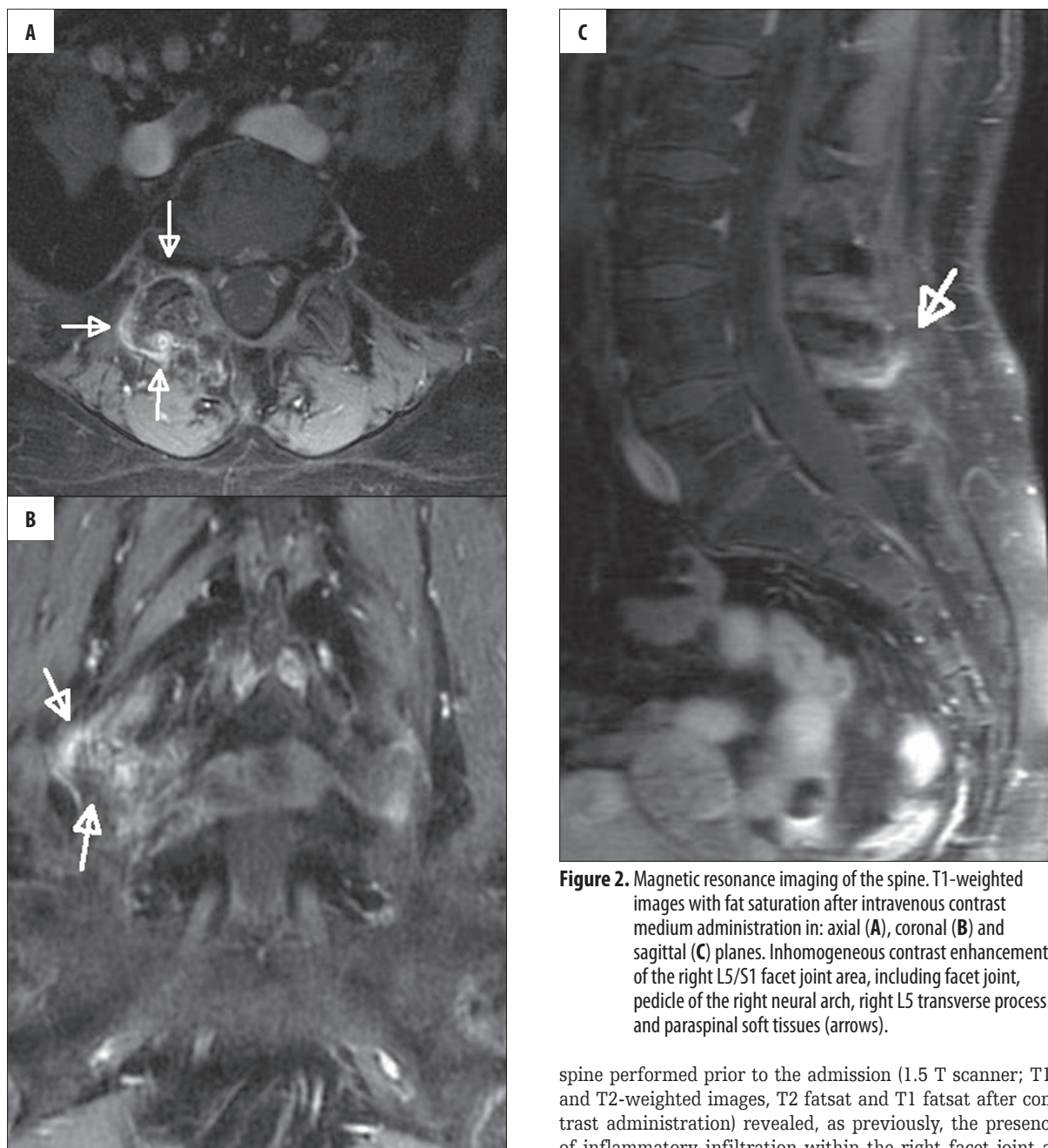


Figure 2. Magnetic resonance imaging of the spine. T1-weighted images with fat saturation after intravenous contrast medium administration in: axial (A), coronal (B) and sagittal (C) planes. Inhomogeneous contrast enhancement of the right L5/S1 facet joint area, including facet joint, pedicle of the right neural arch, right L5 transverse process and paraspinal soft tissues (arrows).

border level. The flaval ligaments at L5/S1 level were also enhanced (Figure 2). Rheumatological consultation excluded lesions associated with a systemic connected tissue disease. Finally, inflammatory infiltration surrounding the right facet joint at L5/S1 level was diagnosed. Analgesics, intravenous and oral antibiotics, as well as orthopaedic corset were used, which resulted in pain relief, disappearance of the radicular symptoms and normalisation of inflammatory markers in laboratory tests. A follow-up MR examination imaging of the lumbosacral spine were recommended in six weeks.

Two months later the patient was admitted to the Department of Neurology due to another pain exacerbation, without accompanying radicular pain or neurological deficits. A high field MR examination of the lumbosacral

spine performed prior to the admission (1.5 T scanner; T1- and T2-weighted images, T2 fatsat and T1 fatsat after contrast administration) revealed, as previously, the presence of inflammatory infiltration within the right facet joint at L5/S1 level, with a possible evolution towards phlegmonous tissue lesions in the right sacral region. After consultation by a neurosurgeon the patient was decided to be operated on. Revision of the right facet joint at L5/S1 level was performed; articular capsule and articular surfaces destroyed by inflammatory process were removed. A garamycin sponge was used locally. In addition, material for microbiological and histopathological examination was obtained. Postoperative period was uncomplicated. Microbiological culture did not produce any microorganisms. Histopathological examination revealed features of chronic, unspecific inflammatory process.

After the surgery a relief of the pain was achieved. The patient was discharged from the hospital in a good general condition, without any neurological deficits.

According to the previous recommendations, a follow-up bone scan (Tc99) was performed after six months from the previous examination, which revealed a total regression of the previously described, pathological focus at the level of L5/S1 on the right side.

A follow-up MR examination of the lumbosacral spine, performed after a year from the operation, did not demonstrate any significant pathologies.

At present, after a few years of follow-up, the patient stay in a good condition and does not show any symptoms of a low back pain.

Discussion

In 1911, for the first time facet joint arthritis was suggested as a cause of low back pain in the world medical literature [6]. Since then, only 40 documented cases of facet joint arthritis have been described worldwide (pyogenic/septic facet joint arthritis) [7]. The disease usually occurs on one side and at a single level [8]. Most of the cases are associated with previous injections of steroids in the perispinal area; the disease may also develop secondary to purulent infections within a vertebral body [7,8]. Recently, it has been noticed that over half of the cases of facet joint arthritis are related to a hematogenous spread [9], which probably occurred in the case of our patient, who had not undergone any previous intraarticular injections or inflammatory processes of other spinal structures that could be a source of the infection. Muffoletto et al. demonstrated that in 6 out of 140 patients (4%) with a spinal infection of the hematogenous origin the facet joints were also involved, and in 83% of cases the primary source of infection was found within the abdominal cavity and pelvis [9]. The main etiological factors were Gram-positive bacteria: *Staphylococcus aureus* and *S. epidermidis*. Factors predisposing to hematogenous facet joint arthritis also include: immunosuppression, intravenous administration of intoxicants, diabetes, liver cirrhosis, renal failure, neoplastic disease and other chronic diseases [8].

In all described cases of facet joint arthritis, like in our patient, elevated ESR and CRP were observed, whereas periodical leukocytosis occurred in approx. 47%, and fever in 50–70% of patients [7–9]. Our patient presented all typical symptoms of the disease: sudden and acute pain in the lumbar spine, passing into chronic, which was not relieved or even increased after resting. It is estimated that pain located at the level involved in the pathological process is experienced by approx. 90–97% of patients with facet joint arthritis [7–9]. Our patient also suffered from a local pain on the right side, exacerbating while bending the body sideways and backwards, which is also a characteristic manifestation of a one-sided facet joint arthritis. A patient can also experience pain located centrally and radiating to the buttocks or thighs, rarely to the knees or lower. Numbness and tingling, and other symptoms resulting from compression of nerve roots are usually absent due to the fact that facet joint arthritis causes only mechanical pain that results from incorrect motion of pathologically changed segment of the spine and inflammatory infiltration, but not from compressed nerve roots. However, in the case of coexisting radiculopathy,

radiculargia may occur concurrently with the pain typical for facet joint arthritis, which happens in up to 44% of cases, masking the disease manifestation and hindering establishing the right diagnosis [9,10], as it was in our patient.

The average period from the onset of symptoms to the moment of establishing the diagnosis is about 4 weeks (from 2 days to 5 months) [9]. In our patient the presumptive diagnosis was established after about 8 weeks, whereas surgical procedure that finally confirmed this diagnosis was performed after approx. 5 months.

A thorough physical examination and detailed anamnesis are extremely important at the early stage of diagnostics process of lower back pain. Such a procedure enables to refer the patient to adequately chosen diagnostic imaging technique which directly determines establishing the diagnosis [6]. Facet joint arthritis does not produce characteristic changes on x-ray images of the spine; only unspecific bone changes are observed, e.g. widening of a joint space, osteolytic and osteosclerotic changes in the facet joint [8,10]. Oblique projection may be useful for imaging of bone erosion within these joints, however, only after approx. 6–12 weeks from the onset of the inflammatory process [6]. In comparison with standard radiograms, transverse images and multiplanar reconstructions obtained during CT examination of the spine enable more accurate evaluation of facet joints and bone structures [6]. Magnetic resonance imaging shows the highest sensitivity and specificity in diagnosing facet joint infections. After 2 days from the onset of symptoms it enables to visualize early pathologies, such as joint effusion or paraspinal muscles oedema. Images obtained after administration of the gadolinium contrasts confirm the presence of inflammatory infiltrations, epidural granulation tissue or an abscess within the surrounding muscles [8]. It is important that when inflammatory process is suspected in a facet joint, the protocol of MR imaging should include T2-weighted images with fat saturation and T1-weighted fat saturation images after gadolinium contrast administration, and the whole examination should be performed by means of a high-field apparatus (at least 1.5 T). In most of cases, standard MR imaging of the lumbar spine without the above-mentioned sequences produces incorrect diagnosis [3]. In our patient, the first MR examination was performed using a low-field MR unit without fat saturation sequences and without contrast administration, therefore it did not reveal any pathologies in the facet joints. During the second MR examination performed with a high-field scanner, only STIR sequence was used for fat saturation and it did demonstrate only subtle changes. In our patient, only T1-weighted images after contrast administration revealed the whole pathology; according to literature, they are regarded as the most sensitive in diagnosing facet joint arthritis [8]. Until now, 40 cases of this disease were described in the world literature; however, it is estimated that it occurs more frequently but is inadequately diagnosed [7]. Thus, properly performed MR imaging of the spine is crucial in diagnosing facet joint arthritis at early stages and in evaluating the extent of inflammatory process [9].

As a supplementary method, bone scintigraphy is also characterised by a high sensitivity, but lower specificity than

MRI in diagnosing inflammatory lesions in the spine. The use of Technet-99 is characterised by 100% sensitivity in diagnosing facet joint arthritis as early as after 3 days from the onset of first symptoms. However, scintigraphy using Galu-67, performed during the first week from the onset of symptoms may produce false negative results, despite its high sensitivity and specificity in diagnosing intervertebral disc inflammation [9].

Radiological differential diagnosis of facet joint arthritis includes degenerative disease of this joint, synovial cyst located in this area, lesions associated with rheumatoid arthritis and neoplastic metastases to the spine [8].

Treatment of facet joint arthritis is mostly based on conservative methods, including antibiotic administration, first intravenously (for approx. 2 weeks), then orally (for approx. 6 weeks) [8,9]. This form of treatment is successful in 71% of cases. Only some patients require surgical treatment – open surgical procedure (as in the case of our patient) or fluoroscopy or CT guided percutaneous drainage with intraarticular application of antibiotics (effective in

85% of patients). Patients with complications such as epidural abscess or early cauda equina syndrome, should be operated on as a matter of urgency, with open drainage of facet joints and possibly decompressive laminectomy [8,9].

In our patient an open revision of the right facet joint with a removal of the articular capsule and intraarticular administration of antibiotics was successfully performed.

Conclusions

1. The most common cause of the low back pain is a degenerative disease of the intervertebral discs. However, one should also remember about pathologies of the other structures of the spine e.g. facet joints, which may be affected with inflammatory processes leading to a severe and difficult to treat pain.
2. Diagnostic process of the facet joint arthritis is based on: physical examination, detailed anamnesis, results of laboratory tests (ESR, CRP, leukocytosis) and proper diagnostic imaging (MR imaging using a high-field scanners, analysis of fat saturation sequences and postcontrast images).

References:

1. Hendrich B, Bładowska J, Szaśiadek M: Znaczenie badań obrazowych w diagnostyce neurazowych zespołów bólowych kręgosłupa. *Polski Przegląd Neurologiczny*, 2010; 6(2): 92–100 [in Polish]
2. Morton M: Zespoły bólowe kręgosłupa. *Przewodnik Lekarza*, 2008; 5: 45–55 [in Polish]
3. D'Aprile P, Tarantino A, Jinkins JR et al: The value of fat saturation sequences and contrast medium administration in MRI of degenerative disease of posterior/perispinal elements of the lumbosacral spine. *Eur Radiol*, 2007; 17: 523–31
4. Maksymowicz H, Kowalewski K, Lubkowska K et al: Diagnostic value of gadolinium-enhanced MR imaging of active sacroiliitis in seronegative spondyloarthropathy. *Pol J Radiol*, 2010; 75(2): 58–65
5. Szaśiadek MJ, Bładowska J: Imaging of degenerative spine disease – the state of the art. *Adv Clin Exp Med*, 2012; 21(2): 133–42
6. Kalichman L, Li L, Kim D et al: Facet joint osteoarthritis and low back pain in the community-based population. *Spine (Phila Pa 1976)*, 2008; 33(23): 2560–65
7. Rhyu K-W, Park S-U, Ji J-H et al: Pyogenic arthritis of the facet joint with concurrent epidural and paraspinal abscess: a case report. *Asian Spine J*, 2011; 5(4): 245–49
8. Chen MZ: Septic facet joint arthritis. In: Ross JS, Brant-Zawadzki M, Moore KR (eds.): *Diagnostic imaging. Spine*. Amirsys, 1st ed., 2005; III, 1: 18–21
9. Muffoletto AJ, Ketonen LM, Mader JT et al: Hematogenous pyogenic facet joint infection. *Spine (Phila Pa 1976)*, 2001; 26: 1570–76
10. Lumbar Facet Joint Arthritis, <http://www.eorthopod.com/content/lumbar-facet-joint-arthritis>