

## Case Report

# Florid Cystic Endosalpingiosis (Müllerianosis) in Pregnancy

**José Morales-Roselló,<sup>1</sup> Loida Pamplona-Bueno,<sup>1</sup> Beatriz Montero-Balaguer,<sup>2</sup>  
Domingo Desantes-Real,<sup>1</sup> and Alfredo Perales-Marín<sup>1</sup>**

<sup>1</sup>*Servicio de Obstetricia, Hospital Universitario y Politécnico La Fe, Valencia, Spain*

<sup>2</sup>*Servicio de Anatomía Patológica, Hospital Universitario y Politécnico La Fe, Valencia, Spain*

Correspondence should be addressed to José Morales-Roselló; [cm@comv.es](mailto:cm@comv.es)

Received 13 March 2016; Revised 16 August 2016; Accepted 17 August 2016

Academic Editor: Maria Grazia Porpora

Copyright © 2016 José Morales-Roselló et al. This is an open access article distributed under the Creative Commons Attribution License, which permits unrestricted use, distribution, and reproduction in any medium, provided the original work is properly cited.

Cystic endosalpingiosis refers to the existence of heterotopic cystic müllerian tissue resembling structures of the fallopian tubes. We report a case of florid cystic endosalpingiosis discovered in a pregnant woman during a scheduled cesarean section and review the current knowledge of this disease. A 30-year-old woman with a twin pregnancy attended the hospital day unit at term. The first twin was in a breech presentation and a cesarean section was scheduled. During the procedure the uterine fundus and part of the body were seen completely seeded with multitude of cyst-like structures resembling hydatids of Morgagni. The immunohistochemistry analysis showed a positive expression for PAX8 (Box-8), CK7, and estrogen and progesterone receptors. The lesions did not disappear after pregnancy. Cystic endosalpingiosis should be always borne in mind, even in pregnancy, when it comes to making the differential diagnosis of a pelvic or systemic multicystic mass.

## 1. Introduction

Cystic endosalpingiosis is a rare disorder caused by the heterotopical presence of tissue resembling structures of the fallopian tubes [1]. It can be considered part of a wider group of anomalies of embryological origin called müllerianosis [2] consisting in the heterotopic presence of müllerian-derived tissue in pelvic organs, or in distant locations. Although müllerian-derived tissues are sensitive to estrogen and progesterone, reports of cystic endosalpingiosis and other forms of müllerianosis in pregnancy are very scarce. We report a case of florid cystic endosalpingiosis discovered in a pregnant woman during a scheduled cesarean section and review the current knowledge of this disease.

## 2. Case Presentation

A 30-year-old woman with no remarkable past medical history and an uneventful follow-up of a bichorial-biamniotic twin pregnancy attended the hospital day unit at term for fetal growth surveillance and heart rate monitoring. The first twin was in a breech presentation and a cesarean section was

scheduled at 39 weeks. During the procedure and after the extraction of both placentas, the uterine fundus and part of the body were seen completely seeded with multitude of cyst-like structures resembling hydatids of Morgagni but with a harder consistency (Figure 1). A sample of the cysts fluid and a couple of entire cysts were sent for anatomopathological study.

The results of the cysts biopsy (Figure 2) showed a histology formed by an external serous layer, a well-organized smooth muscle, and an inner layer of tubal cylindrical epithelium with small fibrous stroma papillae, no atypias, and no proliferative activity. Although some decidualized cells were present, no endometrial stroma was found. The immunohistochemistry analysis showed a positive expression for PAX8 (Box-8), CK7, and estrogen and progesterone receptors and a negative expression for CD10, calretinin, and CK20. The proliferative index with Ki67 was below 1%. The cytology showed histiocytes and scarce inflammatory cellularity. The final diagnosis was of florid cystic endosalpingiosis.

Three months after the cesarean section, the patient was reevaluated with transvaginal ultrasound (Figure 3).

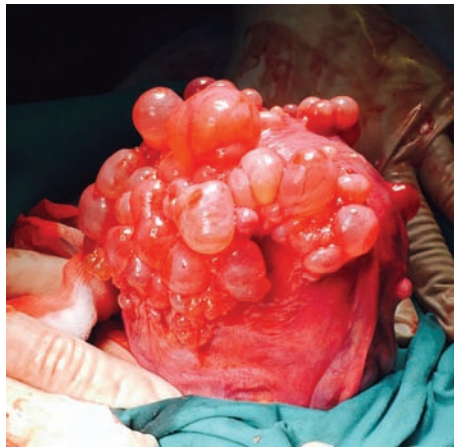


FIGURE 1: Macroscopic view of the cystic endosalpingiosis lesions after the cesarean delivery. The uterine fundus and part of the body are completely seeded with multitude of cyst-like structures resembling hydatids of Morgagni but with a harder structure due to the muscular component.

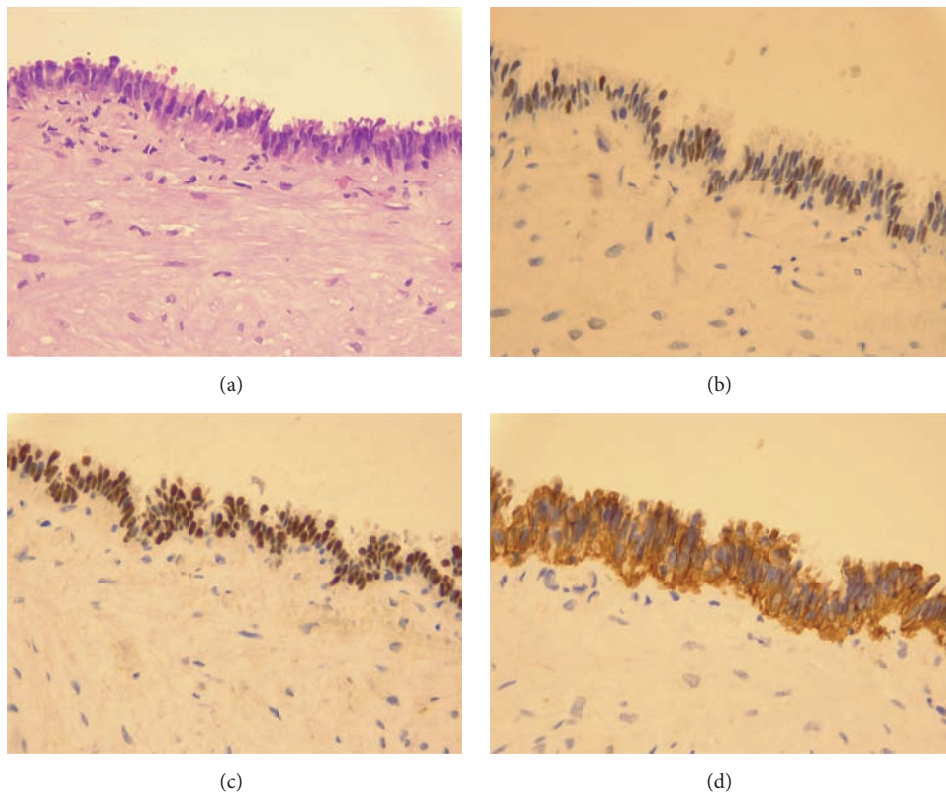


FIGURE 2: Microscopic view of the cystic endosalpingiosis lesions. The hematoxylin-eosin stain (a) showed a histology formed by an external serous layer, a well-organized smooth muscle and an inner layer of tubal cylindrical epithelium with small fibrous stroma papillae, no atypias, and absence of proliferative activity. Although some decidualized cells were present, no endometrial stroma was found. The immunohistochemistry analysis showed a positive expression for estrogen (b) and progesterone receptors, PAX8 (Box-8) (c) and CK7 (d), and a negative expression for CD10, calretinin, and CK20. The proliferative index with Ki67 was below 1%.

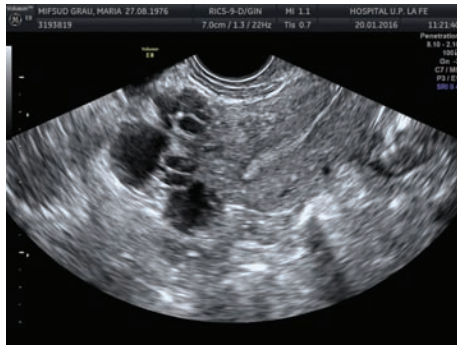

FIGURE 3: Transvaginal ultrasound image of the cystic endosalpingiosis lesions 3 months after the cesarean section. The fundus and part of the uterine body were still covered with multitude of cyst-like structures resembling hydatids of Morgagni. The endosalpingiosis lesions did not disappear after pregnancy.

The examination showed that the fundus and part of the uterine body were still covered with multitude of cyst-like structures. The endosalpingiosis lesions did not disappear after pregnancy.

### 3. Discussion

Cystic endosalpingiosis is part of müllerianosis, disorders consisting in the heterotopic presence of müllerian-derived tissue [1, 2] in pelvic organs like the uterus [3], bladder [4], ovaries [5], parametrium [6], uterosacral mesosalpinx [7], peritoneum [8], and ureters [9] or in distant locations like the small [10] and large intestine (especially in the appendix) [11], coledochal duct [12], axillary nodes [13], mediastinum [14], umbilicus [15], vessels [16], and spine [17].

Most of the reported cases have been observed in non-pregnant women complaining of pelvic pain [18, 19] and urological [9], digestive [20], or neurological symptoms [21] after an ultrasound [22] or MRI [6] examination mimicking diverse kinds of pelvic cystic tumors [23]. Although müllerianosis may contain estrogen and progesterone receptors [14], reports of cystic endosalpingiosis and other forms of müllerianosis in pregnancy are surprisingly very scarce. They are considered choristomas (masses of normal tissue in an abnormal locations) causing endosalpingiosis, endometriosis, adenomyosis, endocervicosis, leiomyomatosis peritonealis disseminata, and probably vascular leiomyomatosis.

During organogenesis, a number of genes of the WNT family [24] like the WNT4 are activated, producing the necessary signals to conduct the development of the müllerian structures. That is the reason why mutations in the WNT-4 gene cause müllerian duct regression [25]. Recent research has underlined the possibility that, on the other extreme, müllerianosis might be caused by the abnormal reactivation of these genes [26, 27], causing metaplasia of normal tissues like the peritoneum. This would explain why these anomalies appear disseminated in the pelvic and abdominal organs [28, 29] or why Box-8 (PAX8) positive cells appear so frequently in peritoneal washing for diverse gynecological indications [30].

However it is true that another possibility for these findings would be the presence of remnants of müllerian precursor cells included within the developing tissues. Be that as it may, these cells are sensitive to estrogen and progesterone and might proliferate during pregnancy increasing the volume of cyst and thus making them detectable at the end of pregnancy. However, the fact that the lesions did not disappear after pregnancy makes this possibility less likely. In summary, cystic endosalpingiosis is a benign condition that should always be considered, even in pregnancy, when it comes to making the differential diagnosis of a pelvic or systemic multicystic mass.

### Competing Interests

The authors declare no competing interests related to this paper.

### References

- [1] L. Prentice, A. Stewart, S. Mohiuddin, and N. P. Johnson, "What is endosalpingiosis?" *Fertility and Sterility*, vol. 98, no. 4, pp. 942–947, 2012.
- [2] R. E. Batt and J. Yeh, "Müllerianosis: four developmental (embryonic) müllerian diseases," *Reproductive Sciences*, vol. 20, no. 9, pp. 1030–1037, 2013.
- [3] A. P. Cil, P. Atasoy, and S. A. Kara, "Myometrial involvement of tumor-like cystic endosalpingiosis: a rare entity," *Ultrasound in Obstetrics and Gynecology*, vol. 32, no. 1, pp. 106–110, 2008.
- [4] K. Maeda, F. Kojima, M. Ishida, M. Iwai, A. Kagotani, and A. Kawachi, "Müllerianosis and endosalpingiosis of the urinary bladder: report of two cases with review of the literature," *International Journal of Clinical and Experimental Pathology*, vol. 7, no. 7, pp. 4408–4414, 2014.
- [5] S. Kaneda, S. Fujii, K. Nosaka et al., "MR imaging findings of mass-forming endosalpingiosis in both ovaries: a case report," *Abdominal Imaging*, vol. 40, no. 3, pp. 471–474, 2014.
- [6] A. L. Hemalatha, K. P. Ashok, K. Anoocha, and C. S. Indira, "Cystic endosalpingiosis of uterine parametrium- a scarcely encountered and sparsely documented entity," *Journal of Clinical and Diagnostic Research*, vol. 8, no. 10, pp. FD06–FD07, 2014.
- [7] S. Lim, J. Y. Kim, K. Park, B. Kim, and G. Ahn, "Müllerianosis of the mesosalpinx: a case report," *International Journal of Gynecological Pathology*, vol. 22, no. 2, pp. 209–212, 2003.
- [8] S. Fredericks, P. Russell, M. Cooper, and N. Varol, "Smooth muscle in the female pelvic peritoneum: a clinicopathological analysis of 31 women," *Pathology*, vol. 37, no. 1, pp. 14–21, 2005.
- [9] W.-M. Li, S.-F. Yang, H.-C. Lin et al., "Müllerianosis of ureter: a rare cause of hydronephrosis," *Urology*, vol. 69, no. 6, pp. 1208.e9–1208.e11, 2007.
- [10] T. Gerber, S. Bontikous, G. Smolka, T. Vestring, D. Schmidt, and W. Gickler, "Cystic lymphangioma with endosalpingiosis as a rare cause of gastrointestinal bleeding," *Zeitschrift für Gastroenterologie*, vol. 40, no. 3, pp. 183–188, 2002.
- [11] M. J. Pollheimer, S. Leibl, V. S. Pollheimer, M. Ratschek, and C. Langner, "Cystic endosalpingiosis of the appendix," *Virchows Archiv*, vol. 450, no. 2, pp. 239–241, 2007.
- [12] I. Mesquita, A. Encinas, C. Gradil et al., "Endosalpingiosis of choledochal duct," *Surgery*, vol. 142, no. 5, article 778, 2007.

- [13] U. Ozerdem and S. A. Hoda, "Endosalpingiosis of axillary sentinel lymph node: a mimic of metastatic breast carcinoma," *Breast Journal*, vol. 21, no. 2, pp. 194–195, 2015.
- [14] R. E. Batt, P. Mhawech-Fauceglia, K. Odunsi, and J. Yeh, "Pathogenesis of mediastinal paravertebral müllerian cysts of hattori: developmental endosalpingiosis-müllerianosis," *International Journal of Gynecological Pathology*, vol. 29, no. 6, pp. 546–551, 2010.
- [15] T. S. Papavramidis, K. Sapalidis, N. Michalopoulos, G. Karayannopoulou, A. Cheva, and S. T. Papavramidis, "Umbilical endosalpingiosis: a case report," *Journal of Medical Case Reports*, vol. 4, article 287, 2010.
- [16] N. Nishida, A. Nonoshita, S. Kojiro, Y. Takemoto, and M. Kojiro, "Intravenous leiomyomatosis with uterine leiomyoma and adenomyosis: a case presentation and brief comment on the histogenesis," *Kurume Medical Journal*, vol. 50, no. 3-4, pp. 173–175, 2003.
- [17] W. W. Scott, B. Ray, K. L. Rickert et al., "Functional müllerian tissue within the conus medullaris generating cyclical neurological morbidity in an otherwise healthy female," *Child's Nervous System*, vol. 30, no. 4, pp. 717–721, 2014.
- [18] J. Heinig, I. Gottschalk, U. Cirkel, and R. Diallo, "Endosalpingiosis—an underestimated cause of chronic pelvic pain or an accidental finding? A retrospective study of 16 cases," *European Journal of Obstetrics & Gynecology and Reproductive Biology*, vol. 103, no. 1, pp. 75–78, 2002.
- [19] T. A. DeHoop, J. Mira, and M. A. Thomas, "Endosalpingiosis and chronic pelvic pain," *Journal of Reproductive Medicine for the Obstetrician and Gynecologist*, vol. 42, no. 10, pp. 613–616, 1997.
- [20] W. G. McCluggage and W. D. B. Clements, "Endosalpingiosis of the colon and appendix," *Histopathology*, vol. 39, no. 6, pp. 645–646, 2001.
- [21] V. Barresi, S. Cerasoli, E. Vitarelli, and R. Donati, "Spinal intradural müllerianosis: a case report," *Histology and Histopathology*, vol. 21, no. 10–12, pp. 1111–1114, 2006.
- [22] M.-W. Lui, S.-F. Ngu, and V. Y. T. Cheung, "Müllerian cyst of the uterus misdiagnosed as ovarian cyst on pelvic sonography," *Journal of Clinical Ultrasound*, vol. 42, no. 3, pp. 183–184, 2014.
- [23] N. Singh, S. Murali, and R. Zangmo, "Florid cystic endosalpingiosis, masquerading as malignancy in a young patient: a brief review," *BMJ Case Reports*, vol. 2014, 2014.
- [24] The WNT homepage, University of Stanford, <http://web.stanford.edu/group/nusselab/cgi-bin/wnt/>.
- [25] A. Biason-Lauber, D. Konrad, F. Navratil, and E. J. Schoenle, "A WNT4 mutation associated with Müllerian-Duct regression and virilization in a 46,XX woman," *The New England Journal of Medicine*, vol. 351, no. 8, pp. 792–798, 2004.
- [26] R. Gaetje, U. Holtrich, K. Engels et al., "Endometriosis may be generated by mimicking the ontogenetic development of the female genital tract," *Fertility and Sterility*, vol. 87, no. 3, pp. 651–656, 2007.
- [27] R. Gaetje, U. Holtrich, T. Karn et al., "Characterization of WNT7A expression in human endometrium and endometriotic lesions," *Fertility and Sterility*, vol. 88, no. 6, pp. 1534–1540, 2007.
- [28] R. Bermejo, A. Gómez, N. Galiana et al., "Peritoneal müllerian tumor-like (endosalpingiosis-leiomyomatosis peritoneal): a hardly known entity," *Case Reports in Obstetrics and Gynecology*, vol. 2012, Article ID 329416, 3 pages, 2012.
- [29] J. Herrero, P. Kamali, and M. Kirschbaum, "Leiomyomatosis peritonealis disseminata associated with endometriosis: a case report and literature review," *European Journal of Obstetrics Gynecology and Reproductive Biology*, vol. 76, no. 2, pp. 189–191, 1998.
- [30] N. Sneige, M. A. Dawlett, T. L. Kologinczak, and M. Guo, "Endosalpingiosis in peritoneal washings in women with benign gynecologic conditions: thirty-eight cases confirmed with paired box-8 immunohistochemical staining and correlation with surgical biopsy findings," *Cancer Cytopathology*, vol. 121, no. 10, pp. 582–590, 2013.