

# Retrospective Study on the Comparative Efficacy of Intra-Articular Injection and Photodynamic Therapy in the Treatment of TMD

Xiaotong Wei<sup>1</sup>, Jing Gao<sup>2</sup>, Zhizhengrong Tian<sup>3</sup>, Fengyun Zhao<sup>4</sup>, Hao Wang<sup>1</sup>, Wei Yan<sup>1</sup>

<sup>1</sup>Department of Oral and Maxillofacial Surgery, Cangzhou Central Hospital, Cangzhou, People's Republic of China; <sup>2</sup>Physical Examination Center, Cangzhou Central Hospital, Cangzhou, People's Republic of China; <sup>3</sup>Department of Ultrasound, Brain Hospital, Cangzhou Central Hospital, Cangzhou, People's Republic of China; <sup>4</sup>Ultrasound Department, Cangzhou Maternal and Child Health Hospital, Cangzhou, People's Republic of China

Correspondence: Xiaotong Wei, Email [weixiaotong0820@163.com](mailto:weixiaotong0820@163.com)

**Objective:** To compare the effectiveness of intra-articular injection and photodynamic therapy (PDT) in the treatment of temporomandibular joint disorder (TMD).

**Methods:** A retrospective analysis was conducted on the clinical data of 91 TMD patients admitted to our hospital from August 2022 to February 2024. Patients were divided into the control group (n=45, treated with intra-articular injection) and the observation group (n=46, treated with PDT). Clinical outcomes, pain levels [Visual Analog Scale (VAS)], maximum mouth opening, masseter muscle pain threshold, Friction Temporomandibular Joint Index (including Joints Number (JN), Joint Pain (JP), Muscle Masseter (MM), Disc Displacement Index (DI), Mandibular Position (MP), Pain Index (PI), and Clinical Measurement Index (CMI)), oral health [Oral Health Impact Profile-14 (OHIP-14)], and quality of life [Short Form-36 (SF-36)] were compared between the two groups.

**Results:** The total effective rate in the observation group (91.30%) was significantly higher than the control group (75.56%) ( $p<0.05$ ). VAS scores showed significant group ( $F=5.487$ ), time ( $F=8.356$ ), and interaction effects ( $F=6.931$ ) ( $p<0.05$ ). Within-group comparisons showed a significant decrease in VAS scores 1 and 4 weeks after treatment ( $p<0.05$ ), with the observation group showing lower VAS scores than the control group ( $p<0.05$ ). After treatment, maximum mouth opening and masseter muscle pain threshold increased in both groups, with the observation group showing greater improvement ( $p<0.05$ ). Friction Temporomandibular Joint Index scores decreased significantly in both groups, with the observation group showing a more significant reduction ( $p<0.05$ ). OHIP-14 scores decreased, and SF-36 scores increased in both groups, with the observation group showing greater improvement ( $p<0.05$ ).

**Conclusion:** PDT is more effective than intra-articular injection in treating TMD. PDT further relieves pain, increases maximum mouth opening and masseter muscle pain threshold, reduces the Friction index, and improves oral health and quality of life.

**Keywords:** intra-articular injection, photodynamic therapy, temporomandibular joint disorder, effectiveness, comparative study

## Introduction

Temporomandibular joint disorders (TMDs) are a collective term for a variety of conditions involving dysfunction of the temporomandibular joints (TMJs) and the masticatory muscles, and they have a global prevalence of approximately 31% in adults.<sup>1</sup> The causes of TMDs are multifactorial, including malocclusions, morphological abnormalities, post-traumatic changes within the TMJs, and masticatory muscle dysfunction.<sup>2</sup> Additionally, general health deterioration, psychological factors (such as stress and anxiety), and even the COVID-19 pandemic have been shown to increase the prevalence of TMDs, with some studies indicating a prevalence rate as high as 42% during the pandemic.<sup>3</sup> Furthermore, mechanical factors, such as wearing medical masks, have been suggested to contribute to the development of TMDs by increasing muscle activity, particularly in the temporalis muscle.<sup>4</sup>

TMDs are often manifested as articular pain, muscular pain, acoustic symptoms (clicking or popping sounds), and reduced jaw mobility, which significantly impair the patient's ability to chew, speak, and engage in daily activities.<sup>5</sup> These symptoms not only affect oral health but also have a significant impact on the patient's quality of life, contributing

to emotional distress and social limitations. Management of TMDs involves a variety of treatment approaches, including conservative methods such as physiotherapy, splint therapy, and oral drug therapy, as well as more invasive treatments such as intra-articular injections and arthroscopic surgery.<sup>6</sup> Among these, intra-articular injections have been widely used in clinical practice. These injections, which include corticosteroids, hyaluronic acid (HA), and platelet-rich plasma (PRP), aim to relieve pain, reduce inflammation, and restore joint function.<sup>7</sup> However, side effects and patient tolerance remain concerns, which has led to the exploration of alternative treatments such as photodynamic therapy (PDT).

PDT has shown promise in treating a variety of medical conditions, including dermatological and oncological disorders, and recent studies suggest its potential efficacy in TMD treatment.<sup>8</sup> PDT uses photosensitizers activated by light to generate reactive oxygen species, which can reduce inflammation and promote healing by improving microcirculation.<sup>9</sup> Despite its promising outcomes, there is limited research directly comparing PDT with intra-articular injection in the treatment of TMDs. This study aims to fill this gap by conducting a retrospective analysis to compare the efficacy of intra-articular injection and PDT, offering clearer clinical guidance for TMD management.

## Materials and Methods

### Basic Information

A retrospective analysis was conducted on the clinical data of 91 patients with temporomandibular joint disorder (TMD) admitted to our hospital from August 2022 to February 2024. Inclusion criteria: (1) TMD diagnoses were confirmed based on clinical evaluation and imaging studies, including MRI and CT scans, as per the diagnostic criteria outlined in.<sup>10</sup> (2) Patients exhibited varying degrees of TMD symptoms such as temporomandibular joint pain and functional impairment. (3) Patients aged  $\geq 18$  years and  $\leq 65$  years, regardless of gender. (4) Patients had undergone at least one treatment course involving medication, hot compresses, or acupuncture before enrollment, but with unsatisfactory results. (5) Patients and their families were fully informed about the study and signed the relevant consent documents. (6) Patients had complete and authentic clinical data available for analysis. Exclusion criteria: (1) Patients with systemic diseases. (2) Patients requiring treatment for other oral diseases. (3) Diagnosed with acute TMD requiring initial medication control. (4) Advised to undergo surgical treatment. (5) History of oral joint trauma or surgery. (6) History of mental illness or cognitive impairment. (7) Allergic reactions or contraindications to the treatment implemented in the study. (8) Inability to fully cooperate with the study for any reason. Patients were divided into the control group ( $n=45$ , treated with intra-articular injection) and the observation group ( $n=46$ , treated with PDT), according to their treatment method. This study was approved by the Medical Ethics Committee of Cangzhou Central Hospital (approval number: KQ24-DB013) and was conducted in strict compliance with ethical norms. Informed consent was obtained from all study participants. All the methods were carried out in accordance with the Declaration of Helsinki.

## Methods

### Control Group

The control group received intra-articular injection treatment: (1) Patient preparation and positioning: Before treatment, patients were instructed to open their mouths as widely as possible to expose the joint cavity area. Physicians palpated the condyle of the temporomandibular joint and marked an injection point 10–12 mm anterior to the tragus. (2) Injection procedure: An 8-gauge needle was used to inject at the marked point anterior to the tragus, directing the needle towards the anteromedial side of the upper joint cavity to ensure even distribution of the drug. A 2 mL injection of lidocaine hydrochloride solution (Shanghai Hefeng Pharmaceutical Co., Ltd., National Drug Approval Number H20023775) was administered for local anesthesia to relieve joint and surrounding soft tissue pain. (3) Joint cavity irrigation: After the injection, the needle was retained in the joint cavity. The cavity was irrigated repeatedly using sodium chloride injection (Sichuan Kelun Pharmaceutical Co., Ltd., National Drug Approval Number H20056626) to remove inflammatory products and metabolic waste, promoting joint cavity cleanliness. (4) Hyaluronic acid injection: Following joint cavity irrigation, 1 mL of hyaluronic acid solution (Shandong Bausch & Lomb Freda Pharmaceutical Co., Ltd., National Drug Approval Number H10960136) was injected. Treatment was performed every 10 days, totaling three sessions to complete a treatment cycle.

## Observation Group

The observation group underwent PDT (In addition to PDT, patients were not allowed to use any other pain relief treatments or rehabilitation methods during the treatment period to avoid confounding factors): (1) Treatment equipment: An LED-IB photodynamic therapy device (Wuhan Yage Optoelectronics Technology Co., Ltd., Production Approval Number: E-SFDA (Zhun) No. 20102260940) was used. The device provides three light wavelengths: red light ( $633\pm 10$  nm), blue light ( $417\pm 10$  nm), and yellow light ( $590\pm 10$  nm), each with different power densities. (2) Treatment parameters: Red light output power density was 20–100 mW/cm<sup>2</sup>, blue light 25–120 mW/cm<sup>2</sup>, and yellow light 10–40 mW/cm<sup>2</sup>. The choice of red ( $633\pm 10$  nm), blue ( $417\pm 10$  nm), and yellow ( $590\pm 10$  nm) light wavelengths was based on their distinct effects on tissue healing and inflammation. Red light is typically used for deeper tissue penetration and inflammation reduction, while blue and yellow light are beneficial for promoting microcirculation and alleviating muscle tension. (3) Treatment process: The light therapy head was positioned directly over the affected temporomandibular joint area for irradiation. Each session lasted 30 minutes, performed twice daily. Both groups were evaluated for efficacy one month after treatment. Photodynamic therapy (PDT) may cause temporary side effects such as skin irritation, redness, or a burning sensation in the treated area. These side effects are typically mild and resolve after a short period.

All treatments were administered by a senior clinician with over 10 years of experience in the management of temporomandibular disorders.

## Observational Indicators

1. **Clinical treatment efficacy:** Assessed using indicators such as pain level and maximum mouth opening. Significant effect: Pain resolved, maximum mouth opening >3.5 cm. Effective: Pain alleviated, maximum mouth opening 3.0–3.5 cm. Ineffective: Pain not improved or worsened, maximum mouth opening <3.0 cm. Total effective rate = 100% - (number of ineffective cases/total cases × 100%).
2. **Pain status:** Pain levels were assessed using the Visual Analogue Scale (VAS)<sup>11</sup> before treatment, one week after treatment, and four weeks after treatment. VAS scores ranged from 0 to 10, with higher scores indicating more severe pain.
3. **Maximum mouth opening:** Measured using a vernier caliper before and after treatment. The distance between the upper and lower lips was recorded to the nearest 0.1 mm, with the average of three measurements taken.
4. **Masseter muscle pain threshold:** Assessed using an HF-10N Ailidigital pressure gauge before and after treatment. The average of three measurements was recorded.
5. **Friction Temporomandibular Index:** The Friction index scoring system<sup>12</sup> was used to evaluate the condition of the temporomandibular joint before and after treatment. This system includes indices such as: Temporomandibular Joint Dysfunction Index (CMI, 0–1 points). Dysfunction Index (DI, 0–1 points). Joint Noise (JN, 0–4 points). Joint Palpation Score (JP, 0–6 points). Mandibular Movement (MM, 0–16 points). Muscle Palpation (MP, 0–28 points). Muscle Pain Index (PI, 0–1 points).  $DI = (MM + JN + JP)/26$ ;  $PI = MP/28$ ;  $CMI = (DI + PI)/2$ .
6. **Oral health:** Evaluated using the Oral Health Impact Profile (OHIP-14)<sup>13</sup> before and after treatment. OHIP-14 scores range from 0 to 56, with higher scores indicating greater negative impact on oral health and quality of life.
7. **Quality of life:** Assessed using the Short Form Health Survey (SF-36)<sup>14</sup> before and after treatment. SF-36 scores range from 0 to 100, with higher scores indicating better quality of life.

## Statistical Analysis

GraphPad Prism 8 was used for chart creation, and SPSS 22.0 was used for statistical analysis. Categorical data were expressed as percentages (%) and analyzed using the  $\chi^2$ -test. Continuous data were expressed as ( $\bar{x}\pm s$ ). Independent sample t-tests were used for comparisons between groups, paired t-tests for intra-group comparisons, and repeated-measures ANOVA for comparisons of different time points between groups.

A P-value < 0.05 was considered statistically significant. A power analysis was performed to ensure sufficient sample size to detect meaningful differences between the groups. Based on preliminary data, the required sample size was determined to be 91 patients to achieve a statistical power of 80% with a significance level of 0.05.

## Results

### Comparison of Basic Data

There were no significant differences in basic data, such as gender, age, duration of illness, disease type, and lesion location, between the two groups ( $P > 0.05$ ), indicating comparability, as shown in [Table 1](#).

### Comparison of Clinical Treatment Effects

Among the 45 patients in the control group, 18 were markedly effective, 16 were effective, and 11 were ineffective. In the observation group, 25 were markedly effective, 17 were effective, and 4 were ineffective. The total effective rate in the observation group (91.30%) was higher than that in the control group (75.56%) ( $P < 0.05$ ), as shown in [Figure 1](#). For the comparison of total efficacy rates, Cohen's  $d = 0.39$ , indicating a moderate effect of the observation group compared to the control group.

### Comparison of Pain Status

The group ( $F=5.487$ ), time ( $F=8.356$ ), and interaction ( $F=6.931$ ) comparisons of VAS scores were statistically significant ( $P < 0.05$ ). Within-group comparisons showed that VAS scores at 1 week and 4 weeks post-treatment were significantly lower than before treatment for both groups ( $P < 0.05$ ). Between-group comparisons showed that VAS scores before treatment were similar for both groups ( $P > 0.05$ ). However, at 1 week and 4 weeks post-treatment, the VAS scores in the observation group were significantly lower than those in the control group ( $P < 0.05$ ), as shown in [Figure 2](#). One week after treatment, Cohen's  $d = 0.61$ , indicating a moderate effect of the observation group in pain reduction; four weeks after treatment, Cohen's  $d = 0.85$ , indicating a strong effect of the observation group in pain reduction.

### Comparison of Maximum Mouth Opening and Masseter Pain Threshold

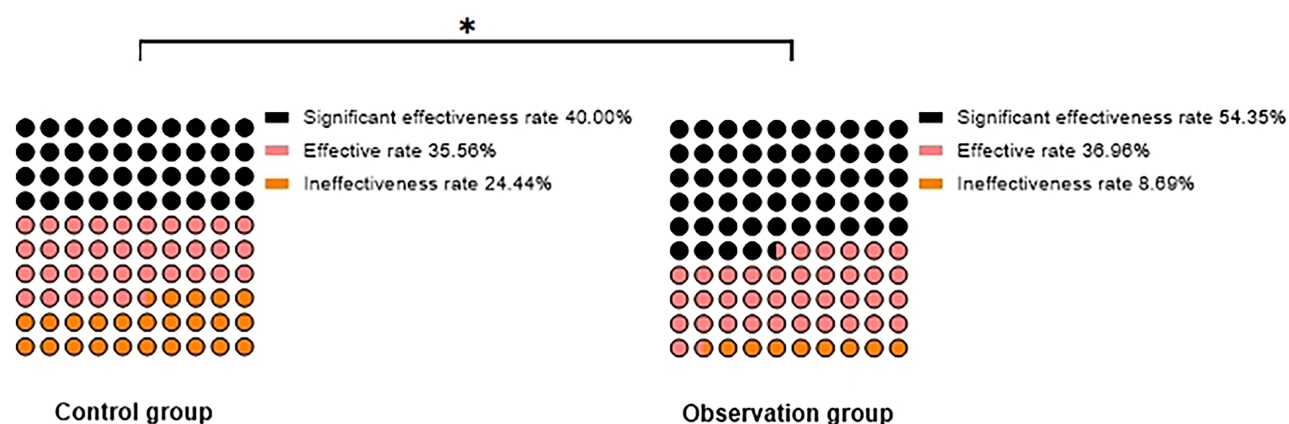
After treatment, the maximum mouth opening and masseter pain threshold in both groups increased, with the observation group showing a greater improvement ( $P < 0.05$ ), as shown in [Table 2](#). For the change in maximum mouth opening, Cohen's  $d = 0.55$ , indicating a moderate effect of the observation group compared to the control group; for the change in masseter muscle pain threshold, Cohen's  $d = 1.25$ , indicating a strong effect of the observation group.

### Comparison of Friction Temporomandibular Joint Index

After treatment, the JN, JP, MM, DI, MP, PI, and CMI scores were lower than before treatment in both groups, with the observation group showing greater changes ( $P < 0.05$ ), as shown in [Figure 3](#). Cohen's  $d$  showed a moderate to strong effect in the changes of all these indicators ( $d$  value range: 0.5–0.8).

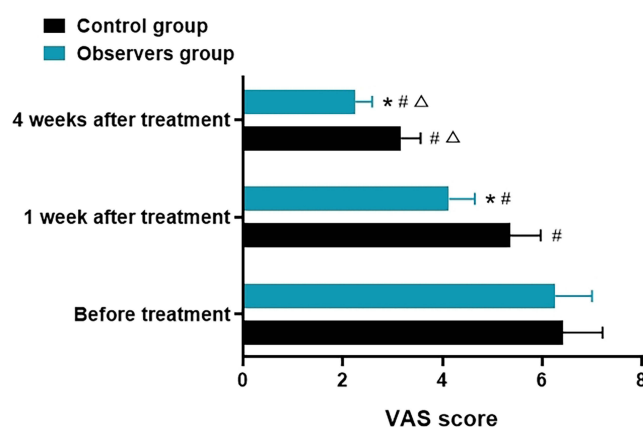
**Table 1** Comparison of Basic Data ( $\bar{x} \pm s$ , n[%])

	Control (n=45)	Observation (n=46)	t/ $\chi^2$	P
Gender	–	–	0.528	0.467
Male	22 (48.89)	19 (41.30)	–	–
Female	23 (51.11)	27 (58.70)	–	–
Age (years)	57.93 $\pm$ 6.02	58.41 $\pm$ 5.78	0.388	0.698
Disease Duration (days)	18.05 $\pm$ 2.39	18.34 $\pm$ 2.97	0.512	0.609
Disease Type	–	–	0.296	0.586
Masticatory Muscle Disorder	27 (60.00)	25 (54.35)	–	–
Joint Structural Disorder	18 (40.00)	21 (45.65)	–	–
Lesion Location	–	–	1.322	0.250
Left Side	22 (48.89)	17 (36.96)	–	–
Right Side	15 (33.33)	19 (41.30)	–	–
Bilateral	8 (17.78)	10 (21.74)	–	–



**Figure 1** Comparison of Clinical Treatment Effects [n(%)].

**Note:** \* $P < 0.05$  for inter-group comparison.



**Figure 2** Comparison of Pain Status ( $\bar{x} \pm s$ , scores).

**Notes:** \* $P < 0.05$  for inter-group comparison at the same time point; # $P < 0.05$  for comparison with pre-treatment in the same group; Δ $P < 0.05$  for comparison with post-treatment at 1 week in the same group.

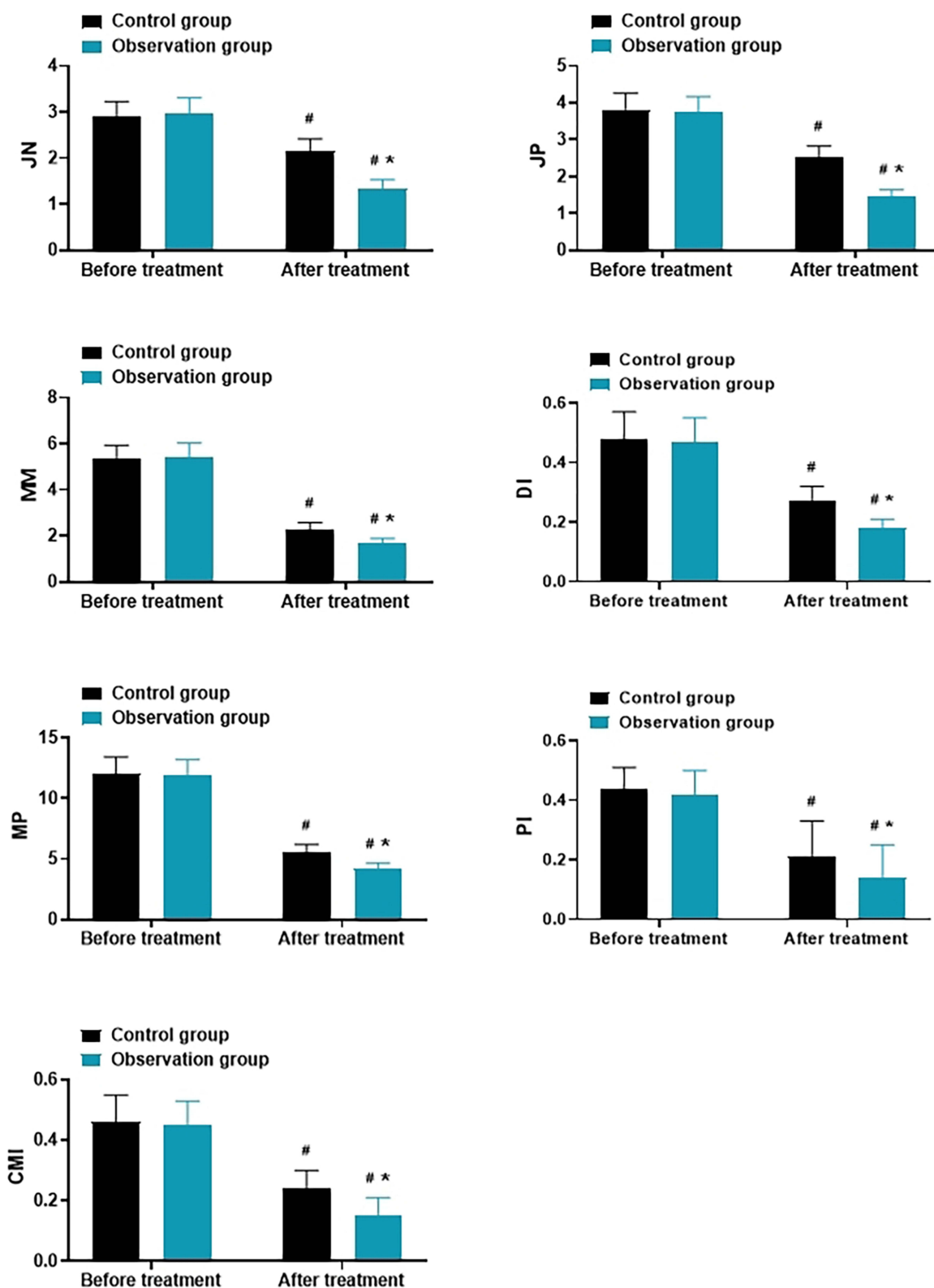
## Comparison of Oral Health and Quality of Life

After treatment, the OHIP-14 scores decreased, while the SF-36 scores increased in both groups. The observation group showed greater improvements in both OHIP-14 and SF-36 scores ( $P < 0.05$ ), as shown in Table 3. For the change in OHIP-14 scores, Cohen's  $d = 1.12$ , indicating a strong effect in the observation group; for the change in SF-36 scores, Cohen's  $d = 0.88$ , indicating a strong effect in the observation group.

**Table 2** Comparison of Maximum Mouth Opening and Masseter Pain Threshold ( $\bar{x} \pm s$ )

	Control (n=45)	Observation (n=46)	t	P
Maximum Mouth Opening (mm)	–	–	–	–
Before treatment	45.17±5.83	45.34±5.39	0.144	0.885
After treatment	47.39±5.41 <sup>#</sup>	50.21±5.14 <sup>#</sup>	2.549	0.012
Masseter Pain Threshold (kg/m <sup>2</sup> )	–	–	–	–
Before treatment	2.69±0.32	2.71±0.31	0.302	0.762
After treatment	2.95±0.36 <sup>#</sup>	3.32±0.38 <sup>#</sup>	4.766	<0.001

**Note:** <sup>#</sup> $P < 0.05$  compared with pre-treatment in the same group.



**Figure 3** Comparison of Friction Temporomandibular Joint Index ( $\bar{x} \pm s$ , scores).

**Notes:** \*P < 0.05 for inter-group comparison at the same time point; #P < 0.05 for comparison with pre-treatment in the same group.



**Table 3** Comparison of Oral Health and Quality of Life ( $\bar{x}\pm s$ , Scores)

	Control (n=45)	Observation (n=46)	t	P
OHIP-14 Score	—	—	—	—
Before treatment	38.25±4.19	38.53±4.12	0.321	0.748
After treatment	12.27±1.76	9.51±1.05 <sup>#</sup>	9.108	<0.001
SF-36 Score	—	—	—	—
Before treatment	64.94±7.18	64.83±7.07	0.073	0.941
After treatment	76.45±8.03 <sup>#</sup>	83.12±8.73 <sup>#</sup>	3.791	<0.001

Note: <sup>#</sup>P < 0.05.

## Discussion

This study aims to compare the effects of intra-articular injection and PDT in the treatment of TMD, evaluating the clinical efficacy of both treatments in terms of pain relief, joint function recovery, improvement in oral health, and quality of life. The following discussion will delve into the results of this study from the perspectives of the pathological mechanisms of TMD, the mechanisms of action of the two treatments, clinical outcomes, and potential clinical applications.

## Analysis of Clinical Characteristics and Pathological Mechanisms of TMD

TMD is a group of disorders that affect the temporomandibular joint and its surrounding soft tissues, often accompanied by symptoms such as limited mouth opening, joint sounds, difficulty chewing, and facial pain.<sup>15</sup> Its pathogenesis is complex, involving multiple factors such as excessive tension in the masticatory muscles, disc displacement, joint cartilage degeneration, and psychological factors.<sup>16</sup> The core goals of clinical treatment for TMD include pain relief, joint function recovery, and improvement in oral health. Patients often experience long-term pain and functional impairments that affect their daily life, leading to anxiety, depression, and other negative emotions, which in turn exacerbate symptoms and impact their quality of life.<sup>17</sup>

Intra-articular injection of sodium hyaluronate is one of the common methods used in the clinical treatment of TMD. It works by directly injecting sodium hyaluronate into the joint cavity, improving joint lubrication, reducing inflammation, alleviating pain, and improving joint function.<sup>18</sup> Sodium hyaluronate, as a derivative of hyaluronic acid, can supplement the natural fluid in the joint cavity, reduce joint friction, and improve the joint's internal environment.<sup>19</sup> However, despite its ability to relieve pain and improve joint mobility, the effectiveness of this treatment tends to be short-lived, and repeated injections may have side effects, such as potential impacts on the joint cartilage.<sup>20</sup> In contrast, PDT, as a novel treatment modality, utilizes the photochemical reactions induced by non-thermal effects to generate reactive oxygen species (ROS), promoting local tissue repair, reducing inflammation and pain, and improving microcirculation.<sup>21</sup> The results of this study indicate that PDT exhibited significant effects in improving treatment outcomes for TMD patients, alleviating pain, improving joint function, and oral health, with a longer duration of efficacy, suggesting its clinical potential.

## Pain Relief

Regarding pain assessment, this study used the VAS to compare the pain levels of the two groups. The results show that VAS scores significantly decreased in both groups after treatment, with the observation group (PDT) demonstrating significantly lower VAS scores at 1 week and 4 weeks post-treatment compared to the control group (sodium hyaluronate injection). This finding is consistent with previous studies,<sup>22,23</sup> suggesting that PDT has better efficacy in relieving pain in TMD patients. Sodium hyaluronate alleviates pain caused by degenerative changes or inflammation in the joint by improving joint lubrication. However, because sodium hyaluronate mainly relies on the physical lubrication of the joint, its effect is often short-term and diminishes over time.<sup>24</sup> PDT, on the other hand, works by photochemical reactions, where the generated ROS penetrate deeper into tissues, inhibiting the release of inflammatory mediators and reducing oxidative damage, thus achieving more lasting pain relief.<sup>25</sup> Therefore, while sodium hyaluronate injection can provide

short-term pain relief, its effects are not as sustained or comprehensive as those of PDT. In chronic TMD patients, PDT offers prolonged pain control through continuous microcirculation improvement and tissue repair.

## Joint Function Recovery and Maximum Mouth Opening Limitation and Masseter Pain Threshold

Recovery of joint function is another critical goal in TMD treatment. In terms of maximum mouth opening and masseter pain threshold, the observation group showed significantly greater improvements post-treatment compared to the control group ( $P < 0.05$ ). This phenomenon can be explained by the treatment mechanism of PDT: PDT improves local microcirculation, enhances blood and oxygen supply, and promotes tissue repair, which effectively reduces inflammation in the joint and muscles, relieves muscle tension, and restores joint mobility.<sup>26,27</sup> Although sodium hyaluronate injection can improve joint lubrication and alleviate movement restrictions caused by synovial inflammation, its effects are mainly limited to the joint's lubrication and are less effective in relaxing surrounding muscles and increasing the pain threshold. Moreover, sodium hyaluronate is concentrated locally and mainly acts within the joint cavity, unlike PDT, which can broadly promote soft tissue repair and functional recovery.<sup>28</sup>

## Oral Health and Quality of Life Improvement

In this study, the Friction temporomandibular joint index, OHIP-14 score, and SF-36 score were used to assess patients' oral health and quality of life. The results indicated that the observation group showed significantly lower JN, JP, MM, DI, MP, PI, CMI, and OHIP-14 scores, and higher SF-36 scores compared to the control group ( $P < 0.05$ ). These findings suggest that PDT demonstrated better efficacy in improving TMD-related symptoms, psychological health, social function, and overall health perception. It is hypothesized that PDT, by reducing inflammation, promoting local repair, and improving microcirculation, not only alleviates joint pain and restores function but also indirectly enhances patients' overall health perception and psychological well-being. In contrast, sodium hyaluronate injection primarily focuses on improving joint function and relieving pain. Although it has some therapeutic effect on TMD, its impact on improving quality of life and psychological state is relatively limited.

## Mechanistic Advantages, Limitations, and Clinical Application Prospects of Photodynamic Therapy

The mechanistic advantage of PDT lies in its multifaceted therapeutic actions. Through photochemical reactions, PDT generates reactive oxygen species without causing thermal tissue damage, directly acting on local tissues to reduce inflammation, improve blood circulation, and enhance tissue repair capacity.<sup>29</sup> For TMD patients, PDT can not only relieve pain in the joint and masticatory muscles but also promote soft tissue repair and joint function recovery. Additionally, PDT is non-invasive and free from side effects, avoiding potential local discomfort or joint cartilage damage associated with sodium hyaluronate injection.

Although this study demonstrates the clinical advantages of PDT, there are still certain limitations. First, this is a retrospective analysis with a relatively small sample size, and larger-scale prospective randomized controlled studies are needed to further verify the reliability of the results. Second, the follow-up period of this study is relatively short, and the long-term effects and safety of PDT have yet to be evaluated. Therefore, future studies should involve multi-center, large-sample, long-term follow-up designs to further clarify the clinical application value of PDT in the treatment of TMD. Although the application of PDT in TMD treatment is still in the exploratory phase, its potential is immense, especially for chronic TMD patients. PDT offers a long-term, sustainable treatment option, and with advancements in technology, more refined treatment plans are expected, such as combining different wavelengths of light and adjusting PDT parameters to achieve more personalized and precise treatments in the future.

## Conclusion

In conclusion, both intra-articular injection and photodynamic therapy (PDT) are effective treatments for temporomandibular joint disorder (TMD), but PDT demonstrates superior clinical outcomes in terms of pain relief, joint function



recovery, improvement in oral health, and overall quality of life. PDT offers a more sustainable and longer-lasting effect compared to sodium hyaluronate injection, likely due to its photochemical mechanism, which promotes tissue repair, reduces inflammation, and improves microcirculation. Additionally, PDT's non-invasive nature and the absence of side effects associated with repeated injections of sodium hyaluronate make it a promising alternative, especially for patients with chronic or severe TMD.

## Funding

Cangzhou Natural Science Foundation (23241001009N).

## Disclosure

The authors report no conflicts of interest in this work.

## References

1. Turosz N, Chęcińska K, Chęciński M, et al. Temporomandibular Joint Injections and Lavage: an Overview of Reviews. *J Clin Med.*;13(10):2855. PMID: 38792396; PMCID: PMC11122581. doi:10.3390/jcm13102855
2. Golanska P, Saczuk K, Domarecka M, Kuć J, Lukomska-Szymanska M, et al. Temporomandibular myofascial pain syndrome-aetiology and biopsychosocial modulation. *Int J Environ Res Public Health.* 2021;18(15).
3. Chęciński M, Chęcińska K, Turosz N, Brzozowska A, Chlubek D, Sikora M. Current clinical research directions on temporomandibular joint intra-articular injections: a mapping review. *J Clin Med.* 2023;12(14):4655. PMID: 37510770; PMCID: PMC10380303. doi:10.3390/jcm12144655
4. Béret M, et al. Efficacy of Intra-Articular Injection of Botulinum Toxin Type a (*Incobotulinumtoxin*) in Temporomandibular Joint Osteoarthritis: A Three-Arm Controlled Trial in Rats. Vol. 15. *Toxins*; 2023.
5. Andre A, Kang J, Dym H. Pharmacologic treatment for temporomandibular and temporomandibular joint disorders. *Oral Maxillofac Surg Clin North Am.* 2022;34(1):49–59. doi:10.1016/j.coms.2021.08.001
6. Wan Y, Zeng Q, Jiang L, et al. Efficacy of photodynamic therapy in the treatment of actinic keratosis: a network meta-analysis. *J Cutan Med Surg.* 2024;28(6):536–542. doi:10.1177/12034754241266177
7. Liu Y, Cao Z, Wei G. Effects of photodynamic therapy using Red LED-light combined with hypocrellin B on apoptotic signaling in cutaneous squamous cell carcinoma A431 cells. *Photodiagnosis Photodyn Ther.* 2023;43:103683. doi:10.1016/j.pdpdt.2023.103683
8. Alimadadi H, Asnaashari M, Naseri M, et al. Effect of apical size and taper on the efficacy of root canal disinfection with LED Photodynamic therapy as an adjunct to irrigation with sodium hypochlorite. *J Lasers Med Sci.* 2021;12:e58. doi:10.34172/jlms.2021.58
9. Kitanaka Y, Takeuchi Y, Hiratsuka K, et al. The effect of antimicrobial photodynamic therapy using yellow-green LED and rose Bengal on *Porphyromonas gingivalis*. *Photodiagnosis Photodyn Ther.* 2020;32:102033. doi:10.1016/j.pdpdt.2020.102033
10. Durham J, Ohrbach R, Baad-Hansen L, et al. Constructing the brief diagnostic criteria for temporomandibular disorders (bDC / TMD) for field testing. *J Oral Rehabil.* 2024;51(5):785–794. doi:10.1111/joor.13652
11. Zhao H, Luo D, Yang JJ, et al. [Clinical effect and analysis of exercise treatment for temporomandibular joint osteoarthritis]. *Zhonghua Kou Qiang Yi Xue Za Zhi.* 2022;57(7):701–707. doi:10.3760/cma.j.cn112144-20220314-00109 Dutch
12. Zhang Z, Luo X, Li X, et al. The preliminary study of the effects of individual musculoskeletally stable position in the treatment of temporomandibular disorders. *BMC Oral Health.* 2024;24(1):1083. doi:10.1186/s12903-024-04864-9
13. Crescente BB, Bisatto NV, Rübensam G, et al. Assessment of temporomandibular disorders and their relationship with life quality and salivary biomarkers in patients with dentofacial deformities: a clinical observational study. *PLoS One.* 2023;18(7):e0288914. doi:10.1371/journal.pone.0288914
14. Qamar Z, Alghamdi AM, Haydarah NK, et al. Impact of temporomandibular disorders on oral health-related quality of life: a systematic review and meta-analysis. *J Oral Rehabil.* 2023;50(8):706–714. doi:10.1111/joor.13472
15. Braz MA, Freitas Portella F, Seehaber KA, et al. Association between oxidative stress and temporomandibular joint dysfunction: a narrative review. *J Oral Rehabil.* 2020;47(4):536–546. doi:10.1111/joor.12930
16. Wei X, et al. Effect of Extracorporeal Shock Wave on IGF-1, TNF- $\alpha$ , and IL-1 $\alpha$  in Joint Fluid of Patients With Temporomandibular Joint Disorder Syndrome. *Cell Biochem Biophys.* 2024.
17. Lerman SF, Mun CJ, Hunt CA, et al. Insomnia with objective short sleep duration in women with temporomandibular joint disorder: quantitative sensory testing, inflammation and clinical pain profiles. *Sleep Med.* 2022;90:26–35. doi:10.1016/j.sleep.2022.01.004
18. Dhiman NK, Jaiswara C, Hirani MS, et al. Efficacy of arthrocentesis with intra-articular injection of hyaluronic acid and corticosteroid in the treatment of internal derangement of temporomandibular joint. *Natl J Maxillofac Surg.* 2023;14(1):93–100. doi:10.4103/njms.njms\_8\_22
19. Ravaggi E, Ramieri G, Bosco GF, et al. Temporomandibular joint arthrocentesis: a single-center experience and review of the literature. *Minerva Dent Oral Sci.* 2023;72(2):69–76. doi:10.23736/S2724-6329.22.04653-8
20. Kukreja P, et al. Efficacy of Hyaluronic Acid in Temporomandibular Disorders Evaluated With Diagnostic Criteria for Temporomandibular Disorders (DC/TMD). *J Oral Rehabil.* 2024.
21. Losev FF, Krechina EK, Tarasova MM, et al. [The effectiveness of photodynamic effects on the clinical and functional state of periodontal tissues in periodontitis]. *Stomatologiia.* 2024;103(4):5–9. doi:10.17116/stomat20241030415
22. Losev FF, Krechina EK, Ivanova EV, et al. [The use of photodynamic therapy in the complex treatment of chronic generalized moderate periodontitis]. *Stomatologiia.* 2023;102(2):11–15. doi:10.17116/stomat202310202111
23. Krechina EK, Myagkova AV, Abdurakhmanova ZU, et al. [Evaluation of the photodynamic effect on the state of microcirculation and oxygenation in periodontal tissues in the treatment of chronic generalized periodontitis]. *Stomatologiia.* 2024;103(2):18–23. doi:10.17116/stomat202410302118

24. Agostini F, Ferrillo M, Bernetti A, et al. Hyaluronic acid injections for pain relief and functional improvement in patients with temporomandibular disorders: an umbrella review of systematic reviews. *J Oral Rehabil.* 2023;50(12):1518–1534. doi:10.1111/joor.13571
25. Long XX, Xie A-D, Yang P, et al. Effect of various types of photodynamic therapy on inflammatory and non-inflammatory lesions in patients with acne: a network meta-analysis of randomized controlled trials. *Photodiagnosis Photodyn Ther.* 2023;42:103365. doi:10.1016/j.pdpdt.2023.103365
26. Pires Marques EC, Piccolo Lopes F, Nascimento IC, et al. Photobiomodulation and photodynamic therapy for the treatment of oral mucositis in patients with cancer. *Photodiagnosis Photodyn Ther.* 2020;29:101621. doi:10.1016/j.pdpdt.2019.101621
27. Silva LAD, Pinheiro SL. Clinical evaluation of intravascular blood irradiation with laser, photobiomodulation, and photodynamic therapy in cancer patients with mucositis. *Photobiomodul Photomed Laser Surg.* 2021;39(11):687–695. doi:10.1089/photob.2021.0031
28. Shipika DV, Ostashko AA, Burenchev DV, et al. Clinical example of complex diagnostic and treatment of patient with temporomandibular joint internal derangements with arthroscopic surgery]. *Stomatologiya.* 2021;100(4):109–116. doi:10.17116/stomat2021100041109
29. Petrini M, Pierfelice TV, D'Amico E, et al. Comparison between single and multi-LED emitters for photodynamic therapy: an in vitro study on enterococcus faecalis and human gingival fibroblasts. *Int J Environ Res Public Health.* 2022;19(5). doi:10.3390/ijerph19053048

## Therapeutics and Clinical Risk Management

### Publish your work in this journal

Therapeutics and Clinical Risk Management is an international, peer-reviewed journal of clinical therapeutics and risk management, focusing on concise rapid reporting of clinical studies in all therapeutic areas, outcomes, safety, and programs for the effective, safe, and sustained use of medicines. This journal is indexed on PubMed Central, CAS, EMBase, Scopus and the Elsevier Bibliographic databases. The manuscript management system is completely online and includes a very quick and fair peer-review system, which is all easy to use. Visit <http://www.dovepress.com/testimonials.php> to read real quotes from published authors.

Submit your manuscript here: <https://www.dovepress.com/therapeutics-and-clinical-risk-management-journal>

**Dovepress**  
Taylor & Francis Group