



Contents lists available at ScienceDirect

International Journal of Surgery Case Reports

journal homepage: www.casereports.com

Leiomyomatosis Peritonealis Disseminata (LPD) ten years after laparoscopic myomectomy associated with ascites and lymph nodes enlargement: a case report

Luigi Nappi^a, Felice Sorrentino^{a,*}, Stefano Angioni^b, Alessandro Pontis^b, Ida Barone^a, Pantaleo Greco^c

^a Institute of Obstetrics and Gynaecology, Department of Medical and Surgical Sciences, University of Foggia, Foggia, Italy

^b Institute of Obstetrics and Gynaecology, Department of Surgical Sciences, University of Cagliari, Cagliari, Italy

^c Department of Morphology, Surgery and Experimental Medicine, Section of Obstetrics and Gynaecology, University of Ferrara, Ferrara, Italy

ARTICLE INFO

Article history:

Received 28 April 2016

Received in revised form 15 May 2016

Accepted 17 May 2016

Available online 2 June 2016

Keywords:

Ascites

Leiomyomatosis peritonealis disseminata

Electrical morcellation

Myomectomy

ABSTRACT

INTRODUCTION: We report a case of leiomyomatosis peritonealis disseminata (LPD) arising 10 years after a laparoscopic myomectomy that was associated with ascites and lymph nodes enlargement.

PRESENTATION OF CASE: The patient presented with small uterine fibroids with a dominant posterior intramural fibroid measuring 9 cm in diameter and normal Doppler. Laparotomy revealed a uterus enlarged with fibroids, which was densely adhering to the urinary bladder, greater omentum, and sigmoid colon. Multiple tumors of different size were found attached to the peritoneum, omentum and bowel. The histopathologic examination was consistent with leiomyomatosis peritonealis disseminata.

DISCUSSION: Pieces of smooth muscle cell lost in the abdominal cavity during electrical morcellation after laparoscopic myomectomy may progress to leiomyomatosis peritonealis disseminata even after many years (ten in our case) and it can be associated with ascites and lymph nodes enlargement.

CONCLUSION: This is the first case reported in literature of leiomyomatosis peritonealis disseminata with these particular features (time of clinical presentation, ascites, lymph nodes enlargement).

© 2016 The Author(s). Published by Elsevier Ltd on behalf of IJS Publishing Group Ltd. This is an open access article under the CC BY-NC-ND license (<http://creativecommons.org/licenses/by-nc-nd/4.0/>).

1. Introduction

Leiomyomatosis peritonealis disseminata (LPD) is a rare pathology of unknown etiology characterized by the appearance of multiple pelvic and abdominal nodules, which are basically composed of smooth muscle. At present, around 100 cases can be found in literature. We present the first case of a patient who developed disseminated peritoneal leiomyomatosis ten years after a laparoscopic myomectomy that was associated with ascites and lymph nodes enlargement.

2. Case report

A 40-year-old multiparous woman was admitted to our Unit in May 2014 with increasing menorrhagia, pelvic pressure, abdominal pain and a 2-years history of polycythemia. Laboratory evaluation revealed an hemoglobin value of 18.0 g/dL, red blood cells of

$6.15 \times 10^6/\mu\text{L}$ and erythropoietin level of 18 mU/mL. The patient's history included a laparoscopic myomectomy with electrical morcellation performed in 2004 in our Unit and a hysteroscopy carried out for heavy and prolonged menstrual loss 3 months earlier showed no focal lesion with no abnormality on histopathological examination of the endometrial biopsy obtained at the time. There was no history of oral contraceptive use. After checking the clinical notes we found that the patient underwent laparoscopic removal of a single, anterior, pedunculated myoma of 6 cm that was morcellated during removal. On admission in May 2014, a pelvic ultrasound scan showed multiple small uterine fibroids with a dominant posterior intramural fibroid measuring 9 cm in diameter and normal Doppler. Computed tomography scans revealed multiple pelvic tumors closely attached to peritoneum and bowel with heterogeneous enhancement of the masses at contrast-enhanced images. Additionally, ascites and slightly enlarged paraaortic and iliac lymph nodes were found. Standard tumor markers were within normal limits: Carcinoembryonic antigen (CEA) 1,1 ng/ml; Cancer Antigen 125 (CA-125) 20,8 U/ml; Cancer Antigen 15-3 (CA15-3) 22,5 U/ml; carbohydrate antigen 19-9 (CA 19-9) 8,3 U/ml; Alpha-fetoprotein (AFP) 3 IU/ml. The surgical procedure (type of incision, risks, possible complications. . .) was explained by our consultant and informed consent for total abdominal hysterectomy and bilat-

* Corresponding author at: Institute of Obstetrics and Gynaecology, Department of Medical and Surgical Sciences, University of Foggia, Viale Pinto, 71100 Foggia, Italy.

E-mail address: felice.sorrentino@alice.it (F. Sorrentino).

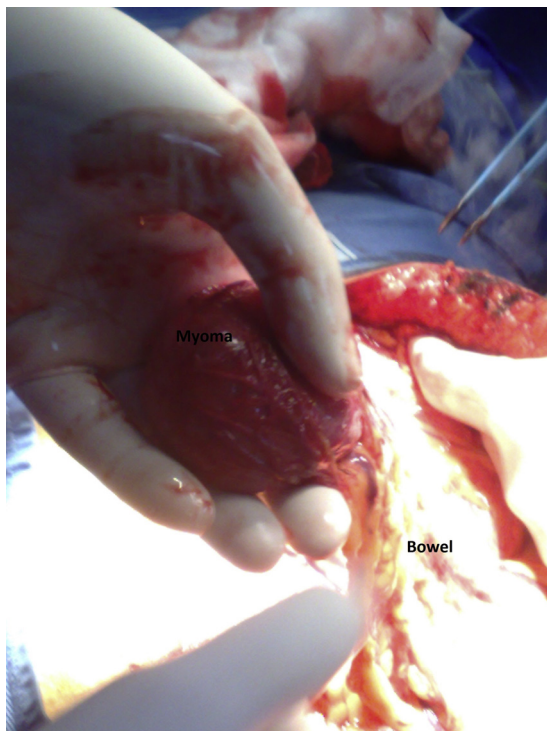


Fig. 1. Myoma attached to the bowel.

eral salpingoopherectomy was signed by the patient taking into consideration she had completed her family. Laparotomy with midline incision revealed a uterus enlarged with fibroids strictly adherent to the urinary bladder, greater omentum, and sigmoid colon. An ascitic fluid sample for examination was collected. Multiple tumors of different size were found attached to the peritoneum, omentum and bowel (size between 0,5 and 3 cm) (Fig. 1). The omental and the bladder adhesions were released. The nodules were dissected and removed using a Ligasure Atlas. Parasitic myomas were removed just opening a window in the peritoneum and gently pulling out the pathology by using a grasping forceps. The peritoneal window was closed using Vicryl 2-0. On the bowel, when necessary, stiches on the serosa were applied. Hemostasis was achieved using bipolar or stitches (Vicryl 2-0 or 3-0). The histopathologic examination was consistent with leiomyomatosis peritonealis disseminata. There was any cytological evidence of malignance after ascitic fluid sample examination. No intraoperative or postoperative complications were reported and patient was discharged 3 days after surgery. Two months after surgery, the patient was asymptomatic with a hemoglobin of 13.9 g/dL and erythropoietin level less than 4.0 mU/mL.

3. Discussion

The case of a patient who developed LPD several years after a laparoscopic myomectomy when electrical morcellation was carried out is timely because of the ongoing concerns about morcellation. LPD is a rare condition first described in 1952, characterized by the presence of multiple smooth muscle nodules throughout the peritoneal cavity which appears grossly malignant but histologically benign [1,2]. Some rare cases of malignant transformation have been reported especially in postmenopausal women [3]. The etiology is unknown, but it is thought to originate from metaplasia of submesothelial, multi-potential mesenchymal cells [4]. An association with high levels of exogenous and endogenous female gonadal steroids has been found [5]. However, in some

cases a link between dissemination of uterine tissue during electrical morcellation and development of LPD has been proposed [6,7]. Probably during electrical morcellation pieces of specimens are dispersed throughout the abdominal cavity; then they become implanted into normal tissue and give rise to development of fibrotic nodules. Laparoscopic in-bag morcellation of fibroids or uterus has the potential to prevent the rare morcellation-related complications typical of “open” morcellation in abdominal cavity [8–10]. Patients may present mostly non-specific symptoms, such as irregular, heavy uterine bleeding, pain or discomfort, gastrointestinal bleeding and peritonitis (following erosion of LPD implants in the bowel wall). In our case a 2-year history of polycythemia was also described. The association between large uterine myomas and secondary polycythemia has been previously reported but the mechanism is not clear (erythropoietin overproduction is one of the postulated theories) [11]. Final diagnosis is based on histological examination. The relationship with myoma morcellation remains unclear. However, our case highlights the need to accurately remove all morcellated fragments of myomas during procedure and the length of time that elapsed between the laparoscopic myomectomy performed in 2004 and the patient’s presentation with disseminated leiomyomatosis: to the best of our knowledge this is longer than in previous studies. Also, the ascites with lymph node enlargement which can raise suspicion of malignancy are worth emphasizing (the association of LPD with ascites is very rare and its presence does not exclude LPD from the differentials when abdominal and peritoneal masses are found). Obviously, a laparoscopic surgery could also have been performed but we preferred to start with a laparotomy for the particular features of the case.

Conflicts of interest

The authors have no conflicts of interest to declare. This study was not supported by any person or institution.

Funding

This study was not supported by any person or institution.

Ethical approval

None.

Consent

Written informed consent was obtained from the patient for publication of this case report.

Authors contribution

Luigi Nappi, Felice Sorrentino, Ida Barone: study concept and design. Felice Sorrentino, Stefano Angioni, Alessandro Pontis: acquisition of data. Felice Sorrentino, Stefano Angioni, Luigi Nappi: drafting of the manuscript. Pantaleo Greco, Stefano Angioni: critical revision of the manuscript for important intellectual content.

Guarantor

Felice Sorrentino

References

- [1] J.R. Willson, A.R. Peale, Multiple peritoneal leiomyomas associated with a granulosa cell tumor of the ovary, *Am. J. Obstet. Gynecol.* 64 (1952) 204–208.

- [2] T.D. Poulsen, Leiomyomatosis peritonealis disseminata, *Ann. Chir. Gynaecol.* 77 (1988) 41–44.
- [3] P. Sharma, K.U. Chaturvedi, R. Gupta, S. Nigam, Leiomyomatosis peritonealis disseminata with malignant change in a post-menopausal woman, *Gynecol. Oncol.* 95 (2004) 742–745.
- [4] J. Heinig, A. Neff, U. Cirkel, W. Klockenbusch, Recurrent leiomyomatosis peritonealis disseminata after hysterectomy and bilateral salpingo-oophorectomy during combined hormone replacement therapy, *Eur. J. Obstet. Gynecol. Reprod. Biol.* 111 (2003) 216–218.
- [5] M.F. Goldberg, W.G. Hurt, W.J. Frable, Leiomyomatosis peritonealis disseminata: report of a case and review of the literature, *Obstet. Gynecol.* 49 (1977) 46–52.
- [6] A. Ostrzenski, Uterine leiomyoma particle growing in an abdominal-wall incision after laparoscopic retrieval, *Obstet. Gynecol.* 89 (1997) 853–854.
- [7] P.G. Paul, A.K. Koshy, Multiple peritoneal parasitic myomas after laparoscopic myomectomy and morcellation, *Fertil. Steril.* 85 (2006) 492–493.
- [8] H. Brölmann, V. Tanos, G. Grimbizis, T. Ind, K. Philips, T. Van de Bosch, et al., Options on fibroid morcellation: a literature review, *Gynecol. Surg.* 12 (1) (2015) 3–15.
- [9] S. Angioni, A. Pontis, A. Multinu, G.B. Melis, Safe endobag morcellation in a single port subtotal hysterectomy, *Minim. Invasive Ther. Allied Technol.* 25 (2) (2016) 113–116.
- [10] H. Krentel, R.L. De Wilde, Complication in laparoscopic supracervical hysterectomy (LASH), especially morcellation related, *Best Pract. Res. Clin. Obstet. Gynaecol.* 15 (2015), S1521–S6934, (00202–3).
- [11] Y. Yokoyama, A. Shinohara, M. Hirokawa, N. Maeda, Erythrocytosis due to an erythropoietin-producing large uterine myoma, *Gynecol. Obstet. Invest.* 56 (2003) 179–183.

Open Access

This article is published Open Access at [sciencedirect.com](https://www.sciencedirect.com). It is distributed under the [IJSCR Supplemental terms and conditions](#), which permits unrestricted non commercial use, distribution, and reproduction in any medium, provided the original authors and source are credited.