

Primary yolk sac tumour of the urinary bladder: A case report and review of the literature

WING HO MUI¹, KA CHAI LEE¹, SIN CHUEN CHIU², CHUN YIN PANG², SAU KWAN CHU³,
CHI WAI MAN³, CHI SING WONG¹, WING KIN SZE¹ and YUK TUNG¹

Departments of ¹Clinical Oncology and ²Pathology, Tuen Mun Hospital, Tuen Mun, Hong Kong SAR;
³Department of Surgery, Division of Urology, Tuen Mun Hospital, Tuen Mun, Hong Kong SAR, P.R. China

Received April 10, 2013; Accepted October 22, 2013

DOI: 10.3892/ol.2013.1670

Abstract. We present a case of rare primary yolk sac tumour of the urinary bladder in adulthood. A 31-year-old female patient presented with a history of chronic ketamine abuse, which has not previously been shown to be associated with malignancy development. The final diagnosis was established only after radical cystectomy. A computed tomography (CT) scan showed paraaortic lymph node metastasis. The patient was treated with systemic chemotherapy. A review of the literature revealed that surgical excision and cisplatin-based chemotherapy remain to be the standard of care for extragonadal yolk sac tumours.

Introduction

There are five types of germ cell tumours according to clinical presentation, pathology and cytogenetics. Type I tumours (teratomas and yolk sac tumours) are more frequent in extragonadal sites than in the gonads; whereas type II tumours (seminomas and non-seminomas) occur mainly in the gonads (1) Primary urinary bladder germ cell tumours are exceedingly rare. The current report presents a case of primary yolk sac tumour of the urinary bladder in a 31-year-old female ex-ketamine abuser. The diagnosis of a yolk sac tumour at this rare site can be difficult and biopsy alone is not reliable. No previous studies have reported a correlation between chronic ketamine abuse and urinary bladder malignancy development. Informed consent was obtained from the patient.

Case report

In 2007, a 26-year-old female presented to the Department of Urology of the Tuen Mun Hospital (Hong Kong, China) with bilateral hydronephrosis. Since 2000, the patient had been consuming 8-10 ketamine tablets daily from illicit sources. Cystoscopy revealed cystitis and a biopsy showed florid reactive changes in the urinary bladder associated with erosion involving the urothelium, which underwent extensive intestinal metaplastic changes. The patient defaulted follow-up examinations.

In January 2012, the patient presented again with gross haematuria. Cystoscopy identified a 4-cm whitish mass at the dome of the urinary bladder, with pathological features indicative of adenocarcinoma (Fig. 1). A computed tomography (CT) scan of the abdomen was performed on February 3, 2012, which demonstrated masses within the urinary bladder (Fig. 2). A transurethral resection of the bladder tumours was subsequently performed on January 31, 2012. Pathological examination showed a muscle-invasive, poorly-differentiated carcinoma with a clear cell component. The patient underwent a radical cystectomy and T-pouch orthotopic substitution cystoplasty on February 21, 2012. Two similar 5-cm tumours were present, with various histological morphologies in different areas, featuring reticular, glandular, papillary, microcystic, solid and hepatoid patterns (Fig. 3). The tumour cells showed immunohistochemical reactivity for antibodies against MNF116, α -fetoprotein (α FP) and Sal-like protein 4 (Fig. 4), but not against EMA, HCG, placental alkaline phosphatase, CD30 and octamer-binding transcription factor 3/4. The final pathological diagnosis was of a yolk sac tumour. A CT scan of the abdomen and pelvis on March 9, 2012, demonstrated several enlarged paraaortic lymph nodes of ≤ 1.5 cm in size (Fig. 5). No sites of suspicious ovarian primary or other disease involvement were identified. An examination performed by a gynaecologist did not reveal a primary gynaecological site of disease.

The serum α FP level was found to be raised (1,028 ng/ml) on March 13, 2012, but fell to 45.9 ng/ml on April 17, 2012, prior to undergoing chemotherapy. In view of the impaired renal function (48.9 ml/min creatinine clearance, according to the Cockcroft-Gault formula), the patient was treated with the combination chemotherapy JEB regimen (day 1,

Correspondence to: Dr Wing Ho Mui, Department of Clinical Oncology, Tuen Mun Hospital, Tuen Mun, Hong Kong SAR, P.R. China

E-mail: whmui@yahoo.com.hk

Key words: yolk sac tumour, urinary bladder, ketamine abuse

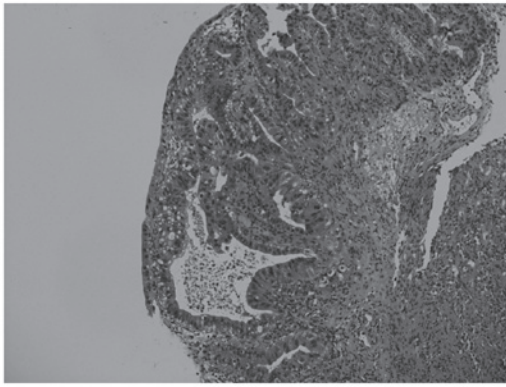


Figure 1. Pathological features indicative of adenocarcinoma (H&E; magnification, x100).

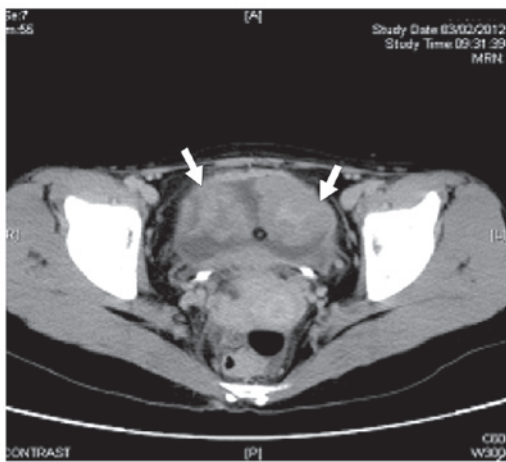


Figure 2. Computed tomography (CT) scan of the abdomen. Arrows indicate urinary bladder masses.

area under curve 5 mg/ml/min carboplatin, intravenously; days 1-5, 100 mg/m² etoposide, intravenously; days 1, 8 and 15, 30 mg bleomycin, intravenously; and the regimen was repeated every 21 days). Two cycles of chemotherapy were administered between April and May 2012. The first cycle of chemotherapy was complicated by grade 3 mucositis and neutropenic sepsis. Moreover, the second cycle was complicated by appendicitis with intra-abdominal abscess formation requiring laparotomy, intensive care and prolonged post-operative management. It was then decided to terminate the chemotherapy. The patient was put on close clinical surveillance, including regular serum tumour marker analysis and CT scan monitoring. The final CT scan, on July 23, 2012, showed no interval change of the paraaortic lymph nodes. The patient's nadir serum α FP level following chemotherapy was 14.1 ng/ml on August 9, 2012.

Discussion

Primary germ cell tumours of the urinary bladder are extremely rare. In the present review of the literature, <10 cases had been previously reported (2-7). To the best of our knowledge, the current case is the first reported primary yolk sac tumour of the urinary bladder in adulthood.

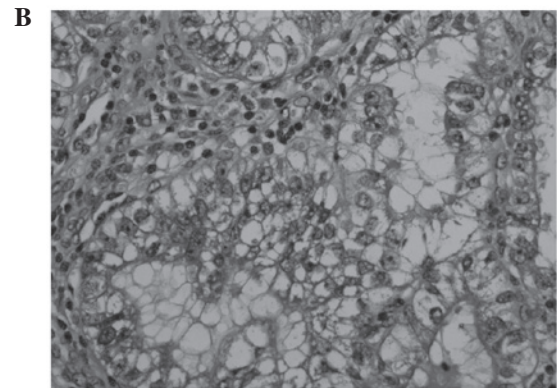
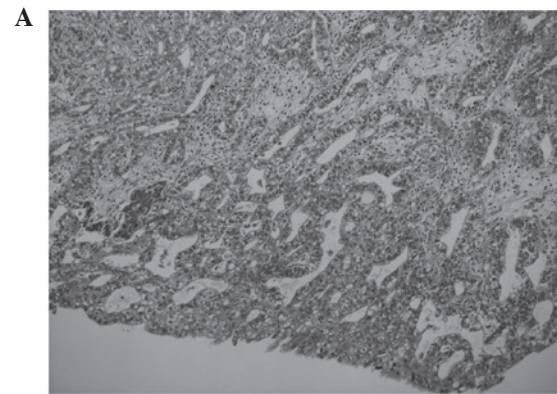


Figure 3. (A) Glandular area (H&E; magnification, x100). (B) Cytoplasmic hyaline globules in tumour cells (H&E; magnification, x400). (C) Hepatoid and solid area (H&E; magnification, x100).

The hypotheses for the development of extragonadal germ cell tumours include the following: i) Failure of the primitive germ cells to complete the normal migration along the urogenital ridges; ii) germ cell tumours undergo reverse migration; iii) germ cell tumours are the metastatic deposits from occult gonadal primaries; and iv) germ cell tumours result from the germ cells distributed to other organs physiologically for function (1,8,9).

The accurate pathological diagnosis of germ cell tumours and the distinction from non-germ cell tumours is critical, as the majority of cases of germ cell tumours are potentially curable, particularly in young patients. Diagnosing a yolk sac tumour may be difficult since a yolk sac tumour may assume a variety of architectural patterns, including microcystic, solid, myxomatous, papillary, polyvesicular vitelline, alveolar, glandular, hepatoid and intestinal (10,11). These may explain

Table I. Immunohistochemical study of germ cell tumours.

Type of germ cell tumour	Reactivity
Seminoma/dysgerminoma	PLAP, c-kit and Oct3/4
Spermatocytic seminoma	c-kit and PLAP
Embryonal carcinoma	MNF116 (cytokeratin), CD30, Oct3/4 and SALL4
Yolk sac tumour	α FP and SALL4
Choriocarcinoma	MNF116 (cytokeratin)

PLAP, placental alkaline phosphatase; Oct3/4, octamer-binding transcription factor 3/4; α FP, α -fetoprotein; SALL4, Sal-like protein 4.

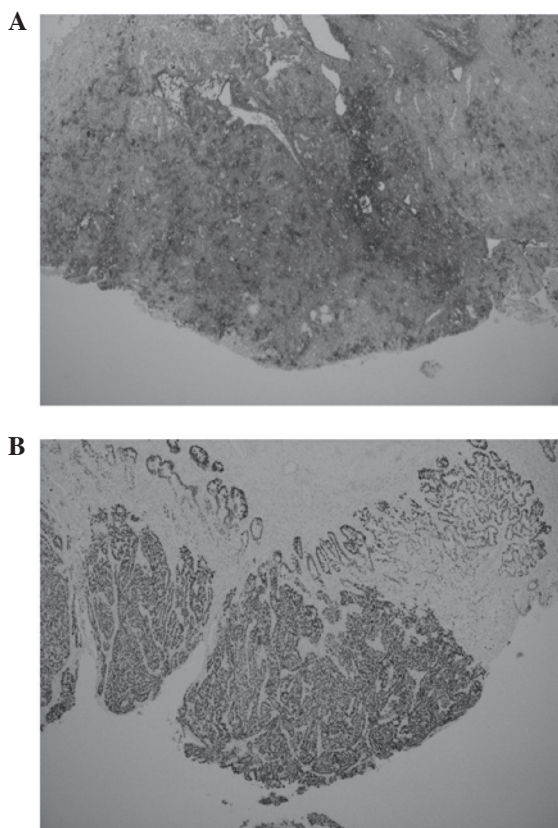


Figure 4. (A) Patchy and moderate reactivity to α FP (magnification, x40). (B) Diffuse and strong reactivity to SALL4 (magnification, x40). α FP, α -fetoprotein; SALL4, Sal-like protein 4.

the diagnoses of adenocarcinoma and invasive carcinoma in the present patient's previous pathological examinations. The presence of the particularly characteristic histological Schiller-Duval body, which consists of arrays of neoplastic cells surrounding a central vessel in a glomeruloid appearance, aided the diagnosis (12-14). Beside classical histological features, immunohistochemical study is essential for determining the correct diagnosis. This is based on the relatively specific immunohistochemical profiles carried by the various types of germ cell tumour (Table I) (12,14-18).

The patient's medical history in 2007 identified a dysplastic process occurring in the urinary bladder. However, in the present review of the literature, the correlation between

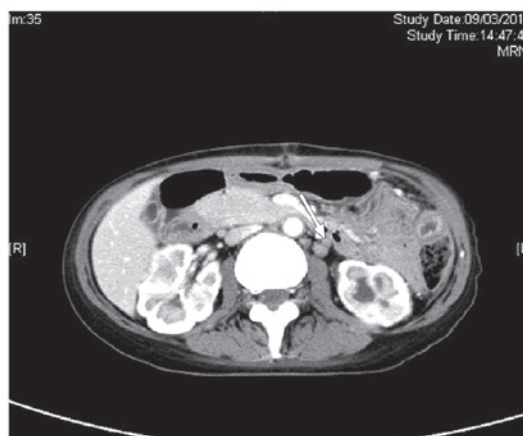


Figure 5. Computed tomography (CT) scan of the abdomen and pelvis. Arrow indicates enlarged paraortic lymph nodes.

ketamine abuse and the formation of a urinary bladder malignancy was shown to have not previously been documented. The chronic recreational use of ketamine and its associated urinary system issues has become a global issue (19-21). The new medical entity 'ketamine-induced ulcerative cystitis' originated from a publication by Shahani *et al* (21) in 2007. Common symptoms include frequent urination, urge incontinence and painful haematuria. The method of production and composition of illicit ketamine is unclear, and the chemicals and metabolites responsible for the pathogenesis are not well known. Cystoscopic observations may reveal features of cystitis and ulceration, characterised by granulation tissue formation and fibrosis in the epithelium and lamina propria (21). Although there is eosinophilic infiltration, the overall pathology of chemical cystitis is distinct from that of eosinophilic cystitis, which has been reported to be associated with transitional cell carcinoma (22).

Despite their rarity, extragonadal yolk sac tumours mainly affect children and young females (9-11,13). The mediastinum and retroperitoneum are the most common extraovarian primary sites. Less common sites may include the omentum, vagina and brain (10-12,17). These tumours are highly aggressive, harbouring the tendency for early lymphatic and haematological metastasis to distant sites (11,17). Long-term survival rates, specifically for extragonadal yolk sac tumours, are not well known. The International Germ Cell Cancer Collaborative Group data, determined the 5-year survival rate for mediastinal non-seminoma (i.e. poor risk group) as 48% (23), and a large case series from the German group of extragonadal germ cell tumours showed similar survival rates (8,24,25). Extragonadal germ cell tumours have been managed under the same principle as their primary gonadal counterparts, using treatment comprised of systemic chemotherapy together with local treatment, including surgery and radiotherapy. Adjunct chemotherapy following local surgical treatment is recommended by the majority of studies if the disease is operable upfront; cisplatin-based regimens are widely used (8-11,13,24-27). Regimens, including bleomycin, etoposide and cisplatin (BEP) and vinblastine, ifosfamide and cisplatin (VIP), are the most commonly adopted. In addition, high-dose chemotherapy followed by autologous bone marrow

transplantation is used (8,24,28). To date, the evidence has not been sufficient to determine the optimal chemotherapy duration for extragonadal germ cell tumours, including yolk sac tumours. Four cycles of cisplatin-based combination chemotherapy is the most prevalent treatment regime (8,11,12,24,26,27), and factors taken into account prior to treatment include patient age, performance status, organ function (particularly the lungs and kidneys), histology, serum marker levels, the location of the primary tumour and the sites of the metastases (23,28,29).

In conclusion, the diagnosis of a yolk sac tumour may be challenging in sites of rare occurrence. A high level of clinical suspicion is required, particularly in young patients. Prior to the availability of new therapeutic agents, systemic cisplatin-based chemotherapy remains the standard of care for extragonadal germ cell tumours.

References

- Oosterhuis JW, Stoop H, Honecker F and Looijenga LH: Why human extragonadal germ cell tumours occur in the midline of the body: old concepts, new perspectives. *Int J Androl* 30: 256-263, 2007.
- Kuyumcuoglu U and Kale A: Unusual presentation of a dermoid cyst that derived from the bladder dome presenting as subserosal leiomyoma uteri. *Clin Exp Obstet Gynecol* 35: 309-310, 2008.
- Taylor G, Jordan M, Churchill B and Mancer K: Yolk sac tumor of the bladder. *J Urol* 129: 591-594, 1983.
- Tinkler SD, Roberts JT, Robinson MC and Ramsden PD: Primary choriocarcinoma of the urinary bladder: a case report. *Clin Oncol (R Coll Radiol)* 8: 59-61, 1996.
- Fowler AL, Hall E and Rees G: Choriocarcinoma arising in transitional cell carcinoma of the bladder. *Br J Urol* 70: 333-334, 1992.
- Yokoyama S, Hayashida Y, Nagahama J, Nakayama I, Kashima K and Ogata J: Primary and metaplastic choriocarcinoma of the bladder. A report of two cases. *Acta Cytol* 36: 176-182, 1992.
- Huang HY, Ko SF, Chuang JH, Jeng YM, Sung MT and Chen WJ: Primary yolk sac tumor of the urachus. *Arch Pathol Lab Med* 126: 1106-1109, 2002.
- Bokemeyer C, Hartmann JT, Fossa SD, *et al*: Extragonadal germ cell tumors: relation to testicular neoplasia and management options. *APMIS* 111: 49-63, 2003.
- Ait Benali H, Lalya L, Allaoui M, *et al*: Extragonadal mixed germ cell tumor of the right arm: description of the first case in the literature. *World J Surg Oncol* 10: 69, 2012.
- Furtado LV, Leventaki V, Layfield LJ, Lowichik A, Muntz HR and Pysher TJ: Yolk sac tumor of the thyroid gland: a case report. *Pediatr Dev Pathol* 14: 475-479, 2011.
- Kim SW, Park JH, Lim MC, Park JY, Yoo CW and Park SY: Primary yolk sac tumor of the omentum: a case report and review of the literature. *Arch Gynecol Obstet* 279: 189-192, 2009.
- Pasternack T, Shaco-Levy R, Wiznitzer A and Piura B: Extraovarian pelvic yolk sac tumor: case report and review of published work. *J Obstet Gynaecol Res* 34: 739-744, 2008.
- Dede M, Pabuccu R, Yagci G, Yenen MC, Goktolga U and Gunhan O: Extragonadal yolk sac tumor in pelvic localization. A case report and literature review. *Gynecol Oncol* 92: 989-991, 2004.
- Moran CA, Suster S and Koss MN: Primary germ cell tumors of the mediastinum: III. Yolk sac tumor, embryonal carcinoma, choriocarcinoma and combined nonteratomatous germ cell tumors of the mediastinum - a clinicopathologic and immunohistochemical study of 64 cases. *Cancer* 80: 699-707, 1997.
- Hoei-Hansen CE, Kraggerud SM, Abeler VM, Kaern J, Rajpert-De Meyts E and Lothe RA: Ovarian dysgerminomas are characterised by frequent KIT mutations and abundant expression of pluripotency markers. *Mol Cancer* 6: 12, 2007.
- Cao D, Humphrey PA and Allan RW: SALL4 is a novel sensitive and specific marker for metastatic germ cell tumors, with particular utility in detection of metastatic yolk sac tumors. *Cancer* 115: 2640-2651, 2009.
- Gupta R, Mathur SR, Arora VK and Sharma SG: Cytologic features of extragonadal germ cell tumors: a study of 88 cases with aspiration cytology. *Cancer* 114: 504-511, 2008.
- Wang F, Liu A, Peng Y, *et al*: Diagnostic utility of SALL4 in extragonadal yolk sac tumors: an immunohistochemical study of 59 cases with comparison to placental-like alkaline phosphatase, alpha-fetoprotein and glypican-3. *Am J Surg Pathol* 33: 1529-1539, 2009.
- Venyo A and Benatar B: A Review of the Literature on Ketamine-Abuse-Uropathy. *WebmedCentral Urology* 3: WMC003048, 2012.
- Chu PS, Kwok SC, Lam KM, *et al*: 'Street ketamine'-associated bladder dysfunction: a report of ten cases. *Hong Kong Med J* 13: 311-313, 2007.
- Shahani R, Streutker C, Dickson B and Stewart RJ: Ketamine associated ulcerative cystitis: a new clinical entity. *Urology* 69: 810-812, 2007.
- Itano NM and Malek RS: Eosinophil cystitis in adults. *J Urol* 165: 805-807, 2001.
- No authors listed: International Germ Cell Consensus Classification: a prognostic factor-based staging system for metastatic germ cell cancers. International Germ Cell Cancer Collaborative Group. *J Clin Oncol* 15: 594-603, 1997.
- Bokemeyer C, Nichols CR, Droz JP, *et al*: Extragonadal germ cell tumors of the mediastinum and retroperitoneum: results from an international analysis. *J Clin Oncol* 20: 1864-1873, 2002.
- De Corti F, Sarnacki S, Pattec C, *et al*: Prognosis of malignant sacrococcygeal germ cell tumours according to their natural history and surgical management. *Surg Oncol* 21: e31-e37, 2012.
- Pliarchopoulou K and Pectasides D: First-line chemotherapy of non-seminomatous germ cell tumors (NSGCTs). *Cancer Treat Rev* 35: 563-569, 2009.
- de La Motte Rouge T, Pautier P, Duvillard P, *et al*: Survival and reproductive function of 52 women treated with surgery and bleomycin, etoposide, cisplatin (BEP) chemotherapy for ovarian yolk sac tumor. *Ann Oncol* 19: 1435-1441, 2008.
- Riese MJ and Vaughn DJ: Chemotherapy for patients with poor prognosis germ cell tumors. *World J Urol* 27: 471-476, 2009.
- Hartmann JT, Nichols CR, Droz JP, *et al*: Prognostic variables for response and outcome in patients with extragonadal germ-cell tumors. *Ann Oncol* 13: 1017-1028, 2002.