

Primary facial demodicosis as a health problem and aesthetic challenge: A case report

Renata Przydatek-Tyrajka PhD Student^{1,2}  | Aleksandra Sędzikowska PhD³  |
Katarzyna Bartosik PhD Habilitated² 

¹Reno-Med, Non-Public Health Care Centre, Warsaw, Poland

²Chair and Department of Biology and Parasitology, Medical University of Lublin, Lublin, Poland

³Department of General Biology and Parasitology, Medical University of Warsaw, Warsaw, Poland

Correspondence

Aleksandra Sędzikowska, Department of General Biology and Parasitology, Medical University of Warsaw, Chałubińskiego 5, 02-004 Warsaw, Poland.
Email: aleksandra.sedzikowska@wum.edu.pl

Abstract

Colonization of skin by *Demodex* mites developing as a single facial lesion with a limited range is diagnosed relatively rarely. The presence of this type of skin lesions may hinder and thus delay the diagnostic process and application of appropriate treatment. The persistent cosmetic defect on the face is extremely onerous/embarrassing to the patient and impedes normal functioning. Describe a case of atypical presentation of primary facial demodicosis and its successful treatment. We present a case of a 38-year-old patient who consulted an aesthetic medicine doctor about a skin lesion, that is, erythematous-papular lesion with single pustules persisting for more than half a year around the right eye corner and below the lower eyelid. Previous topical antibiotic treatment has proved ineffective. Diagnosis was targeted at detection of *Demodex* spp. invasion, which yielded a positive result. Targeted therapy with 1% topical ivermectin was implemented. Complete resolution of the skin lesions was observed after 8.5 weeks of the treatment with no further recurrence. In the case of limited scaly erythematous-papular skin lesions with single pustules, *Demodex* mites should be considered as an etiological factor or one of the factors in the case of a mixed-etiology lesion. A delayed diagnosis of visible lesions on facial skin has a negative impact on patient's well-being and normal functioning. As diagnosis of primary demodicosis is underestimated, knowledge about this dermatosis and its clinical manifestations should be disseminated among cosmetologists and doctors of various specialties.

KEYWORDS

cosmetic dermatology, *Demodex*, esthetics, eyelid, facial redness, primary facial demodicosis

1 | INTRODUCTION

Demodicosis is a parasitic skin disease with medical and veterinary importance caused by the *Demodex* mites (arachnid from the Acarina order). Two *Demodex* species have been identified in humans:

Demodex folliculorum and *Demodex brevis*. They colonize the hair follicles and sebaceous glands in the skin.¹ The mites mainly feed on epidermal cells and sebum components²; hence, they invade areas of skin that are rich in sebaceous glands, that is, the face, cheeks, forehead, and chin, and Meibomian glands in the eyelids. The presence

This is an open access article under the terms of the Creative Commons Attribution-NonCommercial-NoDerivs License, which permits use and distribution in any medium, provided the original work is properly cited, the use is non-commercial and no modifications or adaptations are made.

© 2020 The Authors. *Journal of Cosmetic Dermatology* published by Wiley Periodicals LLC

of *Demodex* may be asymptomatic.³ In symptomatic invasion of *Demodex* spp., skin dryness, redness, exfoliation, rash, and even *erythema* may develop.⁴⁻⁶ Ocular demodicosis is manifested by inflammation of the eyelid margin, dysfunction of the Meibomian glands, chalazion, and *blepharitis*-induced complications of the ocular adnexa, lacrimal film, and eye surface.⁷⁻¹¹ The most common symptoms reported by patients include pruritus, redness of the eyelids, and watery eyes.¹²

2 | PATIENTS/METHODS

A 38-year-old patient consulted an aesthetic medicine doctor about a skin lesion in the right eye area, which had developed more than half a year before. The patient reported subsequent appearance of a small skin lesion near the left eye. During the examination, a slightly scaly erythematous-papular skin lesion with single pustules around the corner of the right eye and under the lower eyelid was noted in the patient (Figure 1A). A similar but small lesion was found at the corner of the left eye (Figure 1B). Both lesions were periodically itchy and caused a burning sensation. The patient was also diagnosed with nasal ala telangiectasia. The patient's history revealed inhalant allergies, that is, seasonal rhinitis and conjunctivitis.

Two months before the appearance of the skin lesions, the patient had a stye of the right eyelid, which resolved spontaneously. In the period between the appearance of the first skin symptoms and the appointment with the aesthetic medicine doctor, the patient was consulted once by a dermatologist and once by a general practitioner. During this time, ointments containing dexamethasone, neomycin, and polymyxin B were applied both into the conjunctival sac and on the affected skin around the right eye as well as a skin ointment containing betamethasone, clotrimazole, and gentamicin. The application of the drugs resulted in only partial improvement, and the lesions recurred after discontinuation of the treatment.

The visible skin lesions on the face negatively influenced the self-esteem of the patient and hindered his professional contacts.

The patient was examined for the presence of *Demodex* mites. The examination consisted in squeezing out the contents of the sebaceous glands, sampling epidermis scrapings with sterile surgical blades, and collecting several eyelashes and several eyebrow hairs with the use of laboratory tweezers onto glass slides. The samples were then fixed with Hoyer mounting fluid¹³ and examined under a low power microscope. The diagnostic procedures were approved by the local Bioethics Committee at the Medical University of Lublin as part of a scientific project "Invasion of *Demodex* spp. in the practice of aesthetic medicine doctor" (approval no. KE-0254/122/2018). Patient permission was obtained as well.

The following results were obtained:

- Scrapings from skin lesions in the right eye area (Figure 2A)- microscopic view: 13 adults, 1 nymph, 1 larva and 2 eggs of *Demodex* mites
- Scrapings from and around the eyebrow area (Figure 2B)- microscopic view: 13 adults, 1 larva and 5 eggs of *Demodex* mites
- Samples of eyelashes—4 adults *Demodex* mites
- Skin scrapings around nasolabial folds—5 adults and 4 eggs of *Demodex* mites

Based on patient's medical history, clinical manifestation, result of microscopic analysis of the sampled material, and absence of preexisting or concurrent inflammatory dermatoses, primary facial demodicosis were diagnosed. Targeted acaricidal topical treatment with ivermectin 1% cream was introduced. The patient was also consulted by a dermatologist, who suggested that the skin lesion in the eye area might indicate development of acne rosacea. Shower gel and hair shampoo with tea tree oil and aloe vera were recommended for daily hygiene. After ophthalmologic consultation, wipes for eyelid skin hygiene and a prescription ointment with 2% metronidazole for the eyelid margin were recommended. Additionally, application of artificial tears in drops and application of an ointment with vitamin A (250 IU/g) into the conjunctival sac were prescribed.

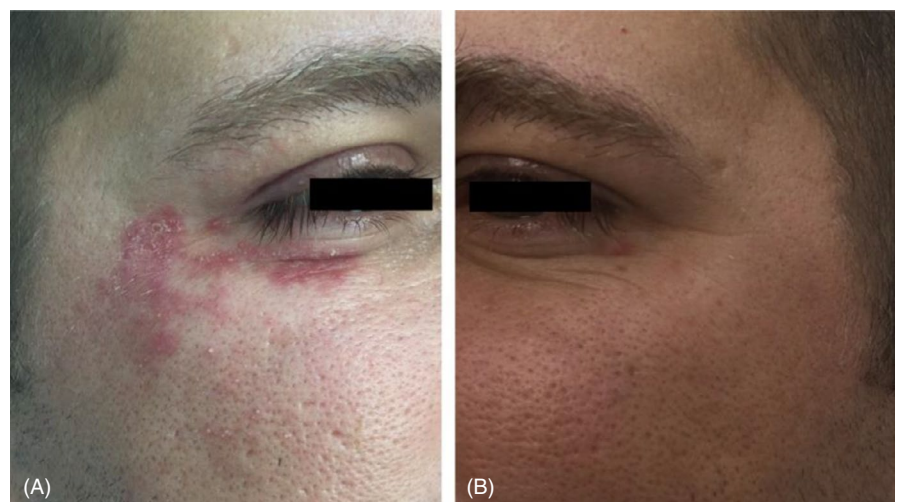


FIGURE 1 Primary facial demodicosis near the corner of the right eye of a 38-year-old male patient (A), small lesion near the corner of the left eye (B) before treatment

A follow-up visit was recommended after five and a half weeks of the treatment. The skin lesions in the right eye area observed previously were less severe (Figure 3A) and those near the left eye subsided completely (Figure 3B). The patient did not experience any ocular symptoms. During the follow-up visit, material was sampled for analysis, in the same way as during the first visit. No developmental stages of *Demodex* spp. (adults, nymphs, larvae, and eggs) were found in the samples from the eyebrows, eyelashes, and facial skin. The patient was recommended to continue the treatment and a follow-up visit in 3 weeks.

During the second follow-up visit (8.5 weeks from the beginning of the treatment), there was almost complete resolution of the skin lesions in the right eye area (Figure 4A). The skin lesions near the left eye did not recur (Figure 4B). During the visit, material for microscopic examination was collected in the same way as previously. One adult mite was detected in scrapings from the glabella. The results of microscopic analysis of the other samples were negative (no *Demodex* mites or their eggs).

3 | DISCUSSION

Atypical skin lesions reported by patients can sometimes be caused by *Demodex* spp. Lesions caused by the mite may occur not only in

the eye area, as in the case described above, but also around the mouth¹⁴ or on hand palms.¹⁵

The literature describes cases of patients who consulted dermatologists about skin lesions and used various treatments with different groups of drugs, but none of them brought the expected results.¹⁶ This situation is difficult both for the doctor who is trying to prescribe more effective drugs and for the patient who expects visible improvement.

Facial redness (erythema) can be caused by rosacea, demodicosis, dermatomyositis, lupus erythematosus, allergic contact dermatitis, or drug-induced erythema.¹⁷ Since there are many diseases that can cause facial lesions, it is important to identify their underlying cause properly and apply appropriate treatment with a greater chance to be effective. One of rare dermatosis connected to facial skin is lupus miliaris disseminatus faciei (LMDF). It is chronic granulomatous inflammatory dermatosis characterized by papular eruption involving the central face, typically on and around the eyelids.¹⁸ LMDF can spontaneously resolve, but often disfiguring scars can remain.¹⁹ The etiopathogenesis of this condition remains unknown. The role of *Demodex folliculorum* as the causative organism was speculated, but this association has not been confirmed. In contrast to demodicosis, in LMDF pustules, and telangiectasia are absent.²⁰ As suggested by Hsu et al, the differential diagnosis of recurrent or refractory acne rosacea or facial skin lesions should include consideration of a possible presence of *Demodex* mites.¹⁴

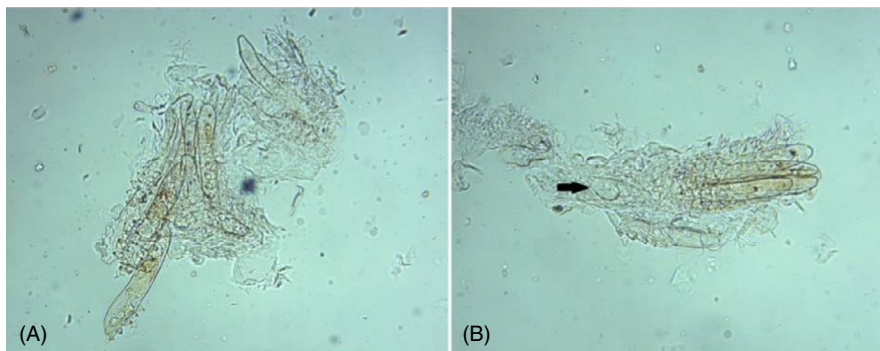
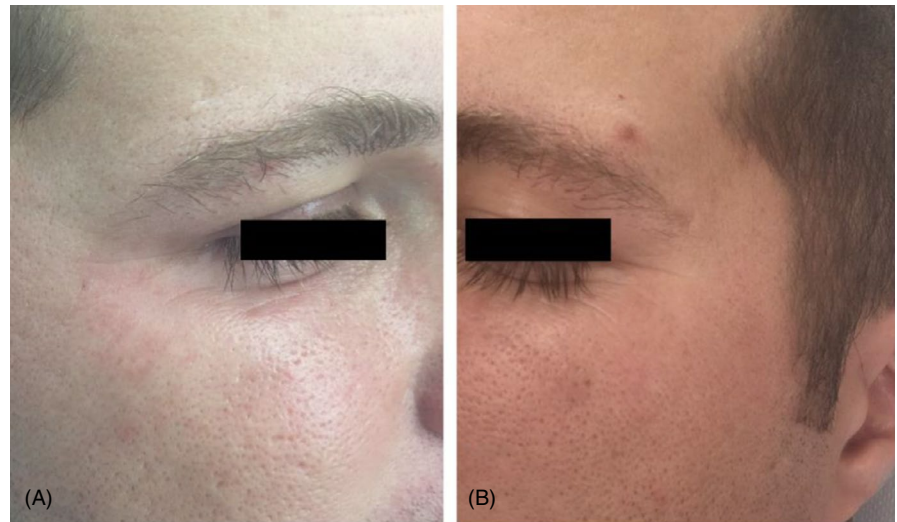


FIGURE 2 Microscopic image of *Demodex* mites.; there are ten adults *D. folliculorum* from the skin lesion (A), eight adults and two eggs of *D. folliculorum* (arrow) from the eyebrow area (B). Original magnification 100×

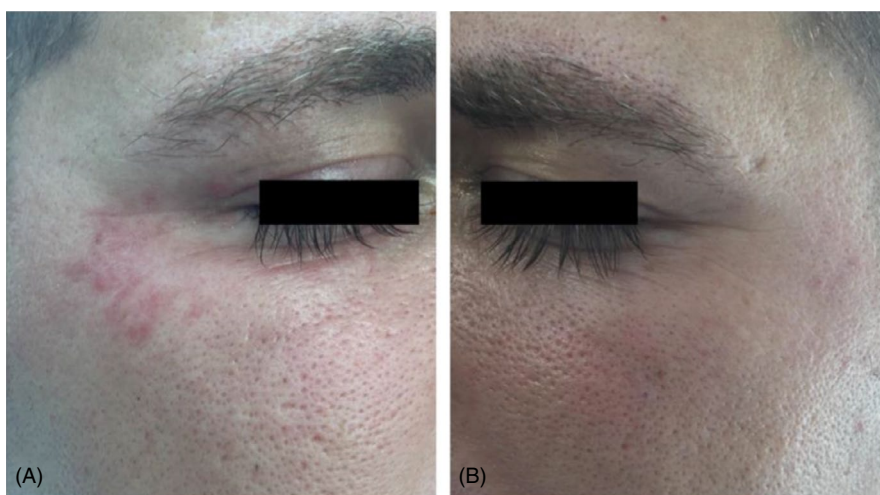

FIGURE 3 Gradual resolution of skin lesions observed previously around the right eye corner in a 38-year-old male patient (A); complete resolution of the skin lesion in the left eye area (B) after the 5.5-wk acaricidal treatment with ivermectin 1% cream

FIGURE 4 Resolution of skin lesions observed previously in a 38-year-old male patient around the right eye corner (A) and around the left eye corner (B) after the 8.5-wk treatment with ivermectin 1% cream



Demodicosis can be manifested by the presence of permanent or recurrent lesions. Noy et al described a patient with a recurrent itchy facial rash.²¹ Topical treatment of the patient with steroids, calcineurin inhibitors, systemic antibiotics, or antihistamines yielded poor results. The lesions resolved within a few weeks only after detection of numerous *Demodex* spp. mites and introduction of local ivermectin treatment, and no recurrence was observed. Similarly, in the case of the patient described in the present report, the lack of early diagnosis of demodicosis delayed the correct treatment and exposed the patient to long-lasting discomfort, reduced self-esteem, and social isolation. Prolonged visible dermatoses have a destructive effect on the patients' psyche and their personal and professional life.²²

Diagnosing non-specific cases of facial demodicosis can be difficult due to the very different clinical pictures in individual patients. Therefore, such case reports may be a clue for doctors for recognition of the cause of lesions in patients. To date, no standard for demodicosis treatment has been established.²³ The facial skin lesions described in this case only disappeared when ivermectin was included in the treatment. By the time of publication, the patient had not reported recurrent lesions or any new foci of demodicosis. In the present case, *Demodex* mites were detected in the patient's lesions. They were present in all samples, including the eyelashes, eyebrows, and facial scrapings. A diagnosis of demodicosis can be made when more than five mites was found in a low power field, more than two mites from five pustules by superficial needle-scraping,²⁴ more than 11 mites/cm² by thumb-nail-squeezing method,²⁵ or by two consecutive standardized skin surface biopsy.²⁶

4 | CONCLUSION

Probably, a sudden and significant increase in the population of *Demodex* mites may induce a local reaction of the organism of a various manifestations. Therefore, the knowledge of the varied


clinical picture, diagnostics, and treatment of demodicosis should be disseminated.

CONFLICT OF INTEREST

The authors have no conflicts of interest to declare.

ORCID

Renata Przydatek-Tyrajka  <https://orcid.org/0000-0002-5697-4037>

Aleksandra Sędzikowska  <https://orcid.org/0000-0003-1721-5676>

Katarzyna Bartosik  <https://orcid.org/0000-0002-4527-9012>

REFERENCES

- English FP, Nutting WB. Demodicosis of ophthalmic concern. *Am J Ophthalmol.* 1981;91(3):362-372.
- Desch C, Nutting WB. *Demodex folliculorum* (Simons) and *D brevis* Akbulatova of man: redescription and reevaluation. *J Parasitol.* 1972;58:169-177.
- Wesolowska M, Knysz B, Reich A, et al. Prevalence of *Demodex* spp. in eyelash follicles in different populations. *Arch Med Sci.* 2014;10(2):319-324.
- Akilov OE, Butov YS, Mumcuoglu KY. A clinico-pathological approach to the classification of human demodicosis. *J Dtsch Dermatol Ges.* 2005;3(8):607-614.
- Hsu CK, Zink A, Wei KJ, Dzika E, Plewig G, Chen W. Primary human demodicosis. A disease sui generis. *Hautarzt.* 2015;66:189-194.
- Luebbers HT, Lanzer M, Graetz KW, Kruse AL. Demodicidosis: an uncommon erythema after crano-maxillofacial surgery. *Br J Oral Maxillofac Surg.* 2013;51(8):e267-e268.
- Fromstein SR, Harthan JS, Patel J, Opitz DL. *Demodex* blepharitis: clinical perspectives. *Clin Optom (Auckl).* 2018;10:57-63.
- Sędzikowska A, Osęka M, Skopiński P. The impact of age, sex, blepharitis, rosacea and rheumatoid arthritis on *Demodex* mite infection. *Arch Med Sci.* 2018;14(2):353-356.
- Sarac G, Cankaya C, Ozcan KN, Cenk H, Kapicioglu YK. Increased frequency of *Demodex* blepharitis in rosacea and facial demodicosis patients. *J Cosmet Dermatol.* 2019;19(5):1260-1265.
- Tarkowski W, Owczyńska M, Błaszczuk-Tyszka A, Młocicki D. *Demodex* mites as potential etiological factor in chalazion- a study in Poland. *Acta Parasitol.* 2015;60(4):777-783.

11. Zhang XB, Ding YH, He W. The association between *Demodex* infestation and ocular surface manifestations in Meibomian gland dysfunction. *Int J Ophthalmol*. 2018;11(4):589-592.
12. Sędzikowska A, Osęka M, Grytner-Zięcina B. Ocular symptoms reported by patients infested with *Demodex* mites. *Acta Parasitol*. 2016;61(4):808-814.
13. Cielecka D, Salamatin R, Garbacewicz A. Usage of the Hoyer's medium for diagnostics and morphological studies of some parasites. *Wiad Parazytol*. 2009;55(3):265-270.
14. Hsu CK, Hsu MM, Lee JY. Demodicosis: a clinicopathological study. *J Am Acad Dermatol*. 2009;60(3):453-462.
15. Wesolowska M, Baran W, Szepietowski J, Hirschberg L, Jankowski S. Demodicidosis in humans as a current problem in dermatology. *Wiad Parazytol*. 2005;51(3):253-256.
16. Jorge MFS, Miguel LMZ, Braghiroli CS, Schmitt JV. Demodicosis as treatment complication of amicrobial pustulosis of the folds. *An Bras Dermatol*. 2018;93(4):566-569.
17. Dessinioti C, Antoniou C. The, "red face": Not always rosacea. *Clin Dermatol*. 2017;35(2):201-206.
18. Toda-Brito H, Aranha JMP, Tavares ES. Lupus miliaris disseminatus faciei. *An Bras Dermatol*. 2017;92(6):851-853.
19. Ma D, Li Q, Jin D, Sun M, Nie X. A case of lupus miliaris disseminatus faciei that was successfully treated with 595 nm pulsed-dye laser combined with drugs. *Dermatol Ther*. 2020;33:e13373.
20. van de Scheur MR, van der Waal RI, Starink TM. Lupus miliaris disseminatus faciei: a distinctive rosacea-like syndrome and not a granulomatous form of rosacea. *Dermatology*. 2003;206:120-123.
21. Noy ML, Hughes S, Bunker CB. Another face of demodicosis. *Clin Exp Dermatol*. 2016;41(8):958-959.
22. Hong J, Koo B, Koo J. The psychosocial and occupational impact of chronic skin disease. *Dermatol Ther*. 2008;21(1):54-59.
23. Jacob S, Van Daele MA, Brown JN. Treatment of *Demodex*-associated inflammatory skin conditions: a systematic review. *Dermatol Ther*. 2019;32(6):e13103.
24. Huang HP, Hsu CK, Lee JY. A new superficial needle-scraping method for assessing *Demodex* density in papulopustular rosacea. *J Cosmet Dermatol*. 2020;19(4):896-900.
25. Huang HP, Hsu CK, Lee JY. Thumbnail-squeezing method: an effective method for assessing *Demodex* density in rosacea. *J Eur Acad Dermatol Venereol*. 2020. <https://doi.org/10.1111/jdv.16321>. [Epub ahead of print].
26. Forton FM, De Maertelaer V. Two consecutive standardized skin surface biopsies: an improved sampling method to evaluate *demodex* density as a diagnostic tool for rosacea and demodicosis. *Acta Derm Venereol*. 2017;97(2):242-248.

How to cite this article: Przydatek-Tyrajaska R, Sędzikowska A, Bartosik K. Primary facial demodicosis as a health problem and aesthetic challenge: A case report. *J Cosmet Dermatol*. 2021;20:420-424. <https://doi.org/10.1111/jocd.13542>