

Anti-arthritic activity of root bark of *Oroxylum indicum* (L.) vent against adjuvant-induced arthritis

Mamatha Karnati, Rodda H Chandra, Ciddi Veeresham¹, Bookya Kishan²

Departments of Pharmacognosy and Phytochemistry, Vaagdevi College of Pharmacy, Hanamkonda, Warangal and ¹University College of Pharmaceutical Sciences, Kakatiya University, Warangal, ²Department of Pathology, Kakatiya Medical College, Warangal, Andhra Pradesh, India

Submitted: 01-08-2012

Revised: 14-09-2012

Published: 15-04-2013

ABSTRACT

Background: *Oroxylum indicum* (Bignoniaceae) also known as Sonapatha is an indigenous medicinal plant widely used in Ayurvedic medicine for over thousands of years. It is an active ingredient of well-known Ayurvedic formulations such as Chyawanprash and Dasamula. Root bark of this plant has tonic and astringent properties and it is also used in rheumatism. **Objective:** The present investigation was carried out to evaluate the anti-arthritic activity of different extracts of root bark of *Oroxylum indicum* against adjuvant - induced arthritis in rats. **Materials and Methods:** Male Wistar rats were used in this study. Arthritis was induced by injecting 0.1 ml Freund's complete adjuvant intra-dermally into the left hind paw of the rats. The paw volume, hematological, biochemical, radiographic and histopathological aspects were evaluated. **Results:** The relative percentage inhibition potential of paw volume in rats treated with various extracts of *Oroxylum indicum* was found to be ethyl acetate extract (67.69%) >chloroform extract (64.61%) >n-butanol extract (58.46%) respectively. The hematological parameters like RBC count, hemoglobin content showed significant increase while there was a significant decrease in total WBC count and ESR in all the groups of animals pretreated with root bark extracts. The biochemical parameters such as catalase, glutathione contents showed a significant increase while the lipid peroxide and Cathepsin-D content decreased significantly only in case of ethyl acetate pretreated rats when compared to others. **Conclusion:** The present study suggests that the chloroform, ethyl acetate and n-butanol extracts of root bark of *Oroxylum indicum* exhibit anti-arthritic activity. The order of activity of extracts was found to be ethyl acetate >chloroform >n-butanol respectively.

Key words: Anti-arthritic activity, biochemical parameters, Freund's complete adjuvant, histopathology, *Oroxylum indicum*

INTRODUCTION

Oroxylum indicum is a small deciduous tree which grows up to 12 m tall and is often irregularly branched. It is found in India and Sri Lanka, South - East Asia, Philippines and Indonesia.^[1] In traditional system of medicine root bark, stem bark, leaves, fruits, and seeds have medicinal value. Root bark has tonic and astringent properties and useful in diarrhea and dysentery; used as diaphoretic and it is also used in rheumatism. Tender fruits of this plant have refreshing and stomachic properties and while the seeds

have purgative property. Roots of *Oroxylum indicum* are used as one of the ingredient in Ayurvedic formulations such as Dasamula, Amartarista, Dantadyarista, Narayana Taila, Dhanavantara Ghrita, Brahma Rasayana, Chyawanaprasha and Awaleha. The plant is claimed to possess anti-inflammatory, diuretic, anti-arthritic, antifungal and antibacterial activity.^[2] The stem bark and leaves of the plant are reported to contain flavonoids namely baicalein, chrysin, oroxylin - A, and scutellarin.^[3] Seeds of the plant contain ellagic acid.^[4] Baicalein and chrysin are reported to possess anti-inflammatory, anti-ulcer, anti-oxidant, hepatoprotective, immunomodulatory activities, anti-bacterial, anti-fungal and anti-viral activity.^[5] Biochanin-A obtained from root bark of this plant is known to possess anti-fungal and tumor necrosis factor- α (TNF- α) inhibitory action.^[6]

Address for correspondence:

Prof. Ciddi Veeresham, Department of Pharmacognosy and Phytochemistry, University College of Pharmaceutical Sciences, Kakatiya University, Warangal, Andhra Pradesh, India.
E-mail: ciddiveeresham@yahoo.co.in

Access this article online

Website:

www.phcogres.com

DOI: 10.4103/0974-8490.110543

Quick Response Code:



Rheumatoid arthritis (RA) is a chronic inflammatory autoimmune disease in which the immune system, which normally protects the body against infections and diseases, instead targets the body. In RA, the immune system attacks the tissues that line the joints, causing pain, swelling, and stiffness in the joints and affect the joints ability. RA is a wear-and-tear condition that commonly occurs as people age. About 1% of world's population is afflicted by rheumatoid arthritis; women are three to five times more prone to RA than men. It is most common at 40-50 years age group people.^[7] Adjuvant arthritis is a good experimental model of polyarthritis in rats which has been widely used for the preclinical testing of numerous anti-arthritis agents.^[8]

Conventional medicines used for RA include non-steroidal anti-inflammatory drugs (NSAIDs), disease-modifying anti-rheumatic drugs (DMARDs), biological response modifiers, and corticosteroids.^[9] However, these drugs have numerous and severe side effects including gastric ulcers and redistribution of body fat. Therefore, agents of natural origin with relatively less side effects are explored.^[10] Plant derived drugs serve as lead molecules to develop more effective and less toxic medicines.^[11] *Oroxylum indicum* was reported to contain many valuable phytoconstituents and it also has a traditional claim of use in arthritis. In view of this the present study was carried out to evaluate the anti-arthritis activity of extracts of root bark of *Oroxylum indicum* against adjuvant – induced arthritis in rats.

MATERIALS AND METHODS

Collection and authentication of plant material

Root bark of the plant was collected from Illandu forest area of Khammam district, Andhra Pradesh. The plant material was identified and authenticated by Dr. V. S. Raju, Professor, Department of Botany, Kakatiya University, Warangal. A voucher specimen (VCOP-OI-01) was deposited in the herbarium of college. The root bark was dried in shade and coarse powder (60 mesh size) was prepared.

Chemicals used

The organic solvents used for the extraction were procured from local distributor of S.D. Fine Chem. Pvt. Ltd (Hyderabad). Freund's complete Adjuvant and 5, 5'-dithiobis (2-nitrobenzoic acid) were purchased from Sigma Aldrich (Bangalore). Trichloroacetic acid, di-nitro-phenyl hydrazine were procured from local distributor of Finar Chemicals (Warangal). Thiobarbituric acid and Folin – Ciocalteu reagent were procured from Himedia (Mumbai). Diclofenac sodium was a kind gift from Dr. Reddy's Laboratories (Hyderabad).

Extraction of plant material

100 g of rook bark powder was packed in soxhlet apparatus

and defatted with petroleum ether for 6 h and later on the plant material was dried, followed by moistening with ammonia solution. The defatted plant material was then extracted with chloroform, ethyl acetate, and n-butanol for 6 h successively. The extracts were filtered and then concentrated by evaporation, dried in desiccator and were stored in airtight containers until usage.^[12]

Experimental animals

Wistar strain male albino rats, weighing 200-250 g were purchased from Mahaveera enterprises, Hyderabad. The animals were maintained in animal house at a room temperature of 25°C, with relative humidity of 75% and alternating 12 h dark - light cycle. The animals had free access to standard laboratory feed (M/s. Hindustan Levers Ltd., Mumbai) and water *ad libitum*. The rats were acclimatized to the environment for two weeks prior to experimental use. The study was approved by the Institutional Animal Ethics Committee (IAEC No. 2011/10/3/2).

Grouping of animals

The rats were divided into 6 groups; each group containing 6 animals. All the extracts and drugs were administered to the rats by oral route. All extracts and drugs were suspended in 5% gum acacia solution. Group-I was kept as normal control and administered with vehicle alone (gum acacia). Group-II served as disease control, while Group-III was administered with standard drug (Diclofenac sodium 10 mg/kg), the Group-IV received the chloroform extract (300 mg/kg), Group-V received the ethyl acetate extract (300 mg/kg) and Group-VI received the n-butanol extract (300 mg/kg).

Induction of arthritis

Arthritis was induced in rats by intradermal injection of 0.1 ml of Complete Freund's Adjuvant (CFA) containing 10 mg/ml *Mycobacterium tuberculosis* into the foot pad of the left hind paw.^[13] All the animals were examined carefully; their body weights and hind paw swelling were recorded on day 0, 1, 3, 7, 14 and 21 respectively. On day 21 the blood samples were collected by puncturing the retro-orbital plexus prior to the sacrifice and the collected blood sample was used for the assessment of RBC, WBC, ESR and hemoglobin content. Later on the rats were sacrificed by over dose of inhalant anesthesia. Livers were rapidly removed and kept in ice cold saline. The liver tissues were later on used for the antioxidant enzyme analysis and for estimation of Cathepsin-D content.

Preparation of tissue homogenate

All liver tissues of rats were pooled and minced into small pieces with sharp scissors and then homogenized with 0.01 M Tris HCl buffer (pH 7.4) using a high speed Potter Elvehjem Teflon homogenizer and a 10% homogenate

was prepared.^[14] Aliquots of this homogenate were used for estimating lipid peroxide, total reduced glutathione, ascorbic acid, catalase and Cathepsin-D levels. The enzyme assays were performed within 24 h of sacrificing the animal.

Radiological and histopathological examination

For radiological and histopathological studies the hind limbs (knee joints) were removed and preserved in 10% formalin. The tissues were fixed in formalin, decalcified with 5% formic acid and embedded in paraffin blocks. The sections prepared with the microtome were stained with hematoxylin (H) and eosin (E). The stained sections were examined under microscope and images were recorded.^[15] Radiographic analysis of hind limbs of arthritic and treated animals were performed by X-ray machine (Meditronics, Hyderabad) with a 300-mA exposition for 5 sec.

Biochemical assays

Lipid peroxide levels

Lipid peroxides were estimated by following the procedure of Ohkawa.^[16] An aliquot of the tissue homogenate was treated with 3 ml of ice cold trichloroacetic acid (10%). The tubes were mixed well and 2 ml of thiobarbituric acid (TBA) was added. The tubes were covered with glass marbles and kept in the boiling water bath for 20 min. After cooling, the tubes were centrifuged and the absorbance of the supernatant was read at 532 nm. The malondialdehyde content in the tissues was expressed as μ moles/mg protein.

Total reduced glutathione

Total reduced glutathione (GSH) was determined by following the method of Sedlak.^[17] The liver homogenate was deproteinized with an equal volume of 10% TCA and was allowed to stand at 4°C for 2 h. The contents were centrifuged at 2000 rpm for 15 min. The supernatant was added to 2 ml of Tris buffer (0.4 M, pH 8.9) containing EDTA (0.02 M, pH 8.9) followed by the addition of 5, 5'-dithiobis-(2-nitrobenzoic acid) (0.01 M). Finally, the mixture was diluted with 0.5 ml of distilled water, to make the total volume to 3 ml and absorbance was recorded at 412 nm using UV spectrophotometer and results were expressed as μ g GSH/g tissue.

Catalase activity

Catalase activity was determined by using method of Sinha.^[18] To 1.0 ml of phosphate buffer (0.01 M, pH 7.0), 0.4 ml distilled water and 0.1 ml of homogenate (10%; prepared in 0.01 M phosphate buffer) were added. Reaction was initiated by adding 0.5 ml hydrogen peroxide, incubated at 37°C for 1 min and reaction was stopped by addition of 2.0 ml of potassium dichromate: acetic acid reagent. The tubes were immediately kept in a boiling water bath for 15 min and later on centrifuged for 10 min (3000 rpm). The green color developed during the reaction was read at 570 nm using spectrophotometer. The activity of catalase

in tissue homogenate was expressed as μ moles of H_2O_2 utilized/min/mg protein.

Cathepsin-D activity in tissue homogenate

Cathepsin-D content was estimated by following the method of Sapolsky.^[19] To 0.3 ml of homogenate, 1 ml of buffered substrate was added and incubated for 2 h at 45°C. The reaction was stopped by addition of TCA (10%) and allowed to stand for 30 min at room temperature. The solution was centrifuged, to 1 ml of the supernatant; 2 ml of sodium hydroxide and 0.6 ml of dilute phenolic reagent were added. The optical density was measured after 10 min. at 620 nm. The standard graph was plotted with 40-200 nanomoles of tyrosine. The enzyme activity was expressed as μ moles of tyrosine liberated per h per 100 mg of protein.

Total phenolic content determination

The total phenolic content of the extracts was determined by the Folin - Ciocalteu method.^[20] Briefly 0.5 ml of the each extract was transferred to a 100 ml Erlenmeyer flask and the final volume was adjusted to 46 ml by addition of distilled water. 1 ml of Folin-Ciocalteu reagent was added and incubated at room temperature for 3 min. 3 ml of sodium carbonate (2%) solution was added and the mixture was shaken on a shaker for 2 h at room temperature. The absorbance was measured at 760 nm. Gallic acid in the concentration range of 20-100 μ g/ml was used as standard for construction of calibration curve. The total phenolic content was expressed as μ g/g in terms of gallic acid equivalents (GAE).

Total flavonoid content determination

Aluminum chloride colorimetric method was used for estimation of total flavonoid content.^[21] 1 ml of each extract was mixed with 3 ml of methanol, 0.2 ml of aluminum chloride (10%), 0.2 ml of 1 M potassium acetate and 5.6 ml of distilled water and set aside at room temperature for 30 min. The absorbance of the reaction mixture was measured at 420 nm with ultraviolet (UV) visible spectrophotometer. The total flavonoid content was expressed in terms of μ g/g in terms of quercetin equivalents (QE).

Statistical analysis

All the data are presented as mean \pm SD. Statistical analysis was performed with one way ANOVA and the differences among groups were determined by Dunnett's multiple comparison tests using Graph Pad Prism 5. *P* values of <0.05, <0.01 and <0.001 were considered to be statistically significant.

RESULTS

The mean changes in body weight of different groups of rats are shown in Table 1. There was no significant loss of body weight in all groups of arthritis induced rats.

Paw swelling is one of the major factors in evaluating the degree of inflammation and therapeutic efficacy of the drug. The arthritic rats showed soft tissue swelling around the ankle joints during the acute phase of arthritis. Swelling and redness were observed in hind paw injected with CFA and they showed maximum intensity on day 7 (first swelling phase) and the swelling in the paw slowly subsided until 14th day. The paw exhibited swelling again after 14th day due to disseminated arthritis (second swelling phase).

The percentages of disease recovery (as measured by the percentage inhibition of hind paw oedema) in arthritic groups which received diclofenac, chloroform extract, ethyl acetate extract and n-butanol extract were found to be 35.38%, 64.61%, 67.69% and 58.46% respectively. The effect of different extracts is shown in Table 2 and Figure 1; the percentage inhibition of paw volume is shown in Table 3.

Table 1: Mean changes in body weight (g)

Group	Before induction	On 21 st day
Control	208±8.53	197.5±26.29
Normal	215±23.8	216.25±33.50
Standard	222.5±21.01	205±36.51
Chloroform extract	220±14.71	225.5±24.66
Ethyl acetate extract	228.75±14.93	196.25±16.01
n-butanol extract	223.75±6.29	200±37.64

All values expressed as mean±S.D, n=6

The changes in hematological parameters in adjuvant induced arthritic rats are shown in Table 4. There was a significant increase in RBC count and hemoglobin content. While, there was a significant decrease in WBC count and ESR of arthritic rats in comparison to the control.

Lipid peroxidation

Extent of LPO was measured through malondialdehyde activity (MDA), a pro-oxidant factor which determines the oxidative damage. The MDA content of homogenate of different groups of rats is shown in Table 5. The results reveal that MDA content of arthritis induced animals was significantly increased when compared to control. The chloroform and ethyl acetate extract treated rats showed significant decrease ($P < 0.01$) in MDA content after 21 days of study. While, butanol extract treated rats showed moderate decrease ($P < 0.05$) in MDA content of tissue homogenate.

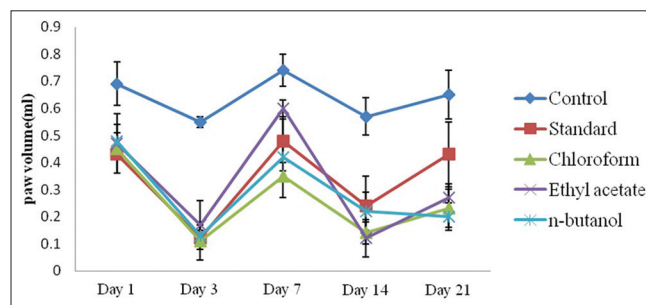


Figure 1: Effect of different extracts on paw volume

Table 2: Effect of different extracts on paw volume (ml)

Group	Day-1	Day-3	Day-7	Day-14	Day-21
Control	0.69±0.08	0.55±0.02	0.74±0.06	0.57±0.07	0.65±0.09
Standard	0.43±0.02**	0.12±0.03**	0.48±0.08	0.24±0.11**	0.42±0.12*
Chloroform extract	0.45±0.09*	0.11±0.07**	0.35±0.02	0.14±0.04***	0.23±0.07***
Ethyl acetate extract	0.47±0.11*	0.17±0.09*	0.6±0.03	0.12±0.07***	0.21±0.05***
n-butanol extract	0.48±0.03*	0.13±0.04**	0.42±0.15	0.22±0.07**	0.27±0.05**

All values expressed as mean±S.D, n=6, * $P < 0.05$ significant, ** $P < 0.01$ highly significant, *** $P < 0.001$ very highly significant

Table 3: Effect of different extracts on percentage inhibition of paw volume

Group	Day-1	Day-3	Day-7	Day-14	Day-21
Standard	37.68	78.18	35.13	57.89	35.38
Chloroform extract	34.70	80.00	52.70	78.94	64.61
Ethyl acetate extract	31.8	69.09	18.90	61.40	67.69
n-butanol extract	30.04	76.36	43.24	75.43	58.46

Table 4: Hematological parameters in various groups of rats

Parameters	Control	Normal	Standard	Chloroform extract	Ethyl acetate extract	n-butanol extract
RBC (millions/mm ³)	4.64±0.14	5.24±0.14*	5.64±0.14**	5.4±0.11**	6.14±0.14***	5.5±0.19**
WBC (thousands/mm ³)	12.9±0.04	7.87±0.04***	8.6±0.2***	9.5±0.17***	7.6±0.04***	7.73±0.22***
Hb (g/dl)	11.45±0.07	14.15±0.07***	14.25±0.07***	14.4±0.14***	14.45±0.21***	14.3±0***
ESR (mm/hr)	9.67±0.57	3.34±0.57***	4.34±0.57***	5±1***	3.16±0.28***	3.5±0.5***

All values are expressed as mean±S.D, n=6, * $P < 0.05$ significant, ** $P < 0.01$ highly significant, *** $P < 0.001$ very highly significant

Total reduced glutathione

The analysis of liver homogenates revealed that the Glutathione (GSH) levels were increased significantly ($P < 0.05$) in ethyl acetate-treated group when compared to other groups as shown in Table 5.

Catalase

Catalase is an intracellular antioxidant, it contributes to the development of rheumatoid arthritis and its levels are reduced in the in arthritis-induced groups. The catalase levels in tissue homogenate were increased significantly in ethyl acetate treated group when compared to disease control as shown in Table 5. The levels were increased in all the extract treated rats compared to the disease induced

group depicting that the extracts have significant influence on increasing catalase levels.

Cathepsin-D

The cathepsin-D content (tyrosine units) in liver homogenates of all groups is shown in Table 5. The results depict that there was a significant ($P < 0.001$) decrease in Cathepsin D content in all groups of rats treated with various extracts of *Oroxylum indicum*.

Radiology

The radiographic images of the knee joints of all groups of rats are shown in Figure 2. It is evident from the radiographic images that adjuvant treated rats developed

Table 5: The biochemical parameters in various groups of rat

Group	Lipid peroxides (nM/mg)	GSH ($\mu\text{g}/\text{mg}$)	Catalase (μM of H_2O_2 utilized/min/mg)	Cathepsin-D units
Control	0.13 \pm 0.04	0.07 \pm 0.003	0.19 \pm 0.01	70.4 \pm 1.22
Normal	0.05 \pm 0.004**	0.17 \pm 0.008***	0.27 \pm 0.04*	28.68 \pm 2.07***
Standard	0.05 \pm 0.01**	0.12 \pm 0.04*	0.41 \pm 0.09***	53.26 \pm 3.12***
Chloroform extract	0.06 \pm 0.008**	0.11 \pm 0.01	0.26 \pm 0.03	37.1 \pm 1.74***
Ethyl acetate extract	0.06 \pm 0.03**	0.12 \pm 0.008*	0.48 \pm 0.1***	28.09 \pm 0.30***
<i>n</i> -butanol extract	0.07 \pm 0.01*	0.10 \pm 0.01	0.22 \pm 0.02	37.86 \pm 1.22***

All values are expressed as mean \pm S.D, $n=6$, * $P < 0.05$ significant, ** $P < 0.01$ highly significant, *** $P < 0.001$ very highly significant

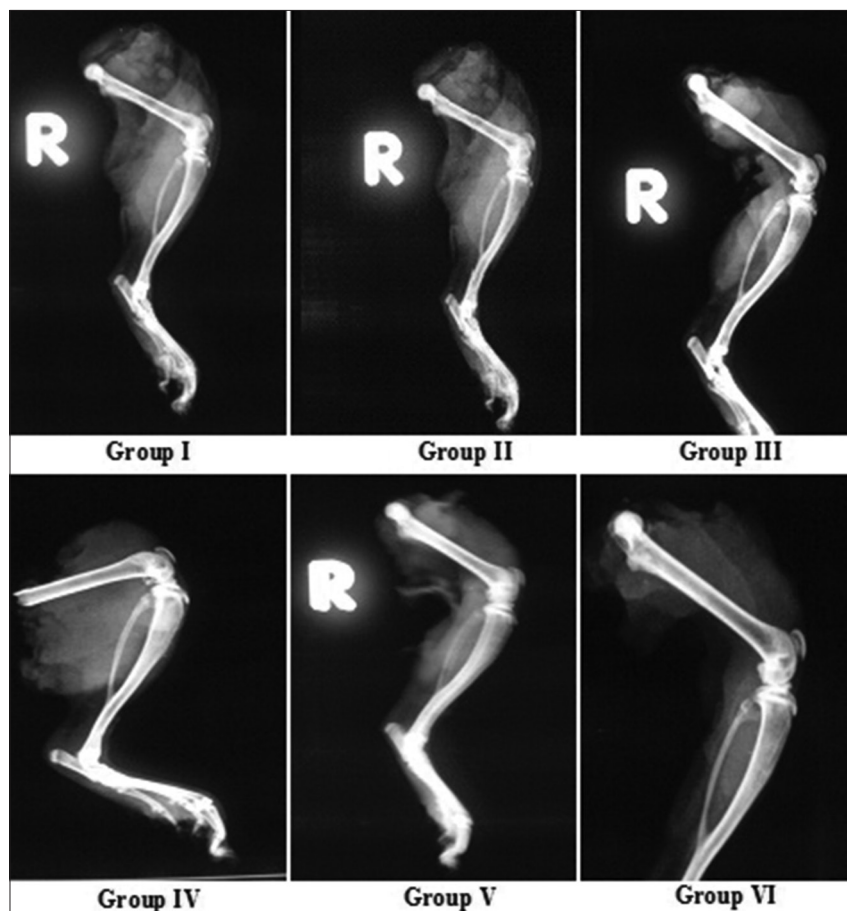


Figure 2: X-ray photographs of knee joints of rats

periosteal reaction, irregular joint space and joint space reduction. Whereas, in the extracts treated and in standard group the joint space appeared normal, no periosteal reaction was observed and joints appeared to be normal.

Histopathology

The histopathological changes in the various groups of animals are shown in Figure 3. The histopathological studies revealed the following changes in the various groups of animals. In normal rats, H and E stained section showed stroma consisting of normal osteoid with normal bony trabeculae and these cells showed centrally placed nucleus with large amount of clear cytoplasm. The marrow exhibited mostly hemorrhage and the synovial lining was found to be normal.

In disease control rats, H and E stained section showed thinned out bony trabeculae and stroma showed mild varying sizes of osteocytes and these cells exhibited mild anisocytosis with centrally placed nucleus and scant amount of eosinophilic cytoplasm. Periosteum showed mostly

mononuclear inflammatory cellular infiltrates mostly lymphocytes. Synovial membrane showed large amount of inflammatory infiltrates. Occasional areas showing pannus formation, angiogenesis and foreign body type of giant cells were also observed. Further, there was decrease in vascular channels with perivascular inflammatory infiltrates with plenty of dead chondrocytes.

In diclofenac treated rats, H and E stained section showed stroma consisting of mostly pannus formation with synovial membrane showing occasional mononuclear cellular infiltrates.

In chloroform extract treated rats, H and E stained section showed normal angiogenesis, decrease in the inflammatory infiltrates in the synovial membrane with stroma containing mostly pannus formation was observed.

In ethyl acetate extract treated rats, H and E stained section showed mostly normal bony trabeculae and some areas showed dead chondrocytes. In addition there was occasional pannus formation and normal angiogenesis. Synovial membrane showed scanty inflammatory cells mostly lymphocytes and plasma cells. The marrow was normal with no formation of giant cells.

In n-butanol extract treated rats, H and E stained section showed mostly pannus formation, dead chondrocytes with empty clear cytoplasm with pyknotic nucleus. Some areas showed occasional vascular channels. Periosteum showed increase periosteal reaction and synovial membrane showed inflammatory infiltrates.

Total phenolic content and flavonoid content

Total phenolic and total flavonoid content of the various extracts is shown in Table 6.

DISCUSSION

The percentage yields of the petroleum ether, chloroform, ethyl acetate and n-butanol extracts were found to be 0.12, 0.58, 1.2 and 1.4 respectively. In petroleum ether extract *Oroxylum indicum* root bark it was found to contain phenols, tannins, steroids and terpenoids; Chloroform extract and ethyl acetate extracts were found to contain flavonoids, phenolics, tannins, alkaloids, steroids and terpenoids. Whereas n-butanol extract was found to contain carbohydrates, flavonoids, steroids, and terpenoids.

In the present investigation rats were selected to induce arthritis because rats develop a chronic swelling in multiple joints under the influence of inflammatory cells, erosion of joint cartilage due to bone destruction. The arthritis produced in rats has close similarities to that of human

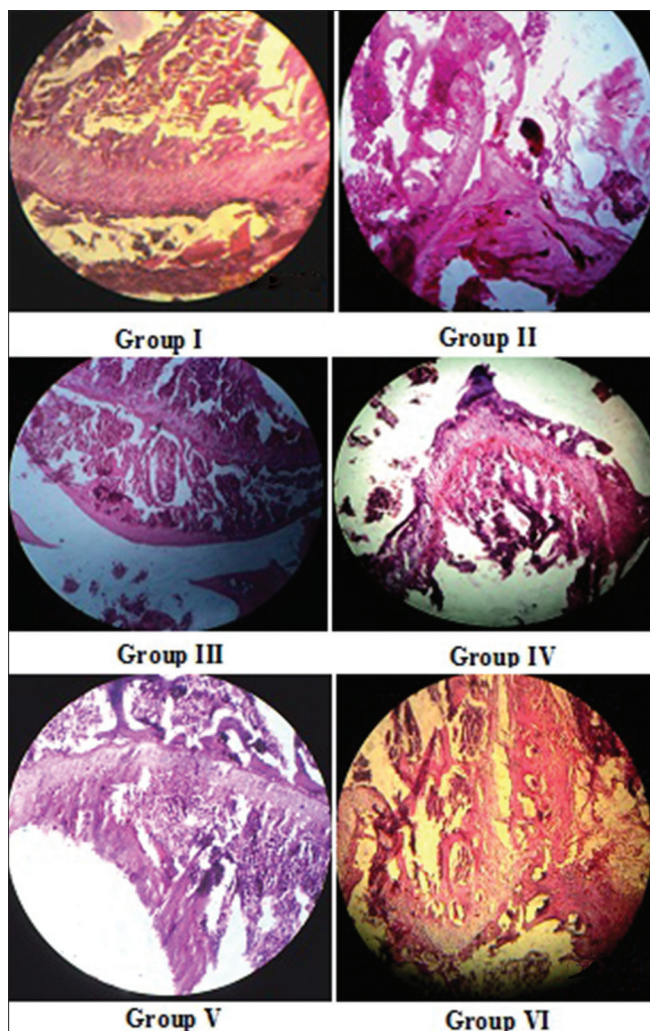


Figure 3: Histopathological photographs of rat knee joints

Table 6: Total phenolic and flavonoid content in the extracts

Type of extract	Concentration of total phenolic content ($\mu\text{g/g}$) equivalent to gallic acid	Concentration of total flavonoid content ($\mu\text{g/g}$) equivalent to quercetin
Chloroform extract	149.88	4.43
Ethylacetate extract	86.25	5.25
<i>n</i> -butanol extract	53.86	2.46

rheumatoid arthritis. The determination of paw swelling is simple, sensitive and quick procedure to assess the degree of inflammation and therapeutic effects of drugs. Chronic inflammation involves the release of inflammatory mediators such as cytokines (IL-1B and TNF- α), interferons and Platelet derived growth factors (PDGF). These mediators are mainly responsible for the pain, destruction of bone cartilage which can cause severe disability.^[22] In the present investigation the percentage inhibition of paw edema showed maximum protection on 21st day. Among all extracts, the ethyl acetate extract was proved to be effective in chronic inflammation when compared to the other two extracts which may be attributed to the phenolic constituents present in the plant. The present results are in agreement with the study of Joshi^[23] which showed that aqueous extract of the root bark significantly reduced the inflammation of colon.

Alteration in the body weight is also generally used to assess the course of the arthritis and to assess positive benefit obtained with the anti-inflammatory drugs. With the increase in severity of arthritis the changes in the body weight of the rats can occur. The decrease in body weight was attributed to reduced absorption of ¹⁴C- glucose and ¹⁴C-leucine in rat's intestine. But the body weight increases in the course of the therapy due to increase in the absorption capacity of intestine. In contrast to the general observation there was no significant increase in body weight in all the groups rats used in the present study.^[24,25]

The hematological data revealed that there was an increase in RBC count and hemoglobin level, and decrease in the ESR. Further, there was a significant decrease in leukocyte count in extract treated groups while it was reverse in control group. These data suggest that the *Oroxylum indicum* root bark extract has significant role in the arthritis.

Free radicals induced oxidative injury is the fundamental mechanism underlying a number of pathological disorders. In the present investigation, after adjuvant induction the anti-oxidant activity was measured and it was observed that the ethyl acetate extract of root bark showed significant ($P < 0.05$) increase in the total reduced glutathione, catalase levels than the chloroform, and *n*-butanol extract. In addition all the extracts showed significant inhibition in the lipid peroxidation. The results are in agreement with the reports of Zaveri and Mishra.^[26,27]

The antioxidant activity may be attributed to the redox potential phenolic compounds which can play pivotal role in absorbing, neutralizing free radicals, quenching singlet/triplet oxygen, and decomposing the peroxides.^[28]

The increase in levels of connective tissue degrading lysosomal glycohydrolases such as acid phosphatase, beta-glucuronidase, beta-*N*-acetyl glucosaminidase and cathepsin-D is commonly observed in arthritic animals.^[29] In the present study the increase levels of Cathepsin – D were observed in case of standard drug treated rats. In contrast the extracts treated rats had significantly ($P < 0.001$) low levels of Cathepsin – D. The results indicate that the extracts played significant role in lysosomal membrane stabilization preventing the connective tissue degradation.

The observed changes in radiographic and histopathological findings can be attributed to positive benefits provided by the extracts on the inflammatory mechanisms in the joint tissues. The antioxidant activity, reduction in inflammatory mediators and lysosomal enzymes involved in tissue degradation by the extracts can be the possible mechanisms for the observed changes in radiographic and histopathological findings.^[24,25]

The phytochemical studies revealed that all the extracts showed the presence of phenolic constituents to greater extent rather than the flavonoids. The observed activities can be attributed to higher phenolic content of the extracts. However, the role of flavonoids in the observed activities cannot be ruled out because earlier studies on this plant report that most of the flavonoidal constituents present in stem bark, leaves and roots have varied pharmacological activities. Of the three extracts investigated the chloroform and ethyl acetate extracts had significant anti-arthritis potential.

In conclusion, our results indicate that root bark extracts of *Oroxylum indicum* have significant anti-arthritis potential. However, there is need to isolate and characterize the active compounds responsible for the observed anti-arthritis activity.

REFERENCES

1. Dev LR, Mishra A, Gupta R. *Oroxylum indicum*: A review. Pharmacogn J 2010;2:304-10.

2. Zaveri M, Sunita J. Anti-inflammatory and analgesic activity of root bark of *Oroxylum indicum*. JGPT 2010;2:79-87.
3. Subramanian SS, Nair AG. Flavonoids of stem bark of *Oroxylum indicum*. Curr Sci 1972;41:62-3.
4. Vasanth S, Natarajan M, Sunderesan R, Bima RR, Kundu AB. Ellagic acid from the root bark of *Oroxylum indicum*. Indian Drugs 1991;28:507.
5. Roy MK, Nakahara K, Na TV, Trakoontivakorn G, Takenaka M, Isoe S, et al. Baicalein, a flavonoid extracted from a methanolic extract of *Oroxylum indicum* inhibits proliferation of a cancer cell line *in vitro* via induction of apoptosis. Pharmazie 2007;62:149-53.
6. Knight DC, Eden JA. A review of the clinical effects of phytoestrogens. Obstet Gynecol 1996;87:897-904.
7. Symmons DP, Hazes JM, Silman AJ. Cases of early inflammatory polyarthritis should not be classified as having rheumatoid arthritis. J Rheumatol 2003;30:902-4.
8. Bendele AM. Animal models of rheumatoid arthritis. J Musculoskelet Neuronal Interact 2001;1:377-85.
9. Gullick NJ, Scott DL. Drug therapy of inflammatory arthritis. Clin Med 2012;12:357-63.
10. Khanna D, Sethi G, Ahn KS, Pandey MK, Kunnumakkara AB, Sung B, et al. Natural products as a gold mine for arthritis treatment. Curr Opin Pharmacol 2007;7:344-51.
11. Rajkumar M, Harish CR, Asres K, Veeresham C. *Toddalia asiatica* (Linn) Lam-A comprehensive review. Pharmacogn Rev 2008;2:386-97.
12. Maitreyi K, Mamta S, Devdas S, Sunitha J. Antiulcer activity of the root bark of *Oroxylum indicum* against experimental gastric ulcers. Pharm Biol 2006;44:363-70.
13. Ramadan G, Al-Kahtani MA, El-Sayed WM. Anti-inflammatory and anti-oxidant properties of *Curcuma longa* (turmeric) versus *Zingiber officinale* (ginger) rhizomes in rat adjuvant-induced arthritis. Inflammation 2011;34:291-301.
14. Chamundeswari D, Vasantha J, Gopalakrishnan S, Sukumar E. Free radical scavenging activity of the alcoholic extract of *Trewia polycarpa* roots in arthritic rats. J Ethnopharmacol 2003;88:51-6.
15. Pathak N, Priyanshee G, Natawar BP, Sanjay K, Nirruddin J, Yagnik B. Curative effect of *Albizia lebbek* methanolic extract against adjuvant arthritis-with special reference to bone erosion. IJPDR 2009;1:183-7.
16. Ohkawa H, Ohishi N, Yagi K. Assay for lipid peroxides in animal tissues by thiobarbituric acid reaction. Anal Biochem 1979;95:351-8.
17. Sedlak J, Lindsay RH. Estimation of total, protein-bound, and non-protein sulfhydryl groups in tissue with Ellman's reagent. Anal Biochem 1968;25:192-205.
18. Sinha AK. Colorimetric assay of catalase. Anal Biochem 1972;47:389-94.
19. Sapolsky AI, Altman RD, Woessner JF, Howell DS. The action of cathepsin D in human articular cartilage on proteoglycans. J Clin Invest 1973;52:624-33.
20. Singleton VL, Orthofer R, Lamuela-Raventos RM. Analysis of total phenols and other oxidation substrates and antioxidants by means of Folin-Ciocalteu reagent. Methods Enzymol 1999;299:152-78.
21. Quettier-Deleu C, Gressier B, Vasseur J, Dine T, Brunet C, Luyckx M, et al. Phenolic compounds and antioxidant activities of buckwheat (*Fagopyrum esculentum* Moench) hulls and flour. J Ethnopharmacol 2000;72:35-42.
22. Eric GB, Lawrence JL. Rheumatoid Arthritis and its therapy. In: The textbook of therapeutics drug and disease management. Baltimore: Williams and Wilkins Company; 1996. p. 579-95.
23. Joshi SV, Vyas BA, Shah PD, Shah DR, Shah AS, Gandhi TR. Protective effect of aqueous extract of *Oroxylum indicum* Linn. (root bark) against DNBS induced colitis in rats. Indian J Pharmacol 2011;43:656-61.
24. Winder CV, Lembke LA, Stephens MD. Comparative bioassay of drugs in adjuvant – induced arthritis in rats: Flufenamic acid, mefenamic acid, and phenylbutazone. Arthritis Rheum 1969;12:472-82.
25. Somasundaran S, Sadique J, Subramoniam A. Influence of extra-intestinal inflammation on the *in vitro* absorption of ¹⁴C-glucose and the effects of anti-inflammatory drugs in the jejunum of rats. Clin Exp Pharmacol Physiol 1983;10:147-52.
26. Zaveri M, Sunita J. Gastroprotective effects of root bark of *Oroxylum indicum*. J Nat Remedies 2007;7:269-77.
27. Mishra SL, Sinhamahapatra PK, Nayak A, Das R, Sannigrahi S. *In vitro* antioxidant potential of different parts of *Oroxylum indicum*: A comparative study. Indian J Pharm Sci 2010;72:267-9.
28. Osawa T. Novel natural antioxidants for utilization in food and biological systems. In: Uritani L, Garcia VV, Mendoza EM, editors. Tokyo, Japan: Japan Scientific Societies Press; 1994. p. 241-51.
29. Semalty M, Semalty A, Badola A, Joshi GP, Rawat MS. *Semecarpus anacardium* Linn.: A review. Pharmacogn Rev 2010;4:88-94.

Cite this article as: Karnati M, Chandra RH, Veeresham C, Kishan B. Anti-arthritis activity of root bark of *Oroxylum indicum* (L.) vent against adjuvant-induced arthritis. Phcog Res 2013;5:121-8.

Source of Support: Nil, **Conflict of Interest:** None declared.