



Contents lists available at ScienceDirect

International Journal of Surgery Case Reports

journal homepage: www.casereports.comOvarian haemangioma: A rare case report[☆]

Bhaskar Mitra*, Subhalakshmi Sengupta, Anshita Rai, Jay Mehta, Aruna Rai Quader, Subhendu Roy, Anita Borges

Drs Tribedi & Roy Diagnostic Laboratory, Kolkata, West Bengal, India

ARTICLE INFO

Article history:

Received 3 February 2013

Received in revised form 21 July 2013

Accepted 29 July 2013

Available online 12 August 2013

Keywords:

Ovarian haemangioma

Ovarian tumour

Mesenchymal tumour

ABSTRACT

INTRODUCTION: Haemangioma of ovary is a rare tumour.**PRESENTATION OF CASE:** We report an ovarian haemangioma which presented as an acute abdomen due to an adnexal mass.**DISCUSSION:** We report an ovarian haemangioma which presented as an acute abdomen due to an adnexal mass. Haemangiomas have been reported in other organs but ovarian haemangioma is a rare tumor, usually asymptomatic and presenting as an incidental finding. Large lesions tend to present clinically with pain. A few cases have been described in the literature.**CONCLUSION:** Considering their rare occurrence such tumors are a diagnostic challenge.

© 2013 The Authors. Published by Elsevier Ltd on behalf of Surgical Associates Ltd. All rights reserved.

1. Introduction

The ovary itself is a highly vascularized organ but vascular tumors of the female genital tract, especially those arising in the ovary, are very rare, not exceeding 60.^{1–5} These neoplasms have been reported in different ages ranging from infancy to 81 years.^{1,6} Though most of these lesions are small and detected only incidentally during an operation or autopsy, a few of them can be large and present with abdominal pain and ascites.⁷

The aim of this article is to emphasize on a rare occurrence with its clinicopathological features and differential diagnoses in view of the recent literature.

2. Case report

A 22 year-old woman presented with an acute onset of lower abdominal pain of 2 days duration. On bimanual pelvic examination, a right adnexal mass was palpated. Routine haematological and biochemical parameters were within normal limits. General urine examination was unremarkable and urine culture showed no growth of any organism. Ultrasonography revealed a right ovarian solid mass measuring 4.5 cm × 3.8 cm × 3 cm with a low-resistant vascular flow pattern on Doppler examination. There was no evidence of ascites. The serum Ca-125 level of the patient was 32 IU/ml. Cervical smear revealed normal cytological findings. An adnexal

mass, identified on ultra-sound, was explored through a lower mid-line incision which revealed a solid hemorrhagic mass in the right ovary. Right oophorectomy was performed and the ovary sent for histopathology. The postoperative recovery was uneventful with subsequent relief of patient's pain.

Macroscopically, the outer surface of the mass was smooth and glistening with a grayish white to purplish tint. The cut surface showed a spongy texture and honeycomb appearance (Fig. 1) due to multiculated cystic spaces filled with frank blood.

Microscopically, most of the ovary was replaced by numerous dilated thin walled vascular channels, of variable size and configuration (Fig. 2) some of which were filled with red blood cells. These vascular channels were separated by connective tissue septa. These vessels were lined by a single layer of flattened endothelium without atypical features. Thrombi were noted but there was no necrosis. A follicle cyst and a corpus luteum were also present. The diagnosis of primary ovarian haemangioma, a benign vascular tumor was made.

Immunohistochemistry, revealed CD 31 & CD 34 positivity of the cells lining the lumina, confirming their vascular nature (Fig. 3).

3. Discussion

Haemangiomas are benign vascular tumors arising from failure in vascular formation, particularly in the canalizing process, forming abnormal vascular channels. These are of two types: cavernous and capillary.⁴ The difference between these two types relate to the size of the blood vessels formed. Vascular tumors of the female genital tract, especially those of the ovary, are very rare. This is not expected since the ovary has a rich vascular supply. Cyclic changes in the female genital organs during the reproductive period and the asymptomatic nature and small size of the neoplasm have been attributed to explain its rarity of occurrence.⁸ Although the exact

[☆] This is an open-access article distributed under the terms of the Creative Commons Attribution-NonCommercial-No Derivative Works License, which permits non-commercial use, distribution, and reproduction in any medium, provided the original author and source are credited.

* Corresponding author at: 54/2/G, Feeder Road, P.O.- Belgharia, Kolkata 700056, West Bengal, India. Tel.: +91 9831252460.

E-mail address: bhaskarmitra12@gmail.com (B. Mitra).

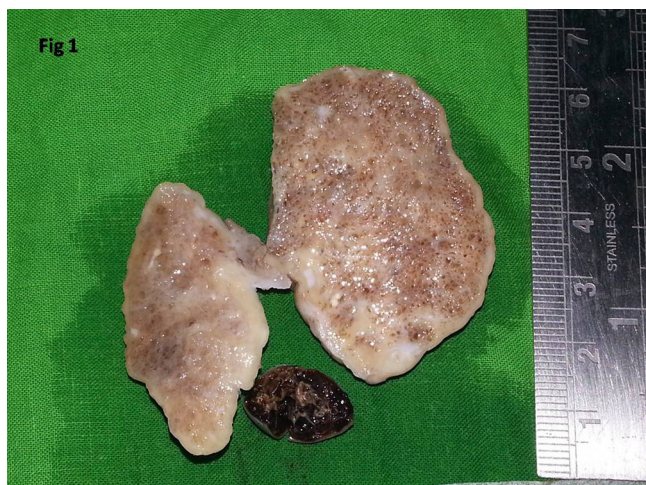

Fig. 1. Gross appearance of the specimen.

number of ovarian haemangiomas is disputed, the number of well documented cases seems to be 50 or more but does not exceed 60.¹⁻⁵

Ovarian haemangiomas are usually asymptomatic and present as incidental findings during operation or autopsy.⁴ Large lesions tend to present clinically as adnexal mass, frequently associated with lower abdominal pain, nausea and vomiting, due to torsion¹ or abdominal distension because of the mass itself. Sometimes clinical diagnosis of pelvic inflammatory disease is suspected initially as in our case.

Only a few of the ovarian haemangiomas have been reported to be associated with massive ascites and elevated serum CA-125 levels clinically mimicking an ovarian carcinoma.^{2,3,9} Preoperative Doppler examination of such a lesion may show a low-resistant vascular flow pattern, supporting malignant neoplasia of the ovary. Pseudo-Meigs' syndrome,² stromal luteinization, stromal

hyperplasia,^{3,9-15} and thrombocytopenia have also been reported as complications of ovarian haemangioma. The decreased platelet count is regarded as one of the manifestations of Kasabach and Merritt syndrome, particularly in bilateral cases associated with diffuse abdominopelvic haemangiomatosis.^{4,16} Coexistence of non-ovarian neoplasms such as endometrial carcinoma,³ cervical carcinoma,⁵ rectosigmoid carcinoma,¹³ and tubal carcinoma¹⁴ has also been reported.

Although the etiology remains unknown, these lesions have been considered either hamartomatous malformations or true neoplasms in which pregnancy, other hormonal effects, or infection¹⁷ have been implicated as factors, enhancing the growth. It has been suggested that the hyperestrogenism caused by pre-existing stromal luteinization of ovaries may stimulate the development of an ovarian haemangioma due to the growth stimulatory effects of estrogens on vessels and expression of estrogen receptors by haemangiomas.^{11,13} According to another hypothesis, the presence of an expansile ovarian hemangioma induces stromal luteinization by mass effect. These luteinized stromal cells produce androgens, which are subsequently converted to estrogens in adipose tissue, potentially causing unopposed estrogenic stimulation to the endometrium which may present as postmenopausal or dysfunctional uterine bleeding,^{3,11,12,14} aching breasts,¹² advanced male type hair loss,³ and elevated androgen and estradiol levels.³

Macroscopically, ovarian haemangiomas are usually small with size ranging from 5 mm to 24 cm in its greatest diameter.⁴ They are usually unilateral and occasional bilateral cases have been reported.^{4,16} Although they may be encountered in any part of the ovary, the medulla and hilum appear to be the most common sites. Histologically, they demonstrate either a cavernous, capillary, or mixed type with the cavernous type predominating,⁴ as in the present case, in contrast to haemangiomas in other parts of the body. Microscopically, they are composed of dilated, blood-filled, generally thin-walled vessels ranging from small to large size, lined by a single layer of flattened endothelial cells. The

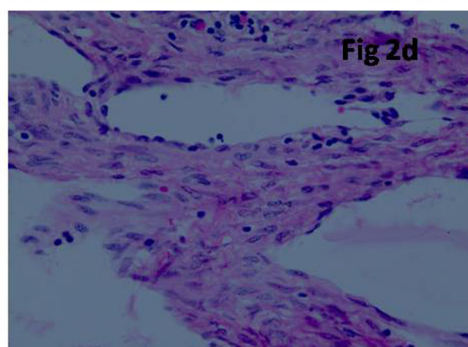
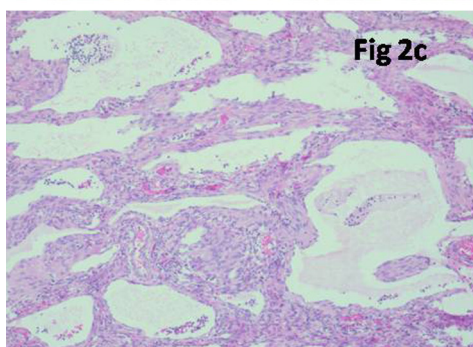
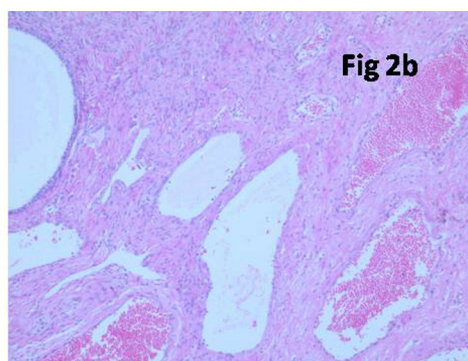
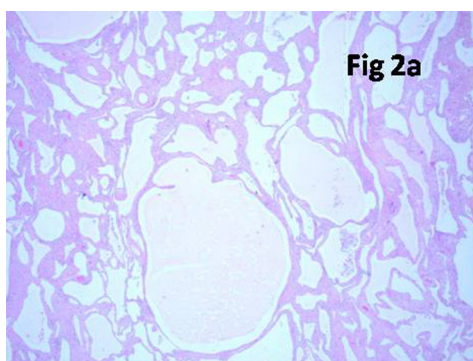


Fig. 2. Photomicrograph of the ovary showing numerous dilated thin walled vascular channels [2a Hematoxylin & Eosin stain 10X] some of which were filled with red blood cells. Adjacent area exhibits a follicle cyst [2b Hematoxylin & Eosin stain 10X]. Vascular spaces are lined by flattened endothelium [2c & d Hematoxylin & Eosin stain 40X].

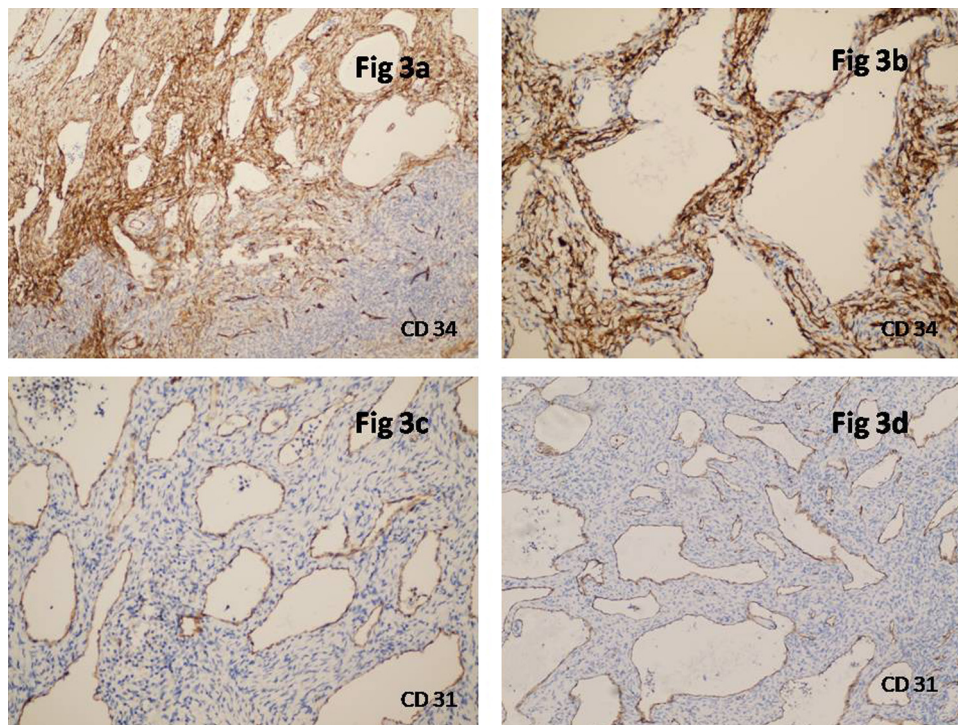


Fig. 3. Photomicrograph showing CD34 [3a & b 10X] and CD 31 [3c & d 10X] positivity of the lining cells of vascular spaces.

vessels may be haphazardly located or display a roughly lobular arrangement in a variable amount of connective tissue stroma in which inflammation, hemorrhage and hemosiderin deposits, can be detected. Extensive punctate calcification in cavernous haemangioma was reported by Kim et al.¹⁸ The present tumor was devoid of calcification probably because of early presentation and surgery.

Sometimes both preoperative findings and intra-operative structures can be confusing. It can be misdiagnosed as malignancy with preoperative imaging studies. The surgical approach differs in the diagnosis of haemangioma. Thus to avoid unnecessary radical surgery for a benign neoplasm, haemangioma should be kept in mind as a differential diagnosis of an ovarian mass before surgery. While the clinical differential diagnoses of ovarian haemangiomas include tubo-ovarian mass, twisted ovarian cyst, and chocolate cyst,⁵ the main pathological differential diagnoses are those of vascular proliferations, lymphangioma, and monodermal teratoma composed of a prominent vascular component. Haemangioma in the ovary must be differentiated from proliferations of dilated blood vessels of the ovarian hilar region.⁴ To define the lesion as a true hemangioma, a mass of vascular channels with minimal amounts of stroma should form a reasonably circumscribed lesion distinct from the remainder of the ovary. One of the main characteristics of these vessels is that they may be calcified or have thickened walls and narrowed lumina due to medial deposition of a hyaline, amyloid-like material.¹⁹ Lymphangioma, which was considered in the differential diagnosis of this case because of a similar morphological appearance, was excluded due to the absence of pale eosinophilic homogeneous material within the vascular channels. One of the controversial issues regarding the differential diagnosis involves distinguishing a monodermal teratoma having an angiomatous component from a pure haemangioma. Although vascular elements are not generally a component of ovarian teratomas, bilateral ovarian teratomas with a large hemangiomatous component have been reported in which the lesions were distinguished from a pure hemangioma by the presence of a focus of respiratory epithelium.²⁰

4. Conclusion

Haemangiomas of the ovary are very rare neoplasms with a wide age range and incidental discovery during operation or autopsy. These neoplasms should be considered in the differential diagnosis of a hemorrhagic ovarian lesion. Surgical extirpation of the involved areas is the treatment of choice. The risk of Kasabach and Merritt coagulopathy has to be considered in larger tumors, thus necessitating correct diagnosis and definitive surgical treatment.

Conflict of interest

There is no conflict of interest related to the work among the authors in this study.

Funding

The source of funding was institutional funds of Drs Tribedi & Roy Diagnostics Laboratory, Kolkata.

Ethical approval

Written informed consent was obtained from the patient for publication of this case report and accompanying images.

Authors contribution

BM and ARQ collected and analyzed the patient's data. SS and AR performed the gross examination. BM, SS; ARQ & SR performed the histological examination and prepared the manuscript. JM & AB interpreted the Immunohistochemical slides and reviewed the case. ARQ & SR have supervised all the work and final correction of the manuscript done by them. All the authors read and approved the final manuscript.

Acknowledgement

We would like to thank Dr. Ruby Sen for her kind assistance in this paper. The authors also gratefully acknowledge the assistance of the laboratory staffs of the Drs Tribedi & Roy Diagnostic Laboratory.

References

- Mirilas P, Georgiou G, Zevgolis G. Ovarian cavernous hemangioma in an 8-year-old girl. *Eur J Pediatr Surg* 1999;**9**:116–8.
- Kaneta Y, Nishino R, Asaoka K, Toyoshima K, Ito K, Kitai H. Ovarian hemangioma presenting as pseudo- Meigs' syndrome with elevated CA125. *J Obstet Gynaecol Res* 2003;**29**(June):132–5.
- Gücer F, Özyılmaz F, Balkanlı-Kaplan P, Mulayim N, Aydin O. Ovarian hemangioma presenting with hyperandrogenism and endometrial cancer: a case report. *Gynecol Oncol* 2004;**94**:821–4.
- Uppal S, Heller DS, Majmudar B. Ovarian hemangioma – report of three cases and review of the literature. *Arch Gynecol Obstet* 2004;**270**:1–5.
- Gupta R, Singh S, Nigam S, Khurana N. Benign vascular tumors of female genital tract. *Int J Gynecol Cancer* 2006;**16**:1195–200.
- Rodriguez MA. Hemangioma of the ovary in an 81 year old woman. *South Med J* 1979;**72**:503–4.
- Alverz M, Cerezo L. Ovarian cavernous haemangioma. *Arch Pathol Lab Med* 1986;**110**:77–8.
- Pethe VV, Chitale SV, Godbole RN, Bidaye SV. Hemangioma of the ovary – a case report and review of the literature. *Indian J Pathol Microbiol* 1991;**34**:290–2.
- Gehrig PA, Fowler WC, Lininger RA. Ovarian capillary hemangioma presenting as an adnexal mass with massive ascites and elevated CA-125. *Gynecol Oncol* 2000;**76**:130–2.
- Alvarez M, Cerezo L. Ovarian cavernous hemangioma. *Arch Pathol Lab Med* 1986;**110**:77–8.
- Carder PJ, Goulesbrough DR. Ovarian hemangiomas and stromal luteinization. Correspondence. *Histopathology* 1995;**26**:585–6.
- Grant JW, Millward-Sadler GH. Haemangioma of the ovary associated with endometrial hyperplasia – case report. *Br J Obstet Gynaecol* 1986;**193**:1166–8.
- Miliaras D, Papaemmanouil S, Blatzas G. Ovarian capillary hemangioma and stromal luteinization: a case study with hormonal receptor evaluation. *Eur J Gynaecol Oncol* 2001;**22**:369–71.
- Savargaonkar PR, Wells S, Graham I, Buckley CH. Ovarian hemangiomas and stromal luteinization. *Histopathology* 1994;**25**:185–8.
- Yamawaki T, Hirai Y, Takeshima N, Hasumi K. Ovarian hemangioma associated with concomitant stromal luteinization and ascites. *Gynecol Oncol* 1996;**61**:438–41.
- Lawhead RA, Copeland LJ, Edwards CL. Bilateral ovarian hemangiomas associated with diffuse abdominopelvic hemangiomatosis. *Obstet Gynecol* 1985;**65**:597–9.
- DiOrio J, Lowe LC. Hemangioma of the ovary in pregnancy. A case report. *J Reprod Med* 1980;**24**:232–4.
- Kim MY, Rha SE, Oh SN, Lee YJ, Jung ES, Byun JY. Ovarian cavernous hemangioma presenting as a heavily calcified adnexal mass. *Brit J Radiol* 2008;**81**:269–71.
- Clement PB. Histology of the ovary. In: Sternberg SS, editor. *Histology for pathologists*. 2nd ed. Philadelphia: Lippincott-Raven; 1997. p. 929–59.
- Feuerstein IM, Aronson BL, McCarthy EF. Bilateral ovarian cystic teratomata mimicking bilateral pure ovarian hemangiomata: case report. *Int J Gynecol Pathol* 1984;**3**:393–7.

Open Access

This article is published Open Access at sciedirect.com. It is distributed under the [IJSCR Supplemental terms and conditions](#), which permits unrestricted non commercial use, distribution, and reproduction in any medium, provided the original authors and source are credited.