

Available online at www.sciencedirect.com

ScienceDirect

journal homepage: www.elsevier.com/locate/radcr

Case Report

Breast implant-associated anaplastic large cell lymphoma with contralateral invasive lobular carcinoma ☆☆☆

Lisa Johnson, MD^{a,*}, Kathryn Lowry, MD^b, John Scheel, MD, PhD, MPH^b, Brian Mau, MD^c, Steven J. Rockoff, MD^d

^a University of Washington, Department of Radiology, 1959 N.E. Pacific St., Box 357115, Seattle, WA 98195-7115

^b Breast Imaging Section, Department of Radiology, University of Washington, Seattle Cancer Care Alliance, Seattle, WA

^c University of Washington, Department of Laboratory Medicine and Pathology, 1959 Seattle, WA

^d Sutter Health, Santa Rosa, CA

ARTICLE INFO

Article history:

Received 1 September 2020

Revised 8 September 2020

Accepted 9 September 2020

Keywords:

Breast implant

Breast implant-associated
anaplastic large cell lymphoma

Invasive lobular carcinoma

ABSTRACT

Breast implant-associated anaplastic large cell lymphoma (BIA-ALCL) is a rare type of T-cell lymphoma that arises in the setting of textured breast implants. In this case report, a 69-year-old woman with a remote history of right-sided invasive lobular carcinoma status post right mastectomy and bilateral breast reconstruction presents with spontaneous right breast swelling and pain, suspicious for implant rupture. Diagnostic MRI revealed a peri-implant fluid collection in the right breast and focal nonmass enhancement in the left breast. The patient was ultimately diagnosed with right-sided BIA-ALCL and left-sided invasive lobular carcinoma. Although intravenous gadolinium contrast is not needed to assess implant integrity, it can be used to evaluate for malignancy when the patient is at an increased risk for developing breast cancer. In this case, the use of contrast revealed the rare instance of a synchronous contralateral invasive lobular carcinoma. Despite the rarity of BIA-ALCL with an estimated incidence of 1:30,000 in women with textured implants, it is essential that radiologists include this entity in the differential in the appropriate clinical setting as surgical resection is curative if performed before the disease has spread.

© 2020 The Authors. Published by Elsevier Inc. on behalf of University of Washington.

This is an open access article under the CC BY-NC-ND license (<http://creativecommons.org/licenses/by-nc-nd/4.0/>)

☆ Disclosures: KPL reports a research grant from GE Healthcare, Inc. JRS reports a research grant from GE Healthcare, Inc.

☆☆ Statement of consent was not taken as no patient identifiers are present in this article.

* Corresponding author.

E-mail address: lisanoel@uw.edu (L. Johnson).

<https://doi.org/10.1016/j.radcr.2020.09.033>

1930-0433/© 2020 The Authors. Published by Elsevier Inc. on behalf of University of Washington. This is an open access article under the CC BY-NC-ND license (<http://creativecommons.org/licenses/by-nc-nd/4.0/>)

Case summary

A 69-year-old woman presented to the emergency department with sudden onset of right breast enlargement and pain over the course of a few days. The patient denied fever, skin changes, or any other infectious symptoms. She had a remote history of right breast invasive lobular carcinoma with treatment that included right mastectomy and bilateral breast reconstruction with unknown type of implants 15 years ago. A right breast ultrasound was subsequently performed in the emergency department, which showed fluid surrounding her right breast implant (Fig. 1). Initial sonographic and clinical findings were concerning for an implant rupture and a diagnostic MRI was recommended for further evaluation. MRI demonstrated intact bilateral silicone implants (double lumen on the right, single lumen on the left) with a large right-sided peri-implant fluid collection. Postcontrast images showed focal nonmass enhancement in the upper outer quadrant of the left breast (Fig. 2).

One week later, an ultrasound-guided fine needle aspiration of the right peri-implant fluid collection was performed, and cytopathologic examination revealed large atypical CD30+ cells compatible with breast-implant associated anaplastic large cell lymphoma (BIA-ALCL) (Fig. 3). A targeted ultrasound of the left breast revealed a suspicious mass corresponding to the area of focal nonmass enhancement

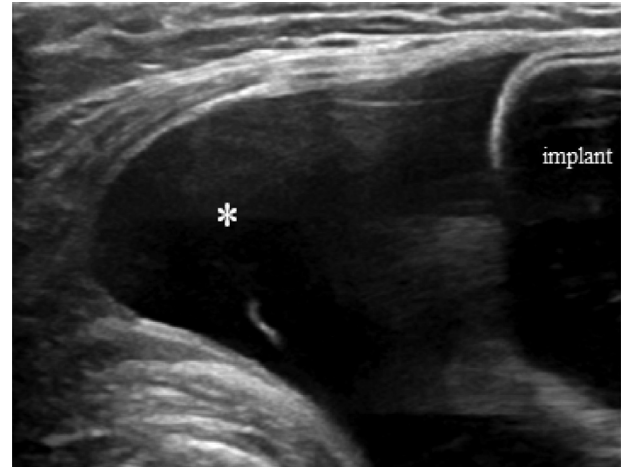


Fig. 1 – Targeted ultrasound of the right breast demonstrates a large fluid collection (asterisk) surrounding the breast implant.

on MRI (Fig. 4) and an ultrasound-guided core biopsy of this mass demonstrated synchronous invasive lobular carcinoma (Fig. 5).

Two months later, the patient underwent left-sided total mastectomy, left axillary lymph node dissection, and

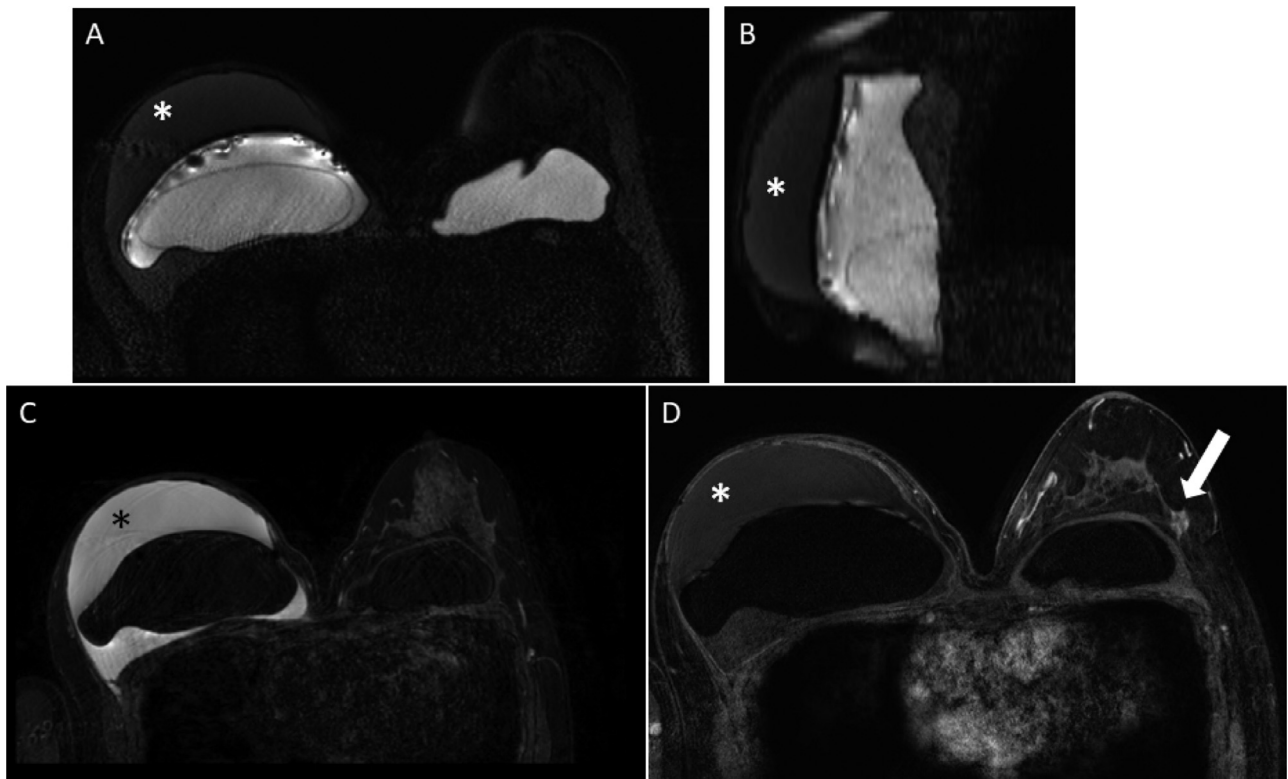


Fig. 2 – Bilateral breast MRI with (A) axial and (B) right breast sagittal silicone-sensitive images, (C) axial T2-weighted SPAIR image, and (D) axial T1-weighted fat-saturated postcontrast image. The patient had prior right mastectomy. There is an intact double-lumen silicone right breast implant and an intact single-lumen silicone left breast implant. A large peri-implant fluid collection is present on the right (asterisks) and there is focal nonmass enhancement in the left breast (arrow).

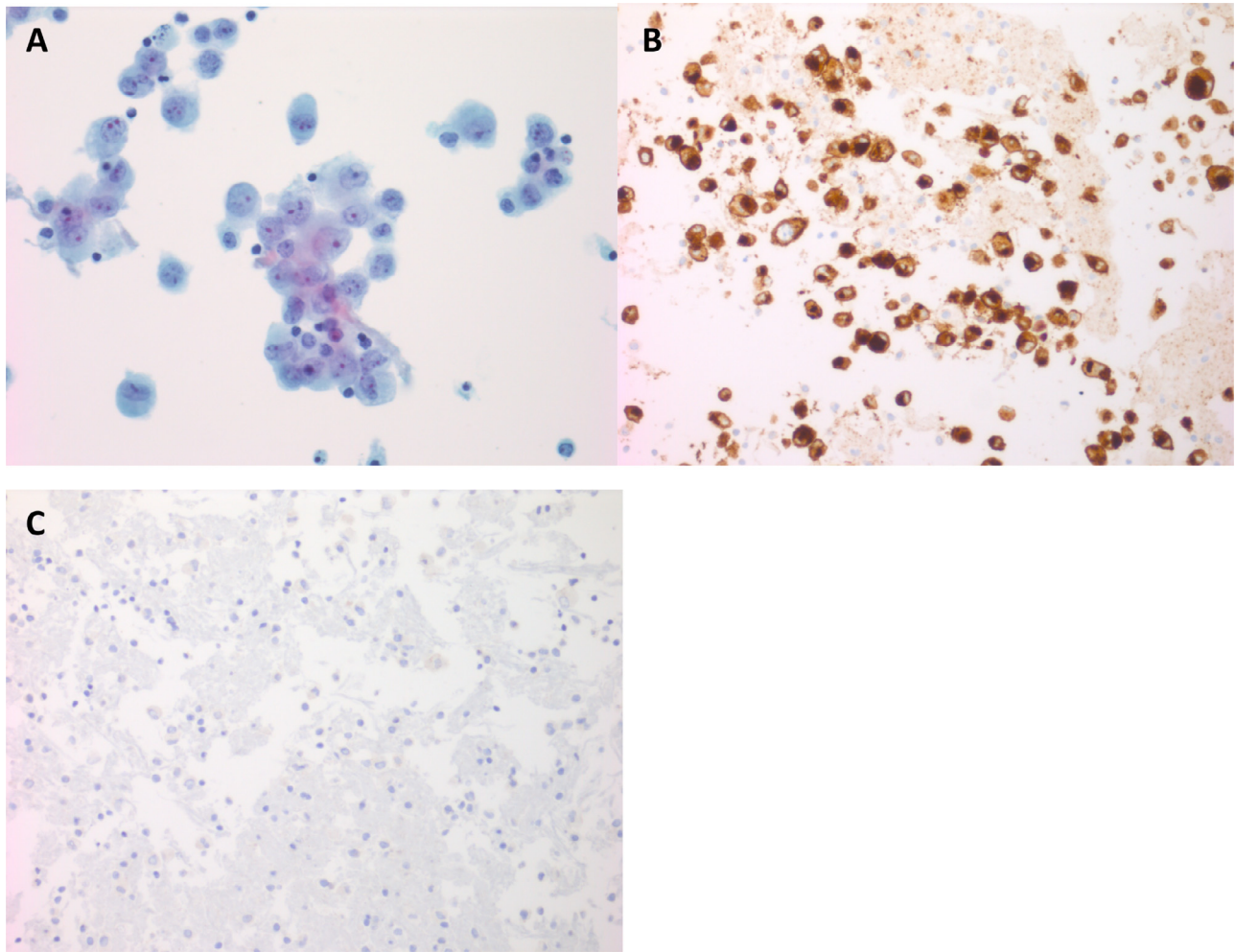


Fig. 3 – (A) Papanicolaou-stained cytologic preparation of the peri-implant fluid aspirate shows abundant large atypical cells with large pleomorphic nuclei and prominent nucleoli. **(B)** An immunohistochemical stain for CD30 demonstrates a strong membranous and perinuclear Golgi pattern of positivity in the neoplastic cells. **(C)** An immunohistochemistry stain for ALK is negative.

bilateral implant removal with capsulectomies (Fig. 6). Pathologic evaluation redemonstrated BIA-ALCL on the right and ER/PR+, HER2- ILC on the left with negative sentinel lymph nodes. Patient tolerated the surgery well and was started on endocrine therapy with letrozole for left breast invasive lobular carcinoma.

Diagnosis

Right breast: Breast implant-associated anaplastic large cell lymphoma.

Left breast: Invasive lobular carcinoma.

Image findings

The MRI demonstrates an intact right double-lumen silicone implant, characterized by the normal well-contoured inner wall merging with the outer wall posteriorly and silicone

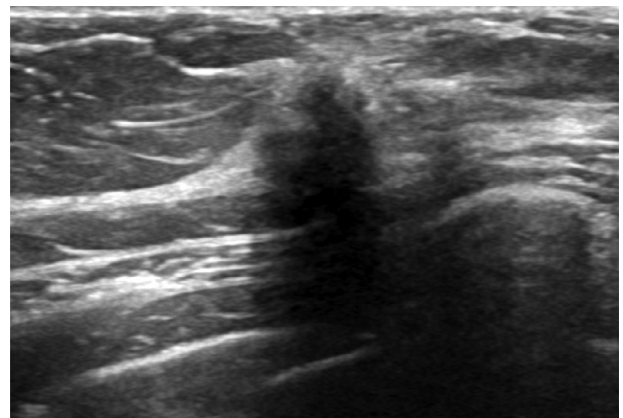


Fig. 4 – Targeted ultrasound of the left breast demonstrates a solid, irregular mass with indistinct margins in the upper outer quadrant, which corresponds to the focal area of nonmass enhancement on MRI.

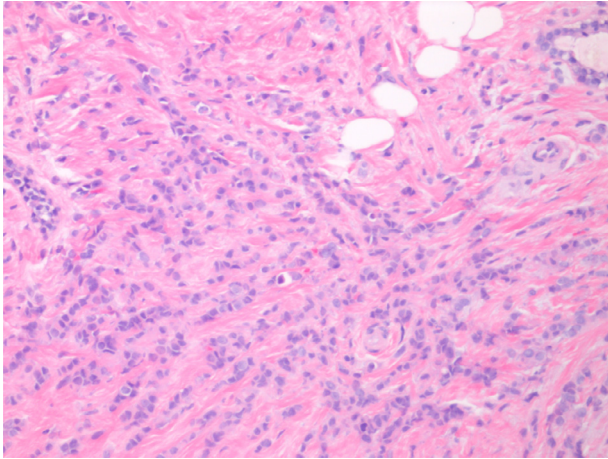


Fig. 5 – Hematoxylin and eosin stained histologic section of the core biopsy of the left breast lesion demonstrating invasive lobular carcinoma.

signal within both lumens. Surrounding the right breast implant there is a large peri-implant fluid collection that is hyperintense on T2-weighted images and hypointense on silicone-sensitive sequences. The fluid is confined by the fibrous capsule and has mass effect on the implant. There is also suspicious focal nonmass enhancement in the left breast at 2:00.

Discussion

BIA-ALCL is a rare T-cell lymphoma, distinct from primary breast lymphoma, which occurs in the setting of textured breast implants. There have been no confirmed cases of BIA-ALCL in the setting of smooth breast implants [1]. By imaging, BIA-ALCL can present as a peri-implant effusion or as

a discrete mass originating from the inner lining of the external implant fibrous capsule [2,3]. Clinically, patients with BIA-ALCL most commonly present with rapid onset of breast swelling due to a large, spontaneous peri-implant fluid collection, which occurs at least 1 year (and on average 9–11 years) following reconstructive or cosmetic implantation. Rarely, other presenting symptoms include skin changes, capsular contracture, and lymphadenopathy [2]. Patients with breast implants presenting with asymmetric breast enlargement or pain should first undergo a targeted ultrasound to evaluate for peri-implant effusion, new breast mass, and lymphadenopathy [3,4]. If the sonographic findings are inconclusive, MRI should be performed. Like ultrasound, MRI is highly sensitive for detecting peri-implant effusions, including loculated posterior collections, with the added benefit of implant integrity assessment [4].

In the absence of an ipsilateral breast mass or regional lymphadenopathy, initial work-up for spontaneous unilateral peri-implant effusion consists of an ultrasound-guided fine needle aspiration of the fluid for cytological analysis. At least 50 mL of fluid should be collected in order to perform anaplastic lymphoma kinase immunohistochemistry and flow cytometry for immunophenotyping, especially for CD30 cell surface protein, which is highly expressed in ALCL and other lymphoproliferative disorders [2,4]. All registered cases of BIA-ALCL have been CD30 positive and anaplastic lymphoma kinase negative [5].

The National Comprehensive Cancer Network guidelines for management of BIA-ALCL recommend implant removal with excision of any associated capsular mass and the surrounding fibrous capsule as the primary treatment for this disease. If the disease is localized to the capsule, surgery alone is considered curative. Approximately 5% of BIA-ALCL cases also have incidental lymphoma in the contralateral breast. Therefore, surgeons may consider removal of the contralateral implant. The patient presented in this case report underwent bilateral implant removal and capsulectomy as part of a left-sided mastectomy for the incidental

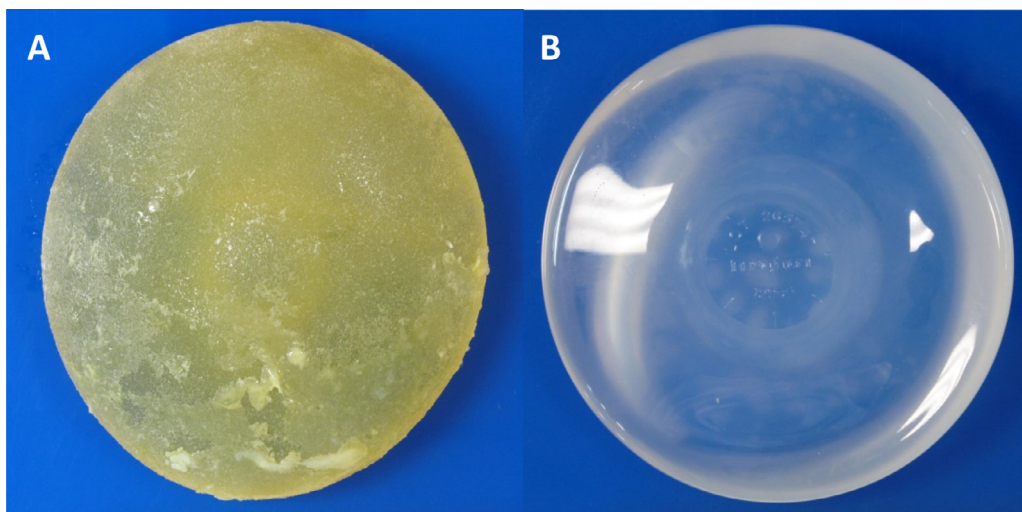


Fig. 6 – (A) Patient's textured right breast implant and (B) smooth left breast implant.

diagnosis of synchronous, contralateral ILC. For locally advanced or metastatic BIA-ALCL, a chemotherapy regimen analogous to the conventional treatment for systemic ALCL is recommended (ie, anthracycline-based chemotherapy). Any replacement implants should have a smooth surface [5].

The pathogenesis of BIA-ALCL is unknown. However, the strong association between ALCL and textured implants suggests that foreign biomaterial may induce a chronic inflammatory response, which in turn leads to neoplastic transformation. As some cases of BIA-ALCL can present with ectopic lymphoid tissue in the form of a discrete mass, lymphoid neogenesis as a result of chronic inflammation could also contribute [6]. Others have postulated that a chronic bacterial biofilm around the implant leads to chronic infection and inflammation with subsequent neoplastic transformation. This may occur in textured implants due to greater surface area compared to smooth implants, which may promote higher levels of bacterial film growth and increased T-cell lymphocyte infiltration and activation [7,8].

The suspected diagnosis of BIA-ALCL in this case was especially challenging because the implant type was unknown at the time of MRI. The double-lumen silicone implant is an uncommon implant type that can mimic intracapsular rupture of the more common single-lumen implant, which is a diagnostic consideration [9]. However, in an intracapsular implant rupture the peri-implant effusion should be isointense to silicone in all sequences, unlike in this case in which the fluid was hypointense to silicone on the silicone-selective sequence and hyperintense to silicone on fluid-sensitive sequence. Like an intracapsular rupture, the peri-implant fluid of early stage BIA-ALCL is contained by the fibrous capsule that occurs as a normal reaction to breast implants [2].

Currently, there is no recommended screening for BIA-ALCL in asymptomatic patients with textured implants. Implant removal is also not recommended in the absence of symptoms. According to the U.S. Food and Drug Administration and the American Society of Plastic Surgeons, all women with breast implants should continue their routine medical care and contact their surgeon if there are any changes around the breast implant including pain, swelling, or palpable mass [10].

In summary, BIA-ALCL must be considered in every case of a new onset peri-implant effusion not attributable to infection or trauma occurring one or more years following placement of a textured implant. When the clinical and imaging presentation is suggestive of BIA-ALCL, further evaluation with fluid aspiration and cytologic analysis is necessary to

facilitate prompt diagnosis and treatment of this rare, but curable disease [3,4].

REFERENCES

- [1] Brody GS, Deapen D, Taylor CR, Pinter-Brown L, House-Lightner SR, Andersen JS, et al. Anaplastic large cell lymphoma occurring in women with breast implants: analysis of 173 cases [published correction appears in *Plast Reconstr Surg*. 2015 Aug;136(2):426]. *Plast Reconstr Surg* 2015;135(3):695–705. doi:10.1097/PRS.0000000000001033.
- [2] Aladily TN, Medeiros LJ, Alayed K, Miranda RN. Breast implant-associated anaplastic large cell lymphoma: a newly recognized entity that needs further refinement of its definition. *Leuk Lymphoma* 2012;53(4):749–50. doi:10.3109/10428194.2011.639020.
- [3] Clemens MW, Jacobsen ED, Horwitz SM. 2019 NCCN consensus guidelines on the diagnosis and treatment of breast implant-associated anaplastic large cell lymphoma (BIA-ALCL). *Aesthet Surg J* 2019;39(Suppl_1):S3–S13. doi:10.1093/asj/sjy331.
- [4] Mitry MA, Sogani J, Sutton EJ, Kumar P, Horwitz S, Elmi A, et al. Rare cancer on the rise: an educational review of breast implant-associated anaplastic large cell lymphoma. *J Breast Imaging* 2020;2(4):398–407. doi:10.1093/jbi/wbaa041.
- [5] Kricheldorf J, Fallenberg EM, Solbach C, Gerber-Schäfer C, Rancsó C, Fritschen UV. Breast implant-associated lymphoma. *Dtsch Arztebl Int* 2018;115(38):628–35. doi:10.3238/arztebl.2018.0628.
- [6] George EV, Pharm J, Houston C, Al-Quran S, Brian G, Dong H, et al. Breast implant-associated ALK-negative anaplastic large cell lymphoma: a case report and discussion of possible pathogenesis. *Int J Clin Exp Pathol* 2013;6(8):1631–42.
- [7] Hu H, Johani K, Almatroudi A, Vickery K, Van Natta B, Kadin M, et al. Bacterial biofilm infection detected in breast implant-associated anaplastic large-cell lymphoma. *Plast Reconstr Surg* 2016;137(6):1659–69. doi:10.1097/PRS.0000000000002010.
- [8] Hu H, Jacombs A, Vickery K, Merten SL, Pennington DG, Deva AK. Chronic biofilm infection in breast implants is associated with an increased T-cell lymphocytic infiltrate: implications for breast implant-associated lymphoma. *Plast Reconstr Surg* 2015;135:319–29.
- [9] Kwek JW, Choi H, Ma J, Miller MJ. Gel-gel double-lumen silicone breast implant: mimic of intracapsular implant rupture. *AJR Am J Roentgenol* 2006;187(4):W436–7.
- [10] U.S. Food and Drug Administration (June 2020). Medical devices: questions and answers about breast implant associated anaplastic large cell lymphoma (BIA-ALCL). Retrieved from <https://www.fda.gov/medical-devices/implants-and-prosthetics/breast-implants>.