


The Usage of Curcumin as Chemopreventive Agent for Oral Squamous Cell Carcinoma: An Experimental Study on Sprague-Dawley Rat

Integrative Cancer Therapies
Volume 18: 1–7
© The Author(s) 2019
Article reuse guidelines:
sagepub.com/journals-permissions
DOI: 10.1177/1534735418822094
journals.sagepub.com/home/ict


Tantry Maulina, PhD¹, Retno Widayanti, BDS¹, Andri Hardianto, PhD¹,
Endang Sjamsudin, PhD¹, Bambang Pontjo, DrVetMed², and Harmas Yazid Yusuf, PhD¹

Abstract

Background: Curcumin, a natural herb that can be isolated from turmeric has been known for its therapeutic potential, including its chemopreventive potential, while heme oxygenase-1 (HO-1) is an antioxidant enzyme that can act as the biomarker for the progression of oral squamous cell carcinoma (OSCC). The current study investigated the efficacy of curcumin as a chemopreventive agent for OSCC by evaluating the immunoexpression of HO-1 at epithelial dysplasia stage. **Methods:** The current experimental study was conducted at the Veterinary Medicine Faculty, Bogor Agricultural Institute, Indonesia, using 40 Sprague-Dawley rats. All rats were randomly divided into 1 of 2 groups: the experimental group that was fed with standard rat food and curcumin and the control group that was fed with standard rat food without curcumin. At the beginning of the fifth week, every animal was wounded on the right buccal mucosa and was exposed to 0.5% 7,12-dimethylbenz(a)anthracene 3 times a week for 4 weeks in order to induce epithelial dysplasia of OSCC. On the ninth week, the right buccal mucosa was biopsied and the immunoexpression of HO-1 in both groups was compared and analyzed. **Results:** Sample examination revealed that all rats showed moderate to severe dysplastic epithelial dysplasia stage of OSCC, while a Mann-Whitney test showed that there was no significant ($P = .09$) difference found between the 2 groups for the immunoexpression of HO-1. **Conclusion:** With regard to its chemopreventive potential, the curcumin dose used in the study was not proven to be effective. Further study is of importance.

Keywords

curcumin, chemopreventive, oral squamous cell carcinoma, DMBA, HO-1

Submitted October 19, 2018; revised November 12, 2018; accepted December 7, 2018

Background

Cancer chemoprevention is defined as the use of natural or synthetic or biological or chemicals agents in order to reverse, suppress, or prevent carcinogenesis as well as the progression of carcinogenesis of tissue(s) that is at risk of developing invasive cancer.¹⁻⁴ It is conducted by addressing the cancer cell(s) with a single or multiple natural ingredients mixture such as fruits or vegetables, as well as chemical mixtures.³ It has become one of the most explored experimental topics due to the “failure” of conventional invasive therapy such as surgery, radiation, and chemotherapy with regard to preventing the

cancer from relapsing as well as from decreasing the risk of having another cancer developing in another location of the body.⁵ Cancer chemoprevention is carried out by using a low side effect and low toxicity level agent that has the ability to neutralize the carcinogenic potential of a certain material.⁴⁻⁶

¹Padjajaran University, Bandung, Indonesia

²Bogor Agricultural University, Bogor, Indonesia

Corresponding Author:

Tantry Maulina, Oral Surgery Department, Universitas Padjadjaran, Jl. Sekeloa Selatan No. 1, Bandung 40132, Indonesia.
Email: tantry.maulina@fkg.unpad.ac.id



One of the most promising natural-chemoprevention agents is curcumin. Curcumin (1,7-bis(4-hydroxy-3-methoxyphenyl)-1,6-heptadiene-3,5-dione, cm) or diferuloylmethane, is a polyphenol that can be found in *Curcuma* species, such as turmeric (*Curcuma longa*) and javanese ginger (*Curcuma xanthorrhiza*). Curcumin is composed of 77% bis- α , β -unsaturated β -diketone or diferuloylmethane or curcumin, 18% demethoxycurcumin, and 5% bisdemethoxycurcumin. Curcumin has been known for its multiple therapeutic potentials, such as antiseptic, analgesic, anti-inflammation, antioxidant, antiviral, antimalaria, and anti-tumor or anticarcinogenic.⁶⁻¹⁵

Oral squamous cell carcinoma, being one of the most common (oral) cancers,^{16,17} is a type of malignancy that develops from the epithelial layer of the oral cavity.²⁻⁵ Malignancies or cancers are caused by gene aberrations that lead to excessive proliferation, epithelial progressiveness, and dysplasia due to cell cycle irregularities and transcription resulting in impaired coordination of cell growth and differentiation. Therefore, the degree of epithelial dysplasia of the oral cavity may be an excellent predictor of the risk of oral cancer.⁵ The prevention of oral squamous cell carcinoma is essential due to its morbidity and mortality rate, not to mention the low survival rate and the risk of developing a second primary cancer and recurrence after surgery.^{2-5,18-20}

Anticarcinogenic activity shown by curcumin in various cancer studies revealed that it inhibited the formation of cancer by modulating the molecular pathways or factors that play a role in the initiation, promotion, and progression stage of carcinogenesis. In studies in which curcumin-containing diets were given to some animal models and carcinogen models, the development of oral squamous cell carcinoma was proven to be suppressed at several stages of carcinogenesis. Curcumin was also found to be effective in inhibiting the incidence of precancerous lesions of the oral cavity.

With regard to oral carcinoma, one of the potential biomarkers is the oxidative stress biomarker^{2,4} heme oxygenase-1 (HO-1). HO-1 is a stress response enzyme that catalyzes the heme and transforms it to biliverdin with the release of ferrous iron and carbon monoxide (CO) ions. HO-1 is also known as one of the main cell effectors for which the level will be elevated due to various physiological, endogenous, and exogenous stimuli. This 32-kDa microsomal enzyme is known to have a role in maintaining cellular homeostasis and is actively involved in natural cellular defense mechanisms by (1) reducing cellular oxidative injury (antioxidant); (2) preventing cell transformation into neoplastic form by excluding reactive oxygen species (ROS)-mediated carcinogenesis; (3) reducing inflammatory response (anti-inflammatory); and (4) decreasing the rate of apoptosis (anti-apoptosis).¹⁹⁻²³ The expression of HO-1 is known to be extremely high in highly dysplastic epithelium.²⁴

With regard to the effect of curcumin to HO-1, in an *in vitro* test of human hepatoma epithelial cells, curcumin was able to induce HO-1 by causing ROS, activating p38, and

inhibiting phosphatase.²⁵ It is known that curcumin has the ability to increase the cytoprotective effect of HO-1 enzyme through the activation of protein-1 activator transcription factor in renal epithelial cells.²⁶ Based on the relationship between curcumin and HO-1 level in previous cancer studies, an experimental study was conducted that aimed at evaluating the effect of curcumin as a chemopreventive agent for oral squamous cell carcinoma in the stage of epithelial dysplasia by evaluating the immunoeexpression of HO-1.

Methods

The current animal experimental study was conducted on 40 Sprague-Dawley rats at the Animal Teaching Hospital and Pathology Anatomy Laboratory of the Faculty of Veterinary Medicine, Bogor Agriculture Institute, Bogor, Indonesia. Prior to the start of the study, an ethical clearance from the Health Research Ethical Committee of the Bogor Agriculture Institute was obtained. All procedures performed were in accordance with the standards set forth in the Guide for the Care and Use of Laboratory Animals and Basel Declaration. All authors hereby confirmed that all legal and ethical aspect of the current study has been fulfilled prior to and during the study period. Ethical clearance (Number: 32-2017 ACUC RSHP FKH-IPB) was given by the Animal Medical Research Ethics Committee of Bogor Agricultural University, Indonesia.

Inclusion criteria of recruited animals consisted of healthy male rats, aged about 8 weeks old, weight about 200 to 300 mg, no anatomical abnormalities, previously quarantined for adaptation purposes (for 7 days prior to the start of the study), and fed with customized meals. Any rat that was declared unwell or deceased by the veterinarian was excluded from the study. All rats that fulfilled the inclusion criteria (40 rats) were then randomly assigned into one of the following groups: the control group, which did not receive any curcumin intervention, or the treatment group, which received 80 mg of curcumin intake per kilogram of body weight per day for 61 days. At the start of the study, each group was assigned 20 rats. During the quarantine period and experimental period of 61 days, all rats were kept in a customized cage where every cage was inhabited by 2 rats with identical body weight. Prior to the start of the quarantined period, all rats received Pes vaccination and went through an internal and external parasite elimination procedure.

Curcumin

Curcumin used in the current study was curcumin in the form of a capsule derived from *Curcuma domestica*, a turmeric herbal product marketed in Indonesia by a national company, Sidomuncul. Each capsule contained 100 mg of curcumin. Every morning after the rats had their morning meal, each rat in the treatment group received 80 mg of

curcumin (originally contained in the curcumin capsule) per kilogram body weight, by using a spoon straw. The customized rat meal comprised 30% crude protein, 4% crude fat, 5% crude fiber, 12% crude ash, 12% moisture, vitamin (A, D₃, E, B₁, B₂, B₅, and B₁₂), niacin, biotin, pantothenic, and choline. Each portion of the customized meal weighted 100 mg, and was given to all rats thrice a day.

Dimethyl-benz(a)anthracene (DMBA)

After 28 days of curcumin intervention, every rat in both groups was anesthetized by administering intramuscular ketamine hydrochloride and xylazine in abdominal muscle. The dose was 45 mg/kg body weight for ketamine hydrochloride and 0.35 mg/kg body weight for xylazine. The buccal mucosa of every rat was then scratched by using the needle of a 27-G syringe that contained 100 µg 0.5% DMBA 3 times a week for the next 4 weeks.

Euthanasia Procedure

On the 61st day, all rats were euthanized for the purpose of biopsy sample handling and a sample was excised from the right buccal mucosa. The euthanasia procedure was performed by injecting sodium pentobarbital as much as 180 mg/kg body weight by using 26-G syringe. Sodium pentobarbital has been recommended by the American Veterinary Medical Association as the drug of choice for euthanasia procedures in animals. The intraperitoneal injection was performed at the abdomen area by one certified veterinarian. Once the rat was injected, the veterinarian closely observed the rat for a period of 3 to 5 minutes. After 3 minutes, the veterinarian checked the rat's pulse rate by placing the index finger at the common carotid artery for 1 minute. Once a pulse was no longer detected, the veterinarian declared the time of death, and the excision of the right buccal mucosa was initiated.

Histopathological Examination

The cleaned tissue sample was inserted into a small pot containing 10% formalin buffer. The biopsy sample was then fixated by using formalin followed by fabricating the paraffin blocks. All paraffin blocks were then cut by using a rotary microtome with the thickness of 5 µm. Prepared preparations were then placed on the object glass for the staining of hematoxylin and eosin. Histopathologic assessment was performed on samples that showed histopathologic sign(s) of epithelial dysplasia of oral squamous cell carcinoma.

Immunohistochemical Examination

The next examination was the immunohistochemistry examination. The paraffin blocks were cut once again by

using a rotary microtome to a thickness of 5 µm. The preparations were then placed on the object glass prior to the application of HO-1 reagents. Immunohistochemical staining protocol was conducted by using the Star Trek Universal HRP Detection system (Biocare Medical, Pacheco, CA) with the Labeled Streptavidin Biotin immunoperoxide complex method. The primary antibody used in this particular protocol was the rabbit polyclonal antibody HO-1 (GeneTex, Irvine, CA).

Epithelial Dysplasia Assessment

The assessment criteria were tailored according to the research objectives. Each sample was assessed based on the diagnosis of epithelial dysplasia and the level of HO-1 immunoexpression. Epithelial dysplasia was assessed by using the following assessment criteria²⁷:

0: No sign of epithelial dysplasia.

1: Apparent signs of mild epithelial dysplasia, such as slight abnormalities of the nucleus, limited-minimal changes from basal to parabasal (1/3 basal) layers, maturation and stratification of the cell surface, no abnormal mitosis, keratosis, and chronic inflammation.

2: Apparent signs of moderate epithelial dysplasia with more variations on nuclear abnormalities. In this stage, nuclear abnormalities on the surface were accompanied by cell maturation and stratification; mitosis was prevalent at parabasal and intermediate layers but still within normal limits, or the emergence of undifferentiated cells from basal to mid layer of spinosum (2/3 basal) were apparent.

3: Severe dysplasia was detected. In this stage, mucosal epithelial abnormality has exceeded 2/3 of epithelial thickness or there were undifferentiated cells on more than 2/3 of the basal layer, nuclear abnormalities were clear, maturation loss happened on more than 2/3 of the epithelium, abnormal mitotic cells in the surface layer was detected, and there was possible appearance of keratinized squamous or horn pearls.

Heme oxygenase-1 Assessment

The immunohistochemical results of HO-1 were determined by using a semiquantitative approach that was based on cell distribution and was graded as following²⁸:

0: There was no sign of immunoreactive cell(s)

1: Immunoreactive cells appearance was less than 20%

2: Immunoreactive cells were between 20% and 50%

3: Immunoreactive cells were between 51% and 80%

4: Immunoreactive cells were more than 80%

The color intensity of HO-1 was rated as follows:

Table 1. Comparison of Level of Epithelial Dysplasia and HO-1 Immunoexpression Level Between Control and Experimental Groups.

	Epithelial Dysplasia			HO-1		
	Mild, n (%)	Moderate, n (%)	Severe, n (%)	Low, n (%)	Moderate, n (%)	High, n (%)
Control group	0 (0%)	8 (50%)	8 (50%)	3 (19%)	8 (50%)	5 (31%)
Experimental group	0 (0%)	13 (76%)	4 (24%)	4 (33%)	12 (71%)	1 (6%)
Total	0 (0%)	21 (64%)	12 (36%)	7 (21%)	20 (61%)	6 (18%)

Abbreviation: HO-1, heme oxygenase-1.

0: There was no coloration

1: A pale brown coloration was apparent or there was weak coloration intensity

2: A light brown coloration was apparent or there was moderate coloration intensity

3: A dark brown coloration was apparent or there was strong coloration intensity

The score cell distribution and color intensity were then converted in histoscore calculations and categorized into the following:

0: There was no sign of HO-1 expression

1-3: A low level of expression of HO-1

4-8: A moderate level of expression of HO-1

9-12: A high level of expression of HO-1

All data from both groups were then collected and compared through statistical analysis by using the Wilcoxon-Mann-Whitney test.

Results

During the 61 days of the experimental period, 7 rats were declared dead due to hypothermia. Out of the 33 Sprague-Dawley rats that survived the entire experimental period, 16 were those assigned in the control group and 17 were those in the experimental group. From these 2 groups, rats assigned in the control group showed more severe epithelial dysplasia (8 out of 16) compared with those in the experimental group (Table 1). As for HO-1 expression level, both groups showed that most of the rats showed moderate level of HO-1 expression (see Table 1). Epithelial dysplasia in the current study showed structural abnormalities found in the buccal mucosa, such as polymorphisms of the nucleus, abnormalities of the nucleus and cytoplasm, nuclear hyperchromatics due to cell activity, higher nuclear-cytoplasmic ratios, and greater epithelial stratification.

As mentioned earlier (see “Material and Methods”), there are 4 levels of epithelial dysplasia categorization. Despite the categorization, there were only 2 types of epithelial dysplasia found in the current study, the moderate and the severe types of epithelial dysplasia. The histopathological feature

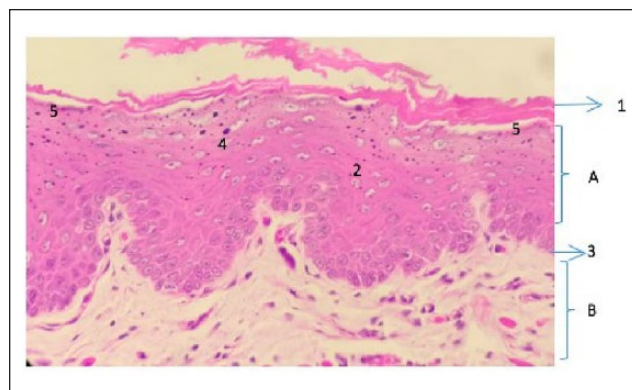


Figure 1. Moderate epithelial dysplasia on hematoxylin and eosin staining. The histopathological image of cell thickening (A) squamous epithelium, (B) connective tissue. (1) Hyperkeratin, (2) mitotic cells, (3) basal cell membrane thickening, (4) pigmentation of the nucleus, (5) maturation cells and stratification.

of moderate epithelial dysplasia (Figure 1) found in the current study were the nucleus abnormality that reached two thirds of basal epithelial layer, hyperkeratosis, cell maturation, and epithelial stratification on the upper surface, and mitotic activity on parabasal layer.

Another epithelial dysplasia representation found in the current study was that of severe epithelial dysplasia (Figure 2). Histopathologically, severe epithelial dysplasia stage in oral squamous cell carcinoma featured cytological abnormalities as well as structural abnormalities of the cells, hyperkeratosis, hyperplastic, abnormalities of the nucleus, and abnormalities of atypical cytological features. Some preparations also showed epithelial cells with horn pearls similar to those of oral squamous cell carcinoma.

As for the immunoexpression of HO-1 that served as the biomarker of the efficacy of curcumin as chemopreventive agent, there were 3 classes of HO-1 immunoexpression found in the current study (Figure 3a-c). Figure 3a showed a low level of immunoexpression of HO-1, of which the amount of immunoreactive cells were between 20% and 50% and weak intensity of coloration (pale brown) was apparent, while Figure 3b showed a moderate immunoexpression of HO-1 and Figure 3c showed a high level of

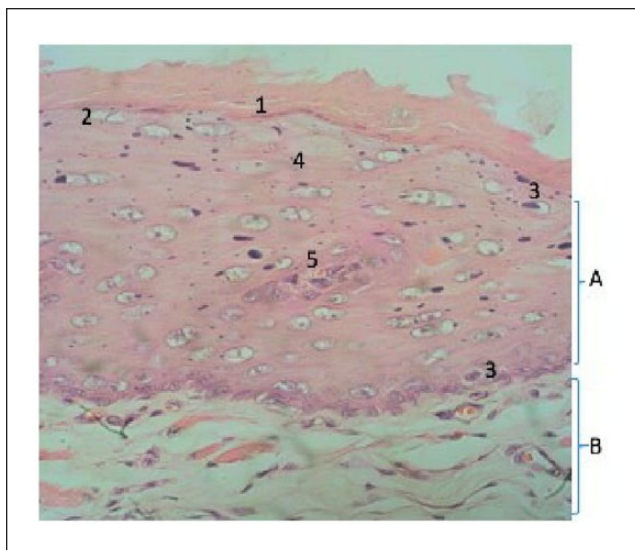


Figure 2. Severe epithelial dysplasia on hematoxylin and eosin staining. The entire layers of the epithelium underwent cytological changes: (A) squamous epithelium; (B) lamina propria. (1) Hyperkeratinized cells with nuclei, (2) abnormal mitosis on the surface layer, (3) hyperchromatic nuclei and ratio changes with cytoplasm, (3) keratinized epithelial on more than two thirds of epithelial horn pearl cells.

immunoexpression of HO-1. The most common level of HO-1 immunoexpression was the moderate immunoexpression of HO-1 (Table 1). Those in the experimental group (12 rats) showed more moderate level of HO-1 expression compared with those in the control group (8 rats).

In order to evaluate the efficacy of curcumin as a chemopreventive agent, the histoscore of both groups were compared and analyzed by using Wilcoxon-Mann-Whitney test with a P value set at $<.05$. Despite the effect seen in the level of epithelial dysplasia found in the experimental group, the difference found in both groups when it comes to HO-1 immunoexpression was not statistically significant ($P = .09$).

Discussion

In this experimental study, the application of 100 μg 0.5% DMBA 3 times a week for a period of 4 weeks on the buccal mucosa of Sprague-Dawley rats has effectively induced epithelial dysplasia in every rat that was included into the final count of the study (33 rats). This suggested that DMBA can be considered as a powerful tumor inducer. Chemical carcinogens such as DMBA have the ability to bind to the DNA and cause gene mutations that play a role in malignant transformation.² DMBA has been known for its ability to produce a carcinogenic dihydrodiol epoxide that plays a role in mediating neoplastic transformations by inducing DNA damage that will lead to the release of ROS, a

chemically reactive species that has the potential to cause serious damage to a normal healthy cell.¹⁸

Aside from the epithelial dysplasia, the findings of the current study included the immunoexpression of HO-1, a rate-limiting enzyme that has been positively correlated with the stage and prognosis of a disease. It is suggested that the oxidative stress as well as stimulation by growth factors will activate several signaling pathways along with the transcriptional factors such as Nrf2 or NF- κ B that, in the end, activate the HO-1 gene transcription in tumor cells.²⁰ The high rate of HO-1 immunoexpression level, therefore, indicates further stage of disease. And a decrease in its immunoexpression level is a sign of a suppressed disease development. With regard to this, the efficacy of curcumin as a chemopreventive agent can be evaluated by analyzing the immunoexpression of HO-1, which in the current study was exhibited by the low number of rats in the experimental group that expressed a high level of HO-1 immunoexpression compared with those in the control group, indicating the efficacy of curcumin in inhibiting HO-1 immunoexpression. This particular result of the current study might be due to the fact that curcumin is a natural ingredient that can actively interact with intra- as well as extracellular components that hold active roles in cancer initiation along with cancer progression.¹⁵ Curcumin interaction with HO-1 expression has been documented in previous studies.^{29,30} In a study conducted by Schwer et al,²⁹ the interaction between curcumin administration and HO-1 level and the effects on proliferation of pancreatic stellate cells (PSCs) revealed that HO-1 expression as well as HO activity were significantly increased by the administration of curcumin. It was further revealed that HO-1 mediates the inhibitory effect of curcumin on PSC proliferation. PSC itself has been known for its role in the development of pancreatic fibrosis, one of the common features of pancreatic cancer.

Despite its well-known therapeutic potentials and its apparent effect on HO-1 immunoexpression rate, an oral daily dose of 80 mg curcumin per kilogram body weight used in the current study did not significantly inhibit the progression of the DMBA-induced epithelial dysplasia when both groups were compared. This particular result of the study was not in line with a previous study conducted by Manoharan et al³¹ about the efficacy of curcumin as chemopreventive agent. In that study, curcumin being given daily for 80 mg per kilogram body weight was proven to be effective in inhibiting the progression of induced oral squamous cell carcinoma in a hamster. Yet, another study by Perrone et al¹⁴ suggested that curcumin has the potential to suppress specific protein 1 activation and therefore is unable to prevent cancer formation, migration, and progression.

These rather inconclusive results of curcumin efficacy as chemopreventive agents might be due to the low oral bioavailability of curcumin, which lead to the unclear optimum dose in treating various disease. Concentrations of

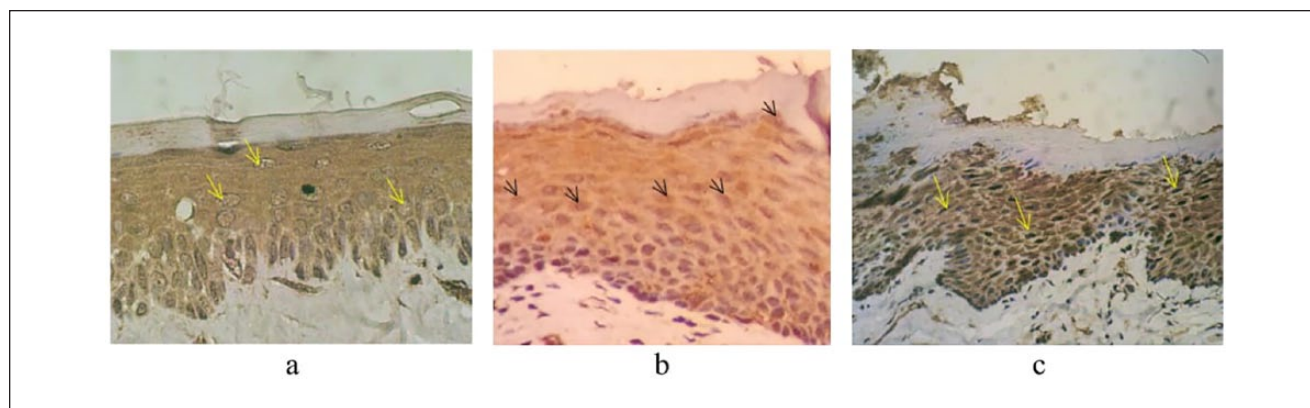


Figure 3. The level heme oxygenase-1 expression: (a) slightly positive with the appearance of pale brown cell (arrow); (b) moderately positive with the appearance of light brown cell (arrow); (c) strongly positive with the appearance of dark brown cell (arrow).

curcumin in human or animal tissue compared with cell culture conditions remain unknown. Although the use of piperine (a black pepper component) to strengthen its bioavailability has been suggested,³¹ consistent results regarding the optimum and effective dose of curcumin still remains an issue. Another study about the dosage of curcumin showed that despite the fact that low concentrations of curcumin may induce antioxidant effects, higher concentration of curcumin may increase cellular ROS levels.³² Last but not least, with regard to the findings of the current study, the insignificant result might be caused by the short period of curcumin administration. A longer period of curcumin administration accompanied with different doses of curcumin being trialed might exhibit different findings.

Conclusion

Despite the apparent effect of curcumin on the epithelial dysplasia level, the results of the current study showed that the chemopreventive potential of curcumin was not proven to be statistically significant. Yet, as the particular study was performed in rats, future study exploring the potential(s) of curcumin in humans might provide additional and different insights. To conclude, the result(s) of this experimental study indicated the importance of further study exploring the therapeutic potentials of curcumin in general, and its chemopreventive potential in particular, both in animal and human participants.

Authors' Note

All data obtained in the current study are available from the corresponding author on reasonable request.

Acknowledgments

The authors would also like to acknowledge the staff of the Animal Teaching Hospital and Pathology Anatomy Laboratorium of the

Faculty of Veterinary Medicine, Bogor Agriculture Institute, Bogor, Indonesia, for their kind assistance during the research period.

Author Contributions

All authors equally contributed to the completion of the current manuscript. RW and AH acted as the field researcher and contributed in the data analysis process; ES, HYY, and BP performed the statistical analysis and contributed in manuscript writing; and TM contributed significantly on manuscript writing as well as data analysis.

Declaration of Conflicting Interests

The author(s) declared no potential conflicts of interest with respect to the research, authorship, and/or publication of this article.

Funding

The author(s) disclosed receipt of the following financial support for the research, authorship, and/or publication of this article: The authors would like to acknowledge the University of Padjadjaran for funding the study through the Academic Leadership Grant.

References

1. Tsao AS, Kim ES, Hong WK. Chemoprevention of cancer. *CA Cancer J Clin.* 2004;54:150-180.
2. Tanaka T, Ishigamori R. Understanding carcinogenesis for fighting oral cancer. *J Oncol.* 2011;2011:603740.
3. Baliga KA, Kini R, Naik V, Kini S. Chemopreventive agents: its role in oral cancer prevention. *Int J Adv Health Sci.* 2015;2:22-28.
4. Tanaka T, Tanaka M, Tanaka T. Oral carcinogenesis and oral cancer chemoprevention: a review. *Pathol Res Int.* 2011;2011:431246.
5. Foy JP, Bertolus C, William WN Jr, Saintingny P. Oral premalignancy: the roles of early detection and chemoprevention. *Otolaryngol Clin North Am.* 2013;46:579-597.

6. Duvoix A, Blasius R, Delhalle S, et al. Chemopreventive and therapeutic effects of curcumin. *Cancer Lett.* 2005;223:181-190.
7. Mullaicharam AR, Maheswaran A. Pharmacological effects of curcumin. *Int J Nutr Pharmacol Neurol Dis.* 2012;2:92-99.
8. Anand P, Sundaram C, Jhurani S, Kunnumakkara AB, Anggarwal BB. Curcumin and cancer: an “old-age” disease with an “age-old” solution. *Cancer Lett.* 2008;267:133-164.
9. Zinoveva VN, Spasov AA. Mechanisms of the anticancer effects of plant polyphenols. I. Blockade of initiation of carcinogenesis. *Biochem Moscow Suppl Ser B.* 2011;5:113-123.
10. Rahmani AH, Al Zohairy MA, Aly SM, Khan MA. Curcumin: a potential candidate in prevention of via modulation of molecular pathways. *Biomed Res Int.* 2014;2014:761608.
11. Baumeister P, Reiter M, Harréus U. Curcumin and other polyphenolic compounds in head and neck cancer chemoprevention. *Oxidative Med Cellular Longevity.* 2012;2012:902716.
12. Wilken R, Veena MS, Wang MR, Srivatsan ES. Curcumin: a review of anti-cancer properties and therapeutic activity in head and neck squamous cell carcinoma. *Mol Cancer.* 2011;10:12.
13. Gupta SC, Patchva S, Anggarwal BB. Therapeutic roles of curcumin: lessons learned from clinical trials. *AAPS J.* 2013;15:195-218.
14. Perrone D, Ardito F, Giannatempo G, et al. Biological and therapeutic activities, and anticancer properties of curcumin. *Exp Ther Med.* 2015;10:1615-1623.
15. Shanmugam MK, Rane G, Kanchi MM, et al. The multifaceted role of curcumin in cancer prevention and treatment. *Molecules.* 2015;20:2728-2769.
16. Ng JH, Iyer NG, Tan MH, Edgren G. Changing epidemiology of oral squamous cell carcinoma of the tongue: a global study. *Head Neck.* 2017;39:297-304.
17. Selvamani M, Yamunadevi A, Basandi PS, Madhushankari GS. Prevalence of oral squamous cell carcinoma of tongue in and around Davangere, Karnataka, India: a retrospective study over 13 years. *J Pharm Bioallied Sci.* 2015;7(suppl 2):491-494.
18. Markopoulos AK. Current aspects on oral squamous cell carcinoma. *Open Dent J.* 2012;6:126-130.
19. Was H, Dulak J, Jozkowics A. Heme oxygenase-1 in tumor biology and therapy. *Curr Drug Targets.* 2010;11:1551-1570.
20. Chau LY. Heme oxygenase-1: emerging target of cancer therapy. *J Biomed Sci.* 2015;22:22.
21. Yadav B, Greish K. Selective inhibition of hemeoxygenase-1 as a novel therapeutic target for anticancer treatment. *J Nanomed Nanotechnol.* 2011;S4:0005.
22. Furfaro AL, Traverso N, Domenicotti C, et al. The Nrf2/HO-1 axis in cancer cell growth and chemoresistance. *Oral Med Cell Longev.* 2016;2016:1958174.
23. Gandini NA, Fermento MA, Salomón DG, et al. Nuclear localization of heme oxygenase-1 is associated with tumor progression of head and neck squamous cell carcinomas. *Exp Mol Pathol.* 2012;93:237-245.
24. Lee SS, Yang SF, Tsai CH, Chou MC, Chou MY, Chang YC. Upregulation of heme oxygenase-1 expression in areca-quid-chewing-associated oral squamous cell carcinoma. *J Formos Med Assoc.* 2008;107:355-363.
25. McNally SJ, Harrison EM, Ross JA, Garden JA, Wigmore SJ. Curcumin induces heme oxygenase 1 through generation of reactive oxygen species, p38 activation and phosphatase inhibition. *Int J Mol Med.* 2007;19:165-172.
26. Mimche PN, Taramelli D, Vivas L. The plant-based immunomodulator curcumin as a potential candidate for the development of an adjunctive therapy for cerebral malaria. *Malaria J.* 2011;10(suppl 1):S10.
27. Geetha KM, Leeky M, Narayan TV, Sadhana S, Saleha J. Grading of oral epithelial dysplasia: points to ponder. *J Oral Maxillofac Pathol.* 2016;19:198-204.
28. Fedchenko N, Reifenrath J. Different approaches for interpretation and reporting of immunohistochemistry analysis results in the bone tissue—a review. *Diagn Pathol.* 2014;29:221.
29. Schwer CI, Guerrero AM, Humar M, et al. Heme oxygenase-1 inhibits the proliferation of pancreatic stellate cells by repression of the extracellular signal-regulated kinase1/2 pathway. *J Pharmacol Exp Ther.* 2008;327:863-871.
30. Nitti M, Piras S, Marinari UM, Pronzato MA, Furfaro AL. HO-1 induction in cancer progression: a matter of cell adaptation. *Antioxidants (Basel).* 2017;6:E29.
31. Manoharan S, Balakrishnan S, Menon VP, Alias LM, reena AR. Chemopreventive efficacy of curcumin and piperine during 7,12-dimethylbenz[a]anthracene-induced hamster buccal pouch carcinogenesis. *Singapore Med J.* 2009;50:139-146.
32. Burgos-Morón E, Calderón-Montaña JM, Salvador J, Robies A, López-Lázaro. The dark side of curcumin. *Int J Cancer.* 2010;126:1771-1775.