

Resolution of massive left atrial appendage thrombi with rivaroxaban before balloon mitral commissurotomy in severe mitral stenosis

A case report and literature review

Yuechun Li, MD, Jiafeng Lin, MD, Chen Peng, MD*

Abstract

Rationale: Data on nonvitamin K antagonist oral anticoagulant being used for the treatment of LAA thrombi are limited only in nonvalvular atrial fibrillation. There are no data on the antithrombotic efficacy and safety of nonvitamin K antagonist oral anticoagulant in the resolution of left atrial appendage (LAA) thrombi in patients with rheumatic mitral stenosis.

Patient concerns: A 49-year-old woman with known rheumatic mitral stenosis and atrial fibrillation was referred for percutaneous transvenous mitral commissurotomy because of progressive dyspnea on exertion over a period of 3 months.

Diagnoses: Transesophageal echocardiography (TEE) demonstrated a large LAA thrombus protruding into left atria cavity before the procedure.

Interventions: Direct factor Xa (FXa) inhibitor rivaroxaban (20 mg/d) was started for the patient. After 3 weeks of rivaroxaban treatment TEE showed a relevantly decreased thrombus size, and a complete thrombus resolution was achieved after 5 weeks of anticoagulant therapy with the FXa inhibitor.

Outcomes: To the best of our knowledge, this is the first documented case of large LAA thrombus resolution with nonvitamin K antagonist oral anticoagulant in severe mitral stenosis, and in which percutaneous transvenous mitral commissurotomy was performed subsequently.

Lessons: The report indicated that rivaroxaban could be a therapeutic option for mitral stenosis patients with LAA thrombus. Further study is required before the routine use of rivaroxaban in patients with rheumatic mitral stenosis and atrial fibrillation.

Abbreviations: FXa = factor Xa, INR = international normalized ratio, LAA = left atrial appendage, NOAC = non-VKA oral anticoagulant, TEE = transesophageal echocardiography.

Keywords: left atrial appendage thrombus, nonvitamin K antagonist oral anticoagulant, rheumatic mitral stenosis, valvular atrial fibrillation

1. Introduction

Valvular heart disease, independent of the underlying cardiac rhythm, is associated with a high risk of thromboembolic events.^[1] The coexistence of atrial fibrillation and rheumatic mitral stenosis

is associated with a higher risk of thromboembolism.^[2] The presence of left atrial appendage (LAA) thrombi is a common finding in rheumatic mitral stenosis.^[3] The majority of embolisms associated with atrial fibrillation are from the LAA.^[4] Non-VKA oral anticoagulants (NOAC) are recommended for prevention of stroke in patients with nonvalvular atrial fibrillation. Data on NOAC being used for the treatment of LAA thrombi are limited only in nonvalvular atrial fibrillation.^[5] There are no data on the antithrombotic efficacy and safety of direct factor Xa (FXa) inhibitor rivaroxaban in the resolution of LAA thrombi in patients with rheumatic mitral stenosis and atrial fibrillation.

Here, we report a case in which rivaroxaban was effective in resolving LAA thrombi in a patient with severe rheumatic mitral stenosis and atrial fibrillation.

2. Case presentation

A 49-year-old woman with known rheumatic mitral stenosis was referred for percutaneous transvenous mitral commissurotomy because of progressive dyspnea on exertion over a period of 3 months. One year ago, she suffered a cerebral vascular accident and received warfarin therapy, but stopped by herself after just 1 month due to the need for frequent international normalized ratio (INR) measurements. On admission, physical examination showed mild pulmonary rales at the bases, an opening snap, and a diastolic rumbling murmur at the cardiac apex. Her

Editor: Lin Yuo-Chun.

Consent statement: Ethical approval was obtained from the Ethics Committee of the Second Affiliated Hospital of Wenzhou Medical University. Written informed consent was obtained from the patients for publication of this case report and any accompanying images.

The authors have no conflicts of interest to disclose.

Department of Cardiology, Second Affiliated Hospital of Wenzhou Medical University, Wenzhou, Zhejiang, China.

* Correspondence: Chen Peng, 109 Xueyuan Road, Wenzhou, Zhejiang, China (e-mail: chenpeng_wzmc@sina.com).

Copyright © 2016 the Author(s). Published by Wolters Kluwer Health, Inc. All rights reserved.

This is an open access article distributed under the terms of the Creative Commons Attribution-Non Commercial-No Derivatives License 4.0 (CCBY-NC-ND), where it is permissible to download and share the work provided it is properly cited. The work cannot be changed in any way or used commercially without permission from the journal.

Medicine (2016) 95:49(e5577)

Received: 13 October 2016 / Received in final form: 30 October 2016 /

Accepted: 4 November 2016

<http://dx.doi.org/10.1097/MD.0000000000005577>

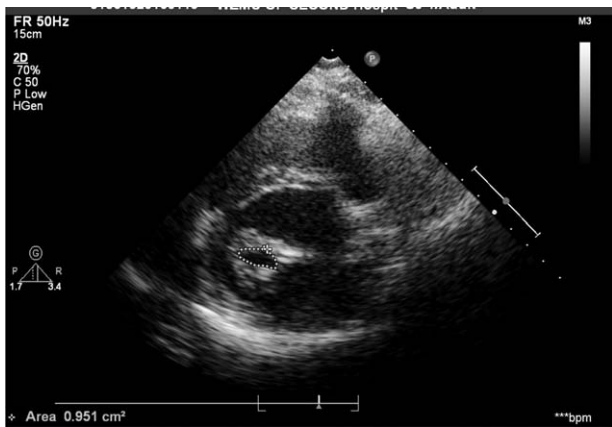


Figure 1. Two-dimensional echocardiography showing severe mitral stenosis with a calculated mitral valve area of 0.95 cm².

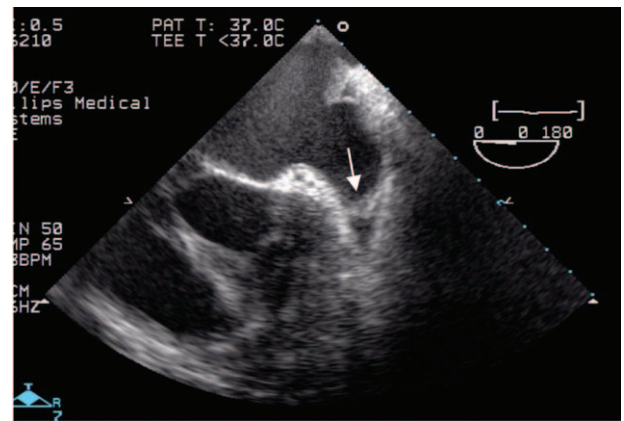


Figure 3. Transesophageal echocardiography showing decreased thrombus formation after 3 weeks of rivaroxaban treatment (arrow).

electrocardiogram showed atrial fibrillation at 85 beats/min. Transthoracic echocardiography revealed severe mitral stenosis with a calculated mitral valve area of 0.95 cm² (Fig. 1), a mean diastolic transmitral pressure gradient of 14 mm Hg, and mild mitral regurgitation. Transesophageal echocardiography (TEE) demonstrated large LAA thrombi protruding into left atria cavity (Fig. 2). Warfarin was suggested for the patient to ensure the LAA thrombus resolution. However, the patient strongly declined the drug therapy because of its inconvenience. Therefore, it was decided to initiate the FXa inhibitor rivaroxaban, dosed with 20 mg once daily. After 3 weeks of rivaroxaban treatment TEE showed a relevantly decreased thrombus size (Fig. 3), and a complete thrombus resolution was achieved after 5 weeks of anticoagulant therapy with the FXa inhibitor (Fig. 4), which was confirmed by 3-dimensional reconstructed image (Fig. 5). There was a slight prolongation in PT (from 14.5 to 15.9 seconds) and INR (from 1.04 to 1.33) after 5 weeks of rivaroxaban treatment. Finally, she successfully underwent percutaneous transvenous mitral commissurotomy without clinical signs of cardiac embolism. The mitral valve area increased from 0.9 to 1.9 cm². She was then discharged on rivaroxaban. During the 6-month follow-up, the patient remained clinically free of symptoms, without any thromboembolic events or bleeding complications.

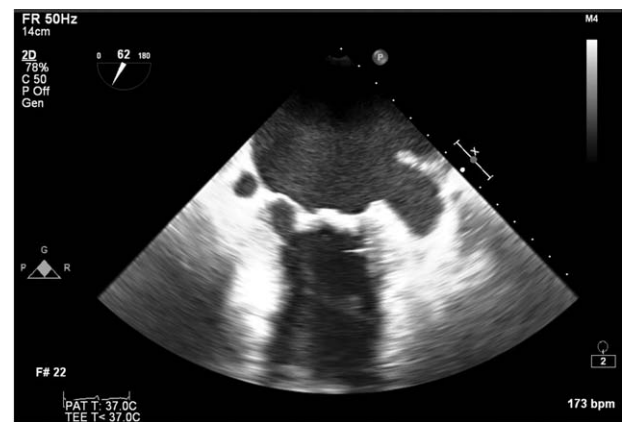


Figure 4. Transesophageal echocardiography showing complete resolution of the thrombi after 5 weeks of rivaroxaban treatment.

3. Discussion

To the best of our knowledge, this is the first documented case of LAA thrombi resolution with NOAC in severe mitral stenosis, and in which percutaneous transvenous mitral commissurotomy was performed subsequently.

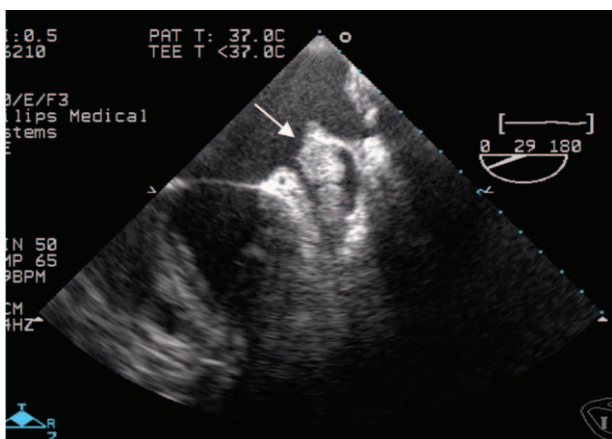


Figure 2. Transesophageal echocardiography showing large left atrial appendage thrombi protruding into left atria cavity (arrow).

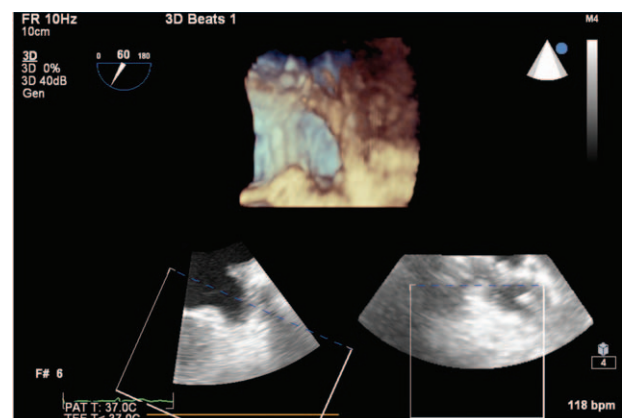


Figure 5. Complete thrombus resolution was confirmed by 3-dimensional reconstructed image.

Table 1**Cases on Non-VKA oral anticoagulants being used for the treatment of left atrial thrombus.**

Study	Pt age (Y) and sex	Nonvalvular AF	Left atrial thrombus	Treatment	Treatment length, d	Major bleeding	Thromboembolic complication	Outcome
Vidal and Vanerio ^[7]	59, F	Yes	LAA thrombus	Dabigatran 150 mg bid	50	No	No	Resolution
Takasugi et al ^[8]	81, F	Yes	LAA thrombus	Rivaroxaban 10 mg qd	35	No	No	Resolution
	75, M				10			
	75, M				19			
Hammerstingl et al ^[9]	64, M	Yes	LAA thrombus	Rivaroxaban 15 mg qd	42	No	No	Resolution
Morita et al ^[10]	72, F	Yes	LA thrombus	Dabigatran 150 mg bid	120	No	No	Resolution
Kawakami et al ^[11]	72, M	Yes	LAA thrombus	Apixaban 5 mg bid	16	No	No	Resolution
Dobashi et al ^[12]	86, M	Yes	left atrium thrombus	Apixaban 2.5 mg bid	77	No	No	Reduced thrombus
Ohyagi et al ^[13]	55, M	Yes	LAA thrombus	Apixaban 5 mg bid	12	No	Embolic stroke	Resolution
Freixa et al ^[14]	61, M	Yes	LAAO device thrombosis	Apixaban 5 mg bid	180	No	No	Resolution
Eftekhari et al ^[15]	63, M	Yes	LAA thrombus	Apixaban 5 mg bid	5	No	Embolic stroke	Dead
Lee and Han ^[16]	78, F	Yes	LAA thrombus	Apixaban 5 mg bid	42	No	No	Resolution
	79, F				35			
Miwa et al ^[17]	63, M	Yes	LAA thrombus	Apixaban 5 mg bid	150	No	No	Resolution
Piotrowski et al ^[18]	45, M	Yes	LAA thrombus	Rivaroxaban 15 mg bid	56	No	No	Resolution
Lip et al ^[5]	69.6 ± 11.0, M/F (prospective study, n = 53)	Yes	LAA or LA thrombus	Rivaroxaban 20 mg qd	42	No	No	41.5% Resolution; 60.4% Resolved or reduced thrombus

AF = atrial fibrillation, F = female, LA = left atrium, LAA = left atrial appendage, LAAO = Left atrial appendage occlusion, M = male, Pt = patient, Y = years.

Percutaneous transvenous mitral commissurotomy was an effective and safe therapy for severe mitral stenosis, but the presence of LAA thrombus was a contraindication to this procedure because of the risk for embolism, when catheters and wires are manipulated in the left atrium.^[3,6] Resolution of LAA thrombus with vitamin K antagonist has been previously reported in mitral stenosis, and it is suggested that percutaneous transvenous mitral commissurotomy can be attempted after complete resolution of LAA thrombus by oral anticoagulation.^[3,6] Compared with nonvalvular atrial fibrillation, the longer duration of warfarin treatment was required to resolve LAA thrombus in mitral stenosis because of the highly thrombogenic environment of the LAA in mitral stenosis.^[6]

Data on NOAC being used for the treatment of LAA thrombus are limited only in nonvalvular atrial fibrillation, and these data mainly consist of case reports.^[5,7-18] From 2012 to 2016, a total of 13 studies^[5,7-18] reported the use of NOACs for the resolution of left atrial or LAA thrombus in patients with nonvalvular atrial fibrillation, which generally indicated beneficial results (Table 1). Rivaroxaban, a potent and highly selective oral, direct FXa inhibitor, may offer some benefits in the relative efficacy, safety, and convenience as well as rapid onset of therapeutic anticoagulation when LAA thrombus is found.^[19] FXa inhibitor inhibits the conversion of prothrombin to thrombin and blocks the generation of thrombin. By suppressing thrombin production, FXa inhibitor resulted in a looser clot to form that is more sensitive to fibrinolytic enzymes.^[8,20] Therefore, the possible cause of the LAA thrombus resolution after treatment with FXa inhibitor is a relative predominance of the plasma fibrinolytic activity over the thrombin activity.^[21] In a case report on 3 patients with nonvalvular atrial fibrillation-related stroke and LAA thrombus detected by TEE, disappearance of thrombi after 1 to 5 weeks of rivaroxaban treatment (10 mg/d) without recurrent stroke was demonstrated by TEE.^[8] Hammerstingl et al^[9] reported rivaroxaban (15 mg/d) resolved LAA thrombus in a patient with ischemic cardiomyopathy with severely impaired left ventricular function, and chronic kidney disease. Piotrowski

et al^[18] also reported the use of rivaroxaban twice daily was effective in dissolving LAA thrombus. A prospective, multicenter study showed that resolved or reduced thrombus was evident for treatment of LAA thrombi by rivaroxaban in patients with nonvalvular atrial fibrillation.^[5] In the present study, massive LAA thrombi were completely dissolved by the treatment of rivaroxaban in the patient with valvular atrial fibrillation. This is the first report documenting LAA thrombi resolution with NOAC in valvular atrial fibrillation. Many case reports found similarly favorable outcomes in patients with LAA or LA thrombus treated with other NOACs, such as dabigatran and apixaban. However, there were 3 cases of patients who experienced embolic stroke and other thromboembolic events during taking apixaban or dabigatran for the treatment of LAA thrombus.^[13,15,22] Thus, it is necessary to monitor for thromboembolic complications after the initiation of NOAC for the treatment of LAA thrombus.^[13,15]

Current guidelines include treatment with vitamin K antagonist therapy such as warfarin to dissolve LAA thrombus for patients with valvular atrial fibrillation.^[23] However, the use of vitamin K antagonist is limited because of frequent dose adjustment, slow onset of action, and monitoring of coagulation status. NOACs provide some advantages over vitamin K antagonist with a fast onset, fewer drug interactions, a fixed dose without the need for coagulation monitoring. NOAC is not recommended in rheumatic mitral stenosis because of the lack of evidence from clinical trials. All contemporary trials comparing NOAC with warfarin excluded patients with clinically significant mitral stenosis.^[24-26] The use of dabigatran in patients with mechanical heart valves was associated with increased rate of thromboembolic complication, as compared with warfarin.^[27] The results from the study are not sufficient to address the issue of NOAC for prevention of thromboembolic events in patients with native valvular atrial fibrillation. In patients with mechanical heart valve, thrombin generation induced by the release of tissue factor from damaged tissues during surgery and by the exposure of the blood to the artificial surface of the valve leaflets and

sewing ring.^[27] In contrast, in patients with rheumatic mitral stenosis and atrial fibrillation, thrombin generation is triggered by left atrium blood flow stasis and endothelial dysfunction.^[27] The mechanism of risk for patients with mechanical heart valves may be substantially different from those with rheumatic mitral stenosis and may require different antithrombotic strategies.^[27] Therefore, there is no reason to think that rivaroxaban would not be effective in reducing stroke and systemic embolism in patients with mitral stenosis. Recently, several studies found that efficacy of rivaroxaban or apixaban or dabigatran versus warfarin was similar in patients with atrial fibrillation and other types of valvular heart disease.^[2,28,29] In the present report, rivaroxaban can even dissolve the LAA thrombi in patients with severe mitral stenosis, indicating that this drug could be a therapeutic option for patients with mitral stenosis. However, before its use can be recommended in patients with rheumatic mitral stenosis, additional randomized data are needed to prove these preliminary findings.

4. Conclusions

Direct FXa inhibitor, rivaroxaban, could resolve the LAA thrombus in patients with mitral stenosis. Further study is required before the routine use of rivaroxaban in patients with rheumatic mitral stenosis and atrial fibrillation.

References

- Petty GW, Khandheria BK, Whisnant JP, et al. Predictors of cerebrovascular events and death among patients with valvular heart disease: a population-based study. *Stroke* 2000;31:2628–35.
- Avezum A, Lopes RD, Schulte PJ, et al. Apixaban in comparison with warfarin in patients with atrial fibrillation and valvular heart disease: findings from the apixaban for reduction in stroke and other thromboembolic events in atrial fibrillation (ARISTOTLE) trial. *Circulation* 2015;132:624–32.
- Silaruks S, Thinkhamrop B, Kiatchoosakun S, et al. Resolution of left atrial thrombus after 6 months of anticoagulation in candidates for percutaneous transvenous mitral commissurotomy. *Ann Intern Med* 2004;140:101–5.
- Camm AJ, Kirchhof P, Lip GYH, et al. Guidelines for the management of atrial fibrillation: the Task Force for the Management of Atrial Fibrillation of the European Society of Cardiology (ESC). *Eur Heart J* 2010;31:2369–429.
- Lip GY, Hammerstingl C, Marin F, et al. Left atrial thrombus resolution in atrial fibrillation or flutter: results of a prospective study with rivaroxaban (X-TRA) and a retrospective observational registry providing baseline data (CLOT-AF). *Am Heart J* 2016;178:126–34.
- Kang DH, Song JK, Chae JK, et al. Comparison of outcomes of percutaneous mitral valvuloplasty versus mitral valve replacement after resolution of left atrial appendage thrombi by warfarin therapy. *Am J Cardiol* 1998;81:97–100.
- Vidal A, Vanerio G. Dabigatran and left atrial appendage thrombus. *J Thromb Thrombolysis* 2012;34:545–7.
- Takasugi J, Yamagami H, Okata T, et al. Dissolution of the left atrial appendage thrombus with rivaroxaban therapy. *Cerebrovasc Dis* 2013;36:322–3.
- Hammerstingl C, Pöttsch B, Nickenig G. Resolution of giant left atrial appendage thrombus with rivaroxaban. *Thromb Haemostasis* 2013;109:583–4.
- Morita S, Ajiro Y, Uchida Y, et al. Dabigatran for left atrial thrombus. *Eur Heart J* 2013;34:2745.
- Kawakami T, Kobayakawa H, Ohno H, et al. Resolution of left atrial appendage thrombus with apixaban. *Thromb J* 2013;11:26.
- Dobashi S, Fujino T, Ikeda T. Use of apixaban for an elderly patient with left atrial thrombus. *BMJ Case Rep* 2014;2014:
- Ohyagi M, Nakamura K, Watanabe M, et al. Embolic stroke during apixaban therapy for left atrial appendage thrombus. *J Stroke Cerebrovasc Dis* 2015;24:e101–2.
- Freixa X, Scalone G, Martín-Yuste V, et al. Large protruding thrombus over left atrial appendage occlusion device successfully treated with apixaban. *Eur Heart J* 2015;36:1427.
- Eftekhari A, Damgaard D, Grove EL. Fatal stroke following treatment with apixaban in a patient with atrial fibrillation and left atrial appendage thrombus. *Int J Cardiol* 2016;214:131–2.
- Lee SH, Han S. Series with complete resolution of left atrial appendage thrombi with apixaban in elderly patients. *Korean J Intern Med* 2016;31:396–8.
- Miwa Y, Minamishima T, Sato T, et al. Resolution of a warfarin and dabigatran-resistant left atrial appendage thrombus with apixaban. *J Arrhythm* 2016;32:233–5.
- Piotrowski R, Zaborska B, Baran J, et al. Rivaroxaban twice daily for lysis of left atrial appendage thrombus: a potential new therapeutic option. *Pol Arch Med Wewn* 2016;126:430–1.
- Lip GY, Hammerstingl C, Marin F, et al. Rationale and design of a study exploring the efficacy of once-daily oral rivaroxaban (X-TRA) on the outcome of left atrial/left atrial appendage thrombus in nonvalvular atrial fibrillation or atrial flutter and a retrospective observational registry providing baseline data (CLOT-AF). *Am Heart J* 2015;169:464–71.
- Varin R, Mirshahi S, Mirshahi P, et al. Whole blood clots are more resistant to lysis than plasma clots—greater efficacy of rivaroxaban. *Thromb Res* 2013;131:100–9.
- Yasaka M, Yamaguchi T, Miyashita T, et al. Regression of intracardiac thrombus after embolic stroke. *Stroke* 1990;21:1540–4.
- Janssen AM, van de Kerkhof D, Szabó B, et al. Left atrial thrombus under dabigatran in a patient with nonvalvular atrial fibrillation. *Neth J Med* 2016;74:313–5.
- January CT, Wann LS, Alpert JS, et al. 2014 AHA/ACC/HRS guideline for the management of patients with atrial fibrillation: executive summary: a report of the American College of Cardiology/American Heart Association Task Force on practice guidelines and the Heart Rhythm Society. *Circulation* 2014;130:2071–104.
- Connolly SJ, Ezekowitz MD, Yusuf S, et al. Dabigatran versus warfarin in patients with atrial fibrillation. *N Engl J Med* 2009;361:1139–51.
- Granger CB, Alexander JH, McMurray JJ, et al. Apixaban versus warfarin in patients with atrial fibrillation. *N Engl J Med* 2011;365:981–92.
- Patel MR, Mahaffey KW, Garg J, et al. Rivaroxaban versus warfarin in nonvalvular atrial fibrillation. *N Engl J Med* 2011;365:883–91.
- Eikelboom JW, Connolly SJ, Brueckmann M, et al. Dabigatran versus warfarin in patients with mechanical heart valves. *N Engl J Med* 2013;369:1206–14.
- Breithardt G, Baumgartner H, Berkowitz SD, et al. Clinical characteristics and outcomes with rivaroxaban vs. warfarin in patients with non-valvular atrial fibrillation but underlying native mitral and aortic valve disease participating in the ROCKET AF trial. *Eur Heart J* 2014;35:3377–85.
- Ezekowitz MD, Nagarakanti R, Noack H, et al. Comparison of dabigatran and warfarin in patients with atrial fibrillation and valvular heart disease: the RE-LY Trial (Randomized Evaluation of Long-Term Anticoagulant Therapy). *Circulation* 2016;134:589–98.